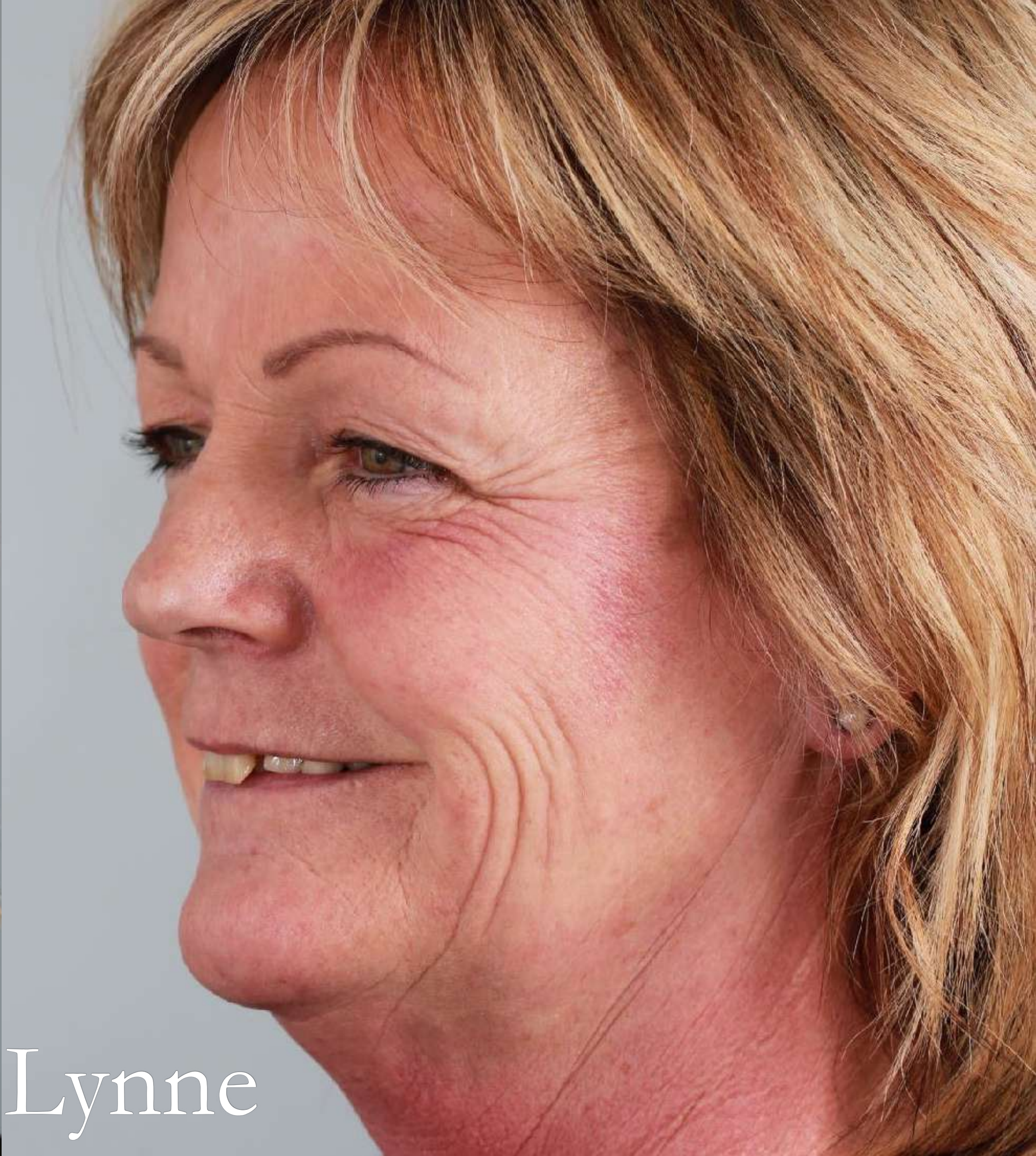
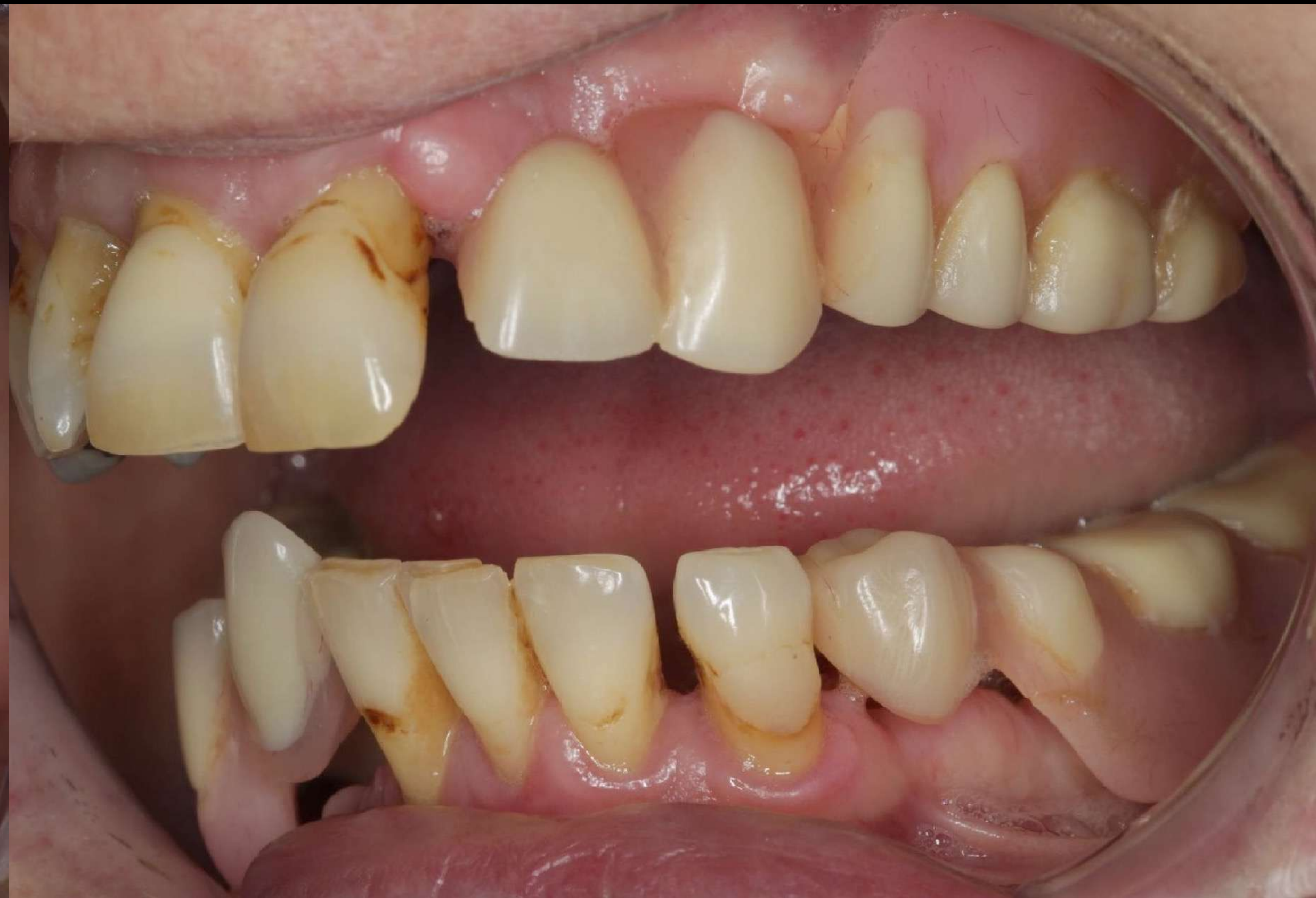
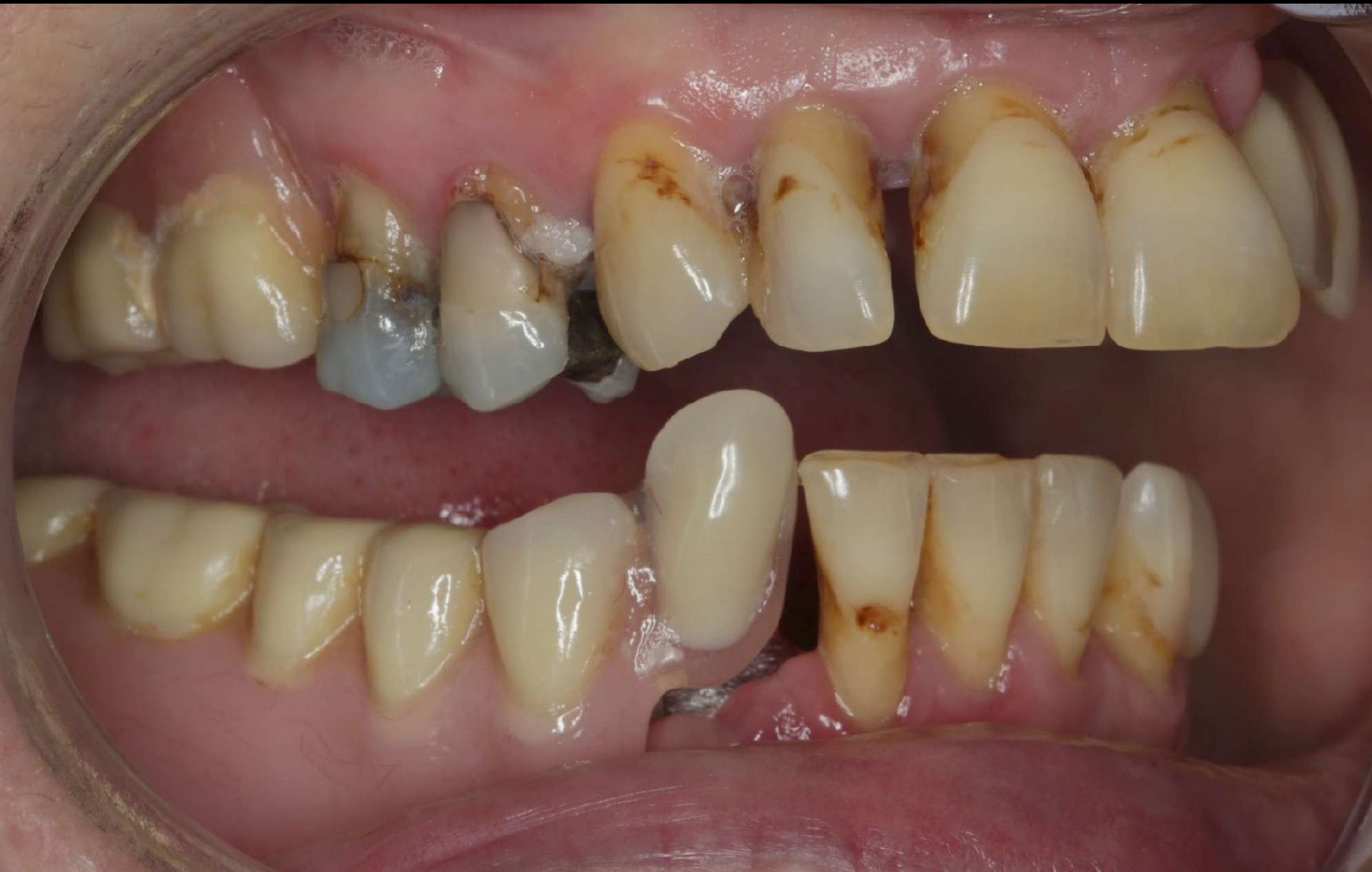

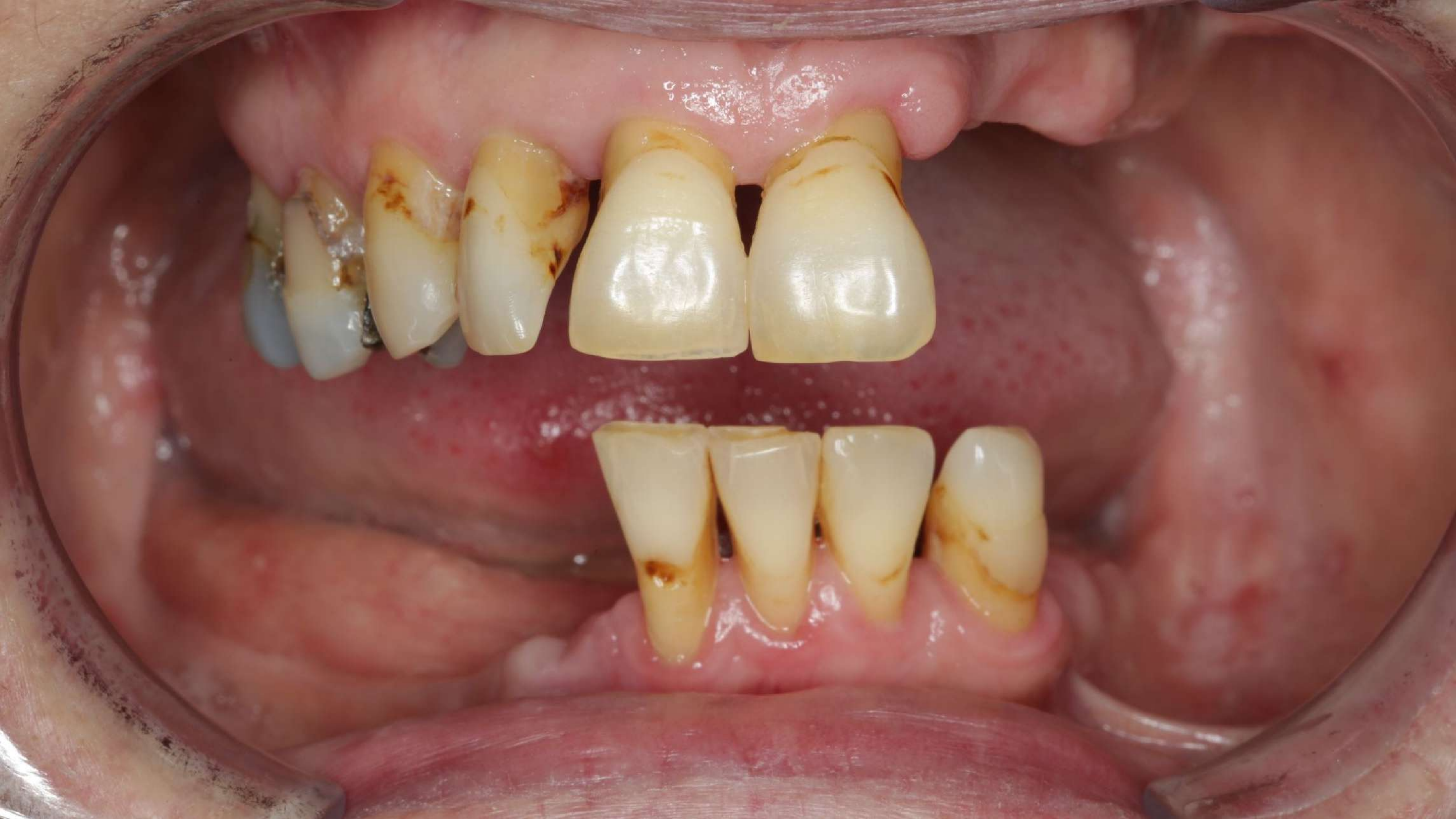Lynne











Lynne makes this part



F 35 Lightning







F 35 Lightning

v

Mclaren Speedtail

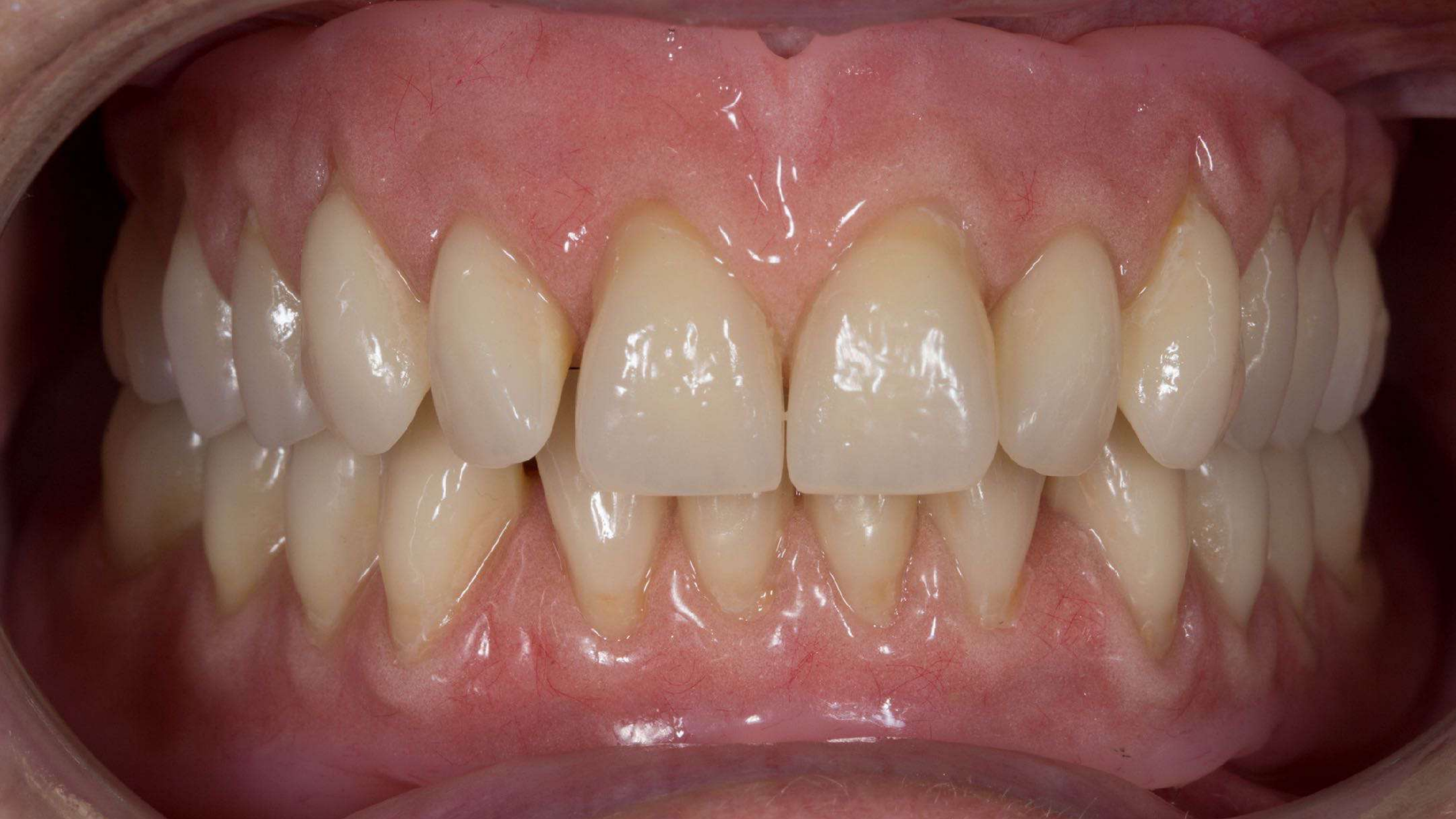



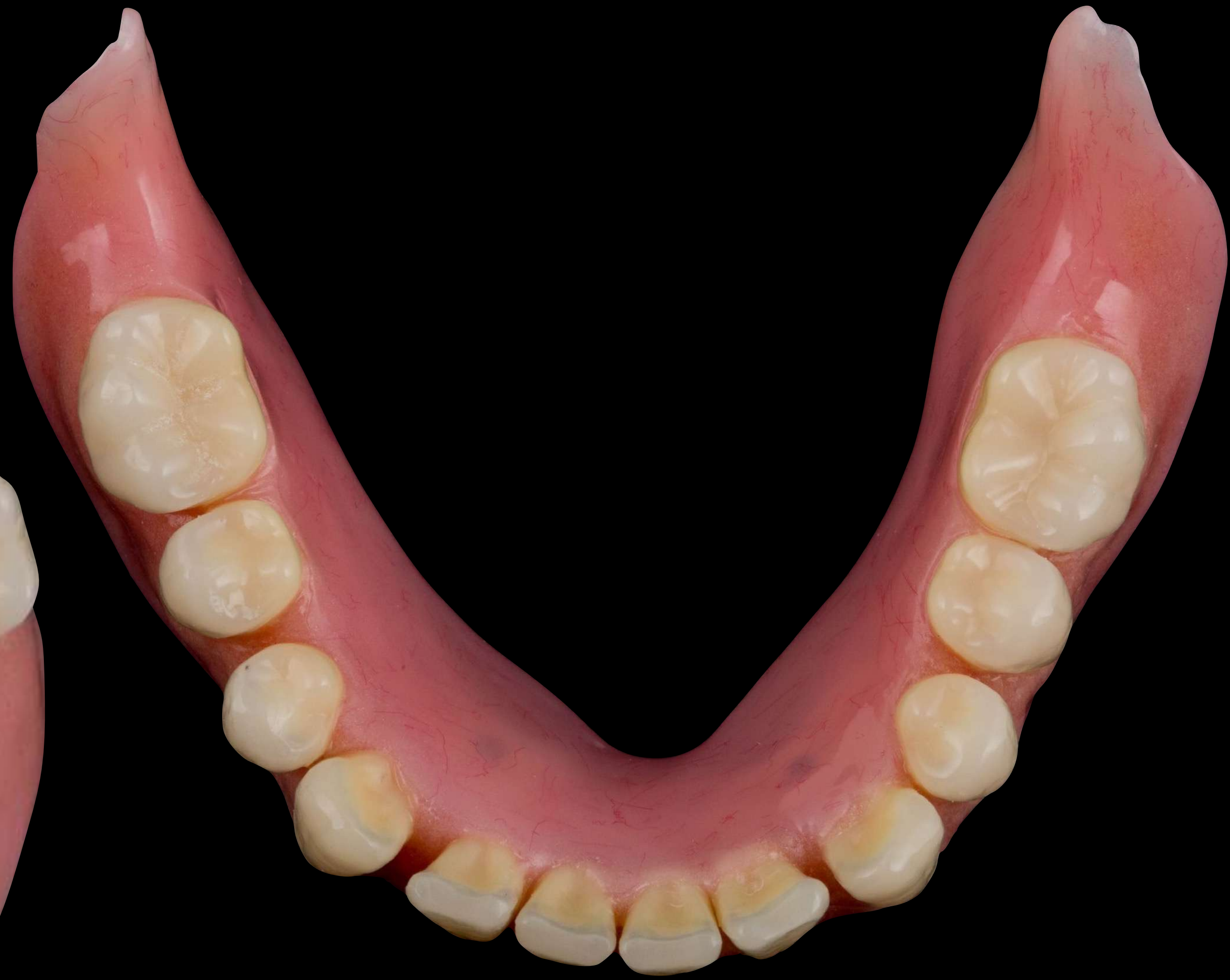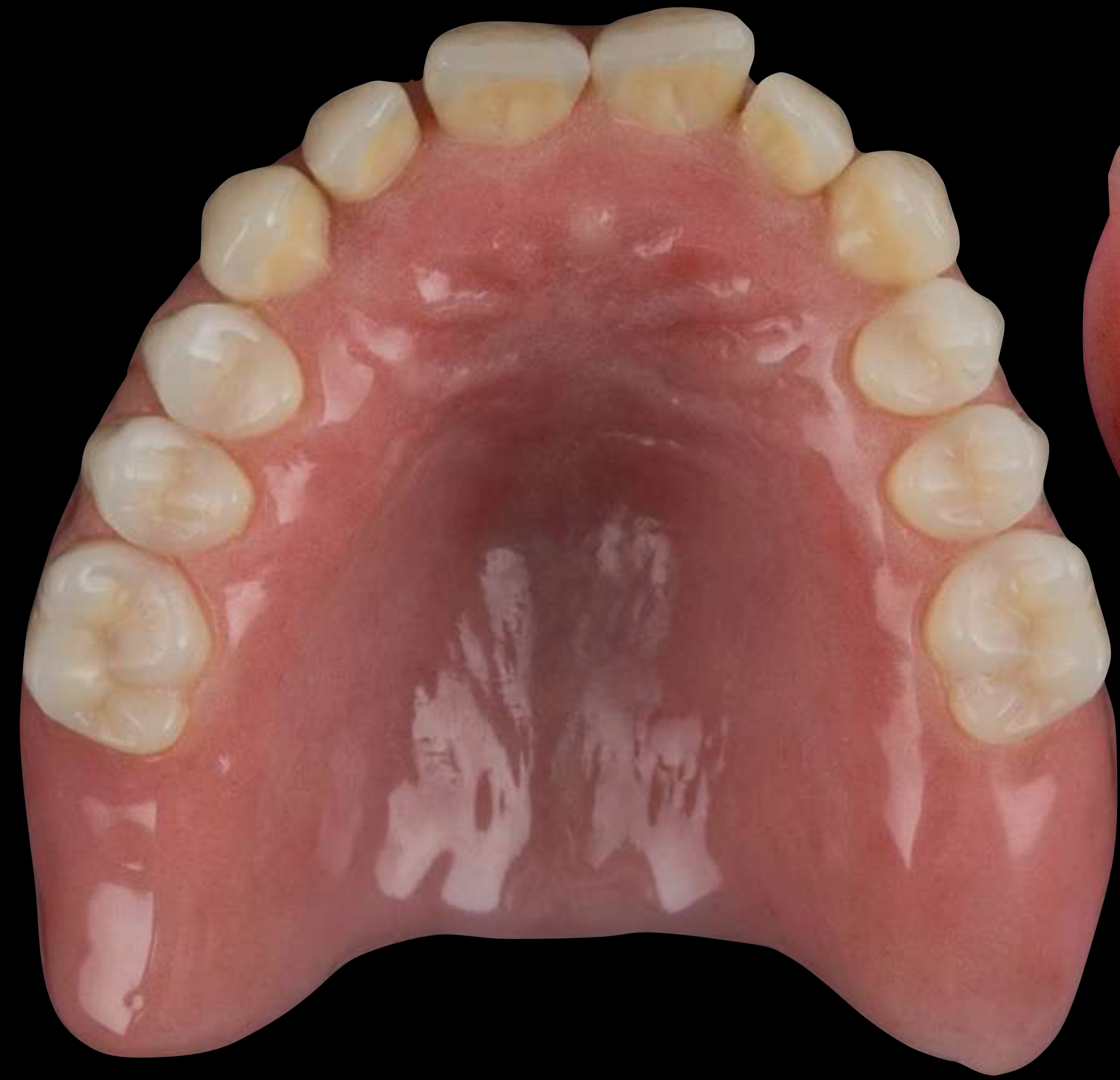A clinical photograph of a patient's upper and lower teeth. The upper teeth show significant yellowish-brown staining and recession of the gingiva. The lower teeth also show staining and recession. The text 'Hopeless prognosis' is overlaid in white serif font on a semi-transparent dark background.

Hopeless  
prognosis

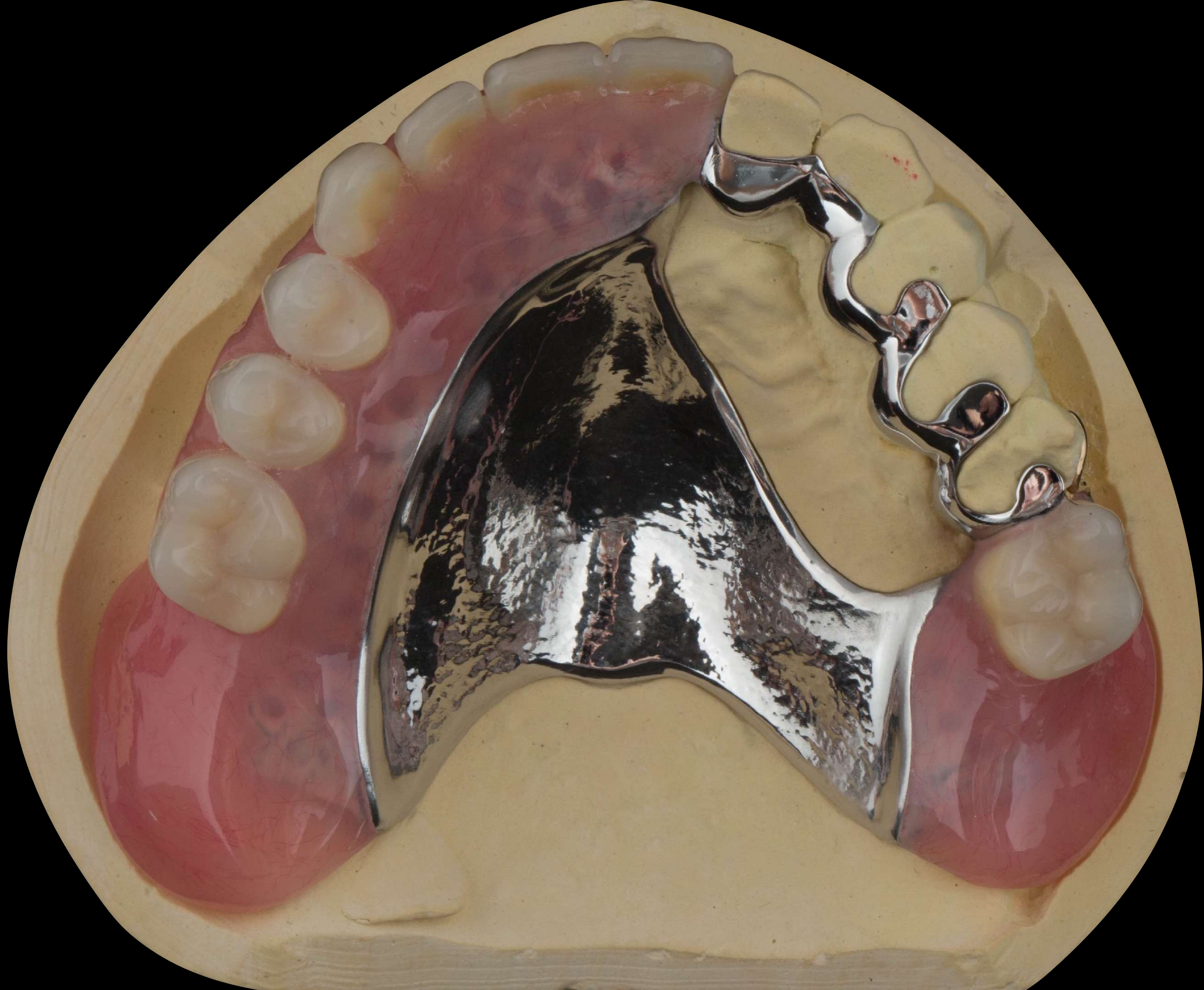




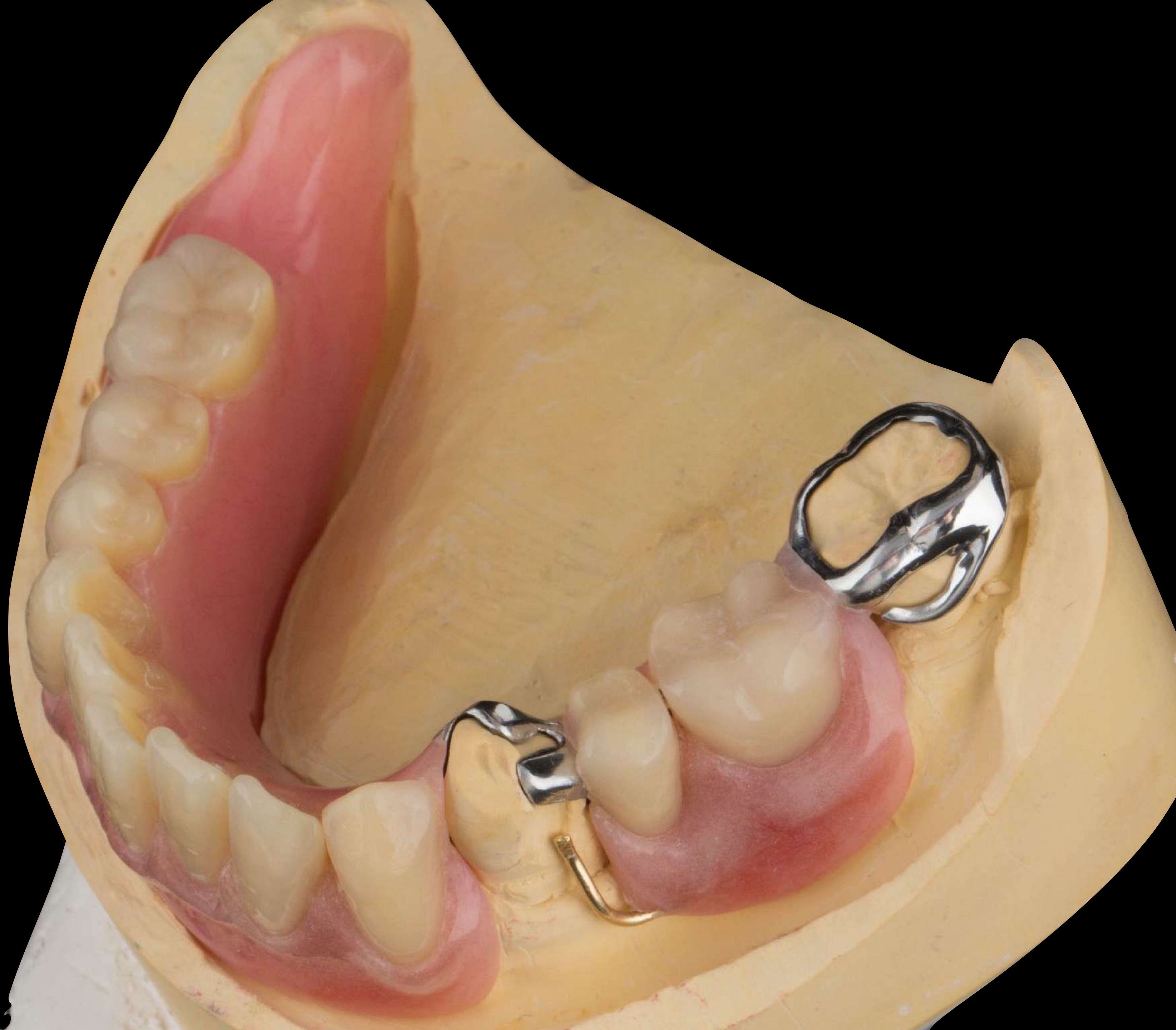




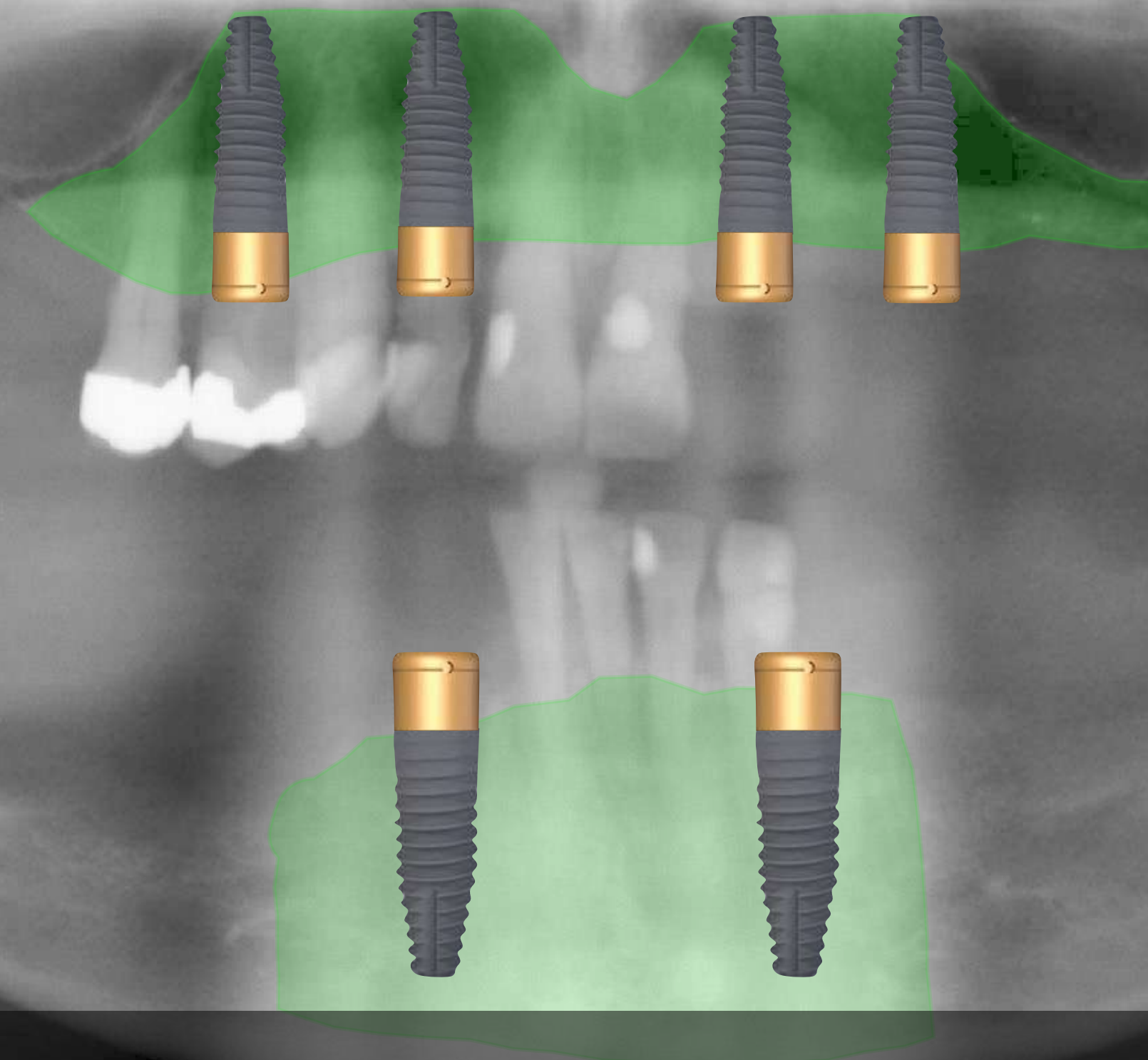








# Implant supported over dentures

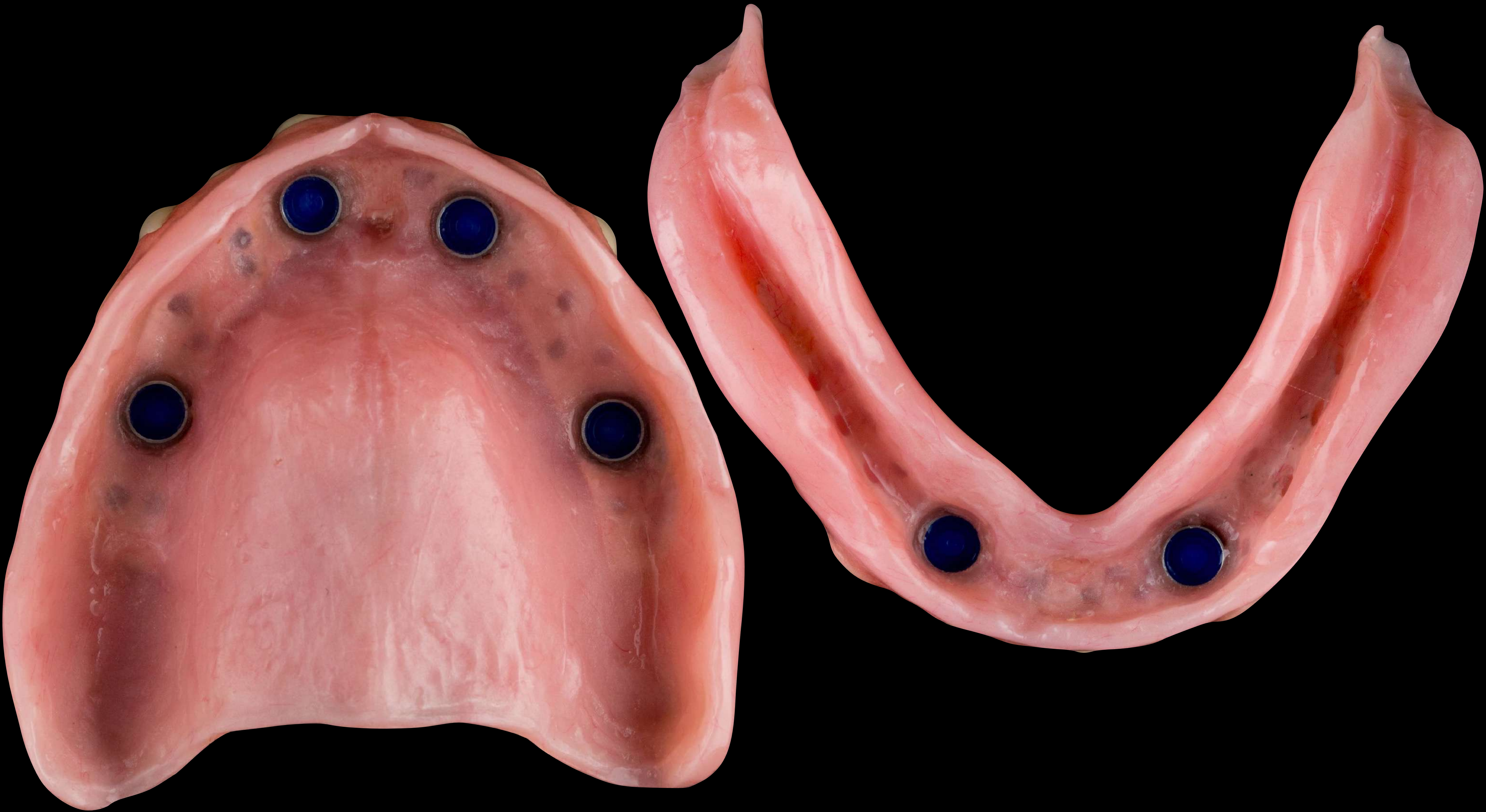

R


£25K (2015)

L









Before



After









F 35 Lightning

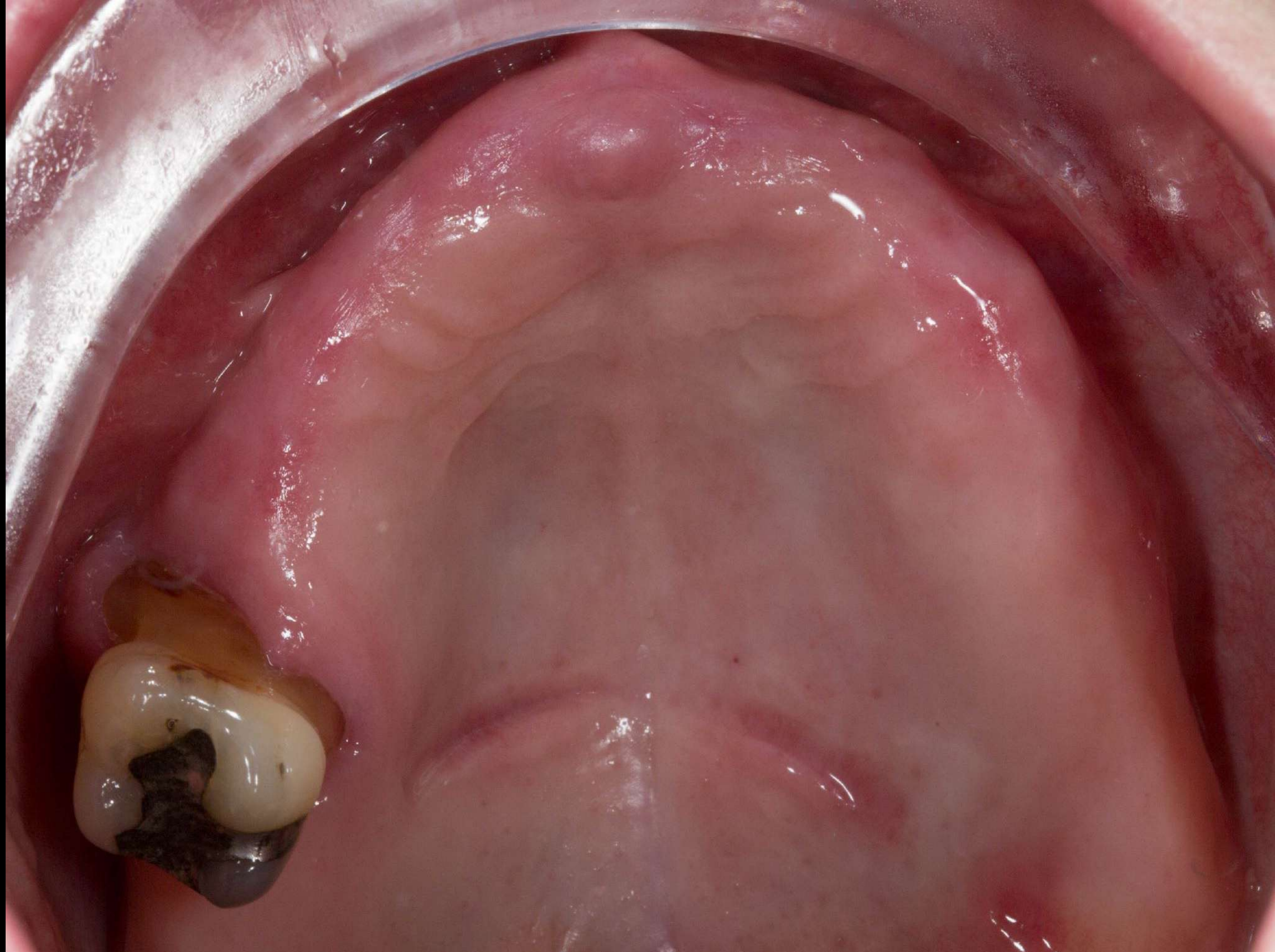



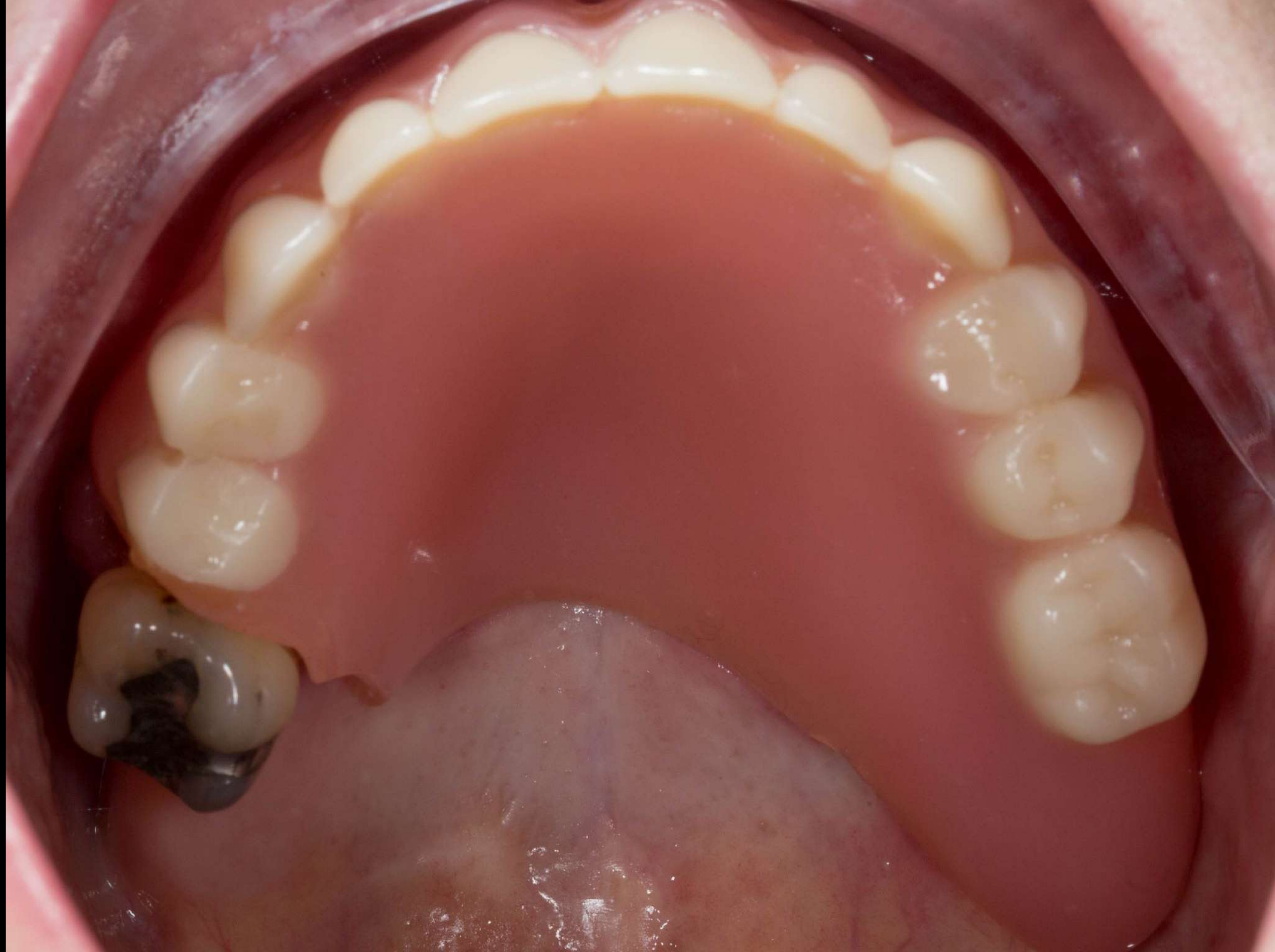
Olga







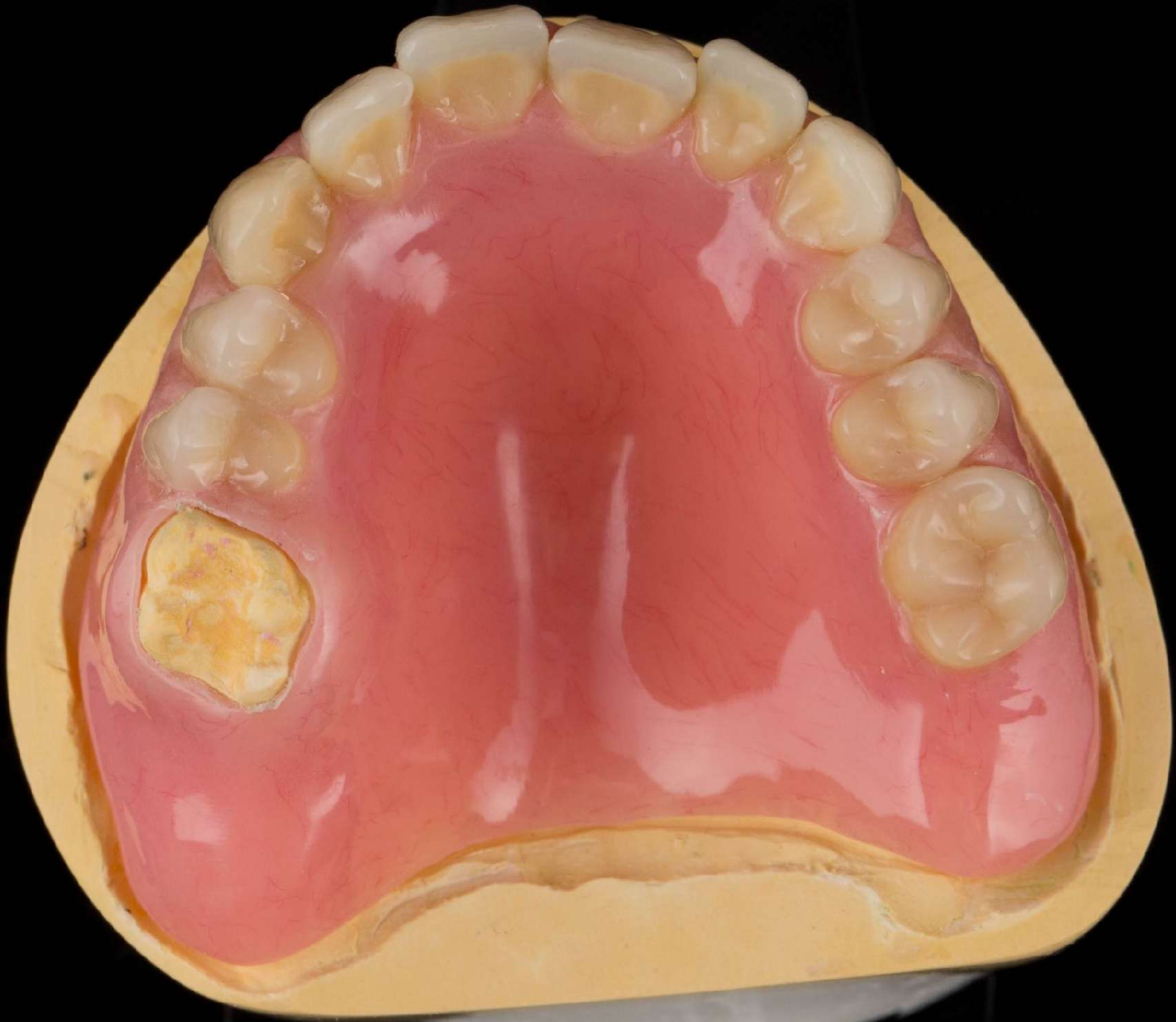



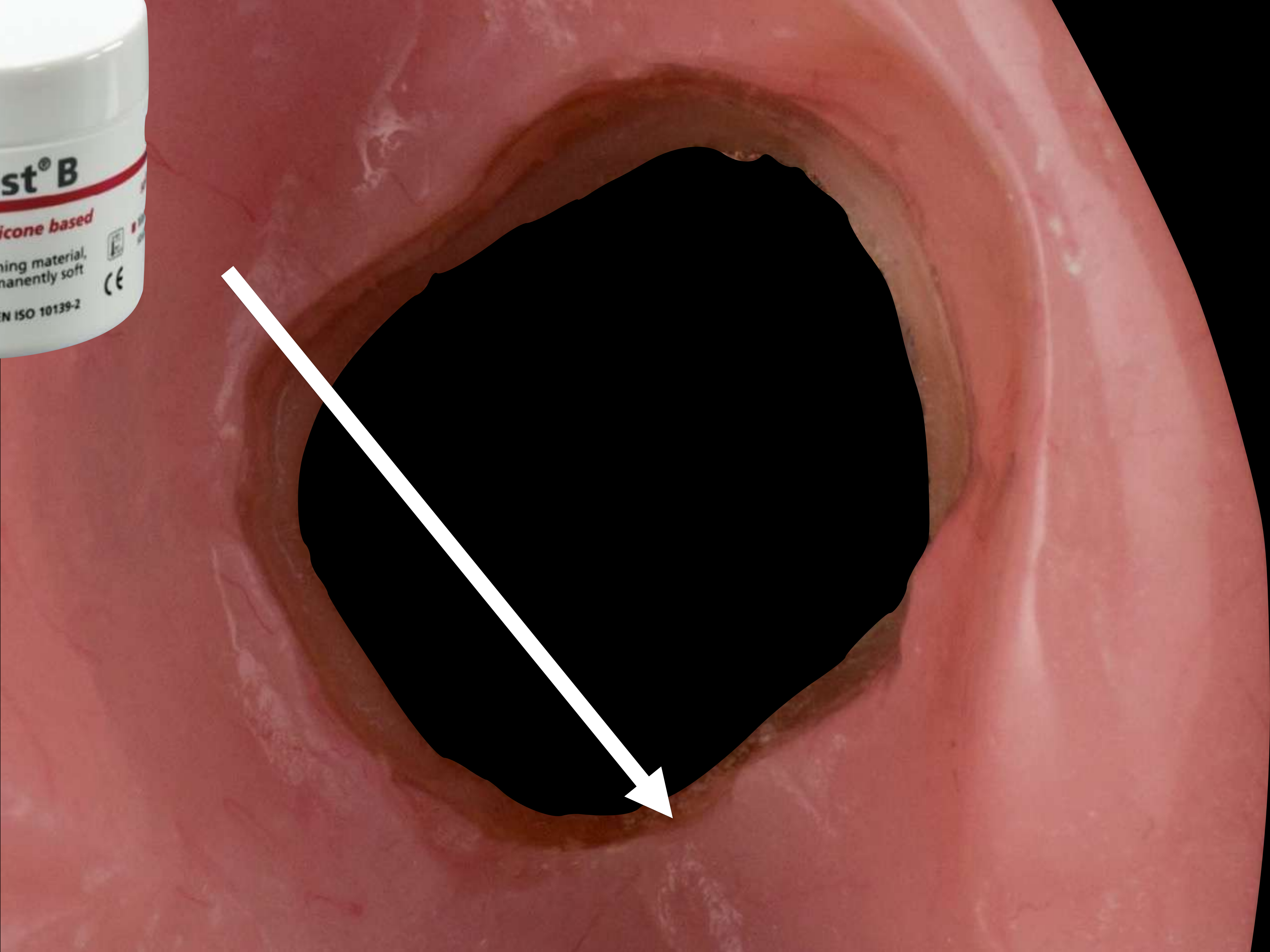

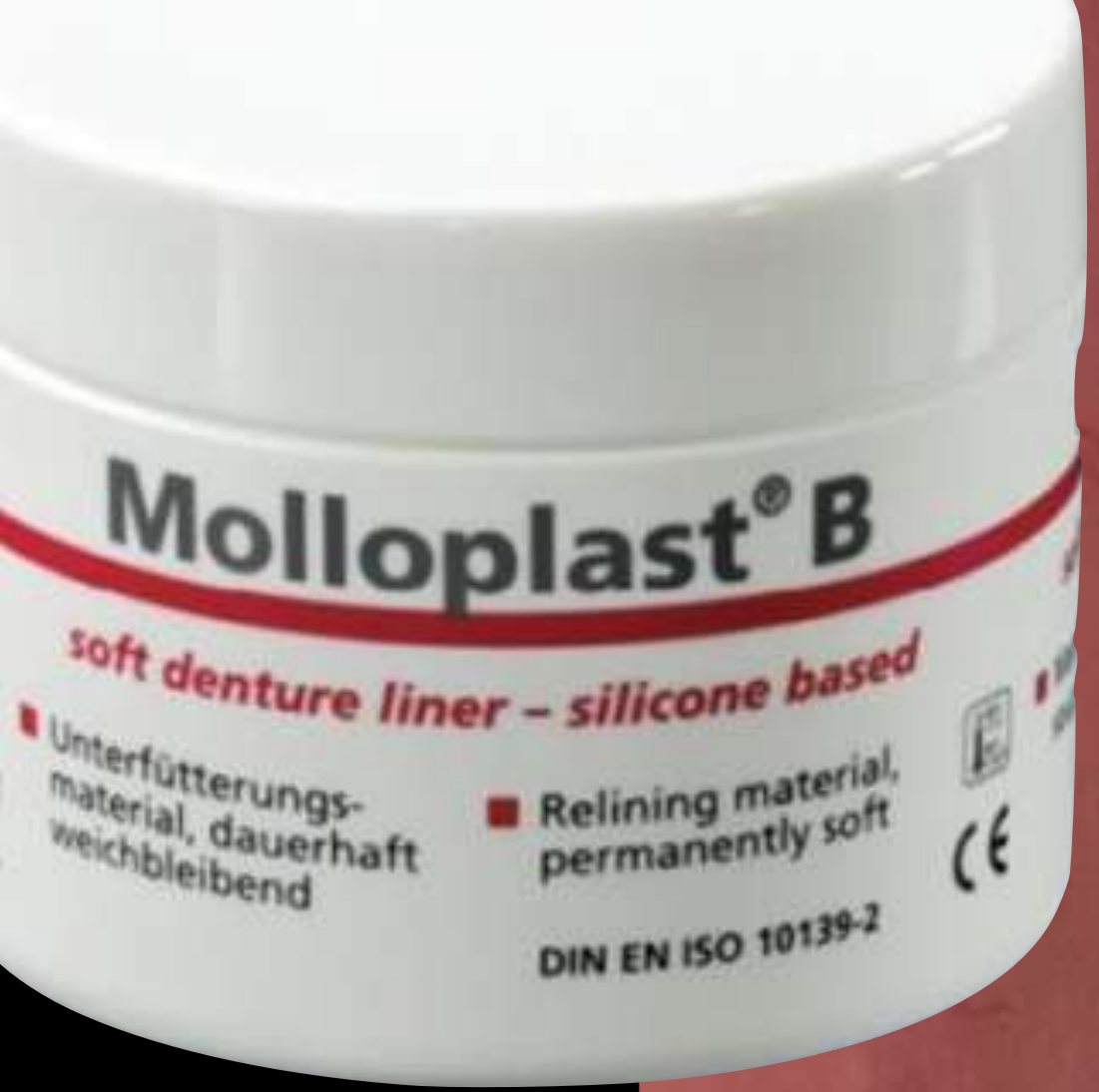




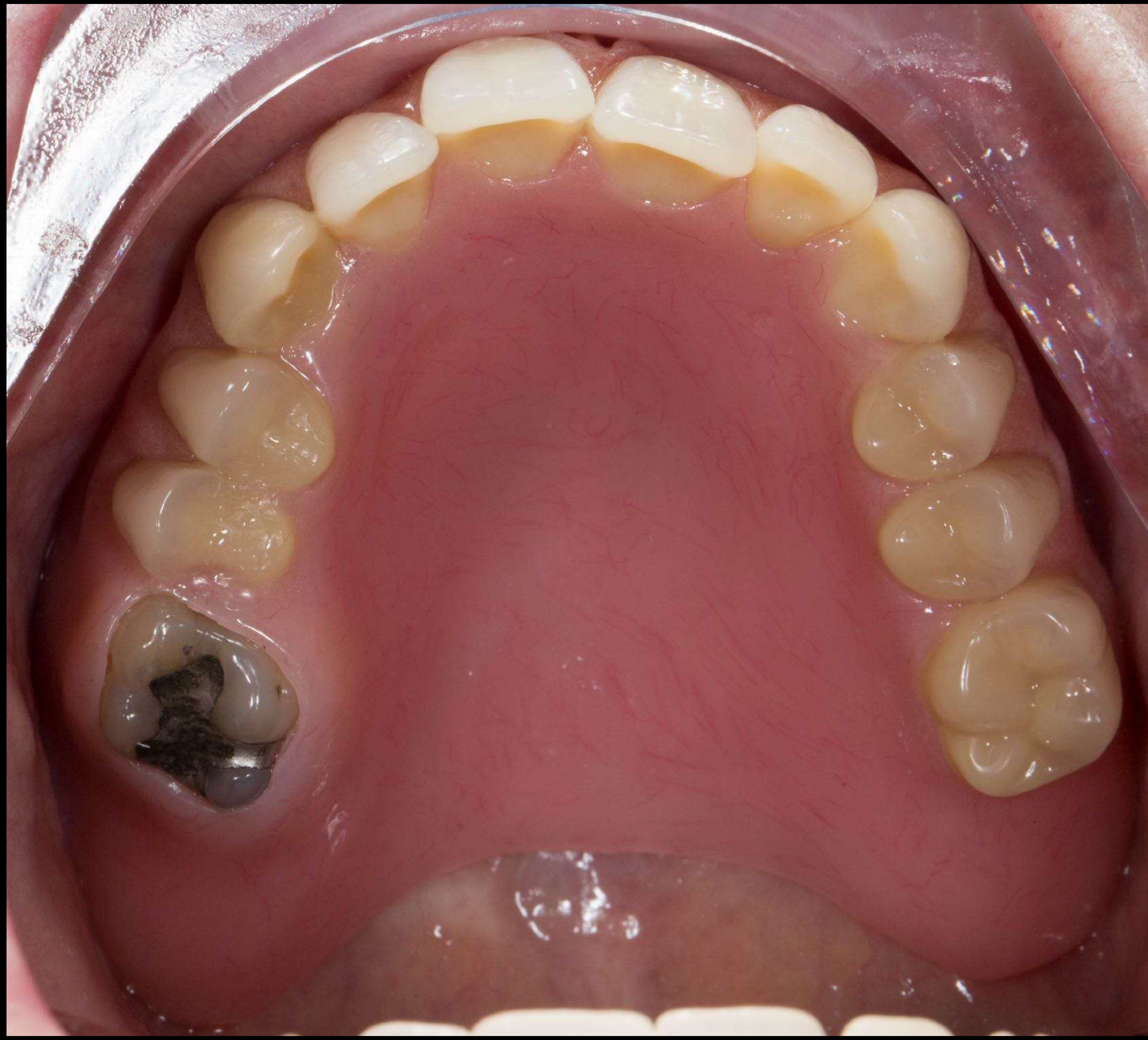








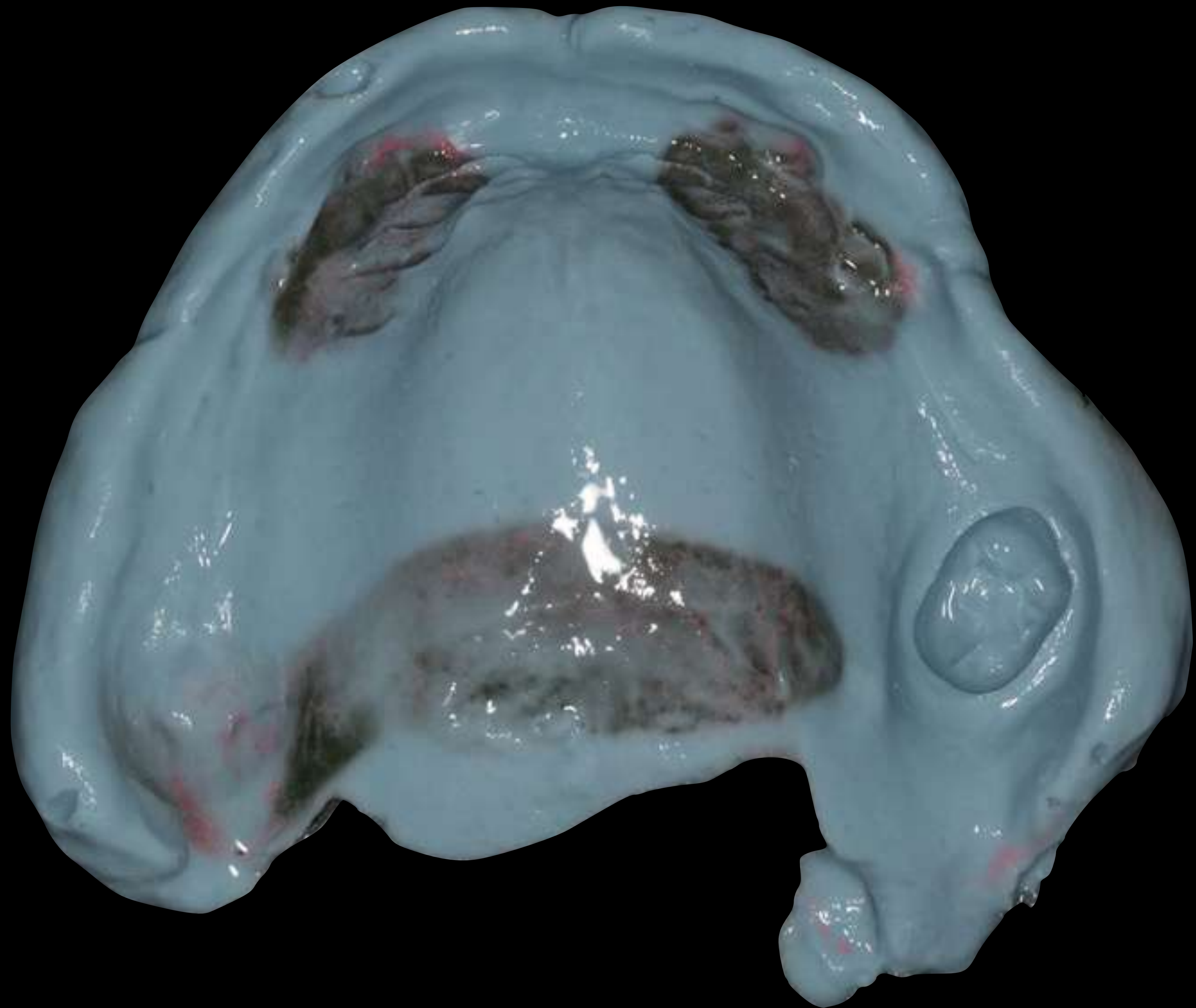




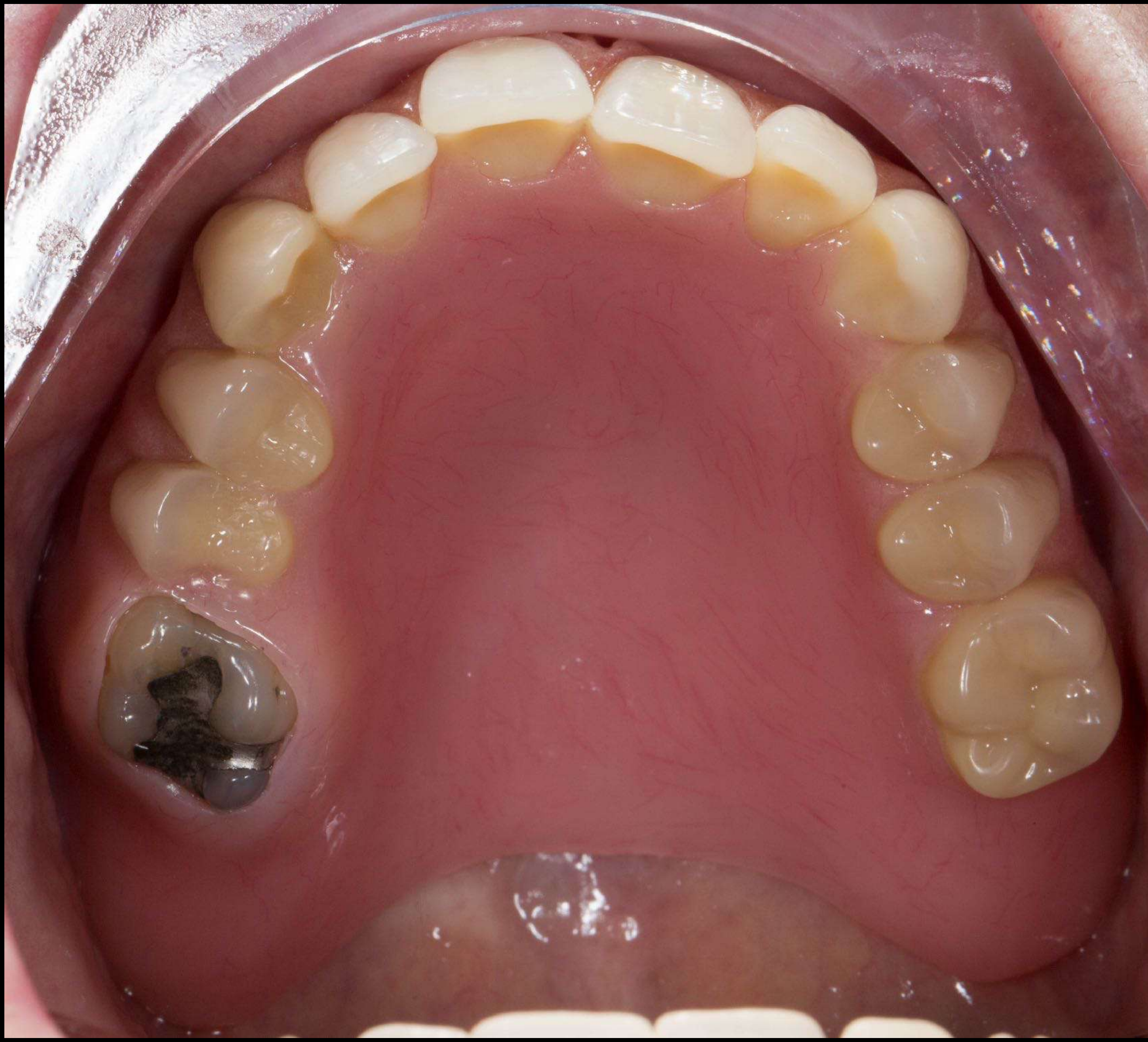



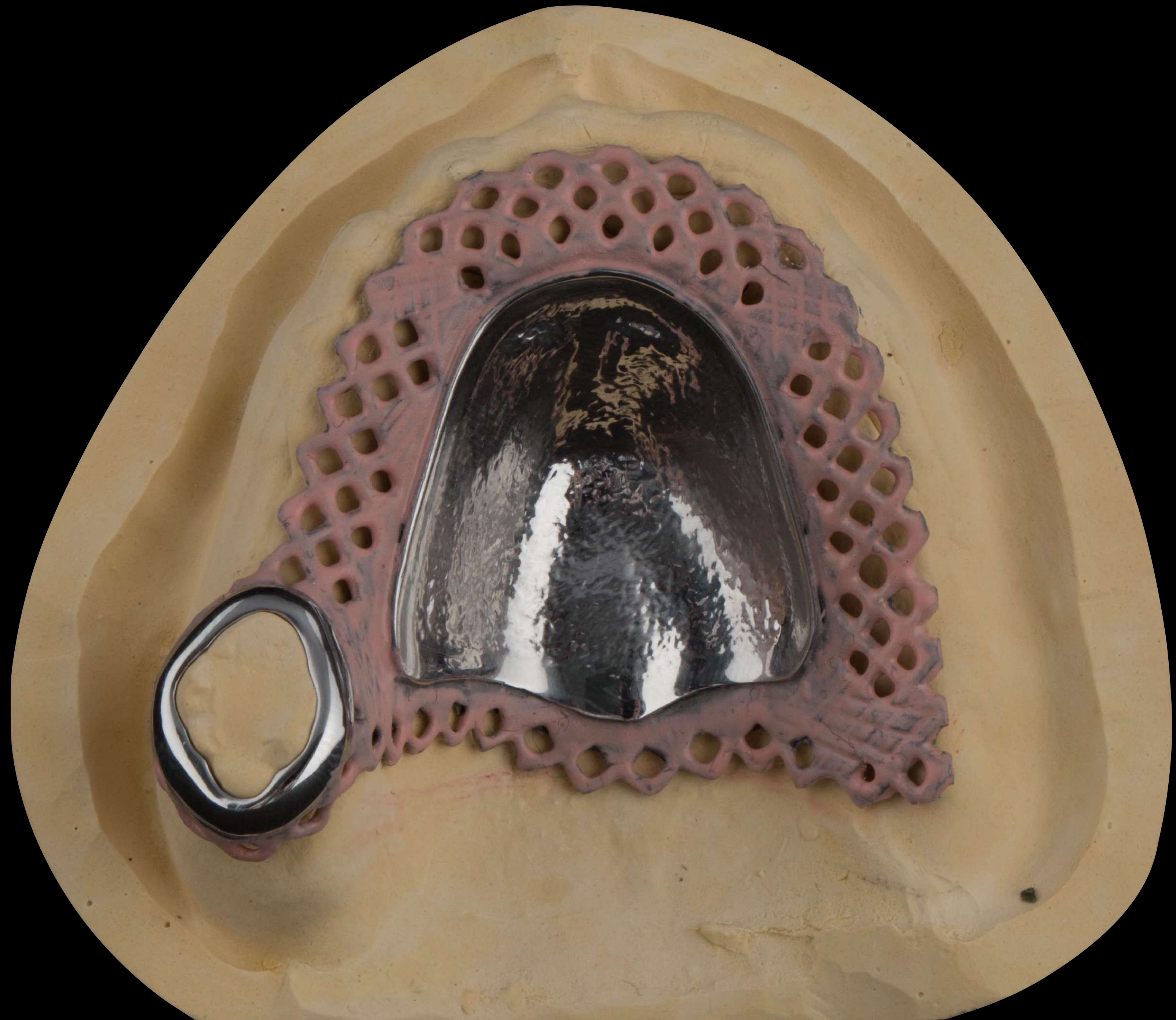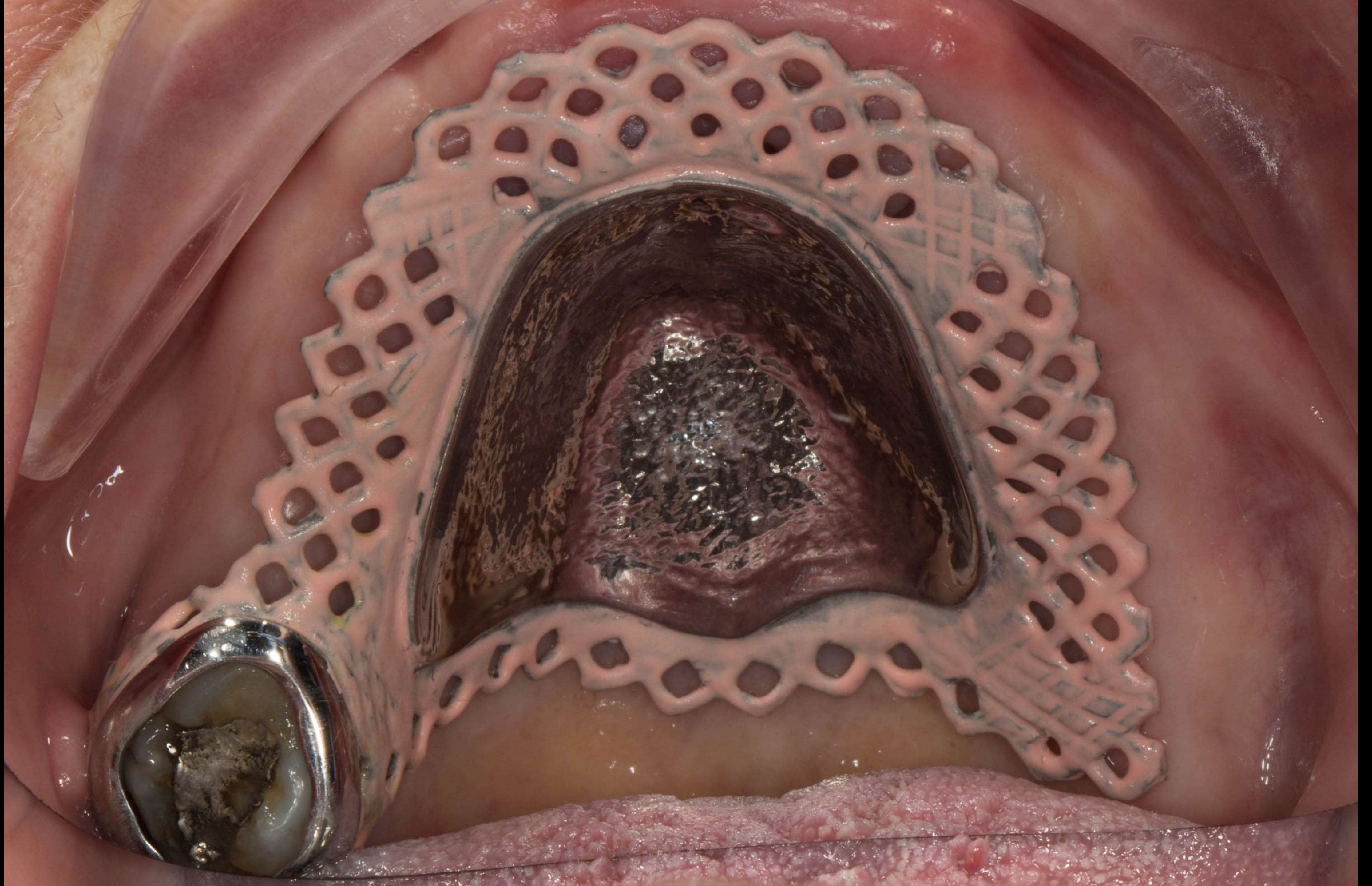




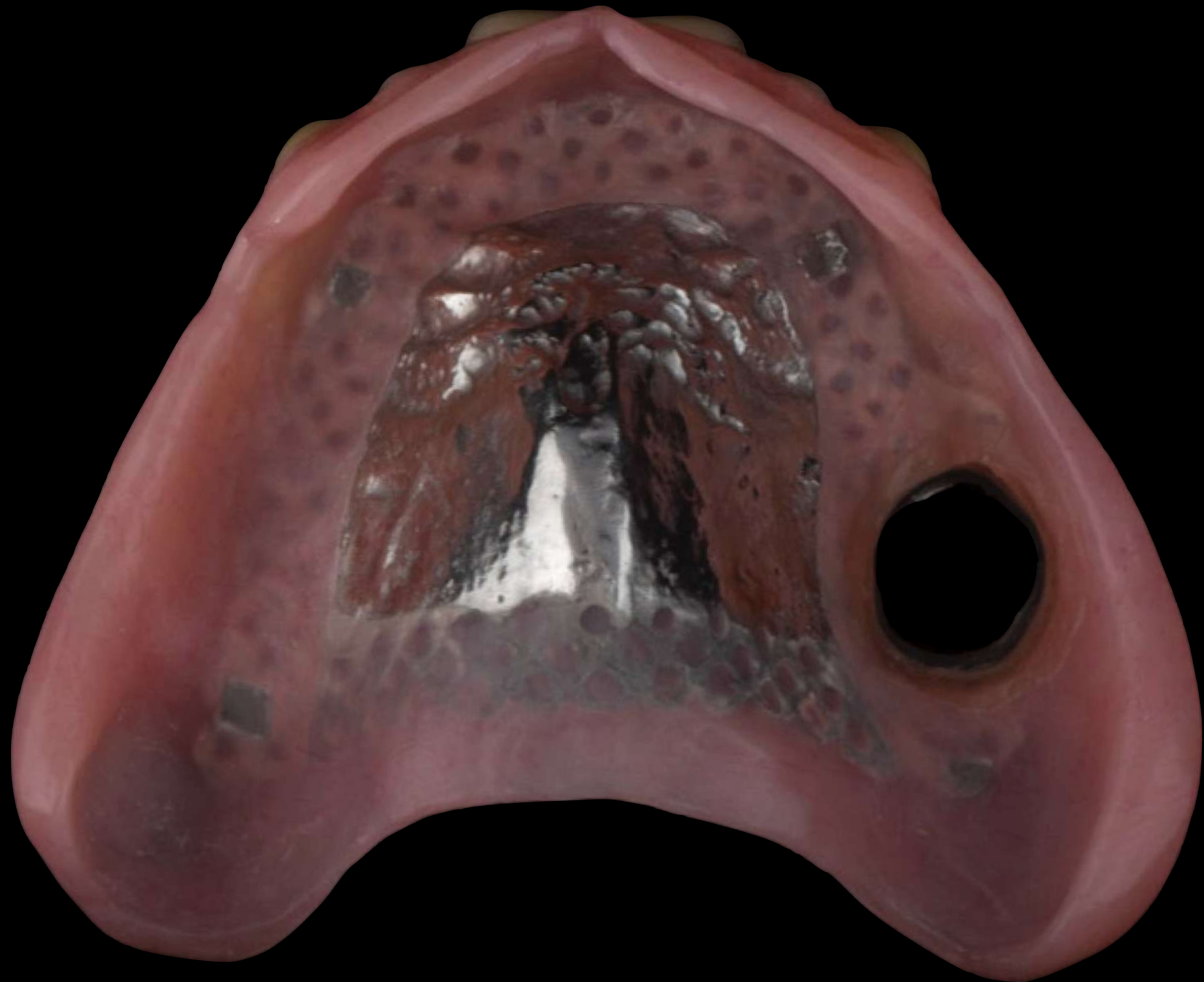












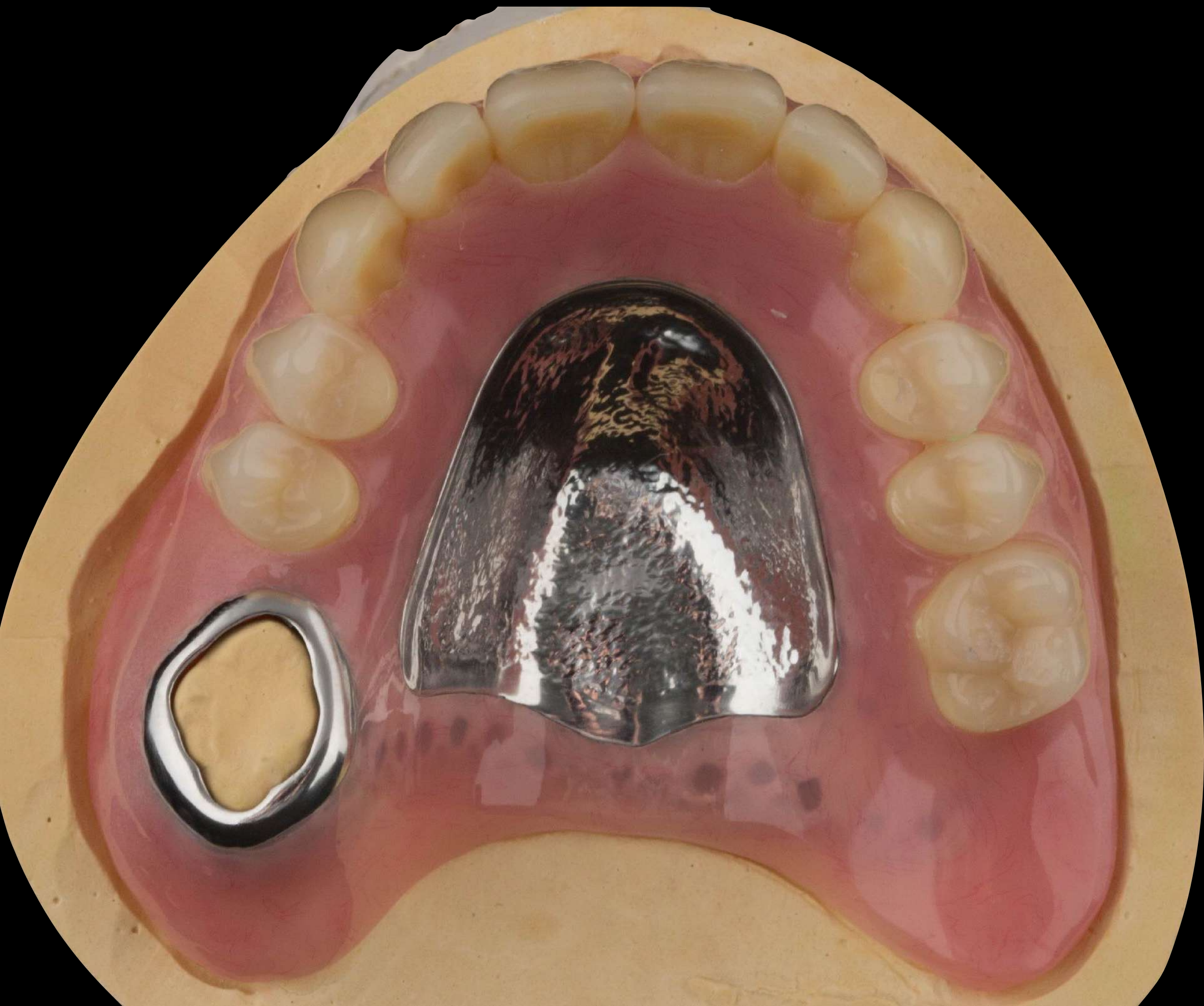

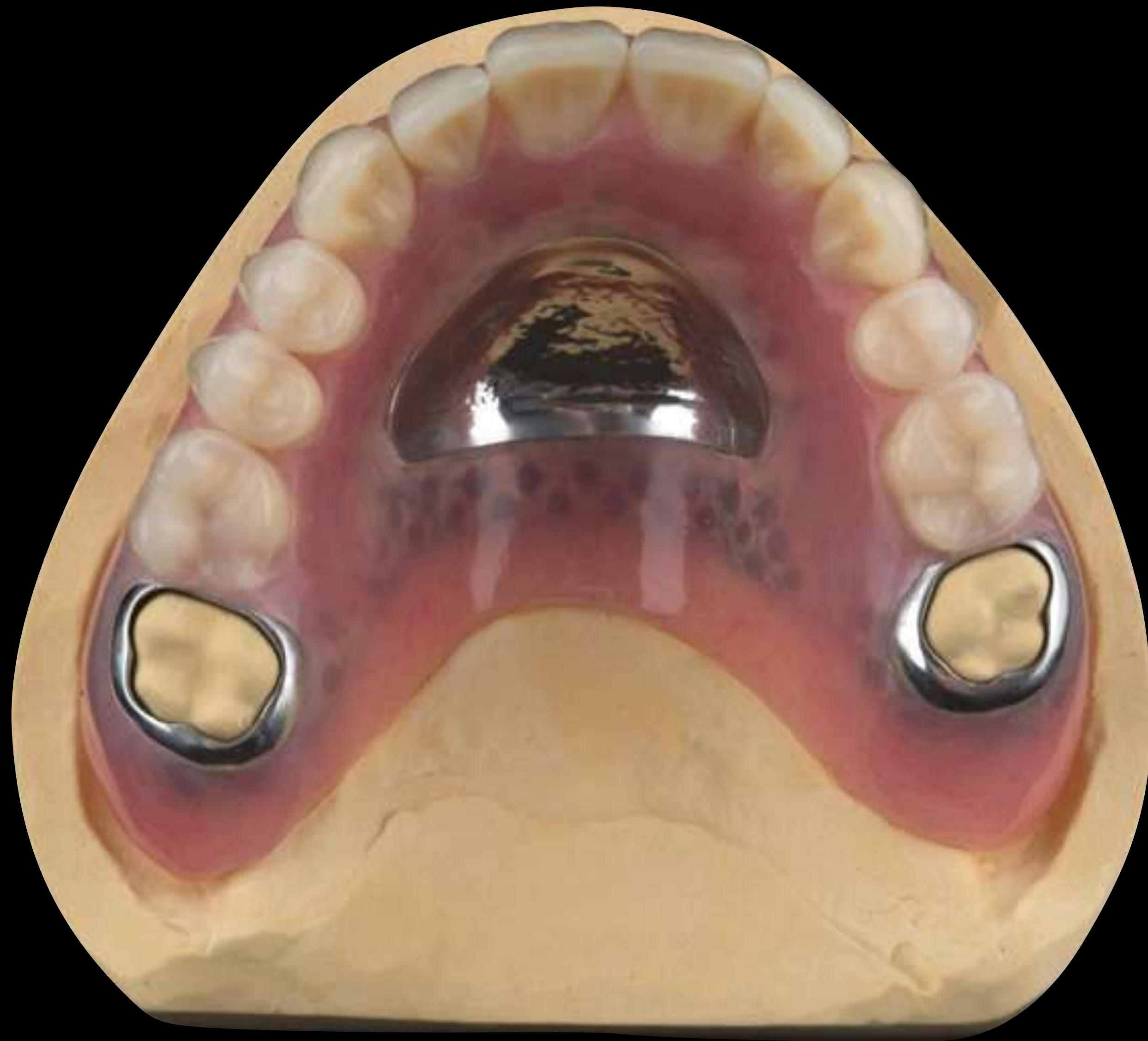One molar



Two molars





Achieving great aesthetics?



Muriel





Muriel

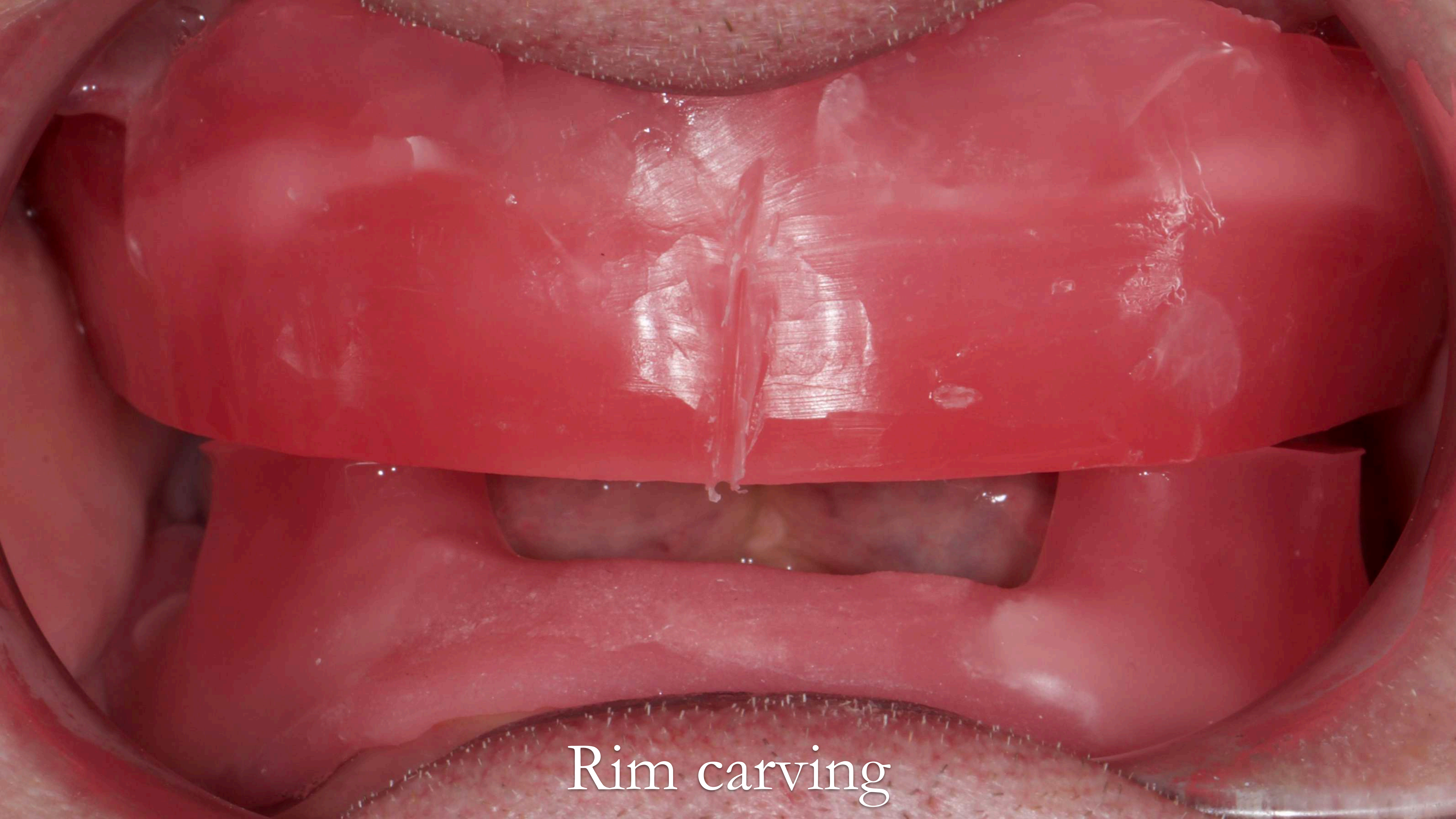




Muriel



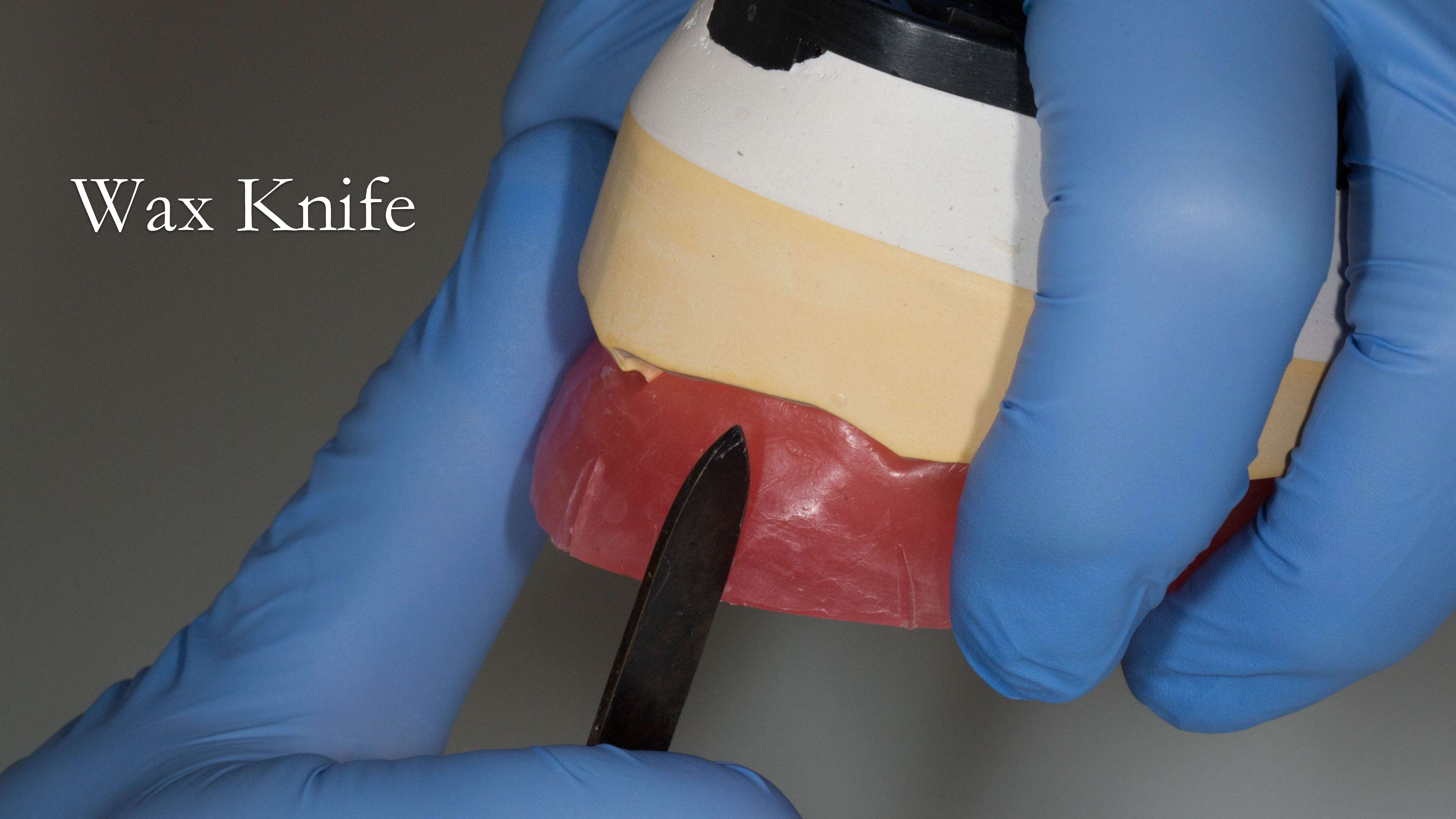




Rim carving

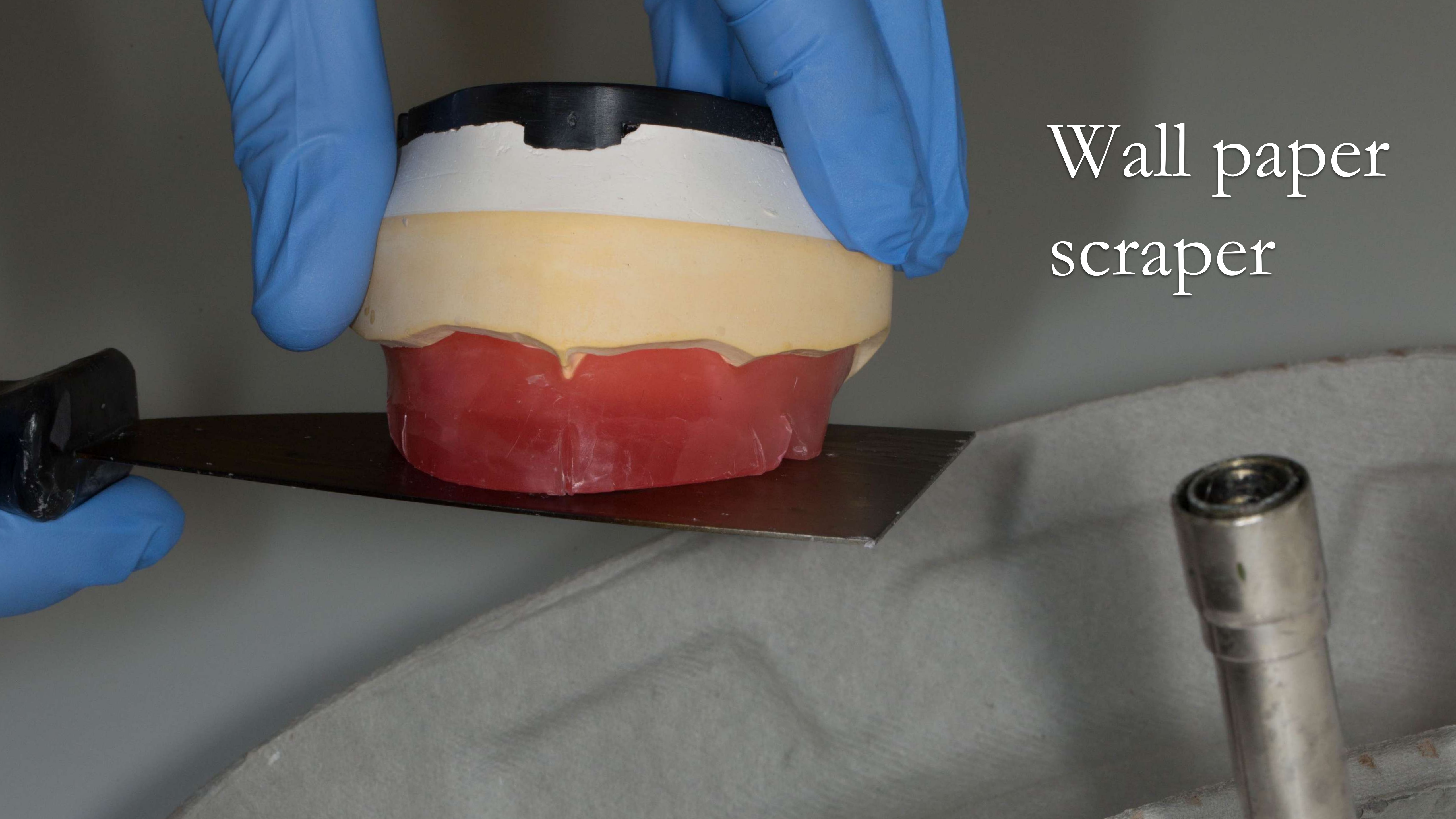

# Wax Knife

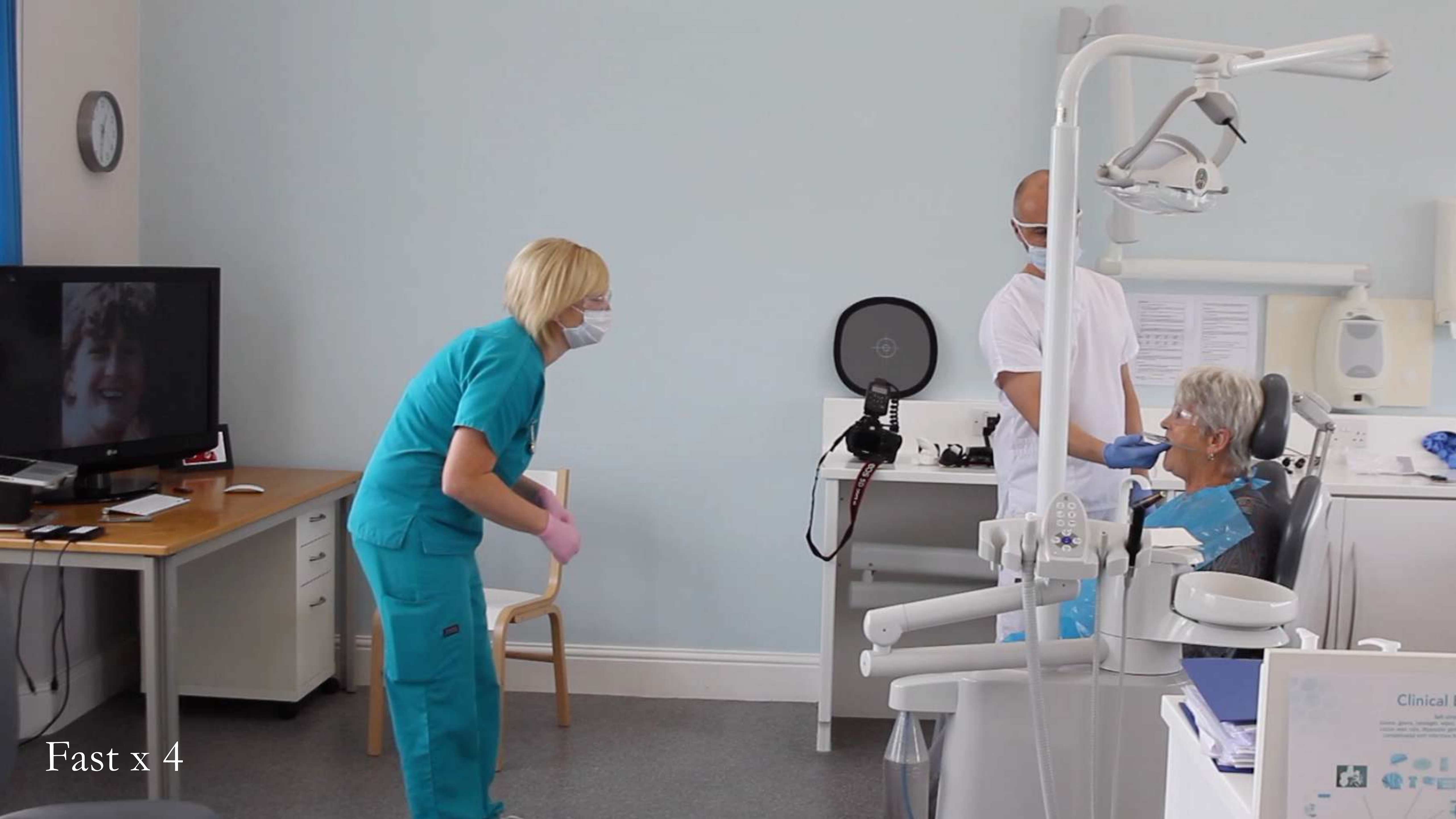



Wall paper  
scraper

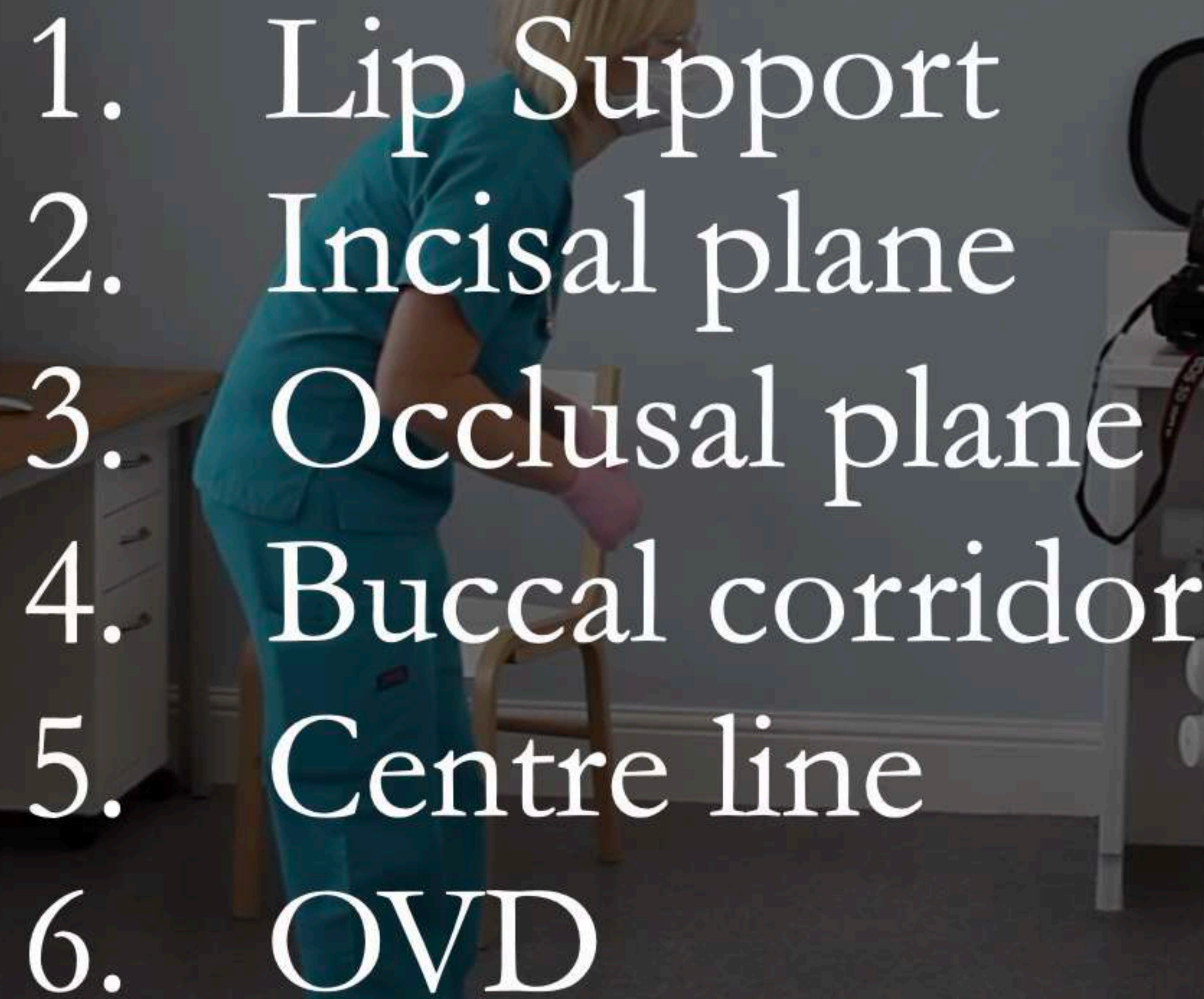







Fast x 4



- 
1. Lip Support
  2. Incisal plane
  3. Occlusal plane
  4. Buccal corridor
  5. Centre line
  6. OVD









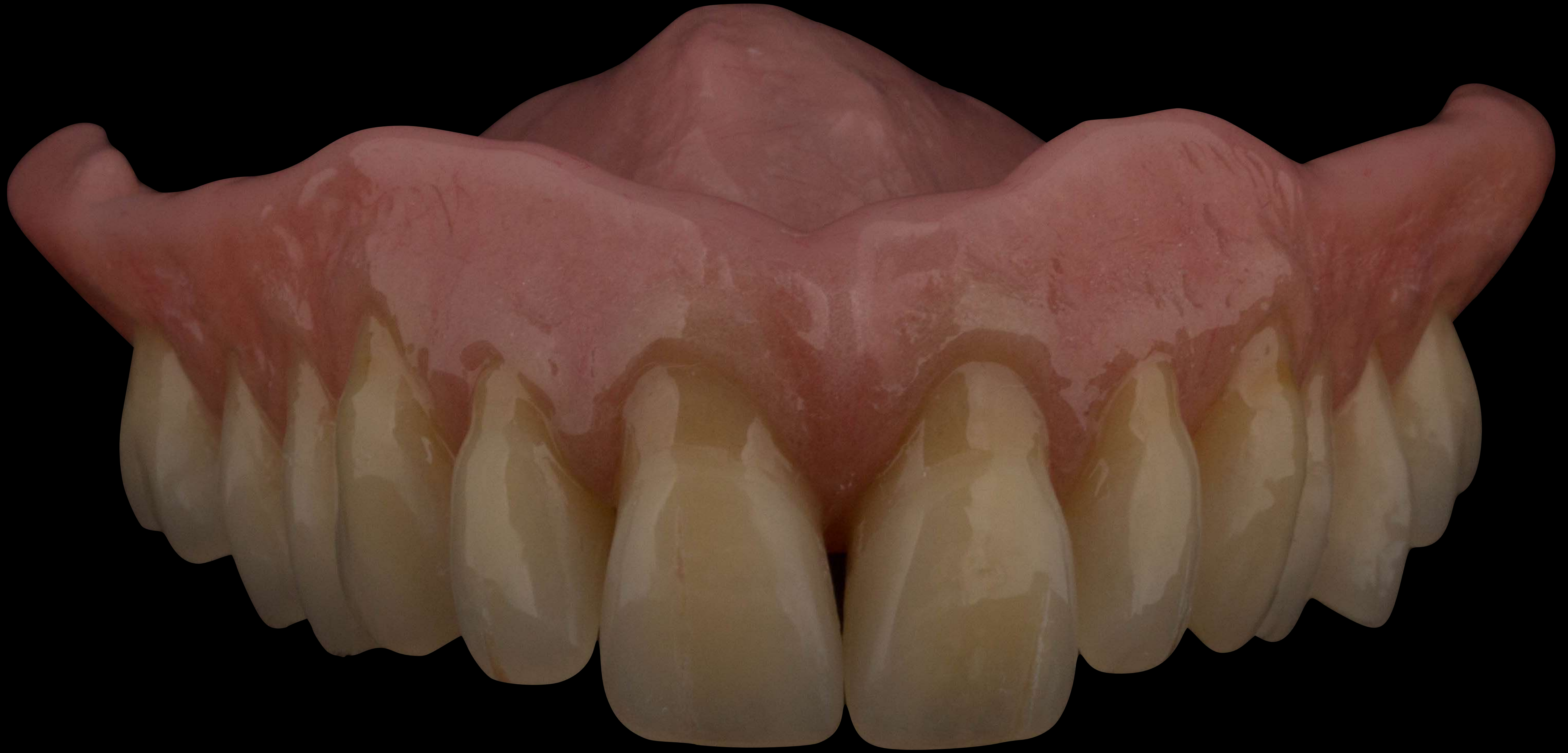# The “must have” photos for Dental Technician











Schottlander Enigmalive teeth



# Manchester DH



# Liverpool DH



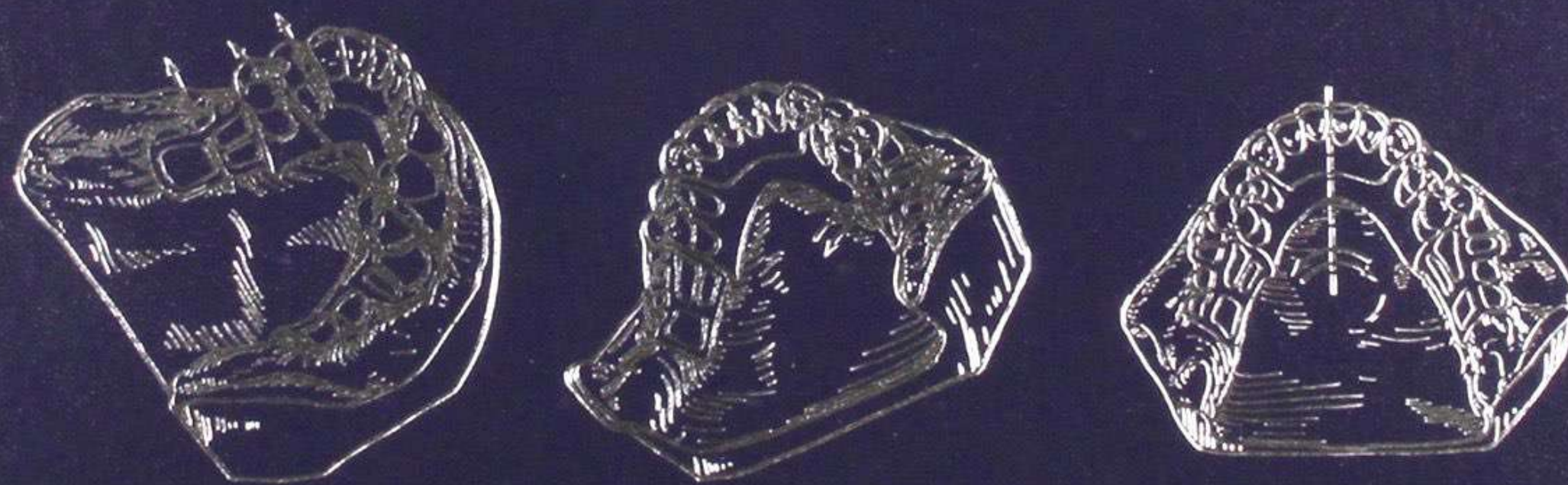

McCRACKEN'S

---

Removable  
Partial Prosthodontics

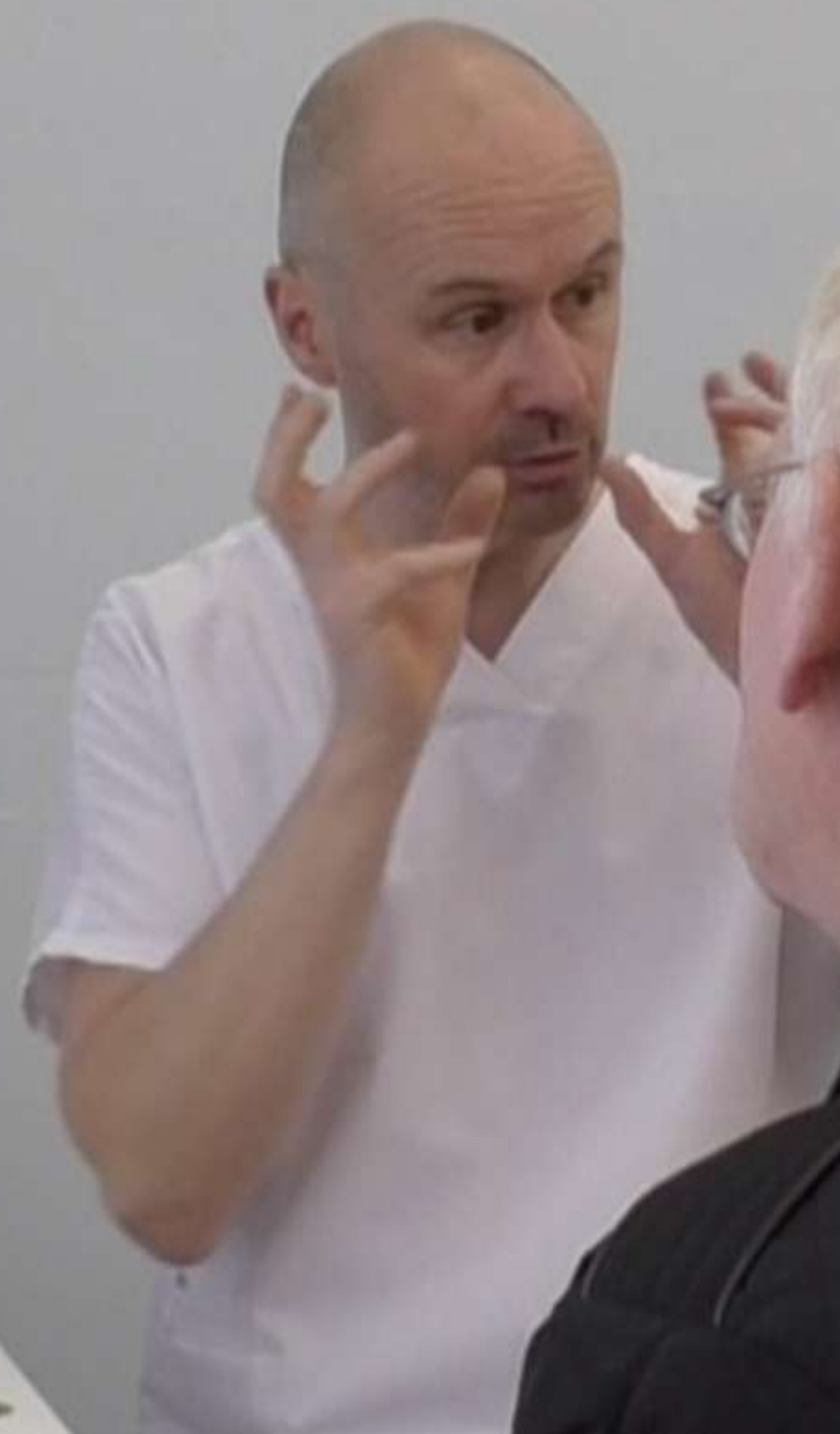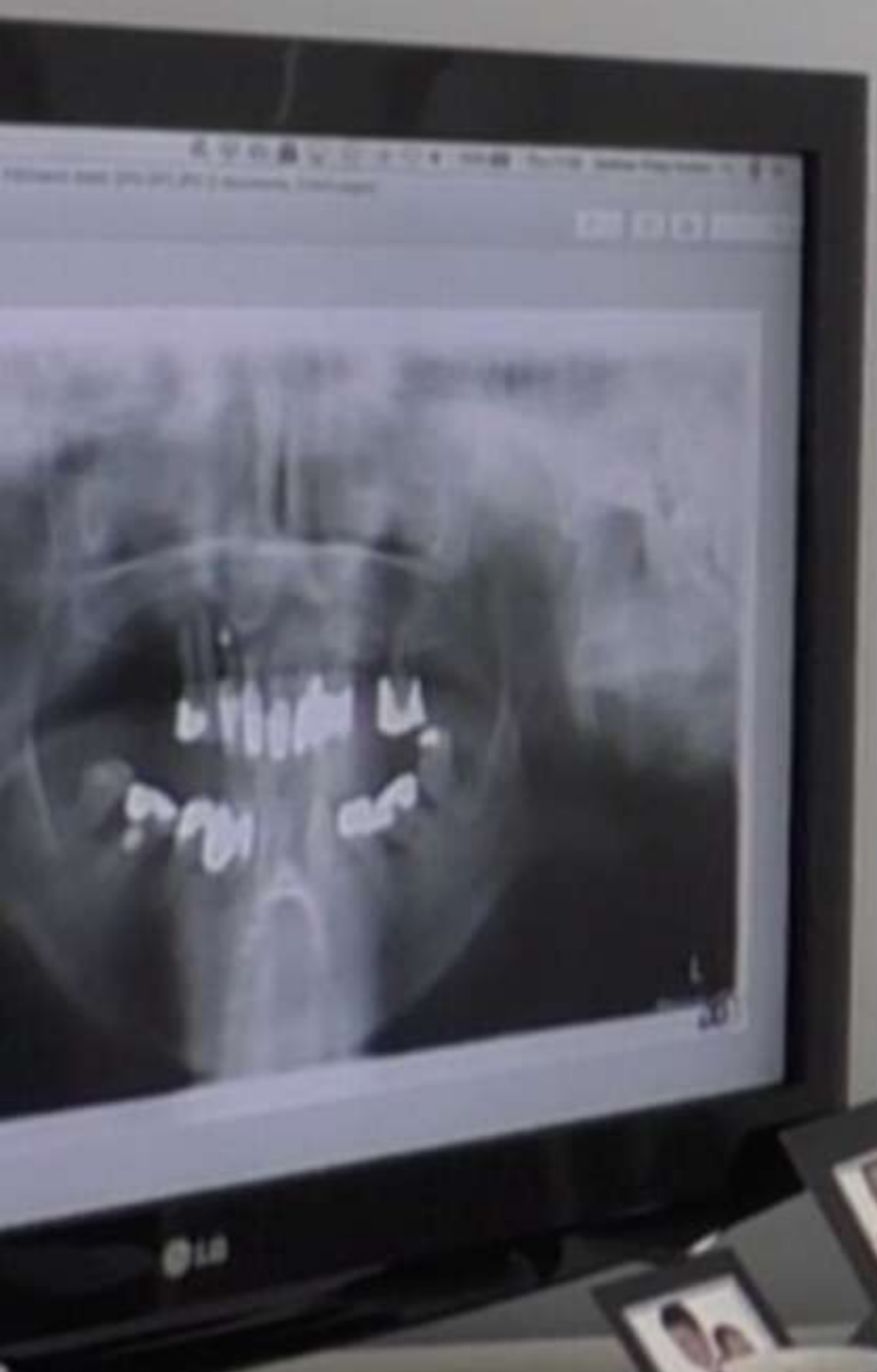TENTH EDITION



---

GLEN P. MCGIVNEY • ALAN B. CARR



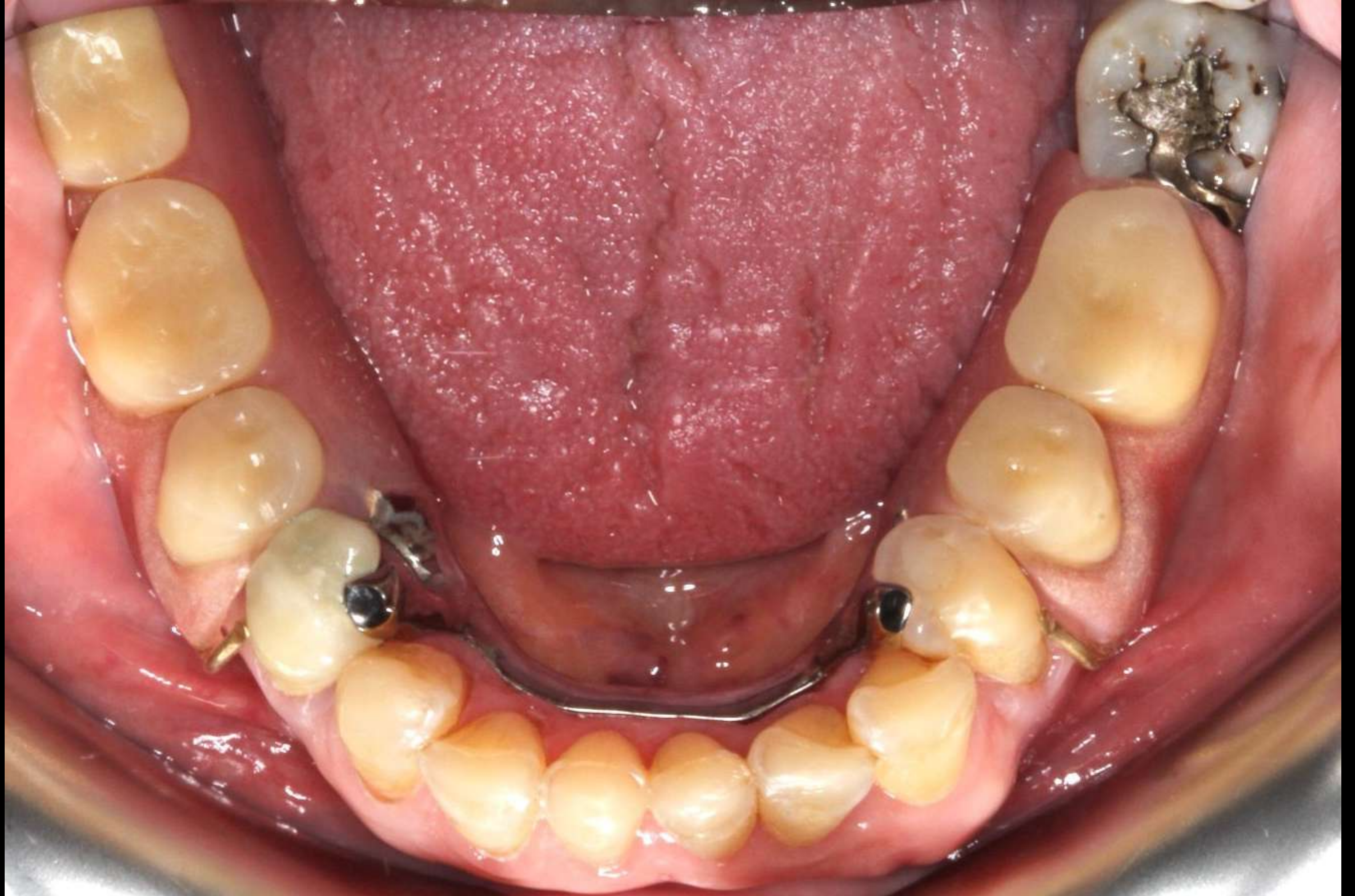



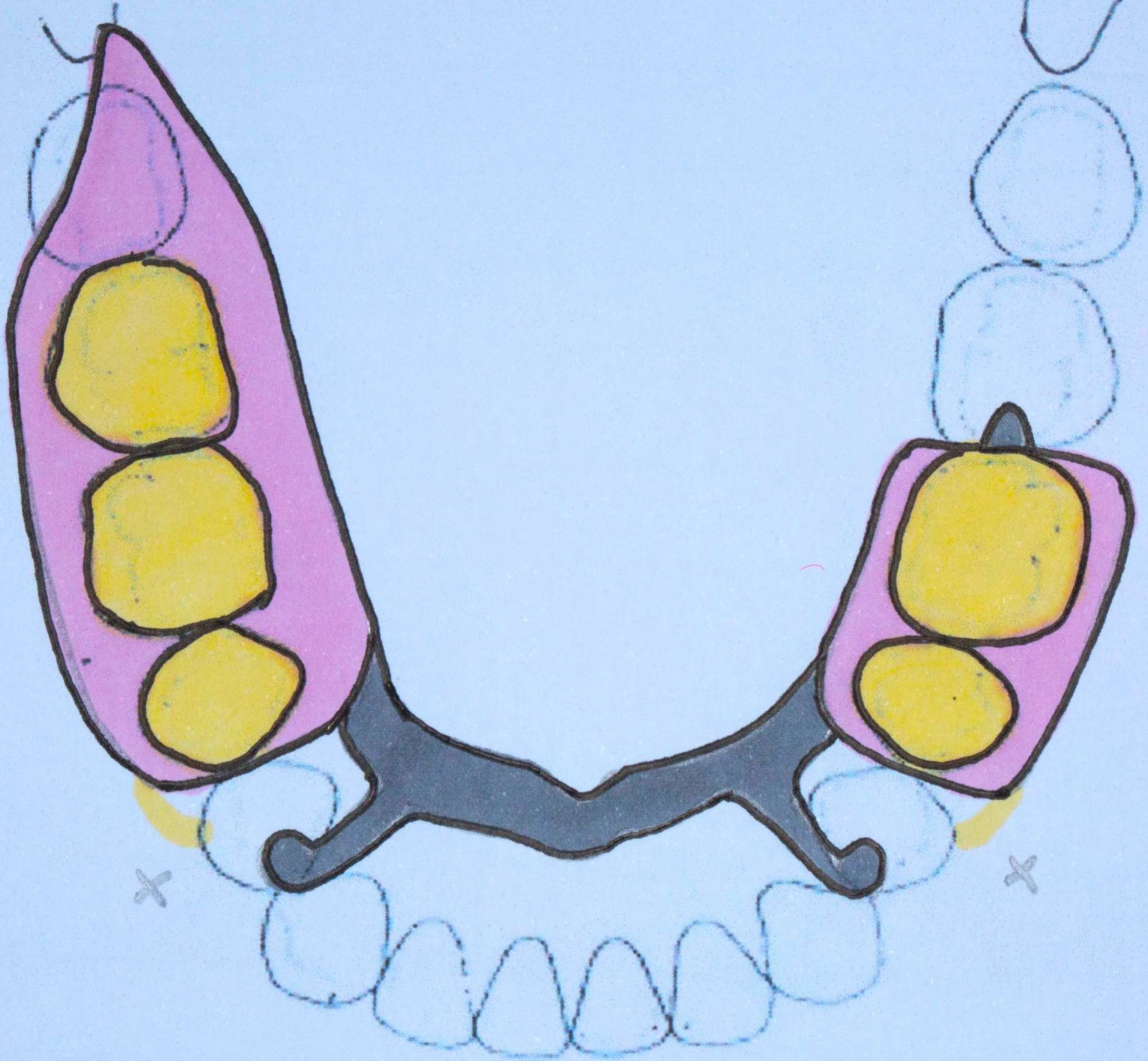


Pat

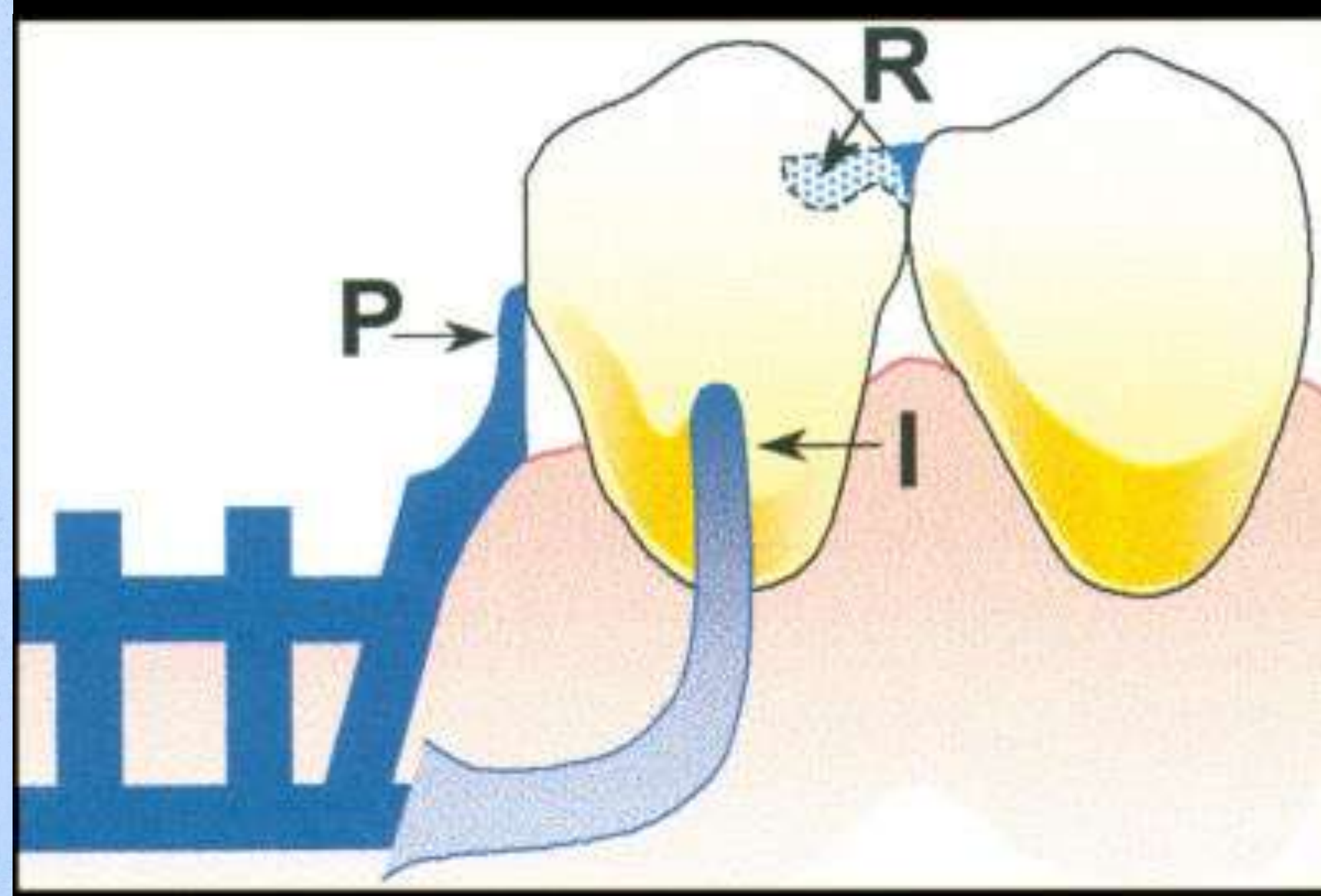




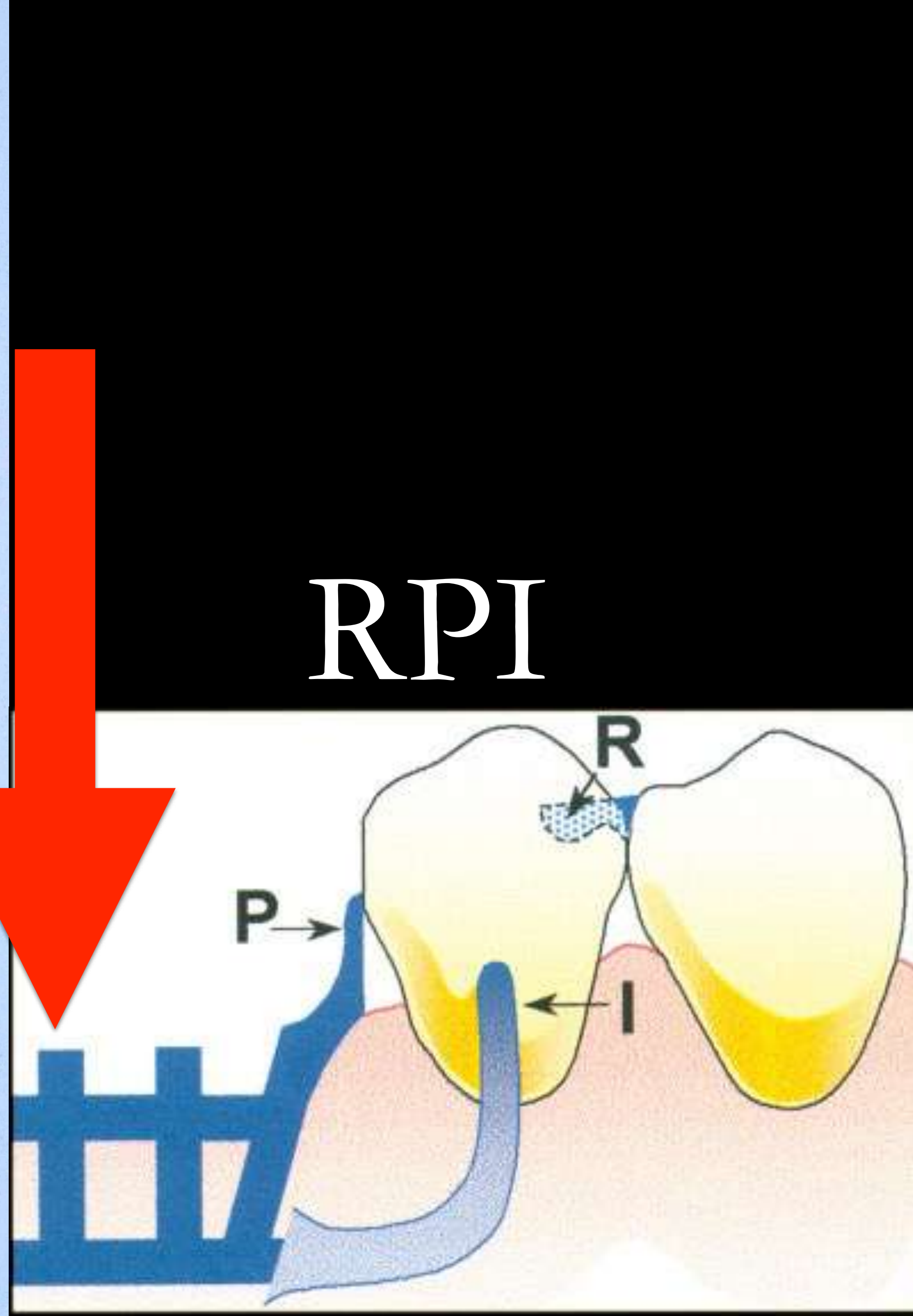
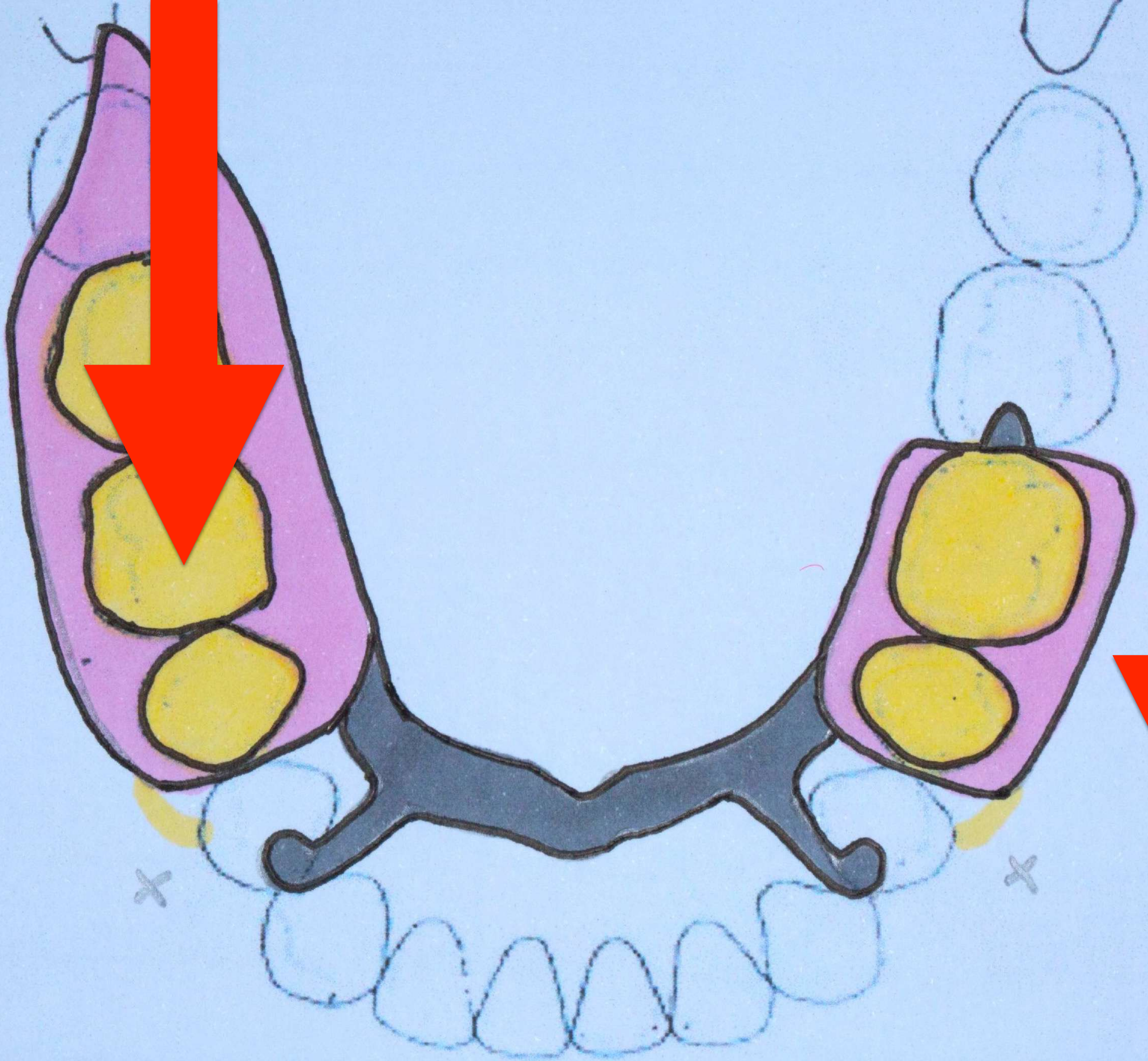




RPI

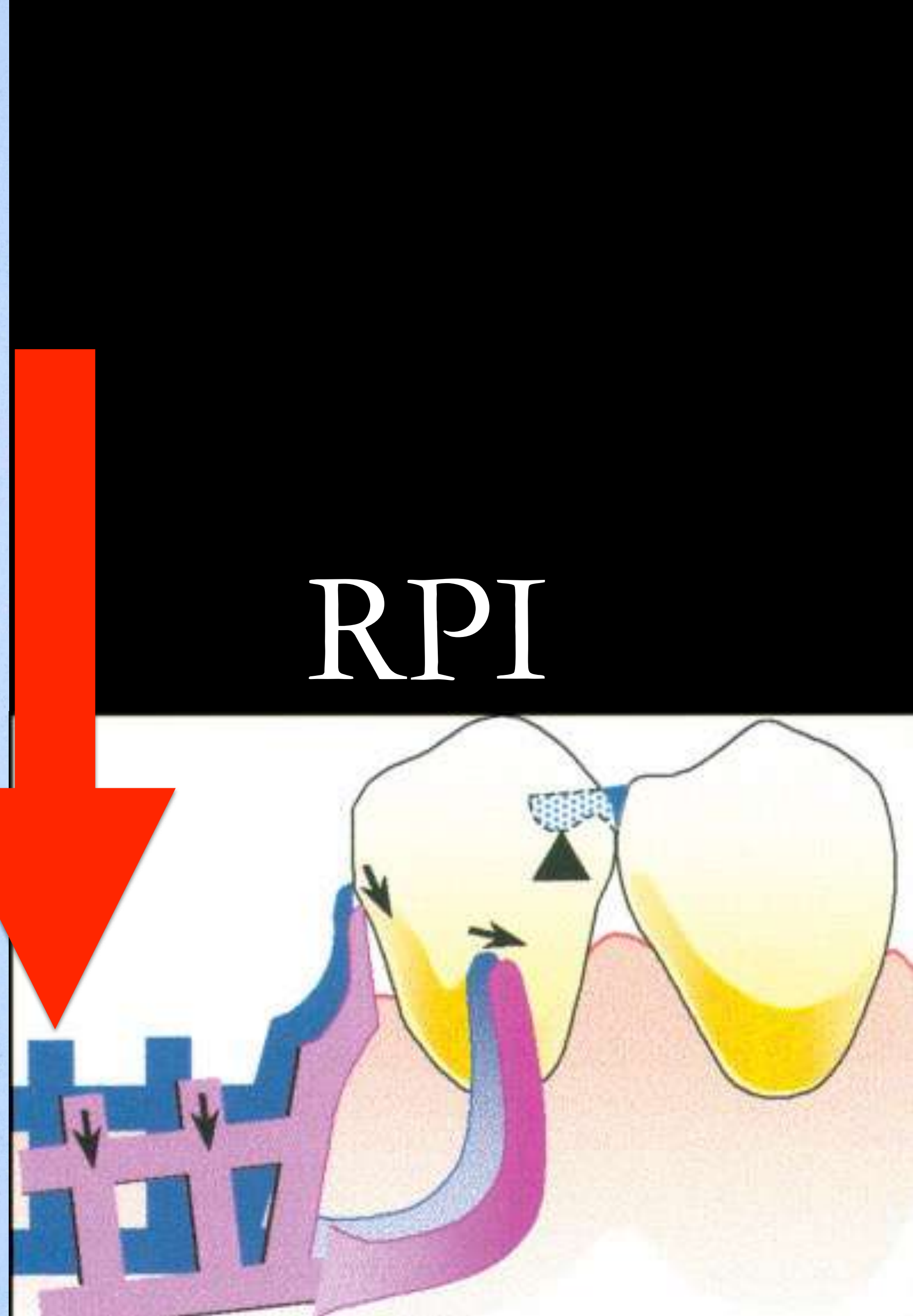
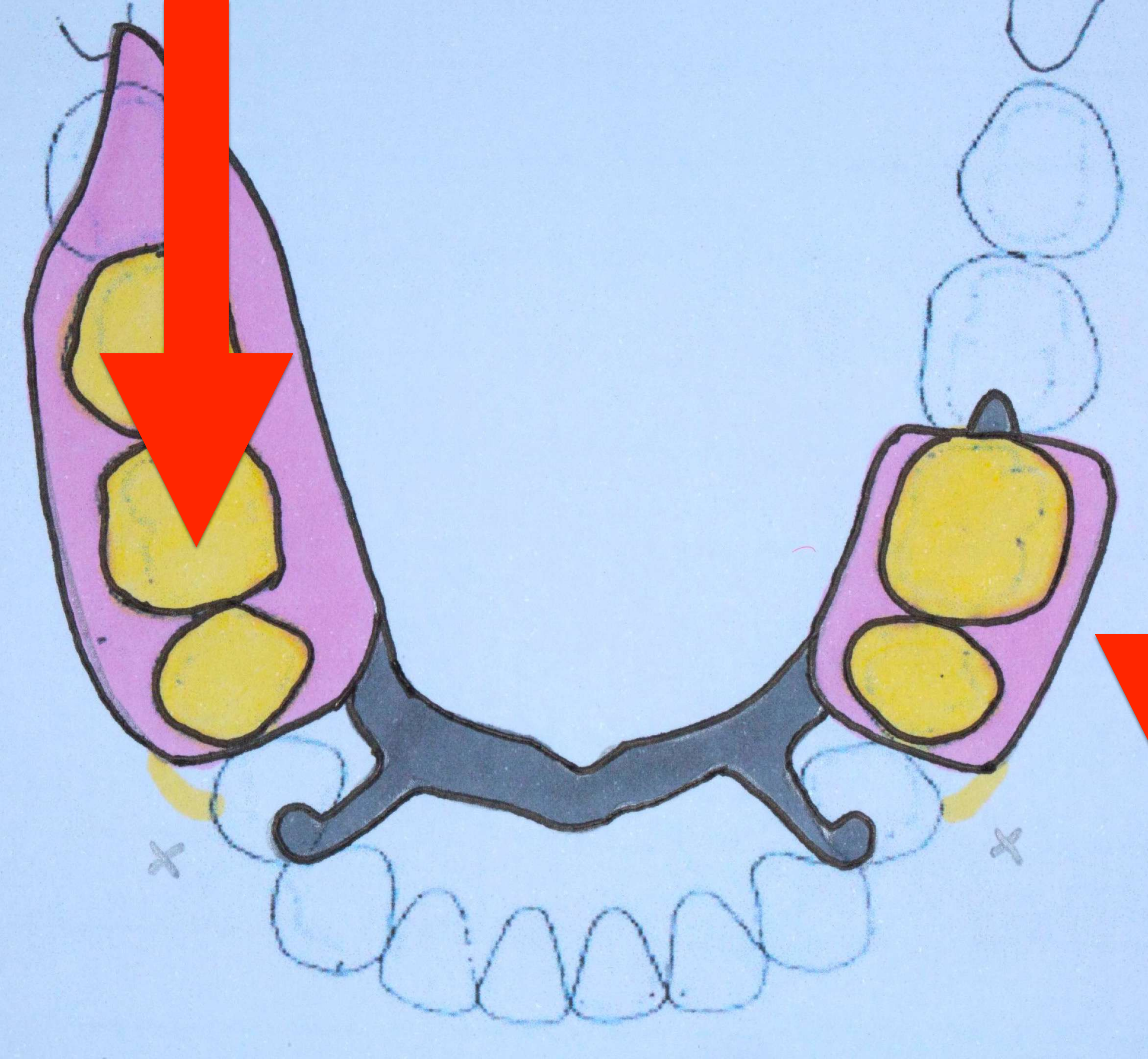






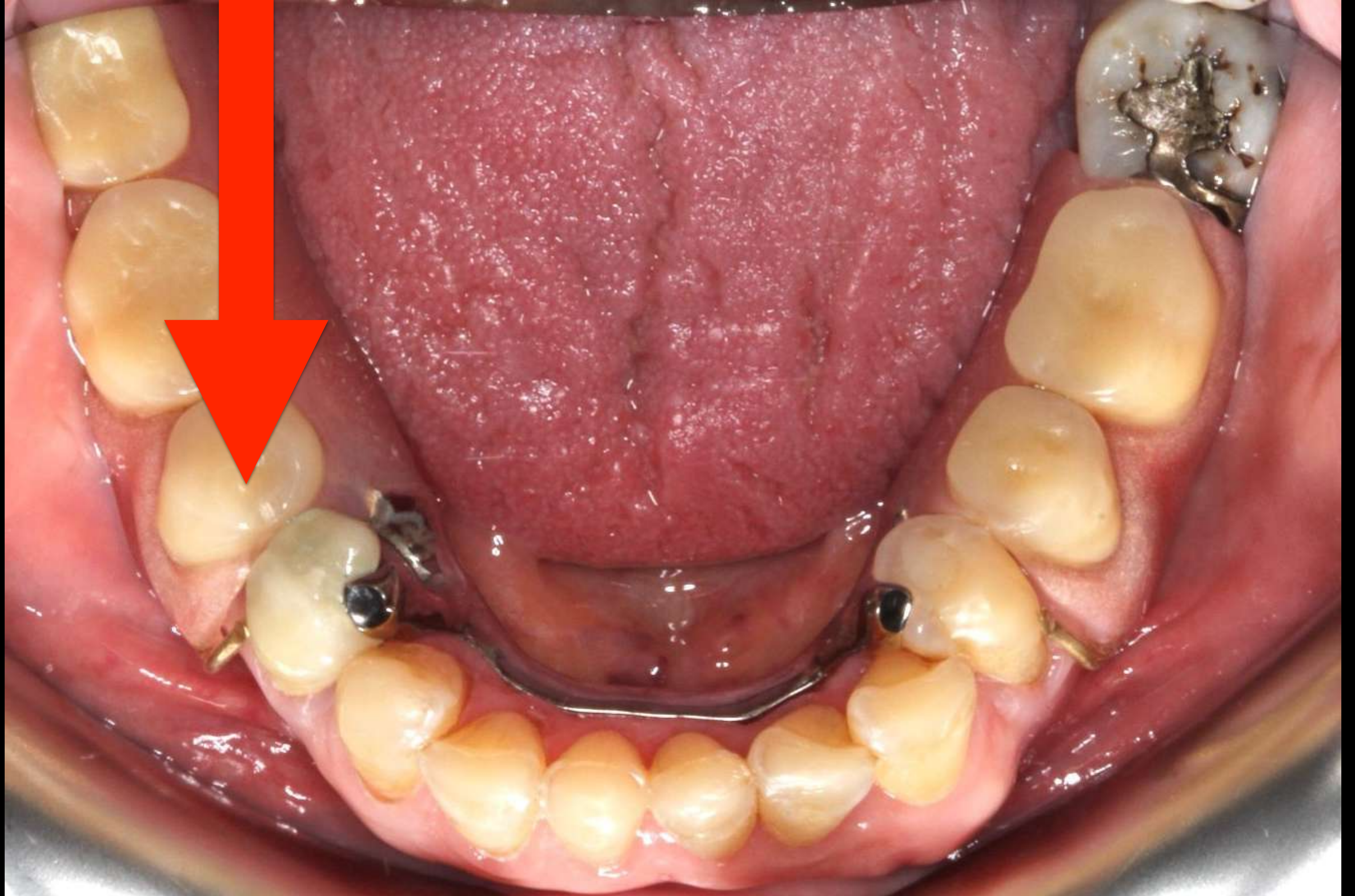RPI





RPI










Charlotte Stilwell





Charlotte Stilwell



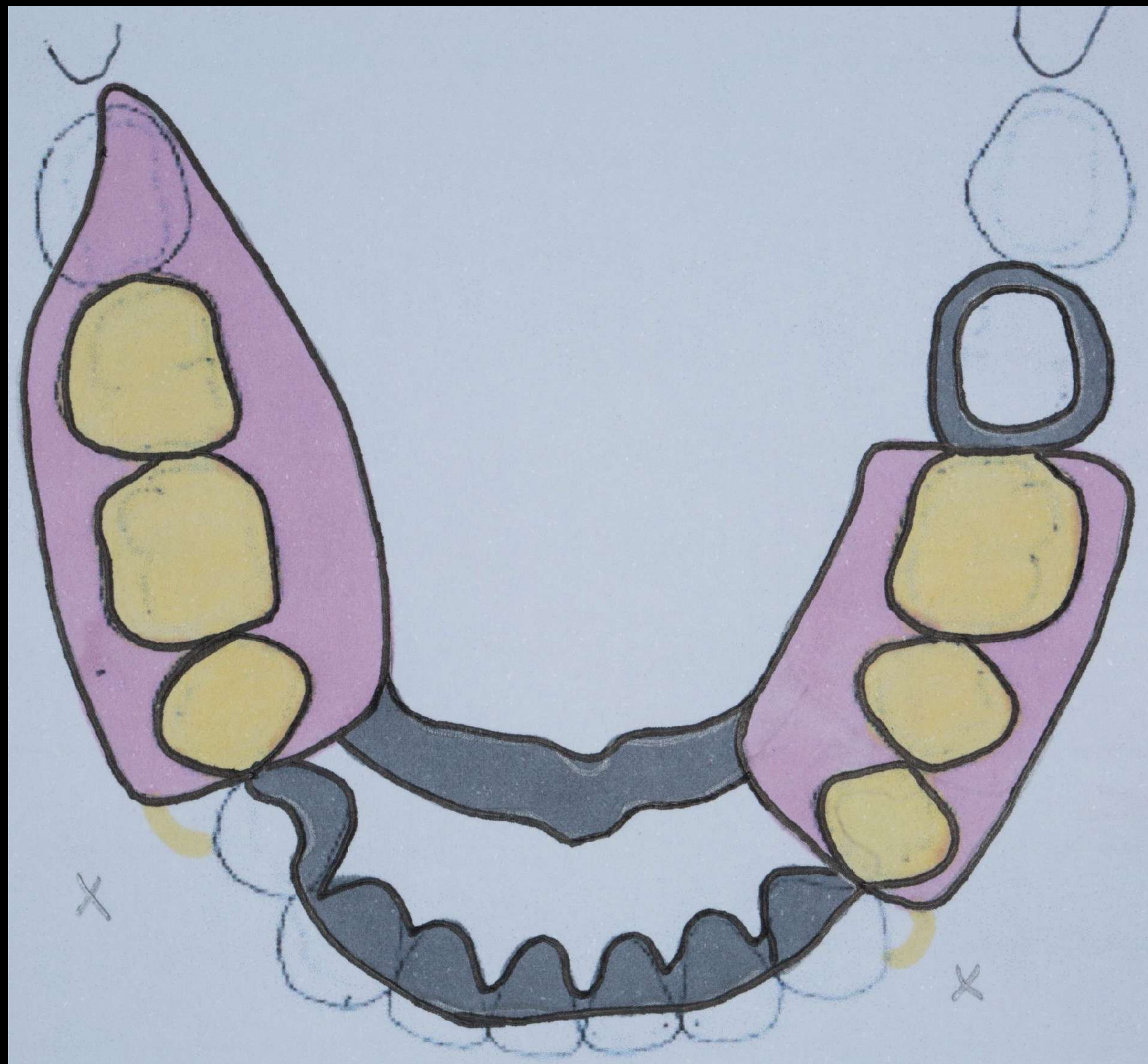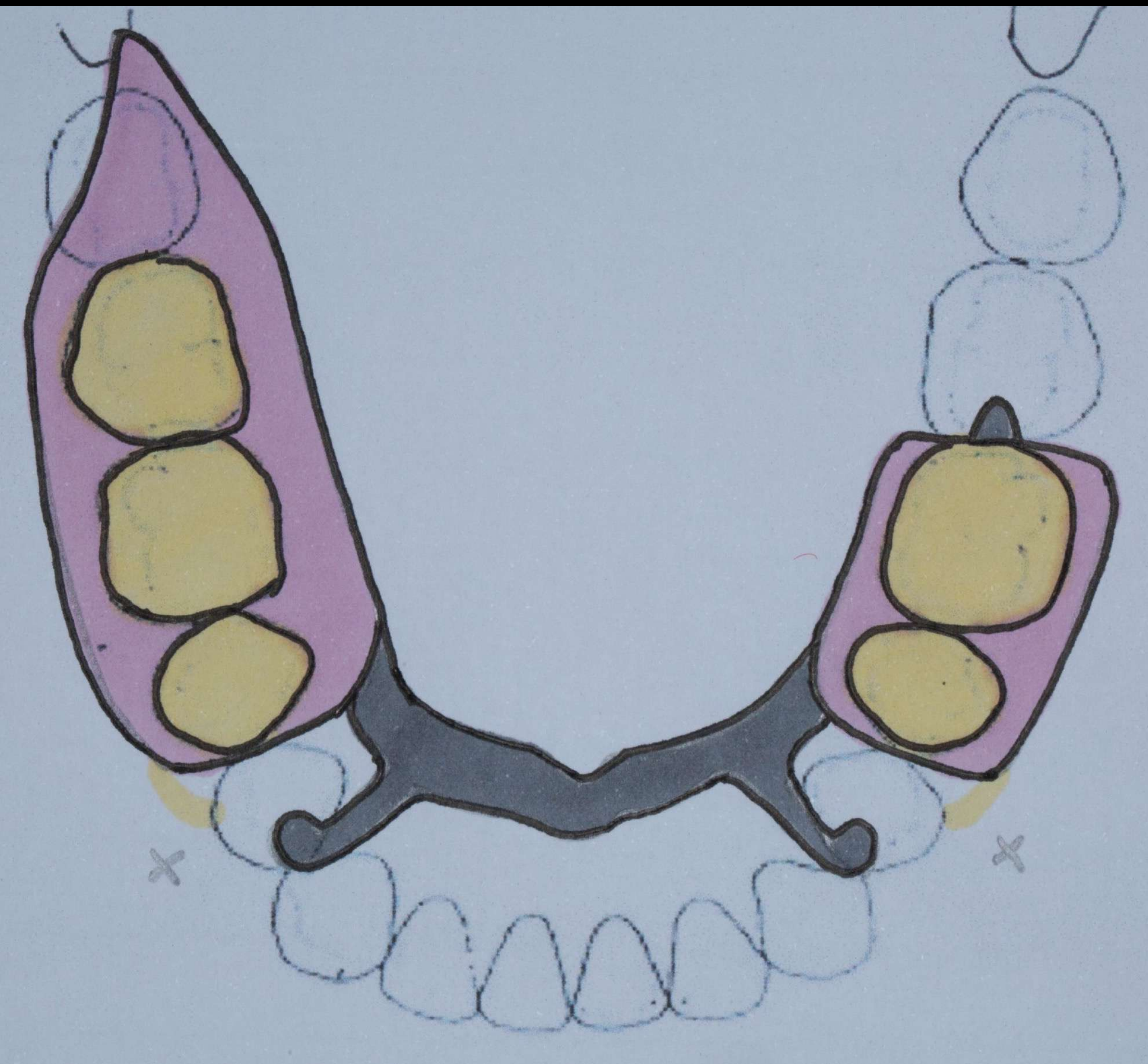
Bengt Öwall



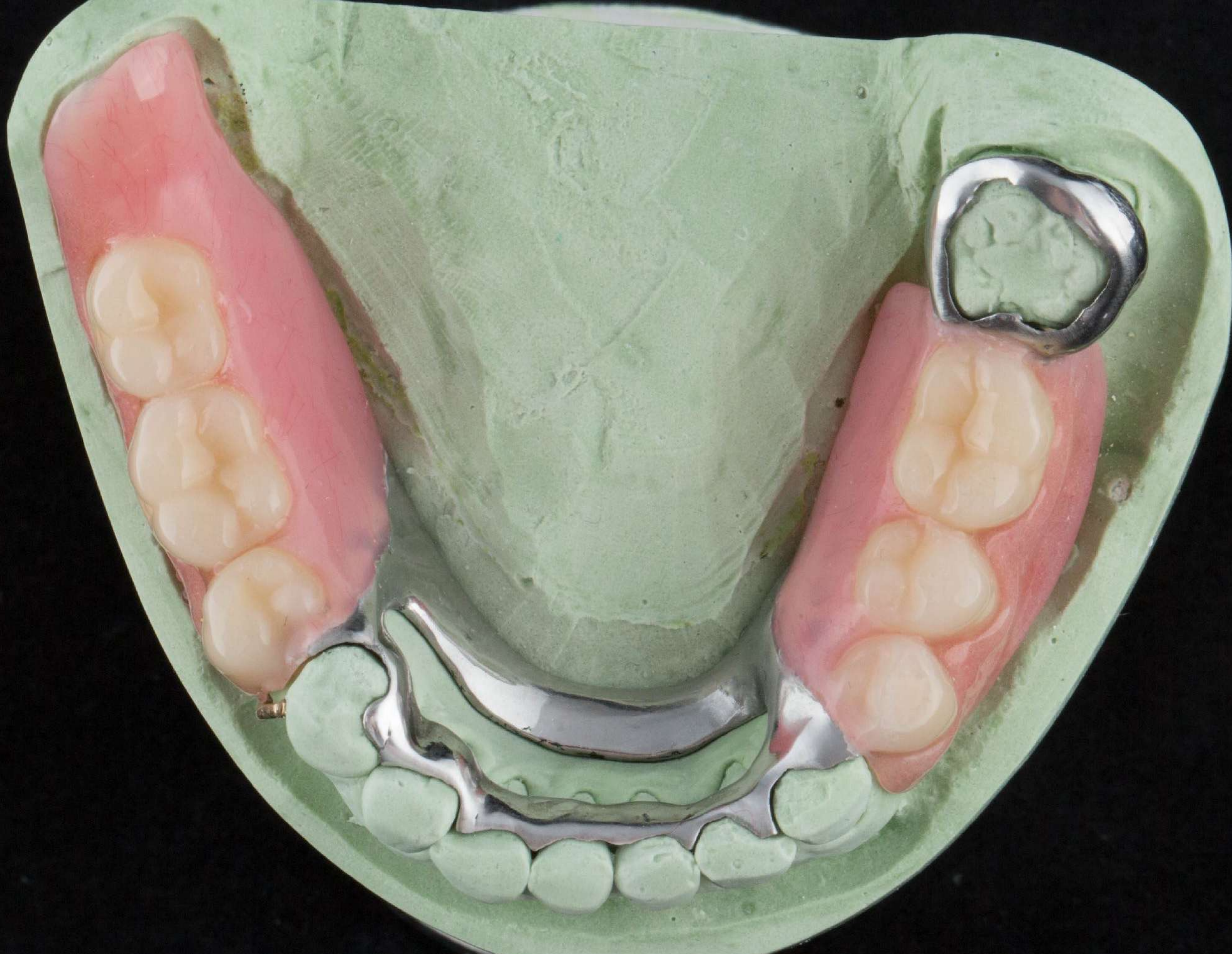RPI system

V

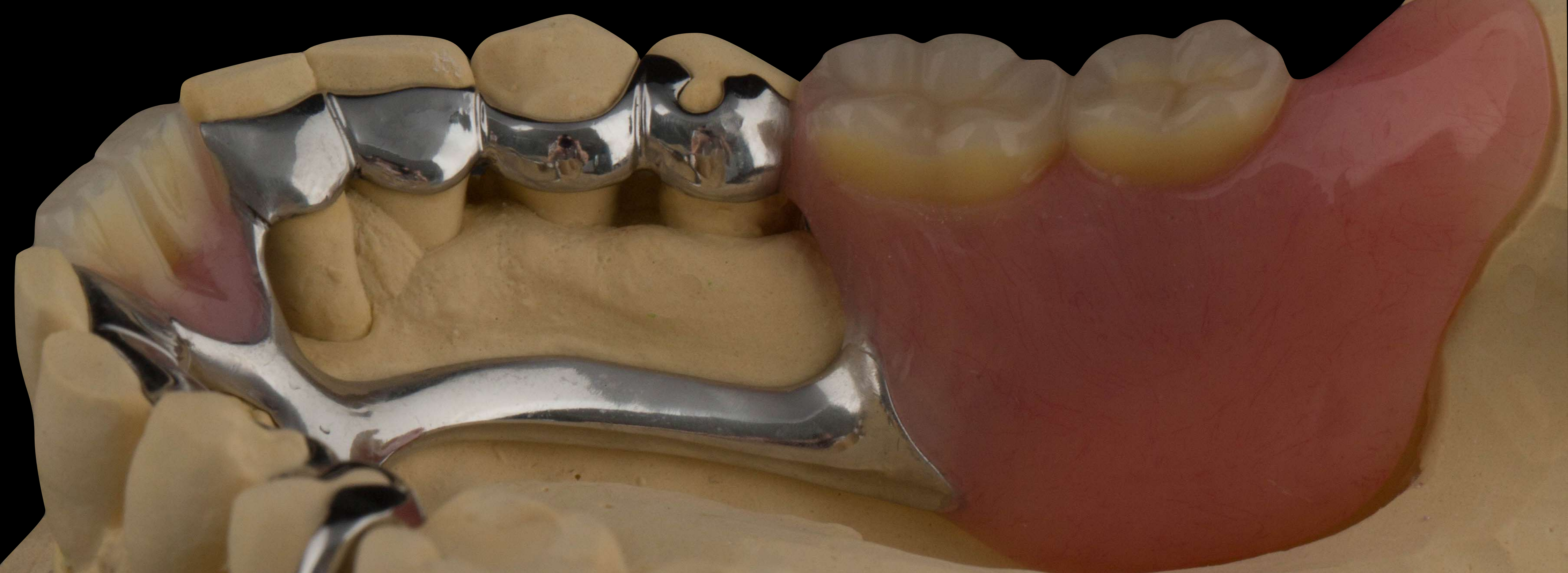Scandinavian RPD system







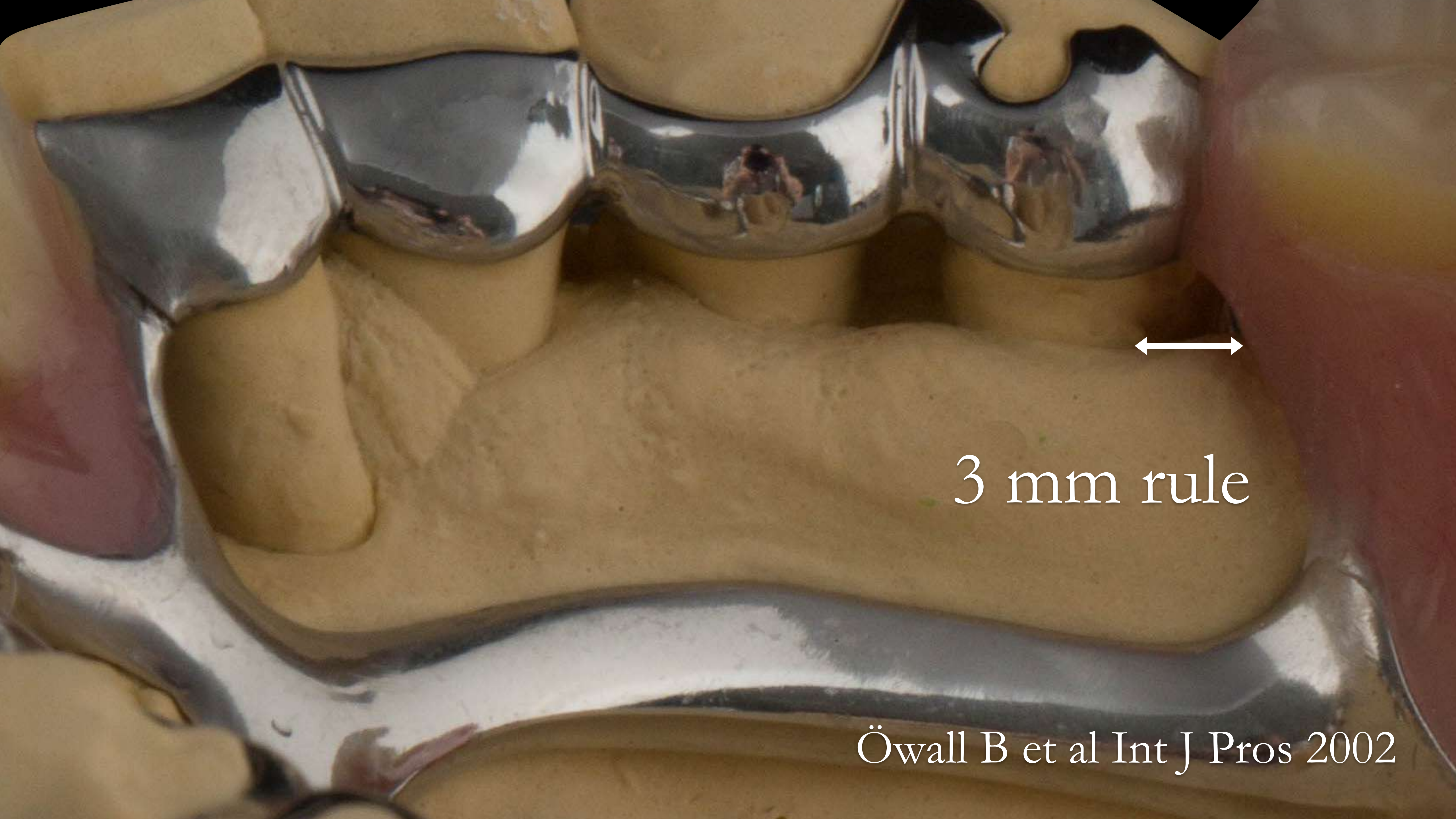




RPD design: a need to focus on Hygienic Principles.

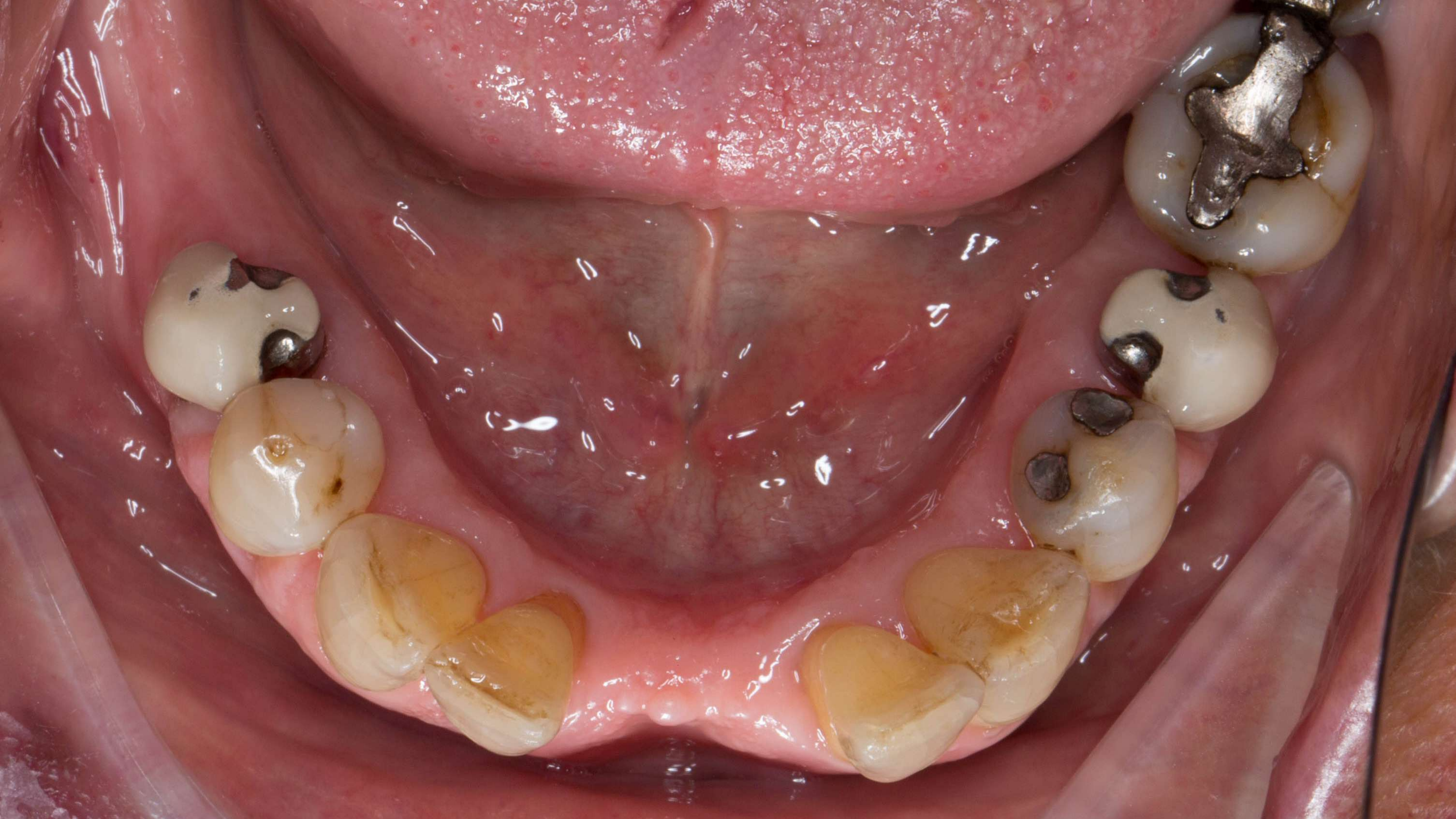Öwall B et al Int J Pros 2002



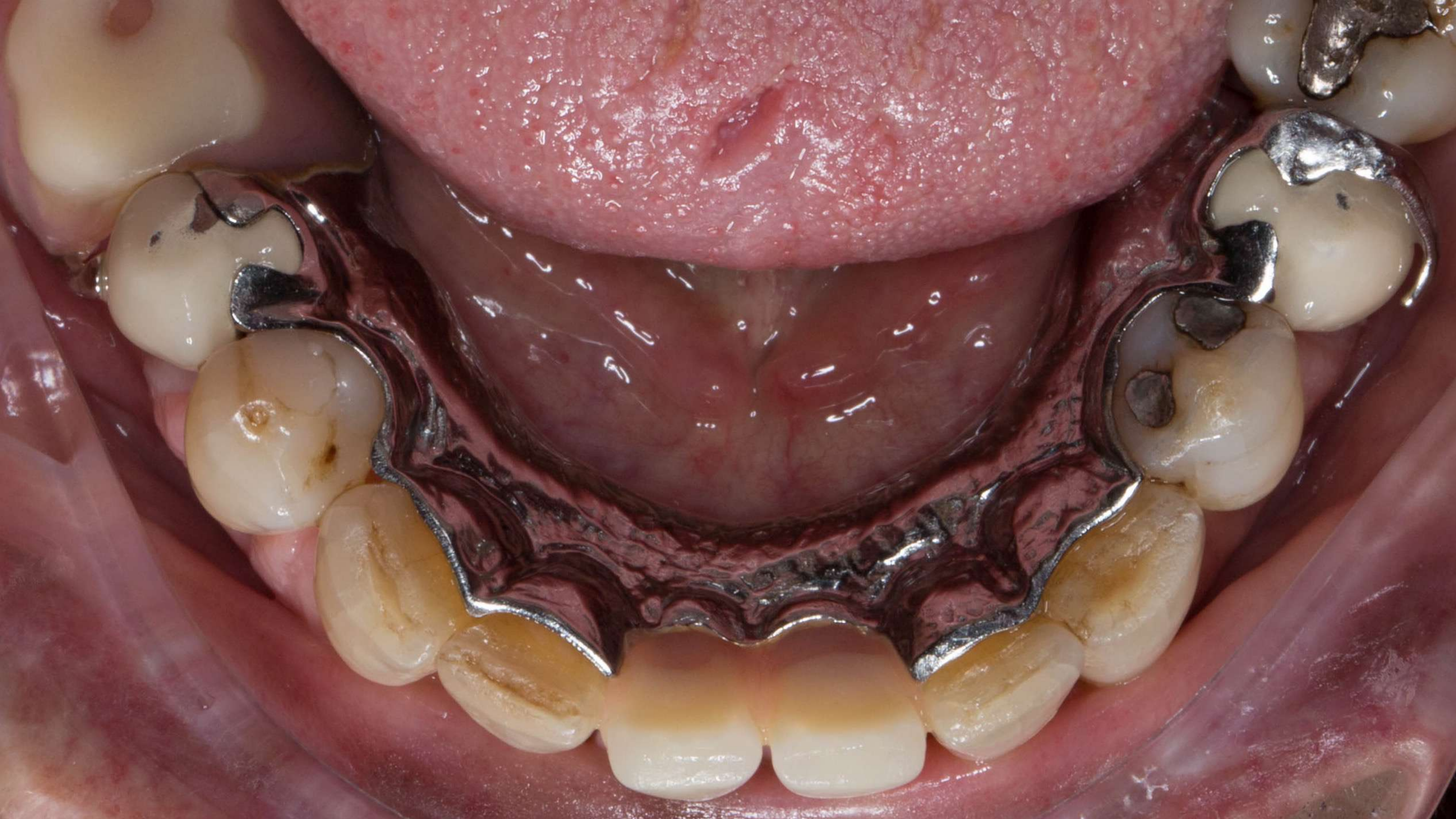

3 mm rule

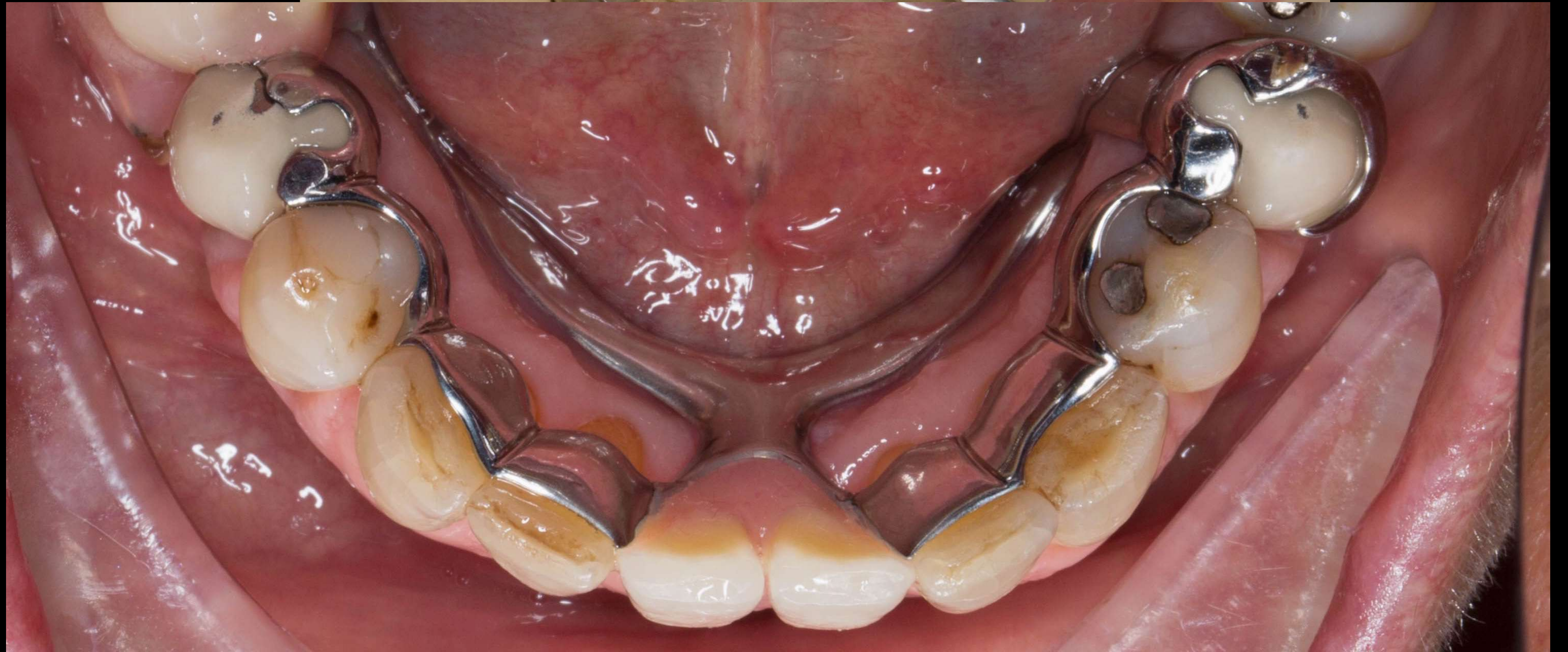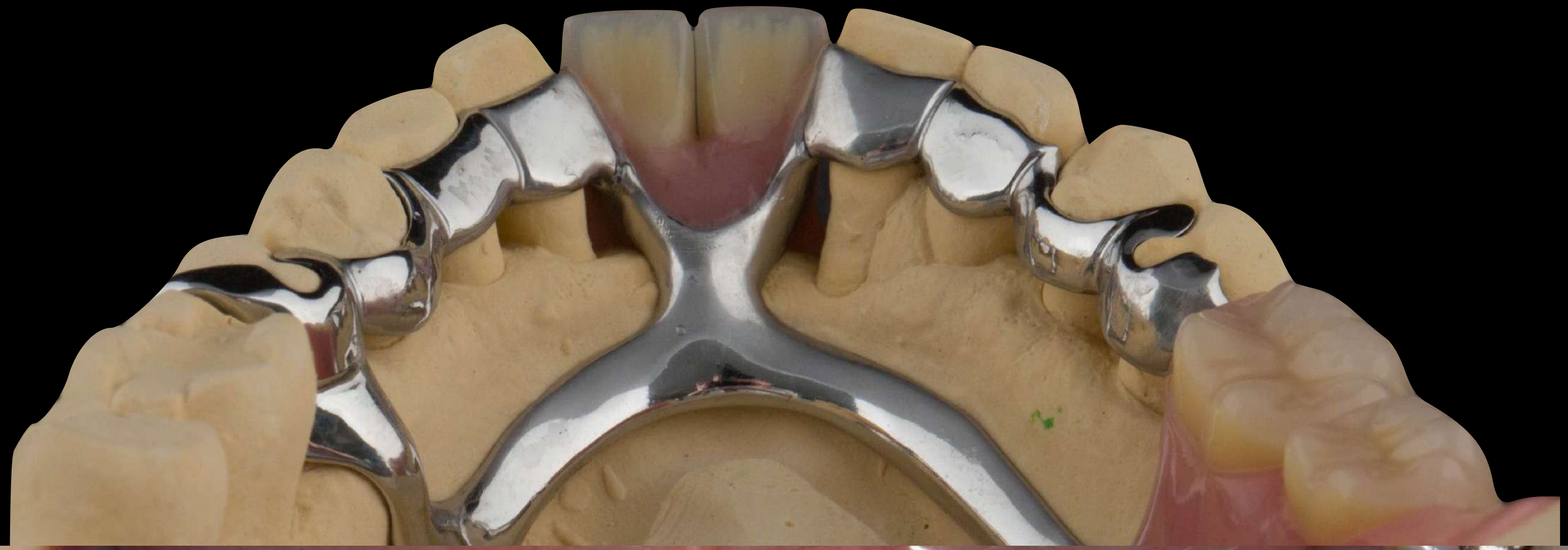














A dental model of a maxillary arch with a metal partial denture. The model shows the teeth and the metal framework of the prosthesis. The text "Personal message" is overlaid in white on a semi-transparent dark background.

Personal message

A clinical photograph of a patient's mouth with a metal partial denture. The image shows the patient's teeth and the metal framework of the prosthesis. The text "We should all adopt this approach" is overlaid in white on a semi-transparent dark background.

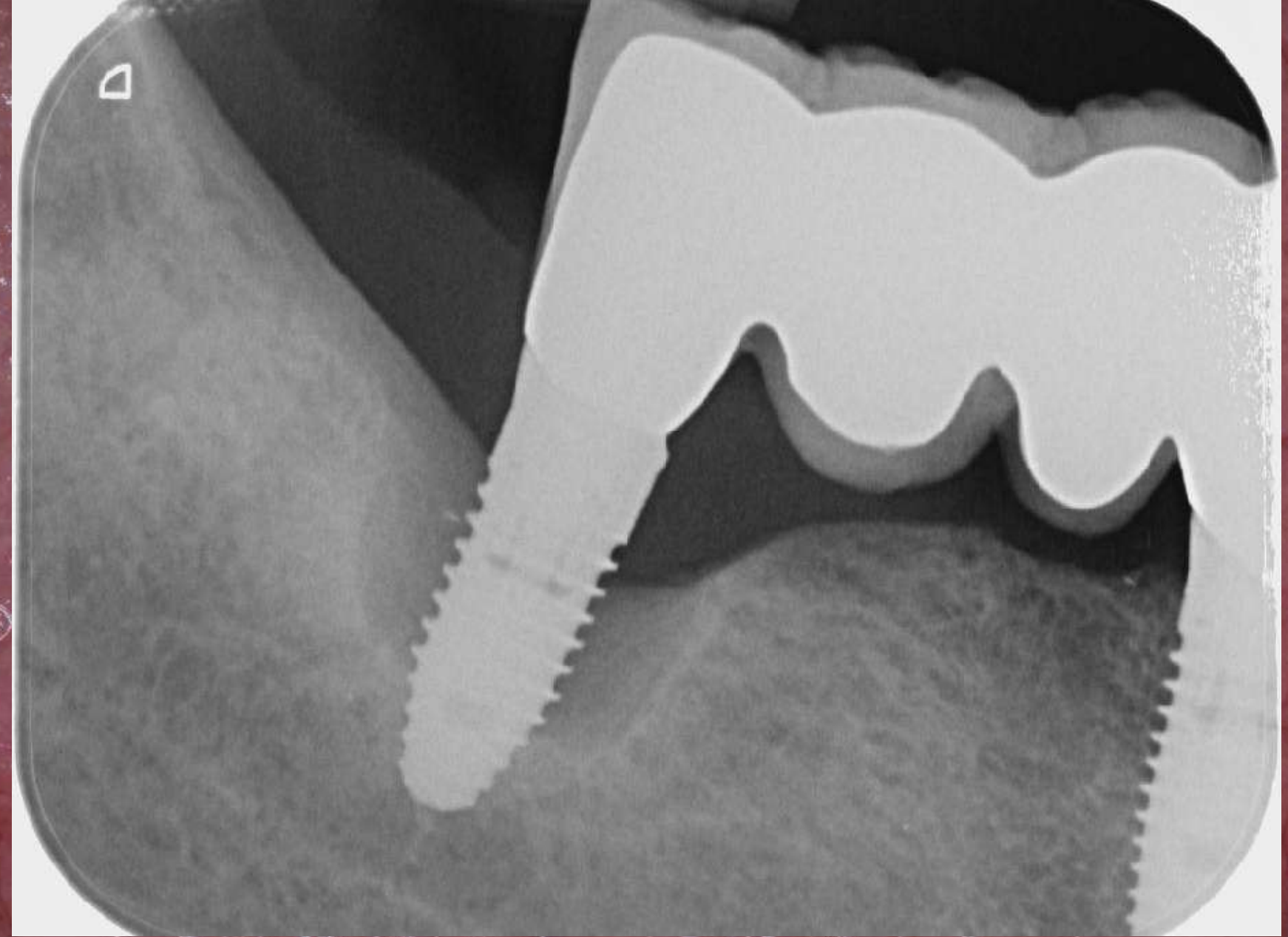
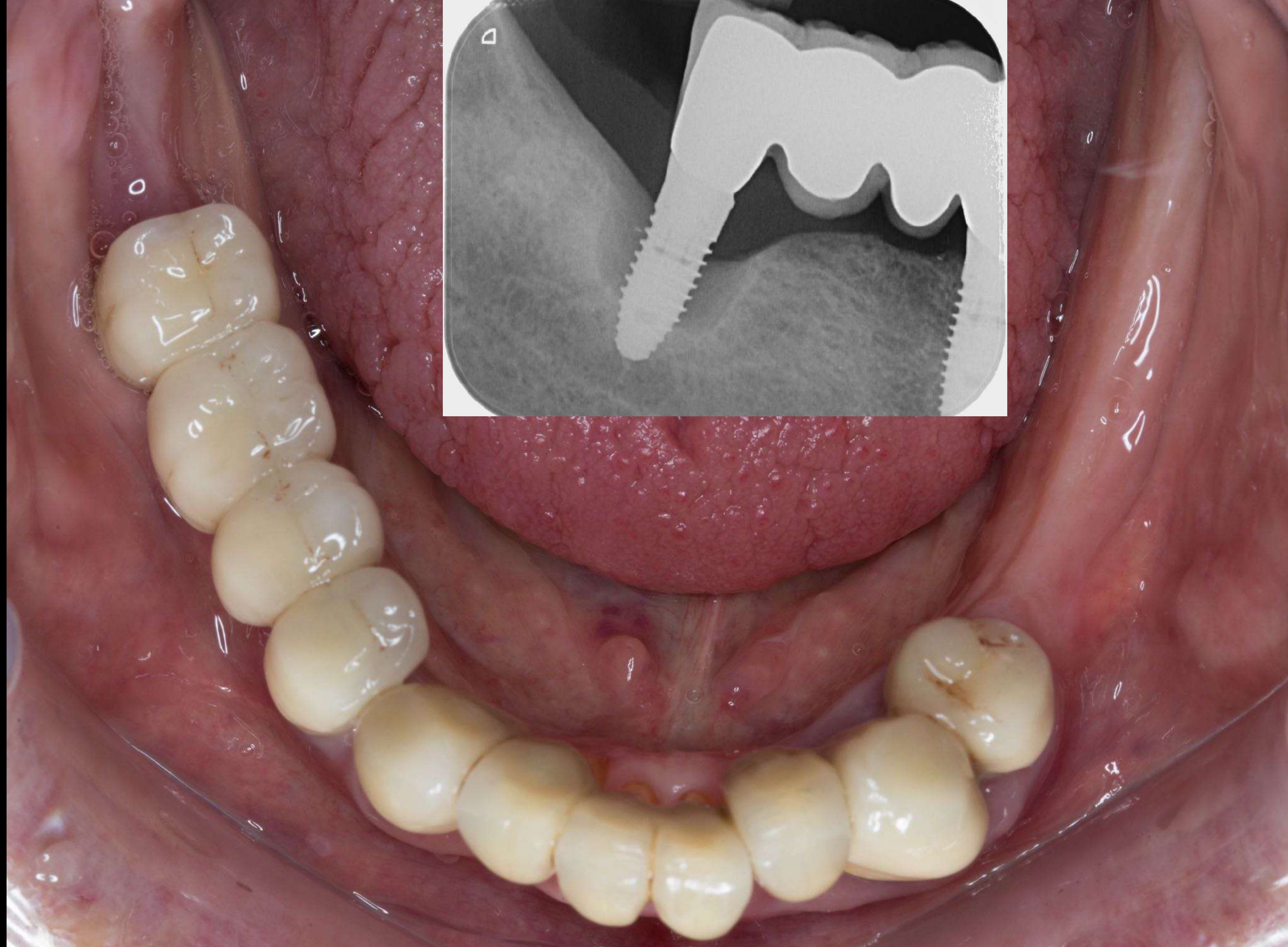
We should all adopt this  
approach



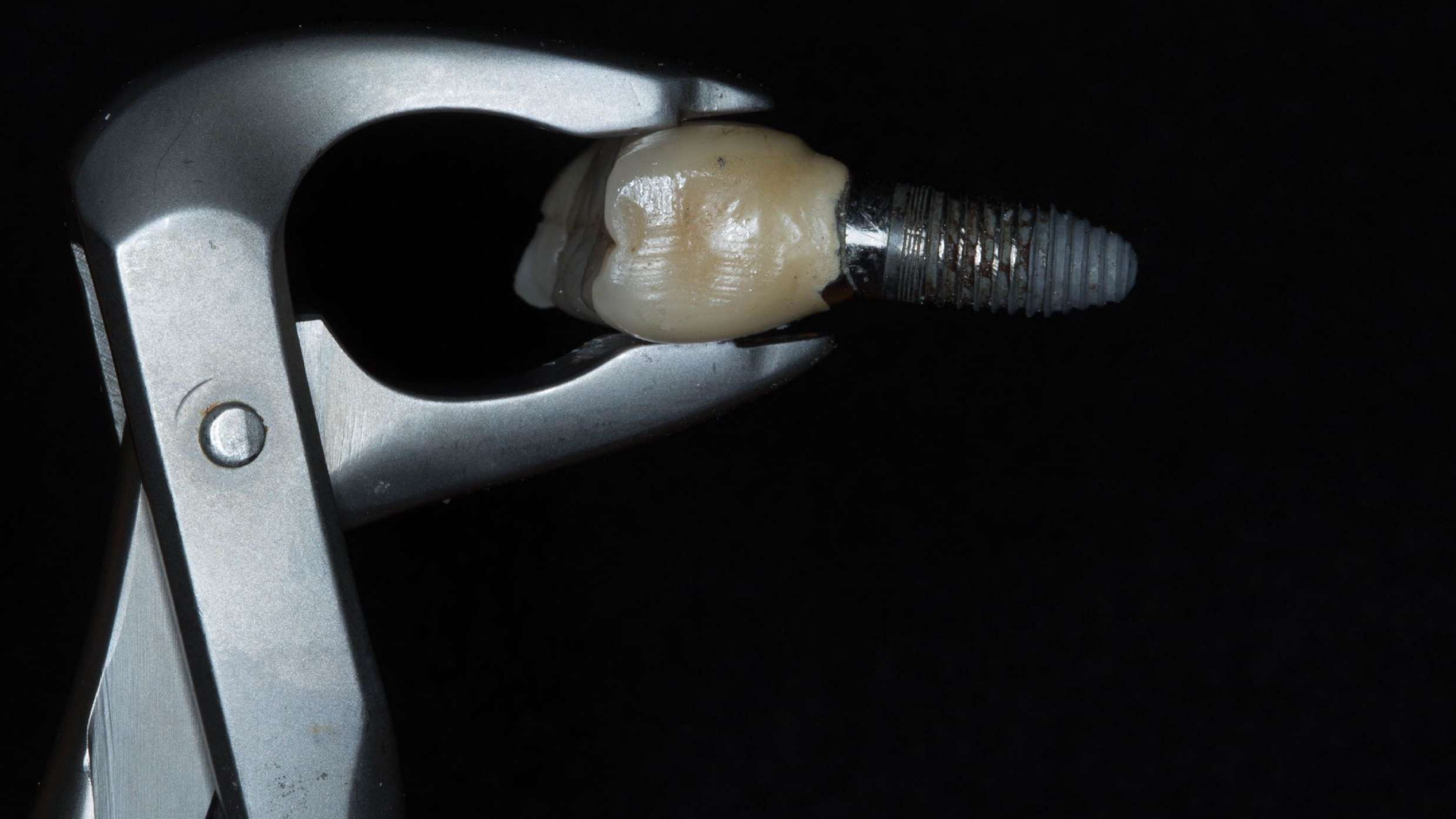Ken



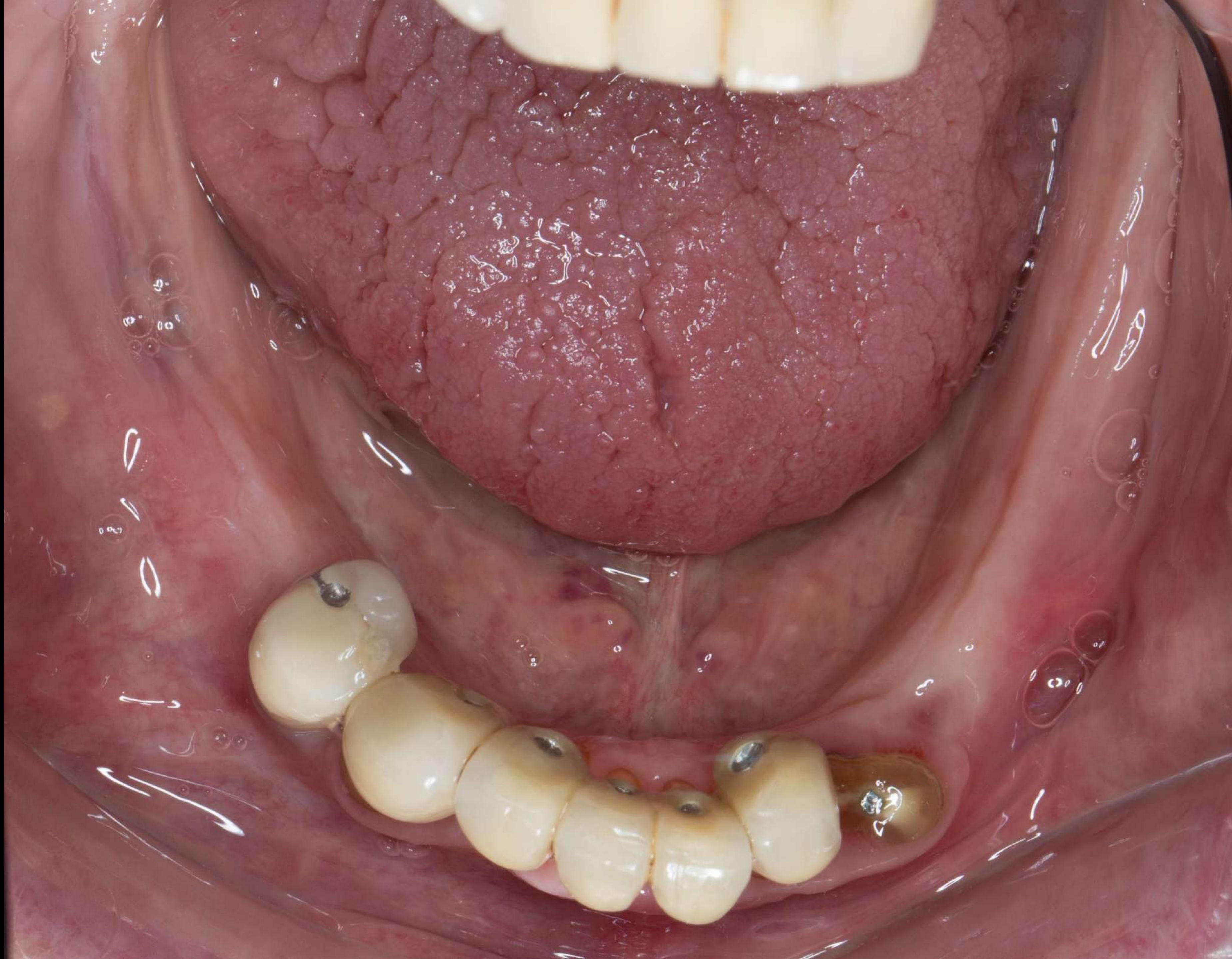




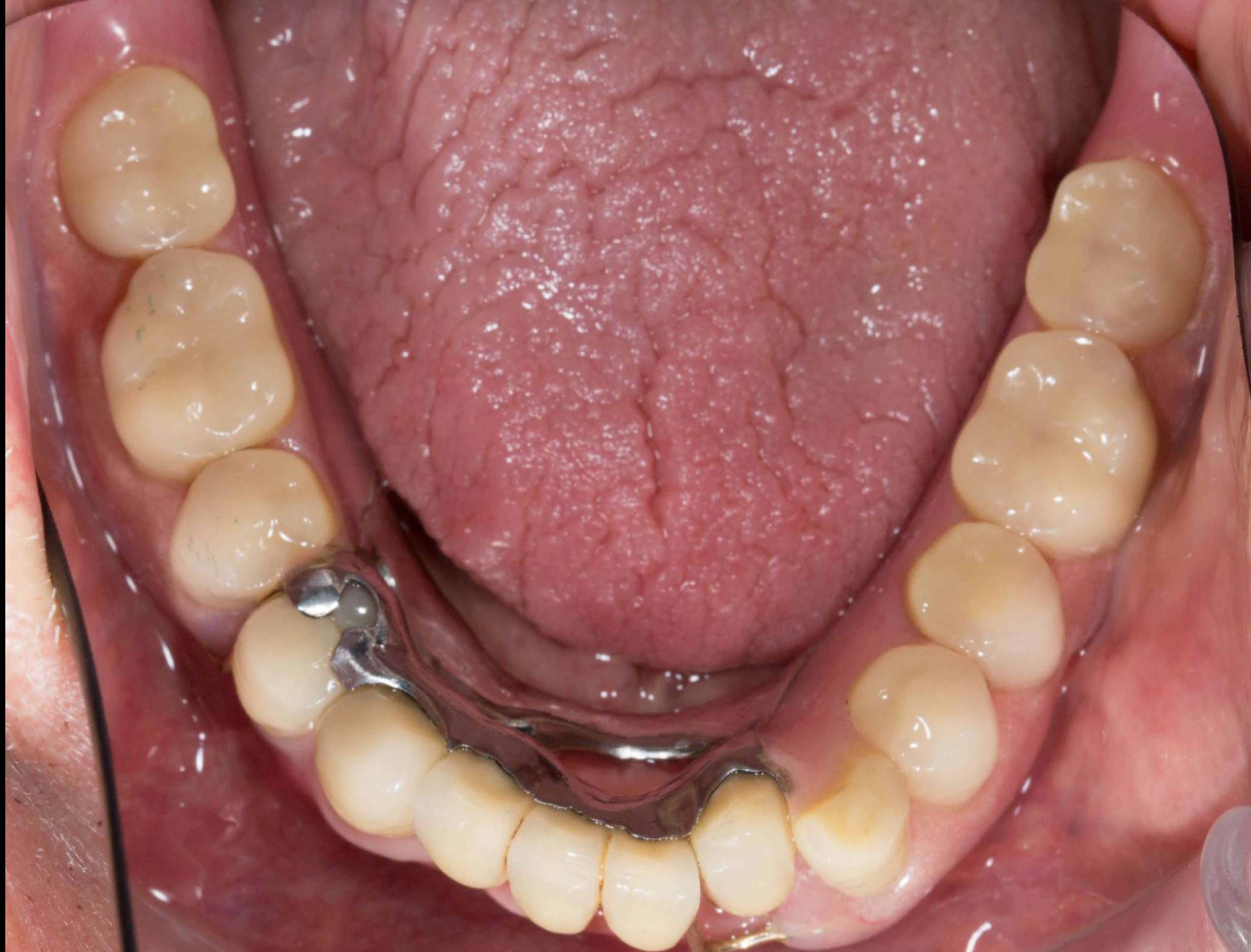




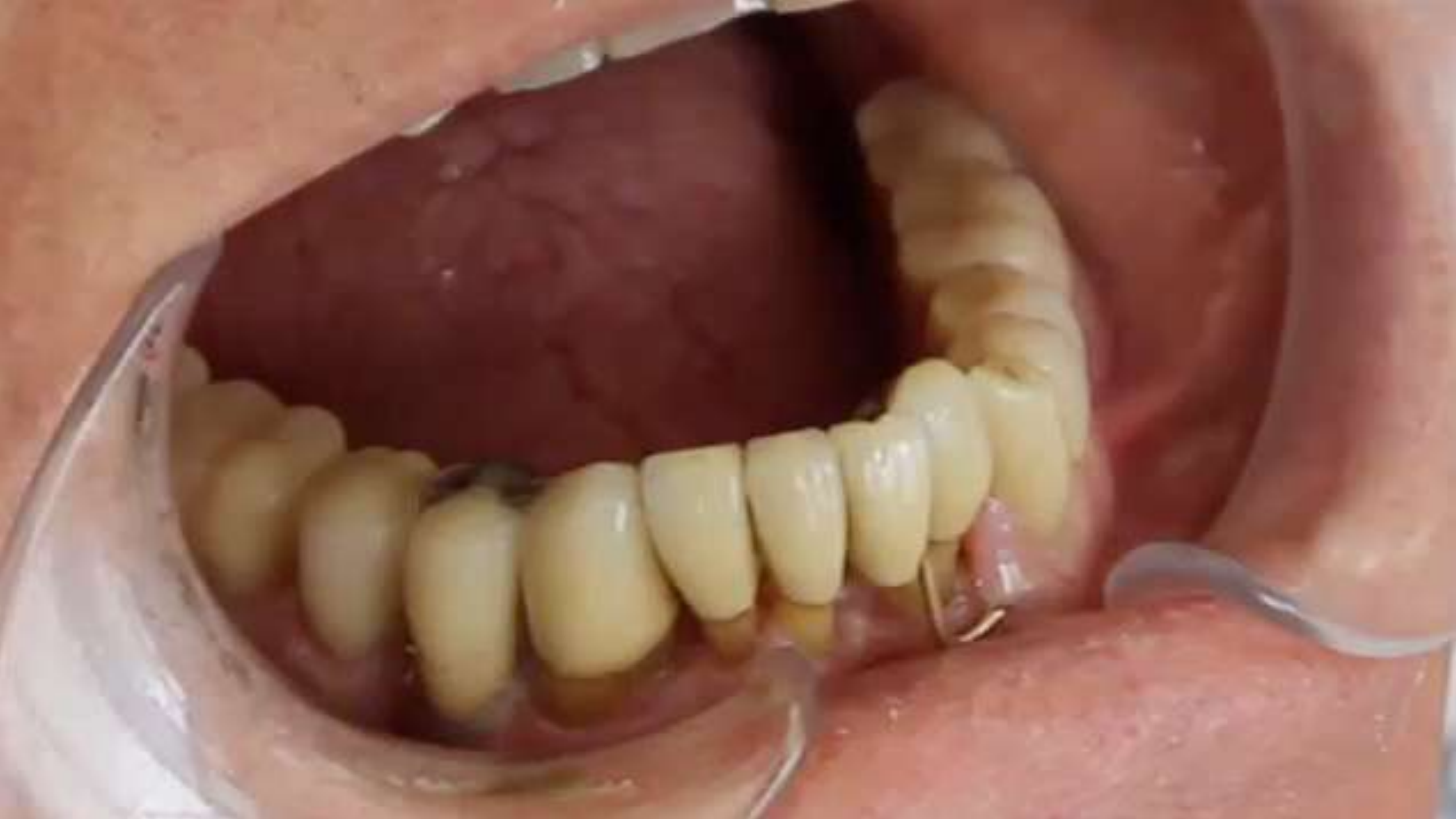










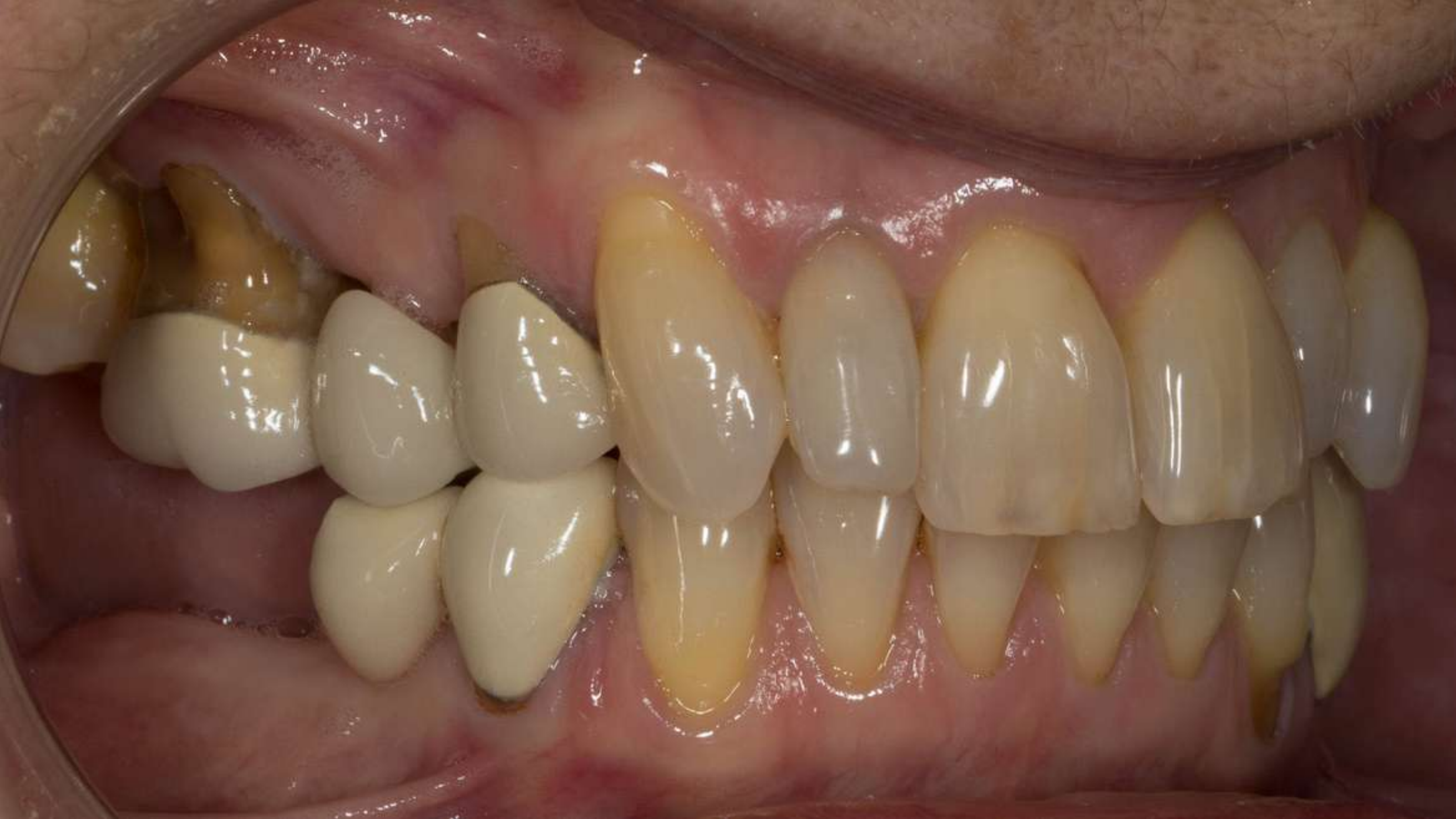
Angela

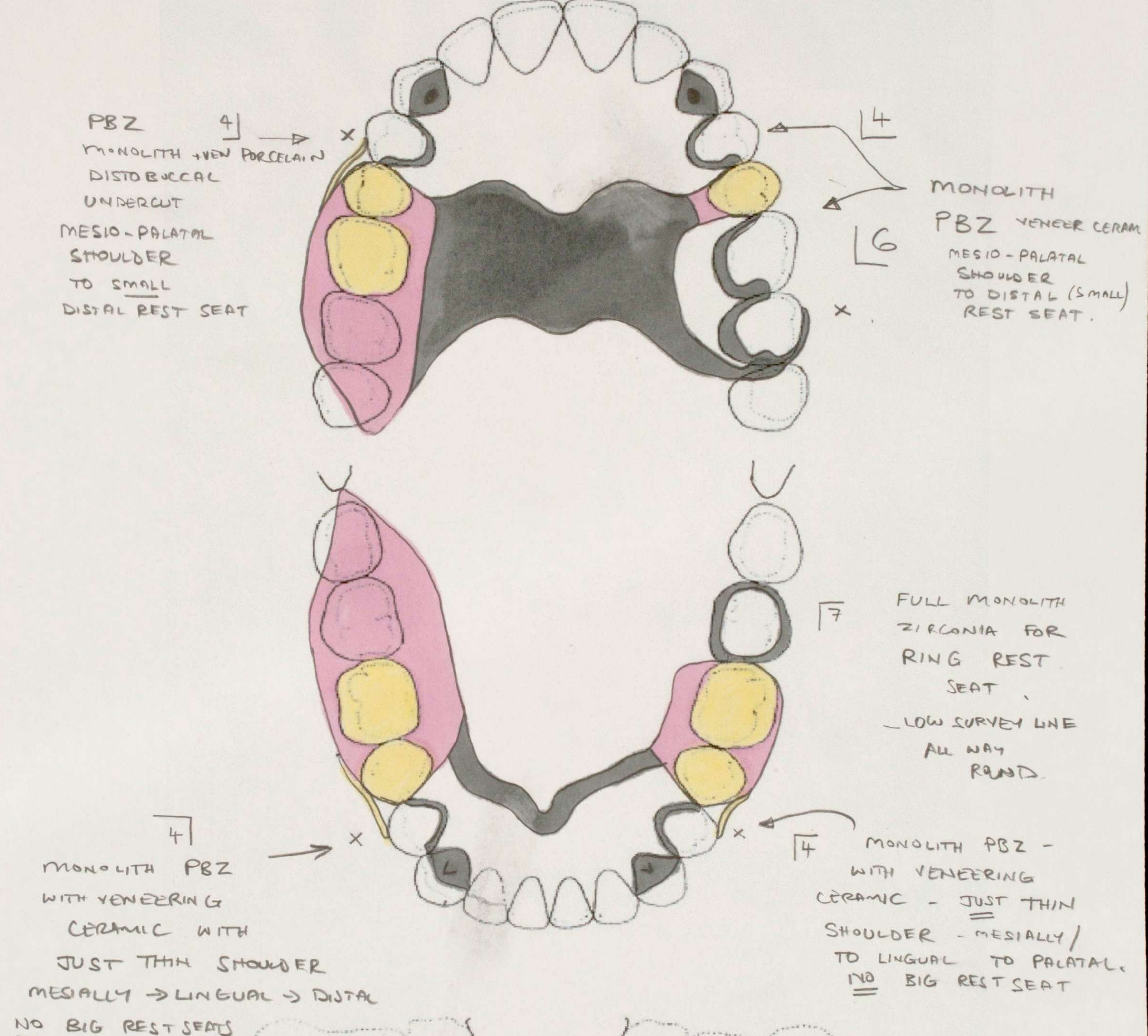




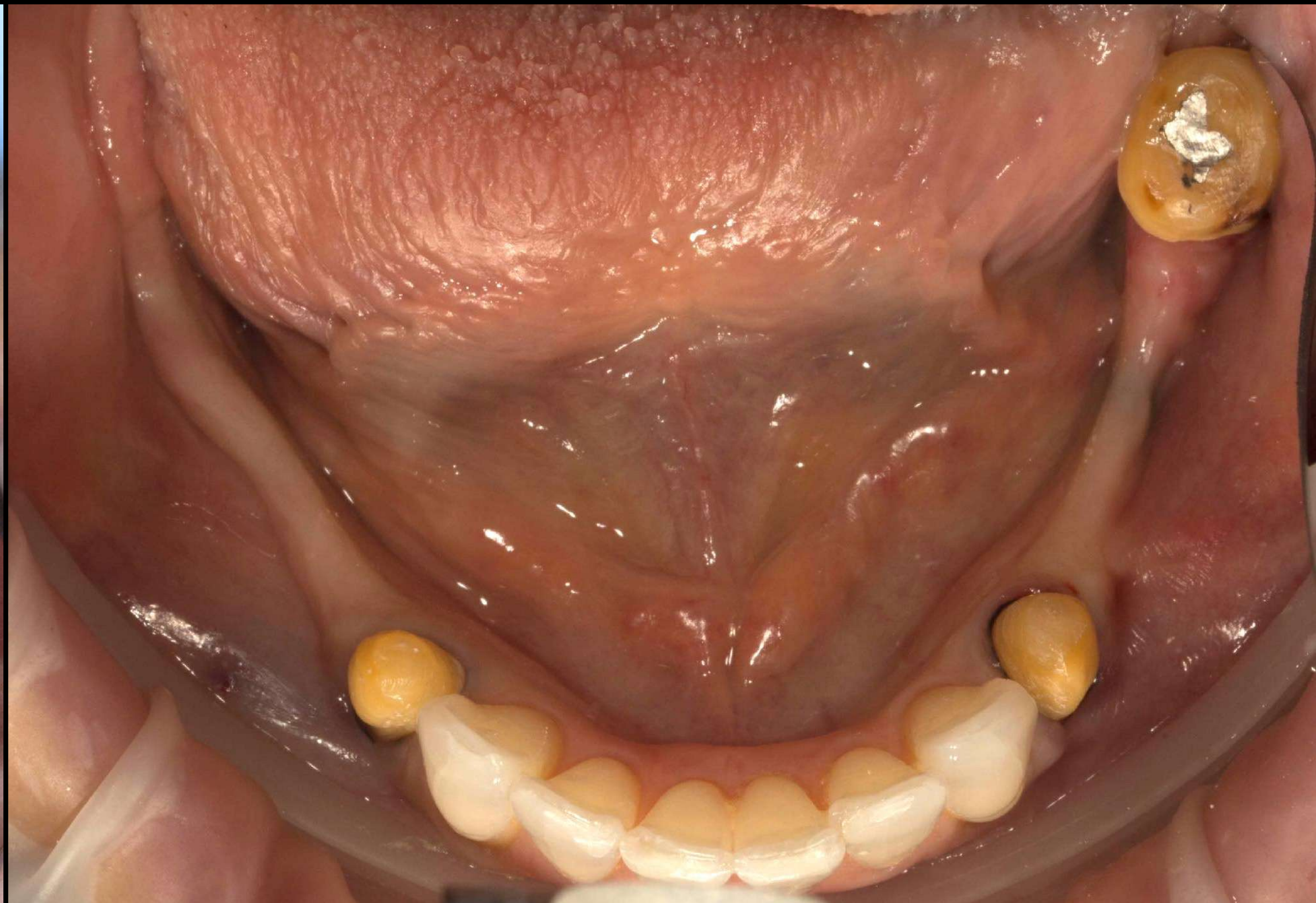
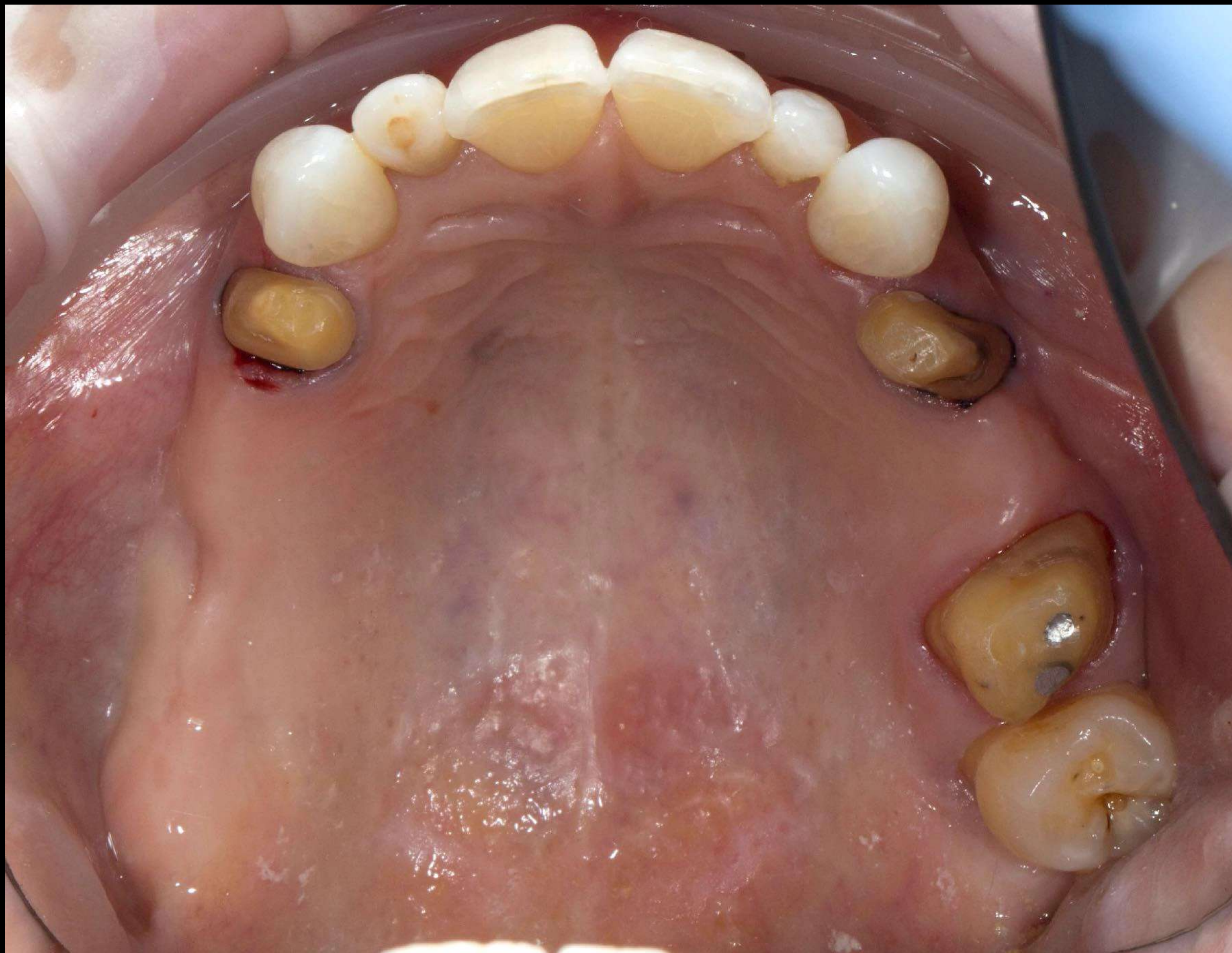



# Crowns










# Lab communication



**matrix**  
DENTAL LABORATORY  
E-mail: info@matrixdental.co.uk

Dentist's Name: FINLAY SUTTON  
 Address: GROSTANG, DENTAL REFERRAL PRACTICE  
WIND HOUSE Account No. \_\_\_\_\_

Patient's Title: Mr / Mrs / Ms  
 Patient's Surname: BRANDWOOD  
 Patient's First Name(s): ANGELA  
 Patient's Age: 59

Delivery Date Required: 6/10/2020  
*N.B. The date required should be one day before fit date*

SHADE: A1 - ENIGMALIFE

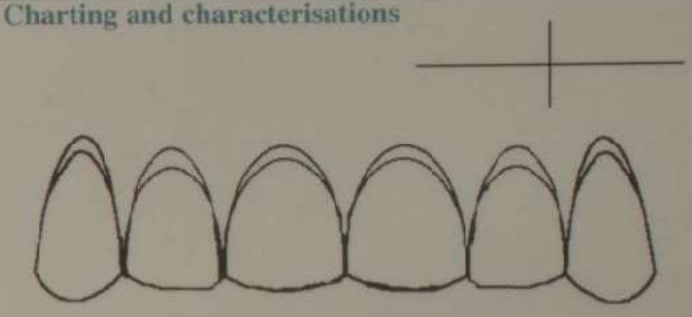
Enclosures:  
 Silicone:  Alginate:  Bite:   
 Study Models:  Face Bow:  Photo / X-ray:   
 Other:  email

Surface Texture:  
 Heavy:  Medium:  Smooth:   
 Glaze: \_\_\_\_\_  
 Low:  Medium:  High:

For a collection please phone  
**0845 1305859**

ALL PORCELAIN	
Porcelain Veneer	
Resin bonded crown	
Porcelain Inlay/Onlay	
Lava Crown	✓
Lava Bridge	
Pressed Ceramics	
ALL COMPOSITE	
Belle Glass Veneer	
Belle Glass Crown	
Belle Glass Inlay/Onlay	
PORCELAIN BONDED TO METAL	
Porcelain bonded to precious metal	
Porcelain bonded to non precious metal	
Porcelain bonded to precious metal bridge	
Porcelain bonded to non precious metal bridge	
Maryland Bridge	
CAST METAL RESTORATIONS	
<i>please use the alloy tick box (below)</i>	
Cast Metal Crown	
Cast Metal Inlay/Onlay	
Cast Post and Core	
ALLOY TYPE	
Precious Bonding	
Yellow Precious Bonding	
Non Precious Bonding	
Yellow Casting 60%	
White Gold Casting	
Non Precious Casting	
MISCELLANEOUS	
Temporary Crown	
Metal Reinforced Temporary Crown	
Diagnostic Wax-up	
Mouth Guard	
Bleaching Tray	
P.V.C. Night Guard	
Tanner/Gelb Appliance	
IMPLANTOLOGY	
Implant Bonded Crown	
Implant Bonded Bridge	
Surgical Stent	
Diagnostic Wax-up	
Implant Retained Denture	
Cresco Precisioning	

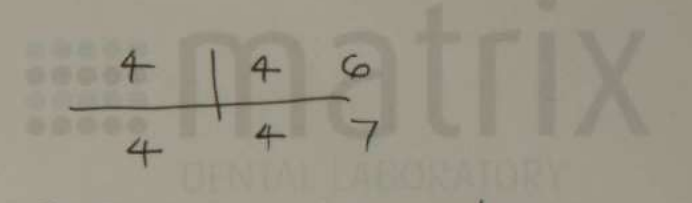
Charting and characterisations



Special Instructions

PLEASE SEE EMAIL .

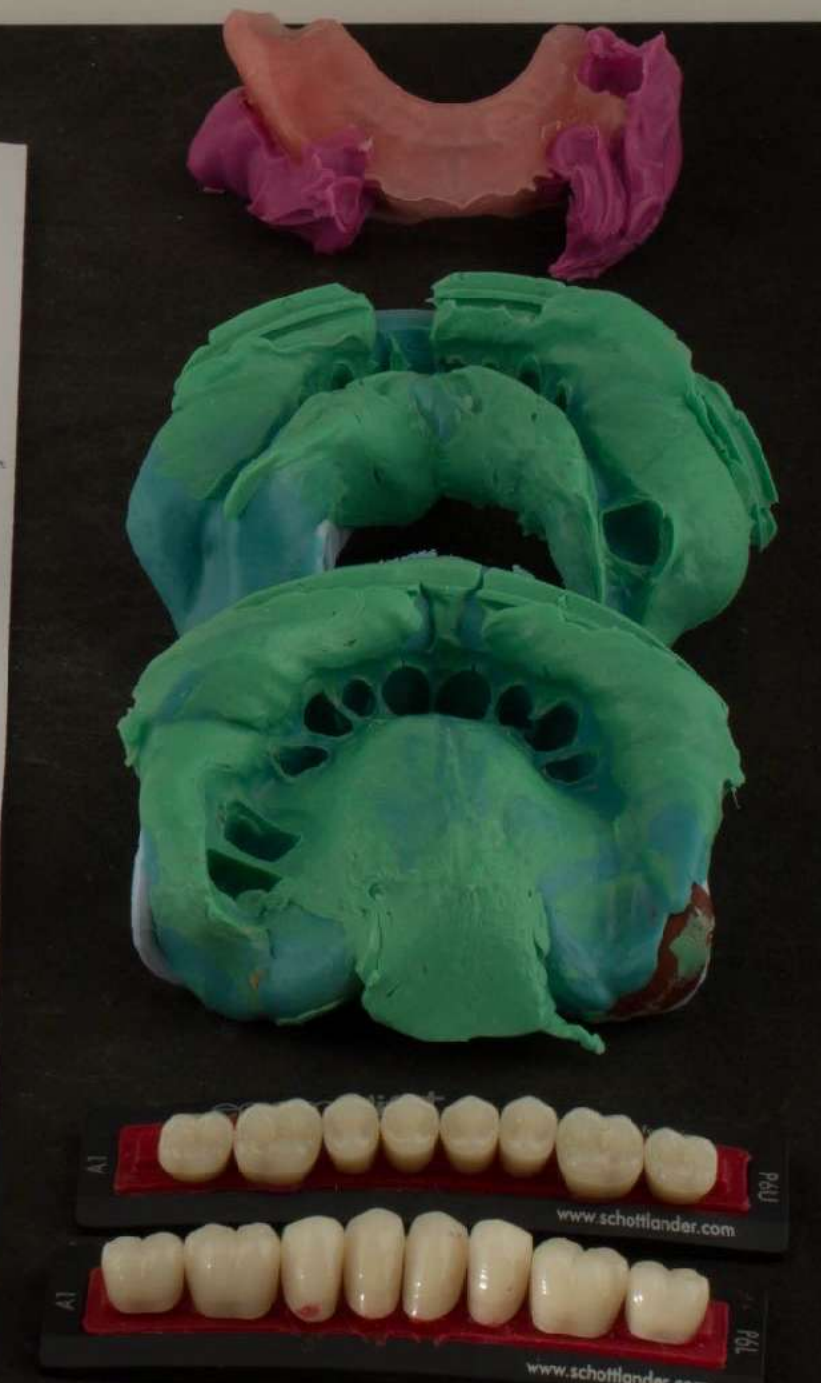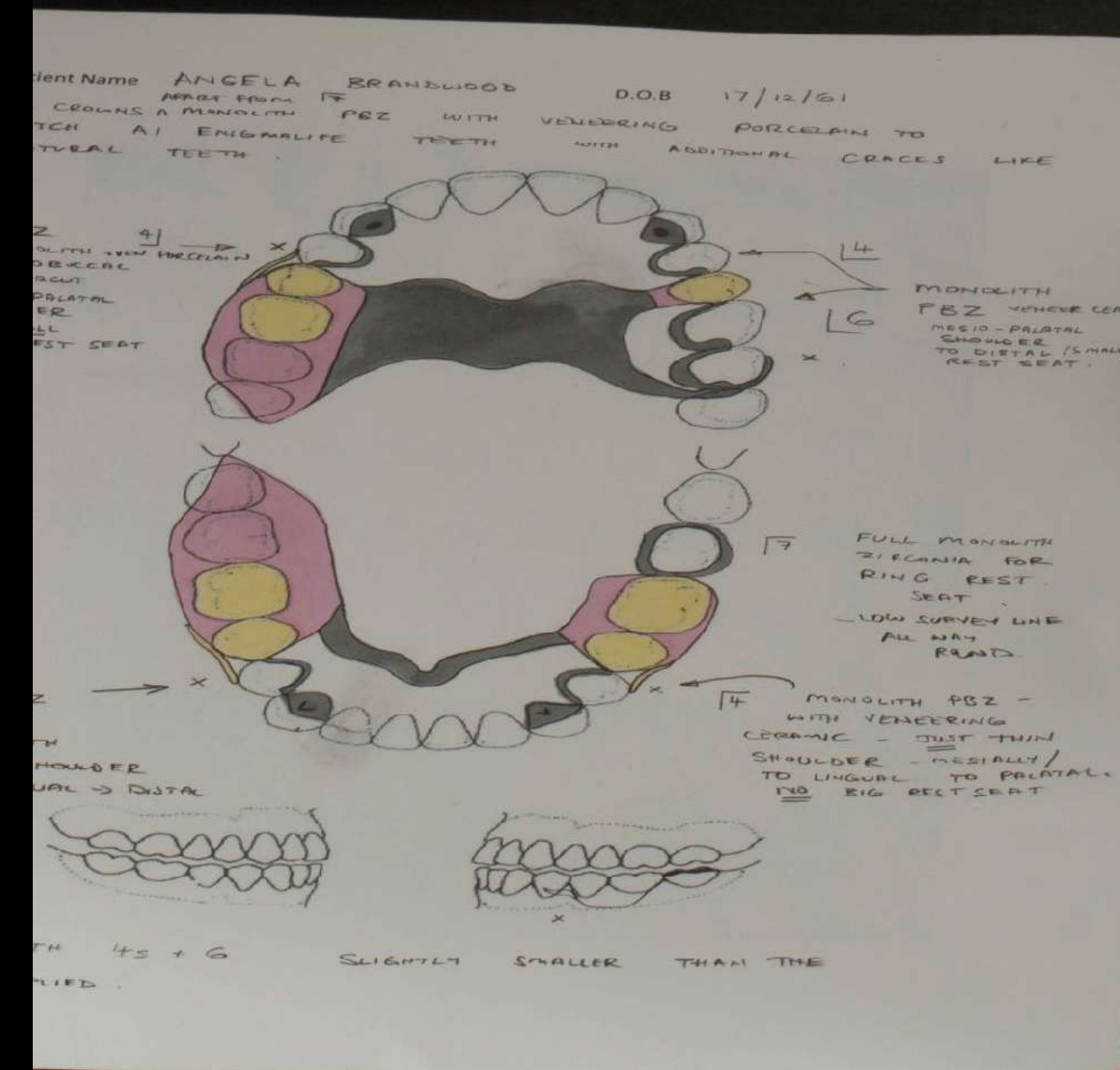
FAO GWYN + SCOTT .



PBZ WITH MILLED / GUIDE SURFACES .

When signed, this device meets the essential requirements of the Medical Devices Directorate.  
 MHRA Reg. No. CA 007978 Signed: \_\_\_\_\_

Job Number: \_\_\_\_\_





# Lab communication - email


6 PBZ Monolith with veneering porcelain (apart from LL7 which will be all monolith).

1. UR4 - PBZ monolith with veneering porcelain to match Enigmalive A1 supplied with small cracks like neighbouring teeth. Please make tooth slightly smaller than the Enigmalive analogue tooth supplied. Disobuccal undercut with mesio, palatal shoulder to small distal rest seat.
2. UL4 - de-rotate PBZ monolith with veneering porcelain to match Enigmalive A1 with small cracks like neighbouring teeth. Please make tooth slightly smaller than the Enigmalive analogue tooth supplied. Mesio, palatal shoulder to small distal rest seat.
3. UL6 PBZ monolith with veneering porcelain to match Enigmalive A1 with small cracks like neighbouring teeth. Please make tooth slightly smaller than the Enigmalive analogue tooth supplied. Mesio, palatal shoulder to small distal rest seat.
4. LL7 PBZ A1 monolith to accommodate a ring rest.
5. LL4 PBZ monolith with veneering porcelain to match Enigmalive A1 supplied with small cracks like neighbouring teeth. Please make tooth slightly smaller than the Enigmalive analogue tooth supplied. Disobuccal undercut with mesio, palatal shoulder to distal - NO REST SEAT.
6. LR4 PBZ monolith with veneering porcelain to match Enigmalive A1 supplied with small cracks like neighbouring teeth. Please make tooth slightly smaller than the Enigmalive analogue tooth supplied. Disobuccal undercut with mesio, palatal shoulder to distal - NO REST SEAT.

All guiding surfaces parallel on all teeth please.



# Loom video



Patient Name ANGELA BRANDWOOD D.O.B 17/12/61  
 APART FROM 17  
 ALL CROWNS A MONOLITH PBZ WITH VENEERING PORCELAIN TO  
 MATCH A1 ENIGMALIFE TEETH WITH ADDITIONAL CRACKS LIKE  
 NATURAL TEETH.

**4** PBZ MONOLITH WITH PORCELAIN  
 DISTOBUCCAL UNDERCUT  
 MESIO-PALATAL SHOULDER  
 TO SMALL DISTAL REST SEAT

**4** MONOLITH PBZ WITH VENEERING CERAMIC WITH JUST THIN SHOULDER  
 MEDALLY → LINGUAL → DISTAL  
 NO BIG REST SEATS

**4** MONOLITH PBZ - WITH VENEERING CERAMIC - JUST THIN SHOULDER - MESIALLY / TO LINGUAL TO PALATAL. NO BIG REST SEAT

**6** MONOLITH PBZ VENEER CERAMIC  
 MESIO-PALATAL SHOULDER TO DISTAL (SMALL) REST SEAT.

**7** FULL MONOLITH ZIRCONIA FOR RING REST SEAT.  
 LOW SURVEY LINE ALL WAY ROUNDS.







**Scott Cunliffe** <scottcunliffe1@googlemail.com>

to me ▼

Hi Finlay.

This is quality communication! You're the best! It really is a pleasure to do your work.

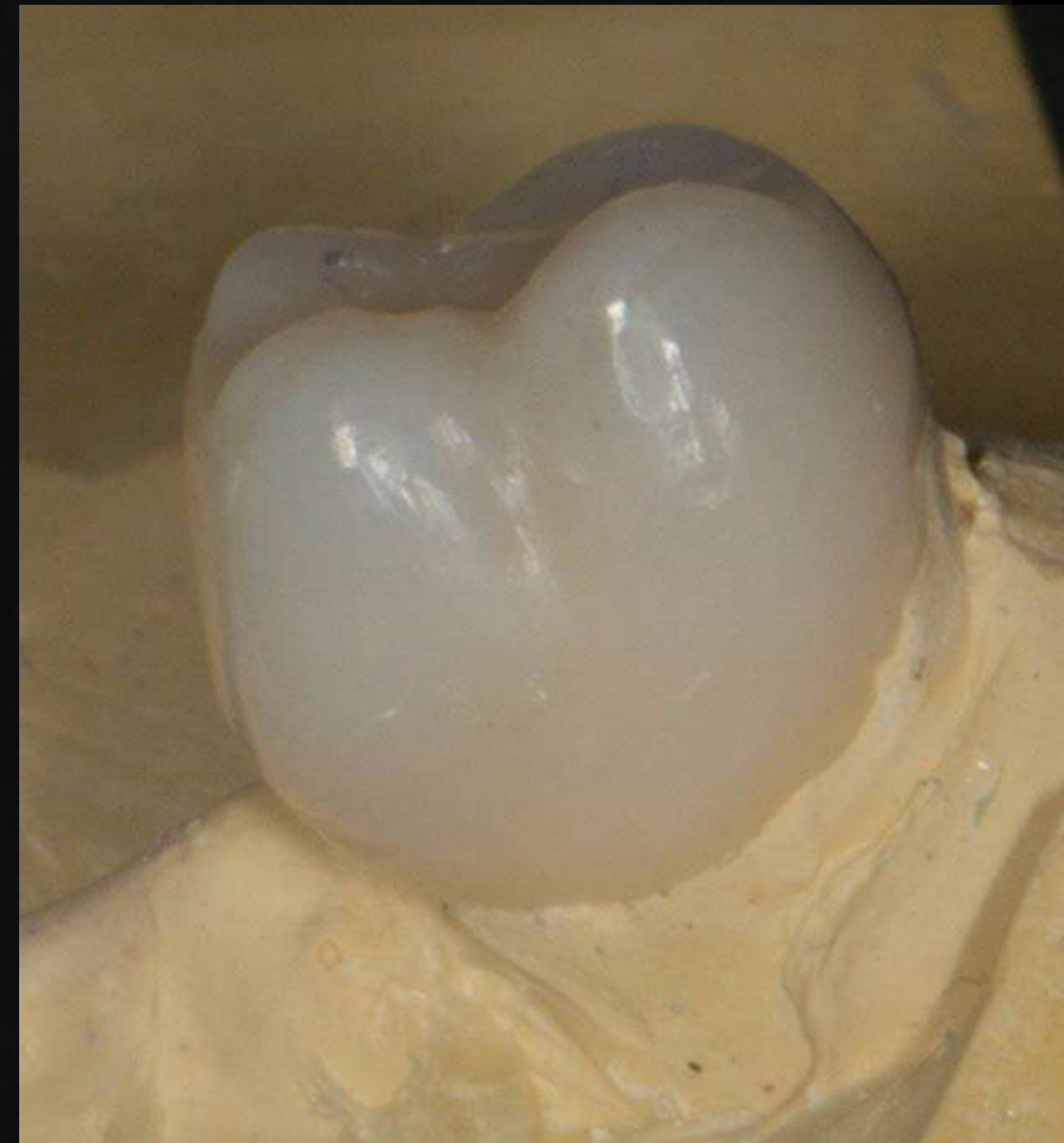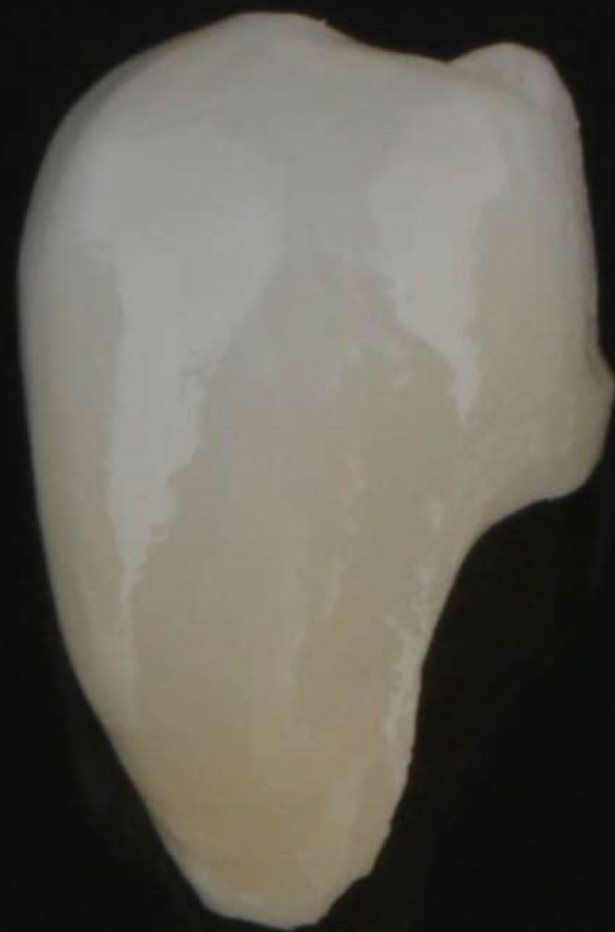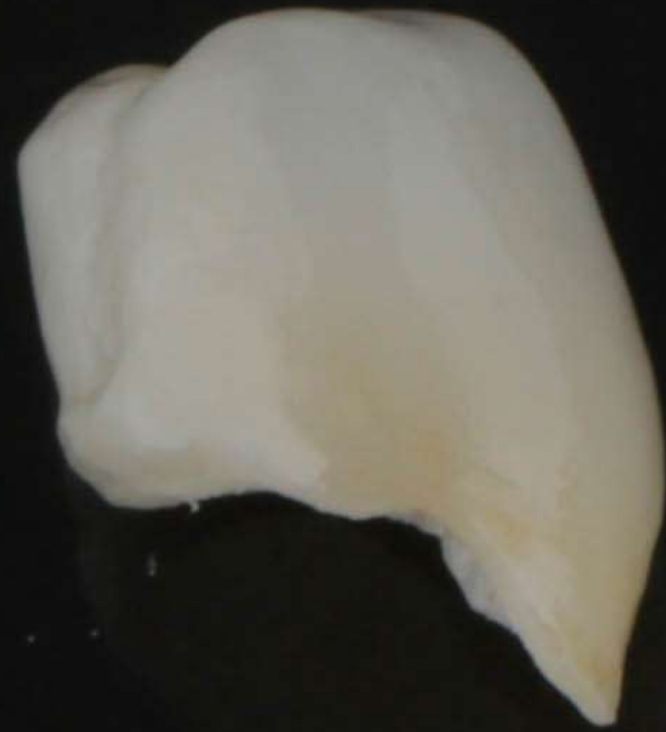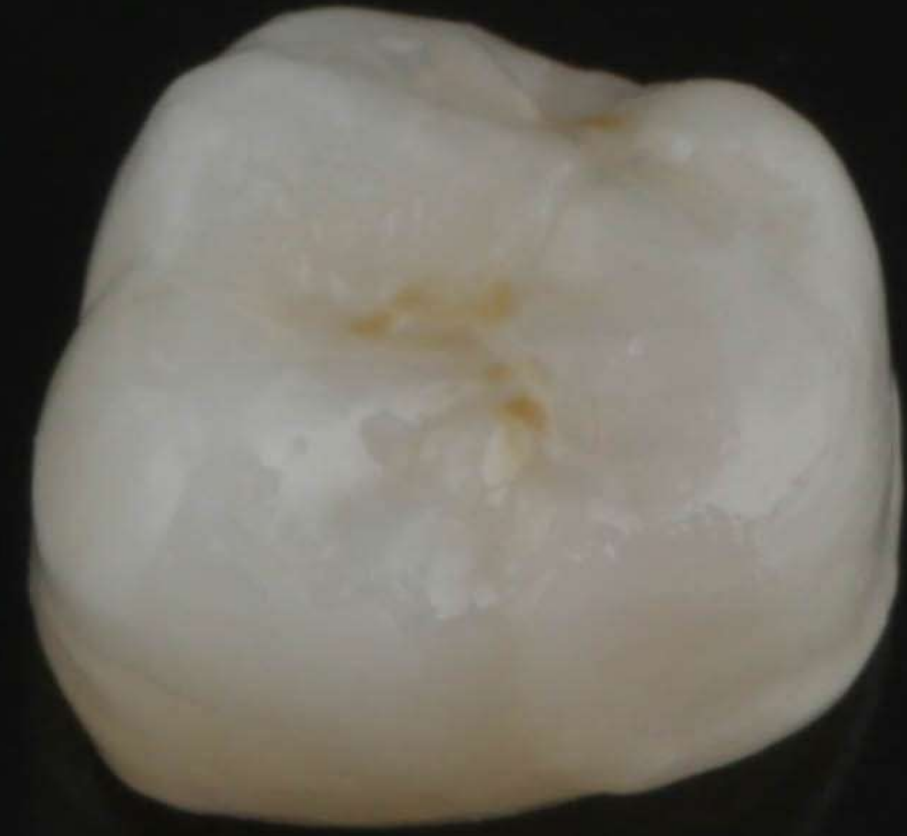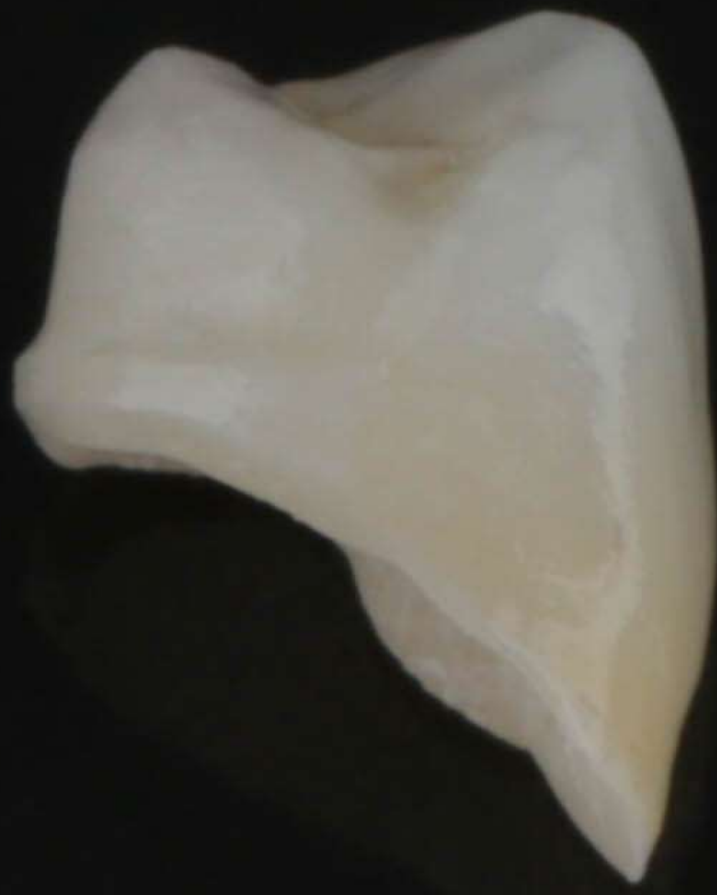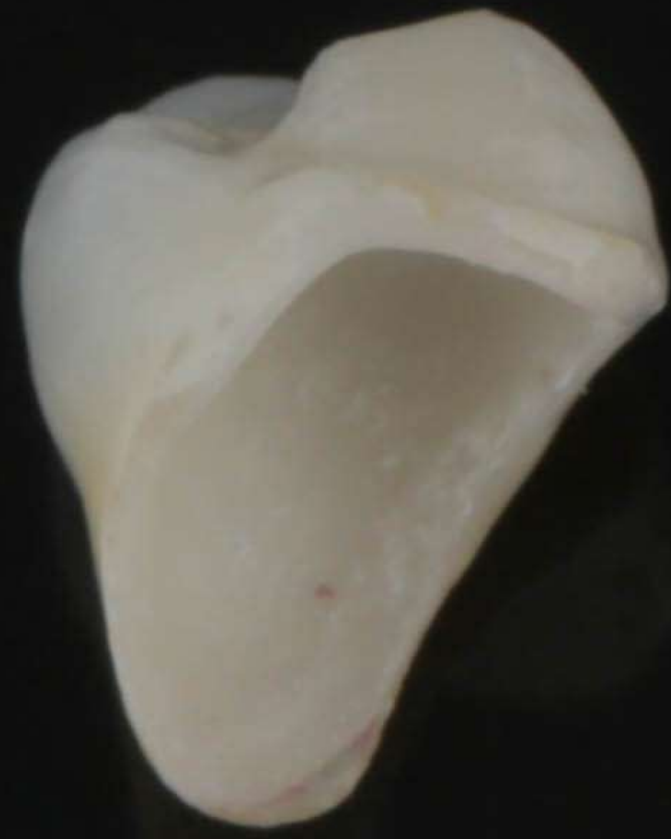I wish more were like you.

Good man!

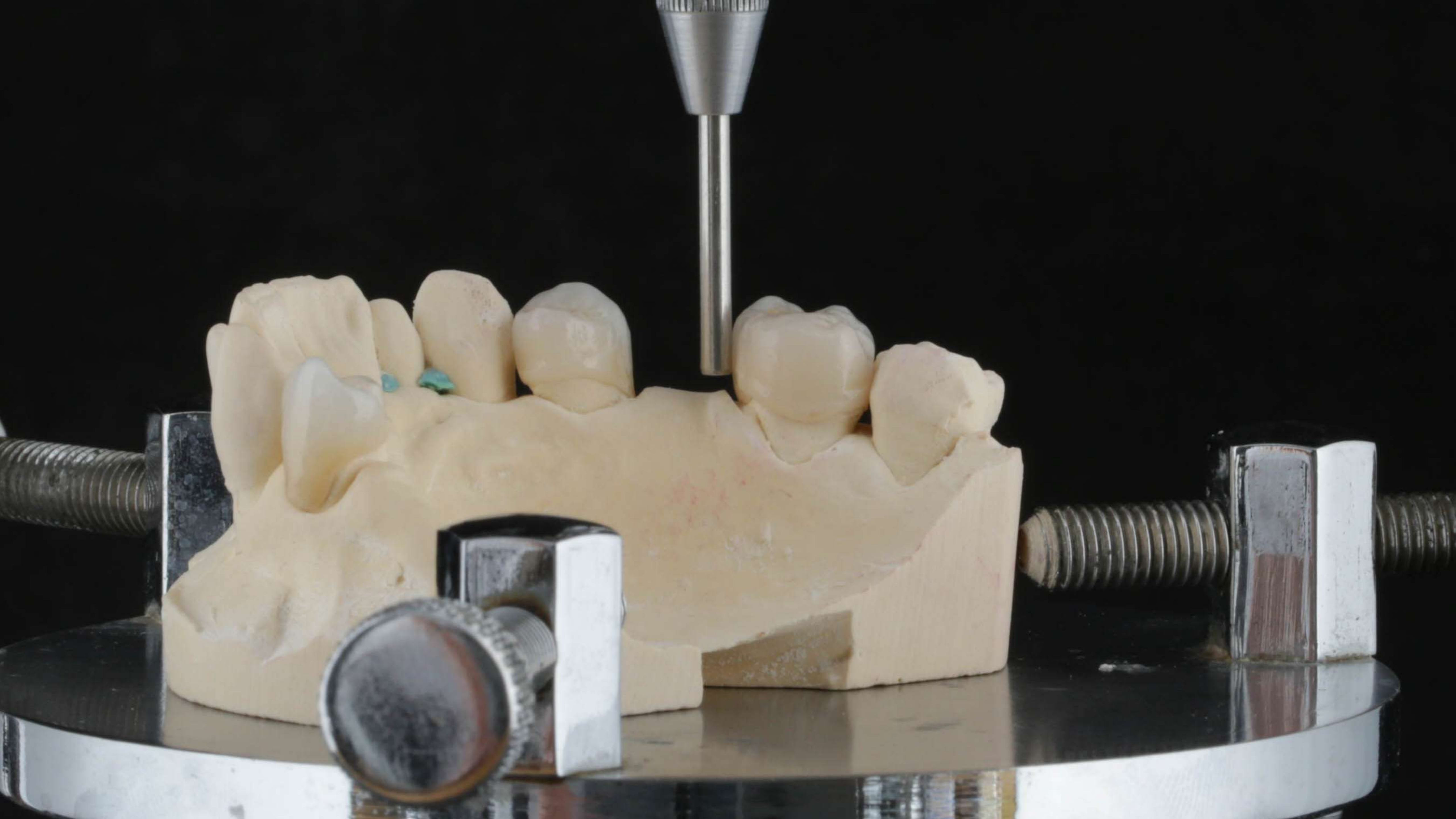Many thanks

Scott.

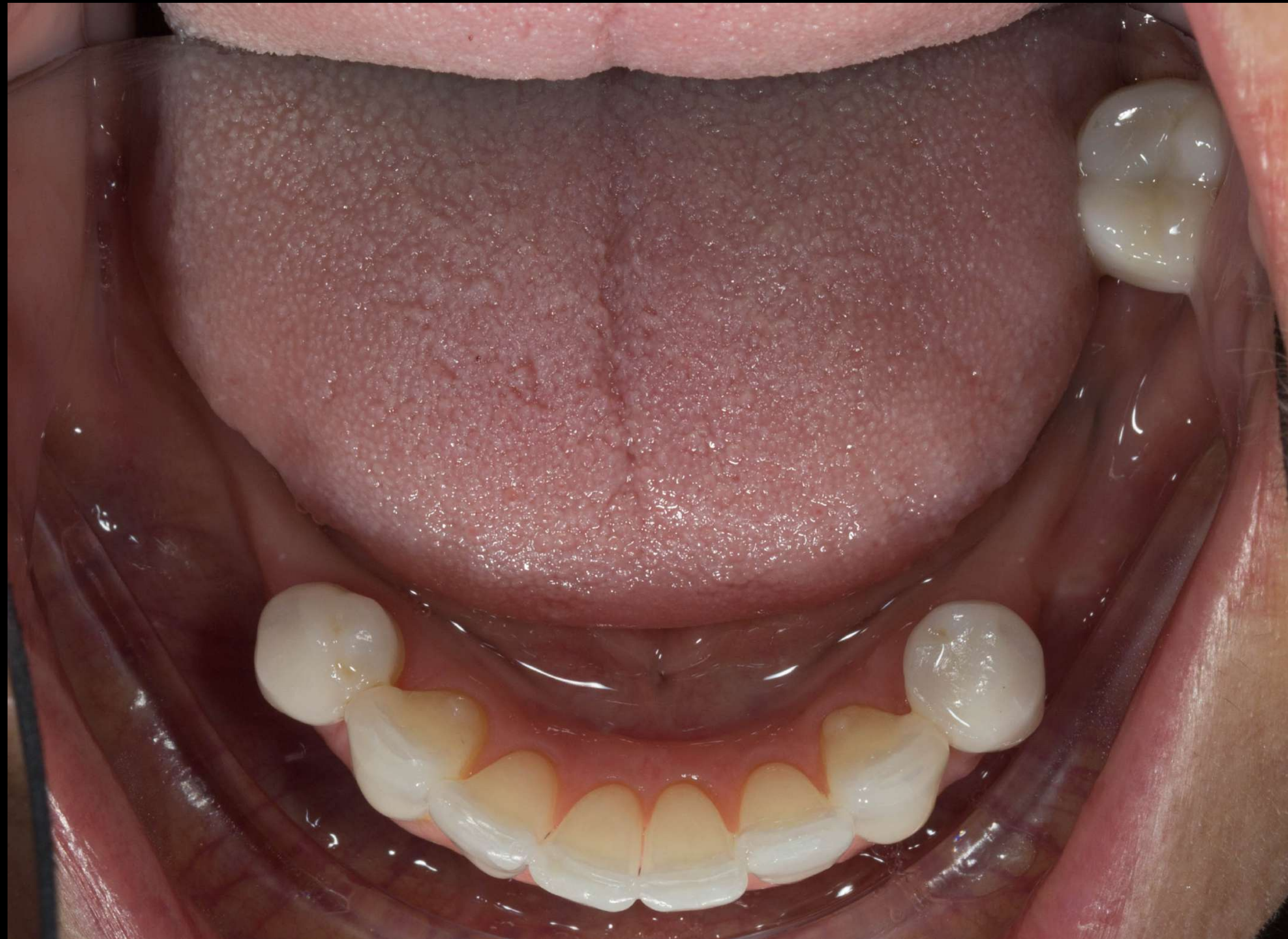
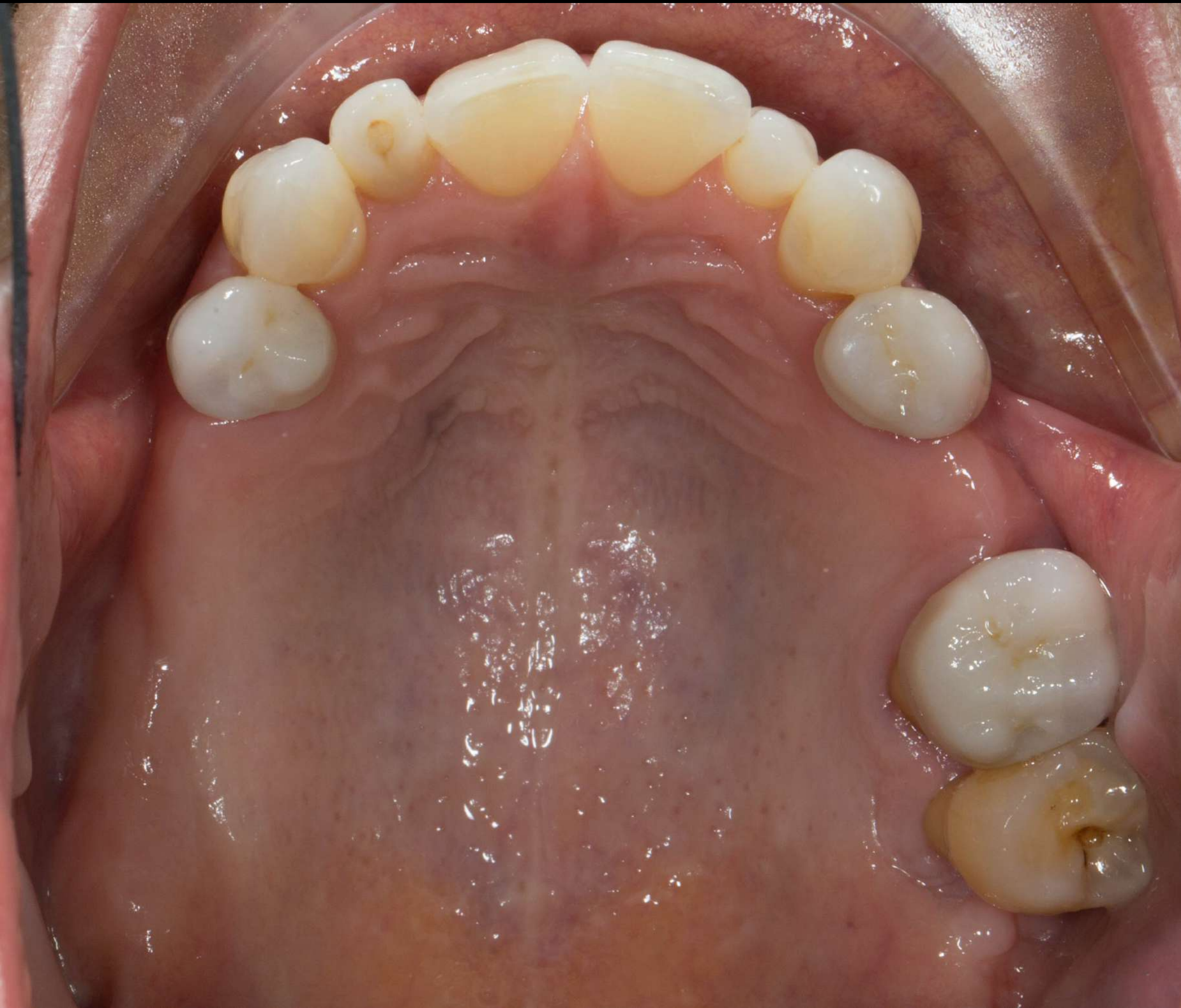




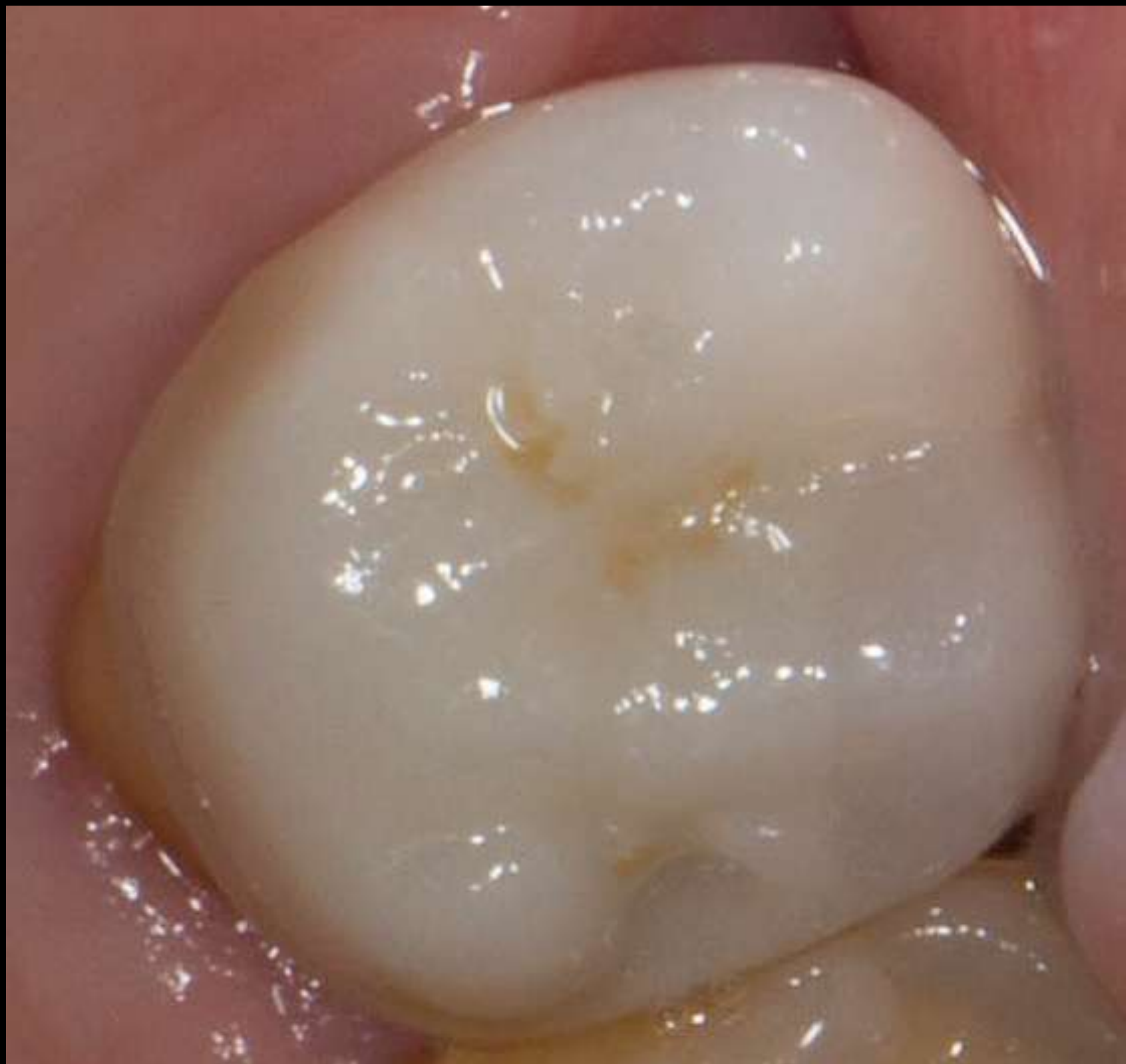
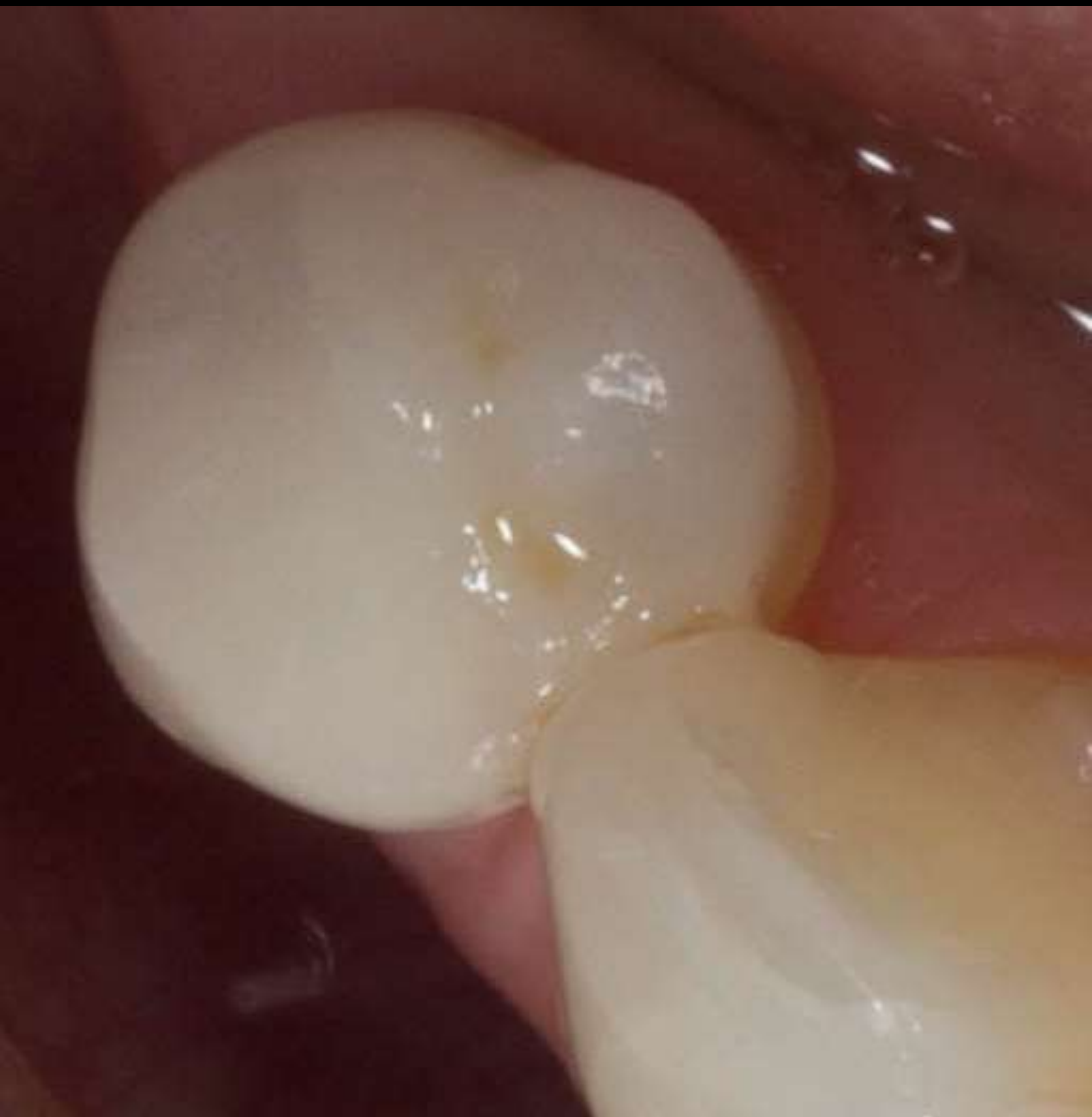




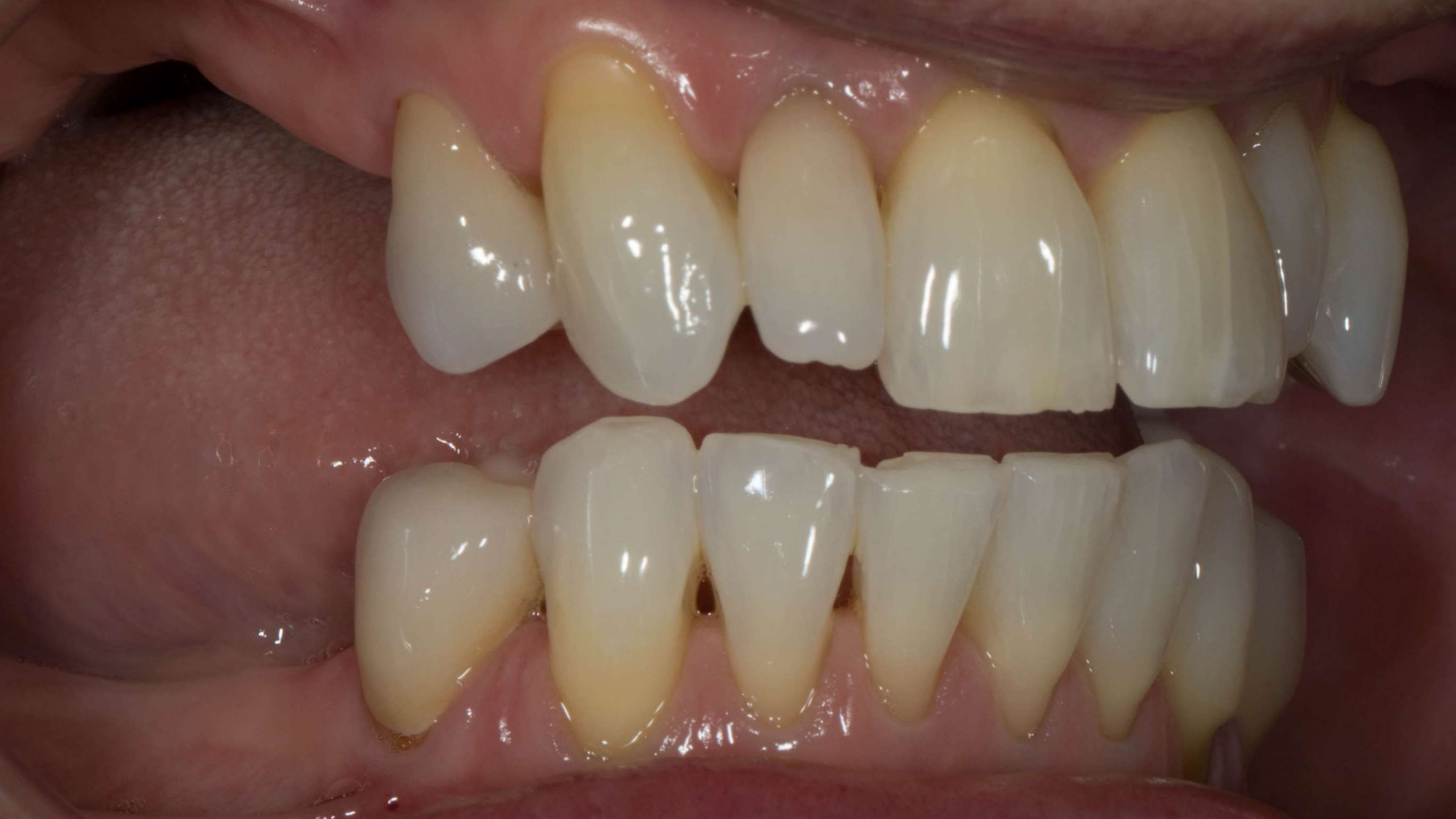




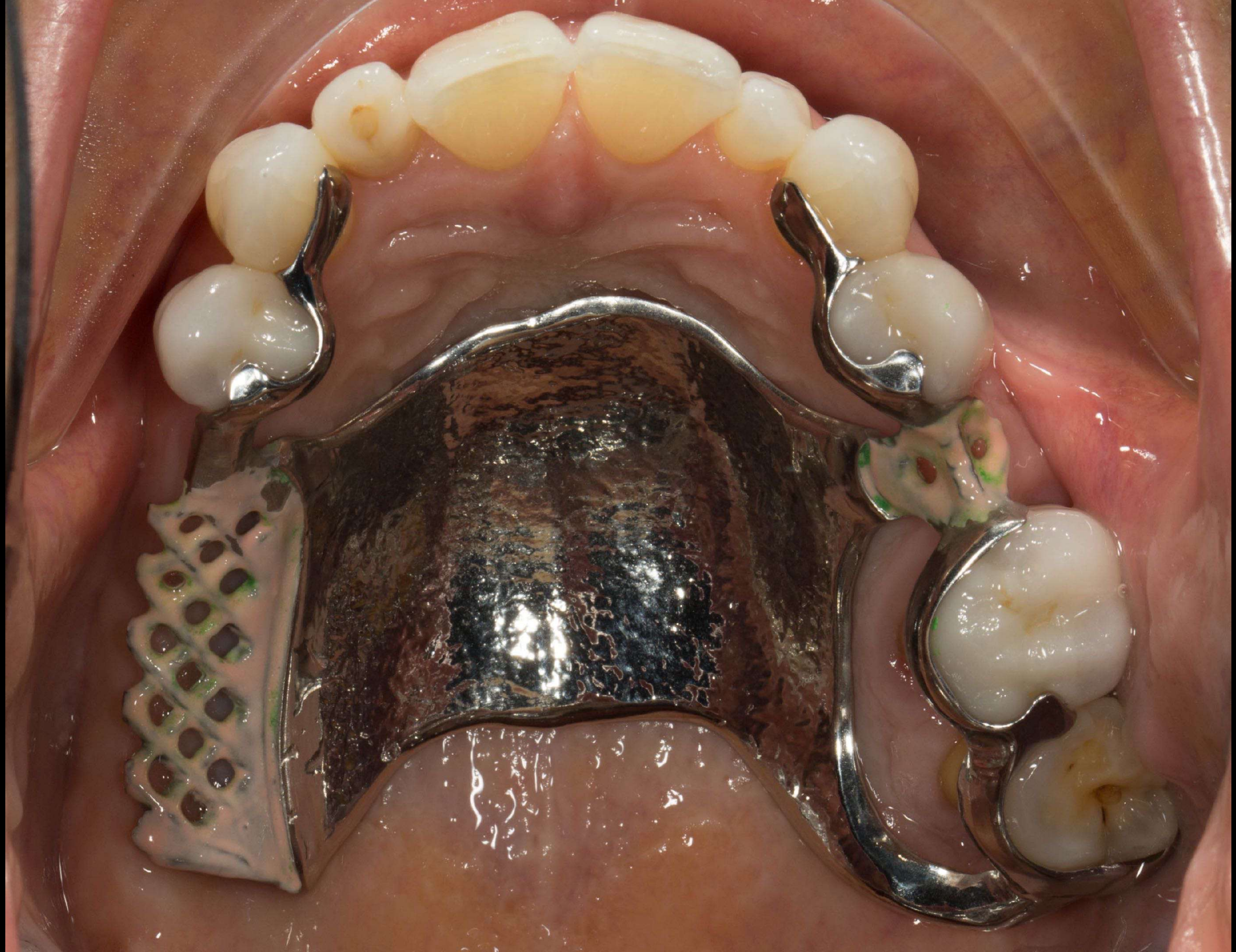




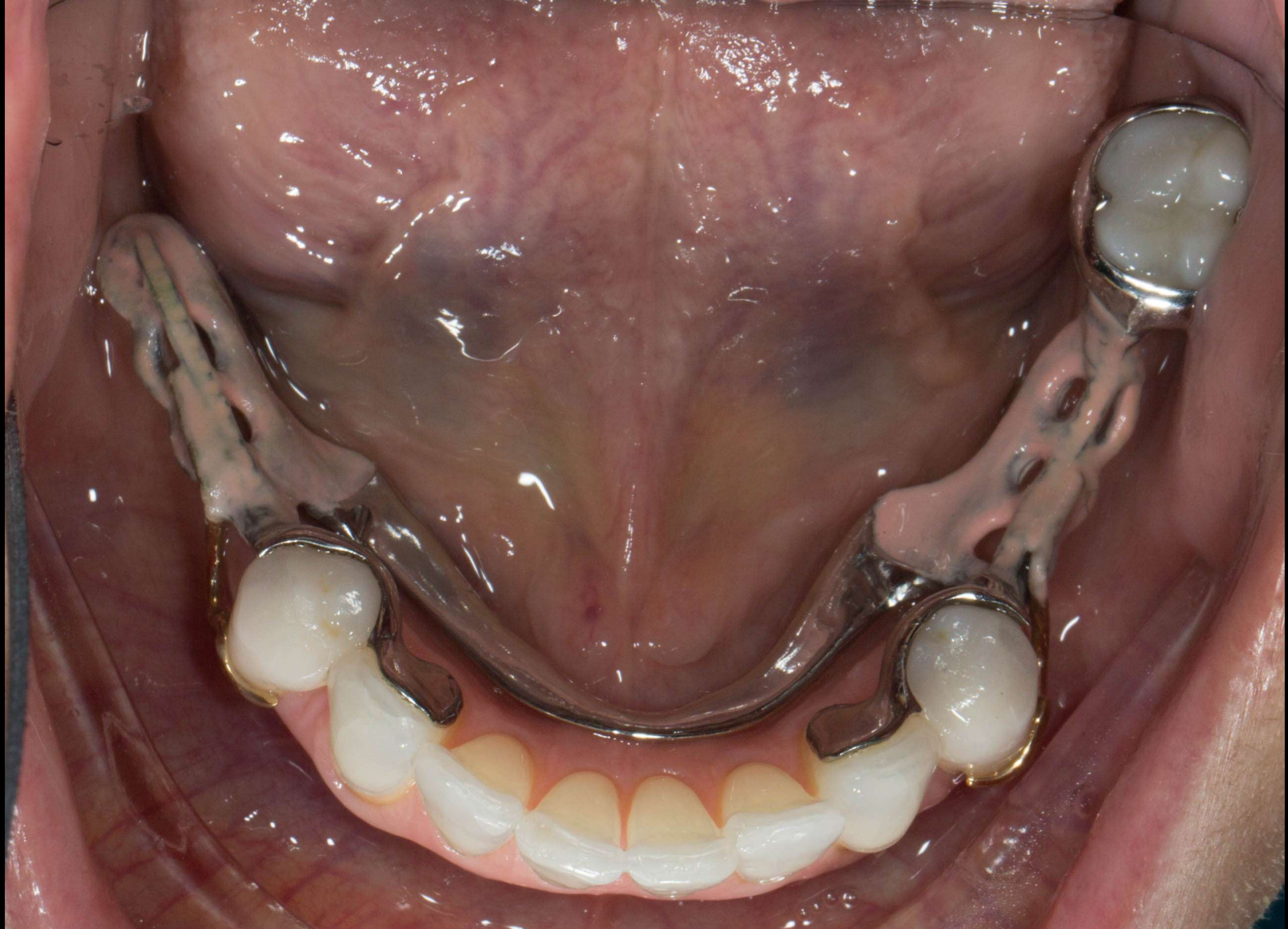




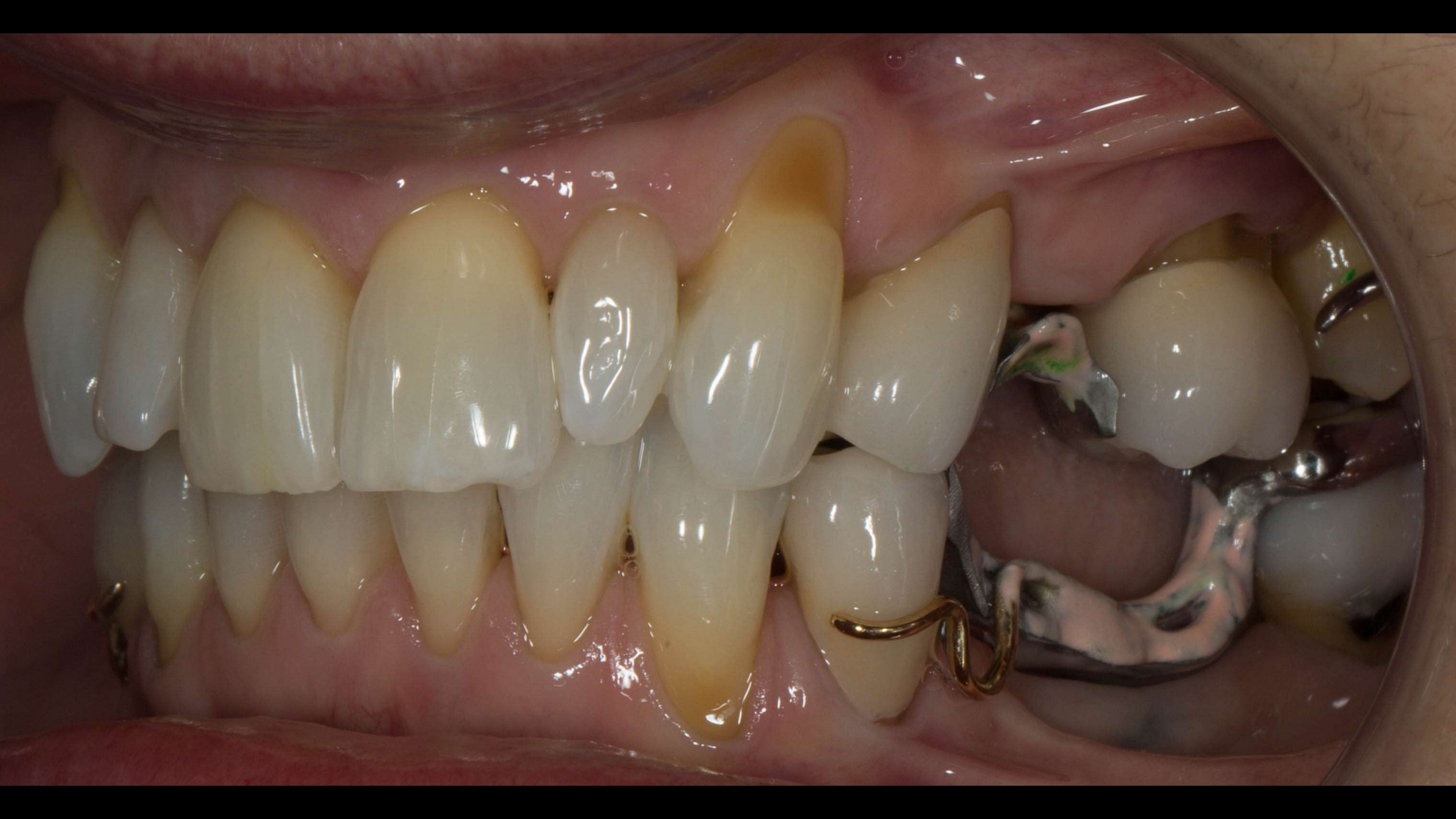
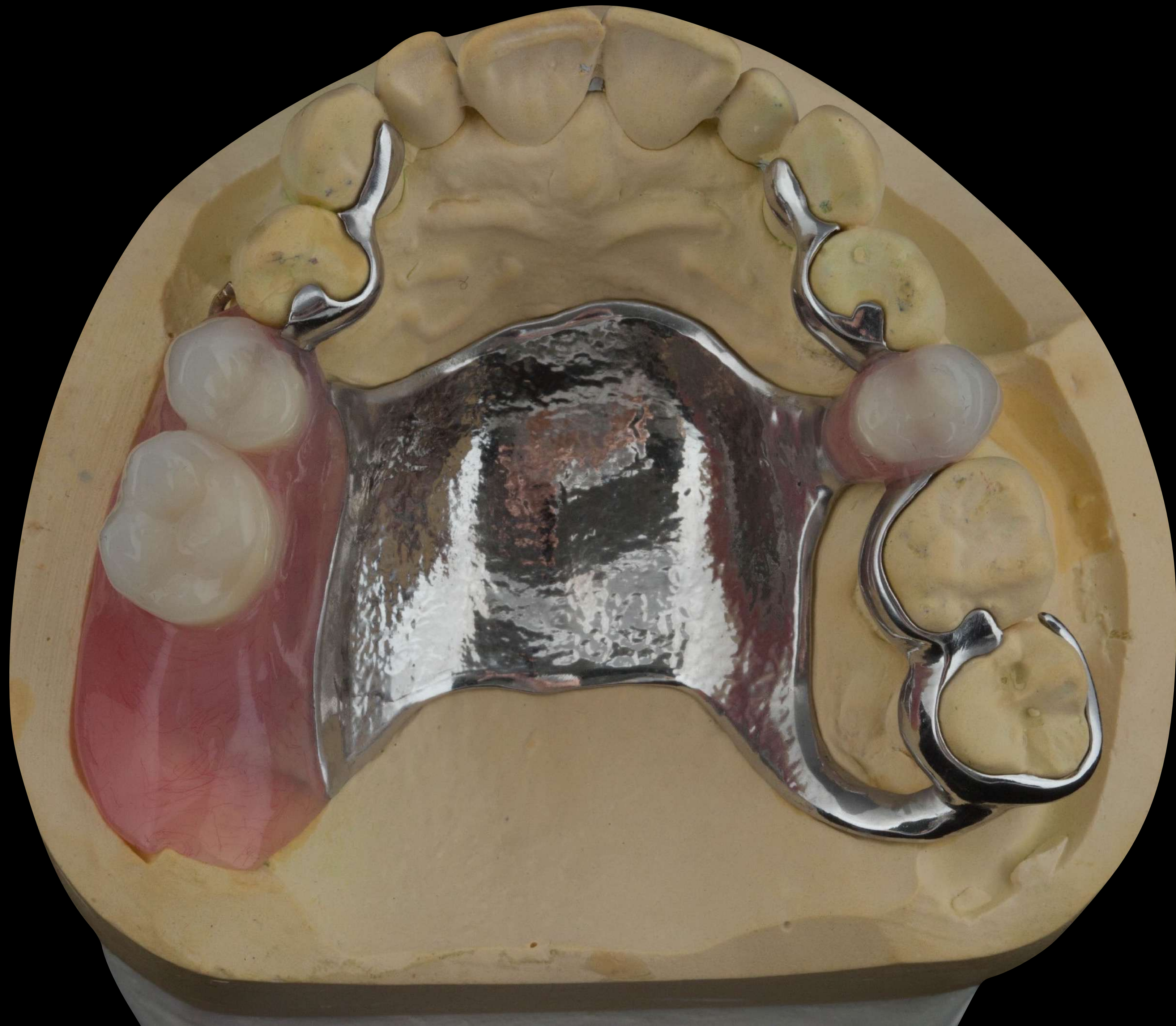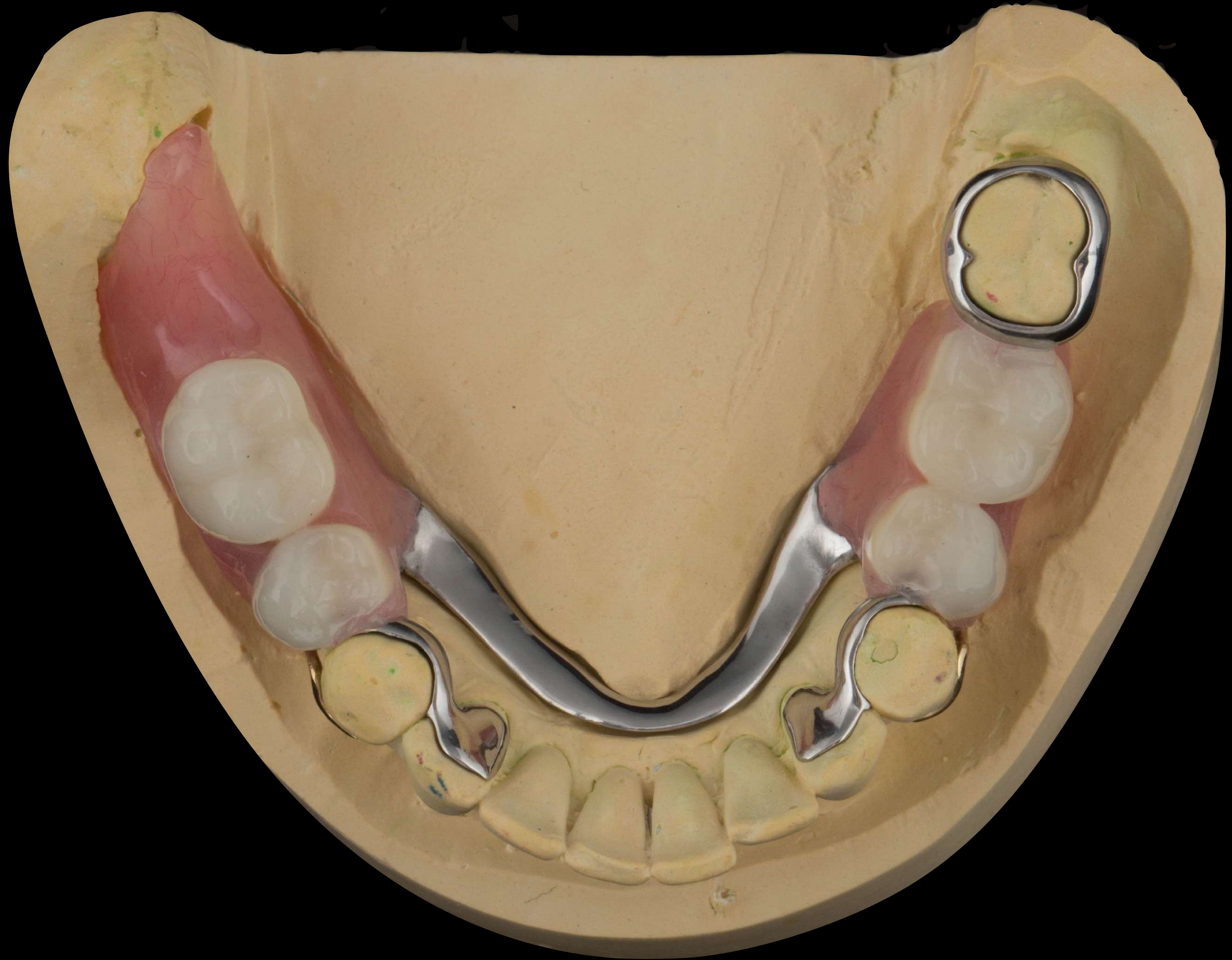













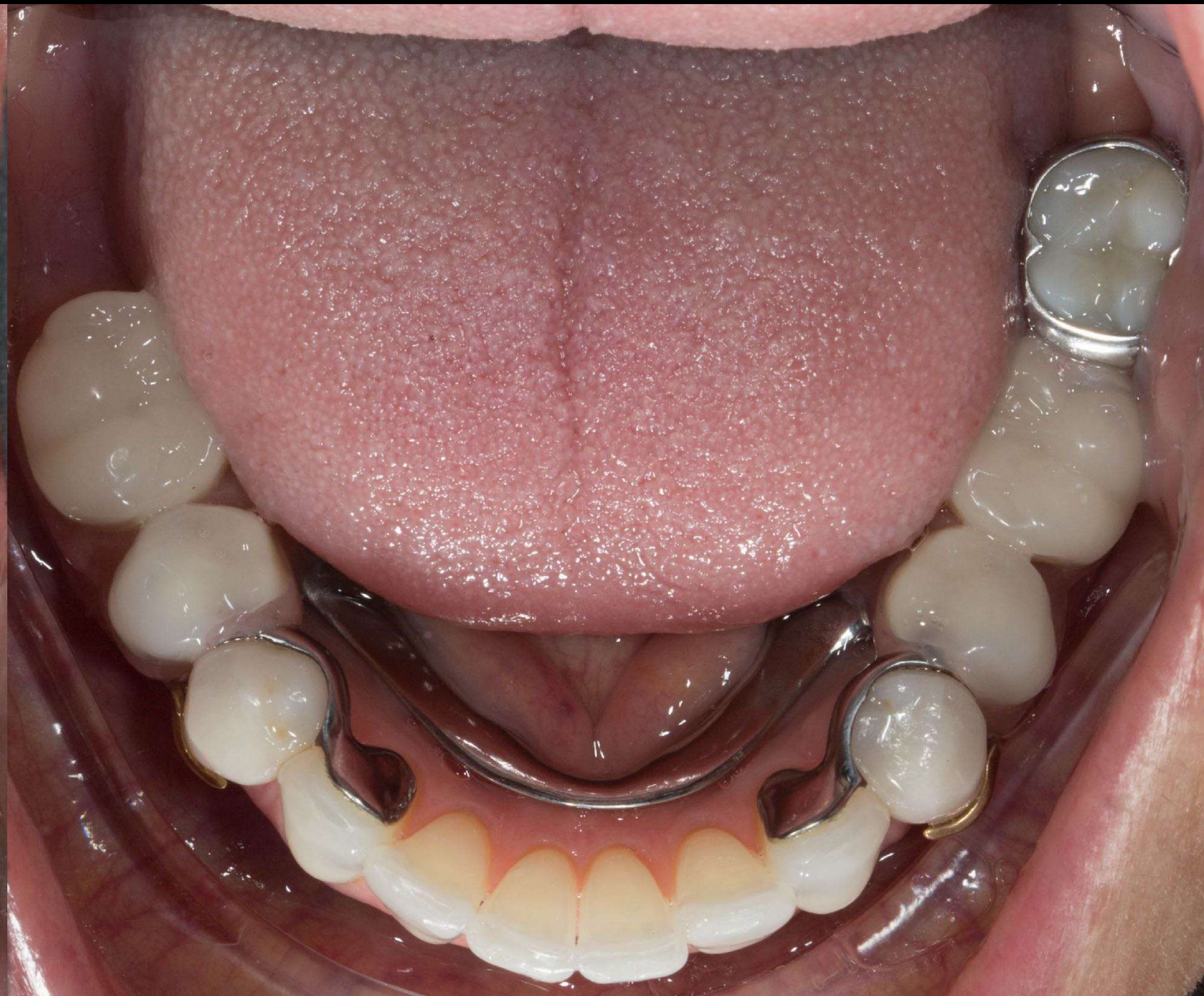
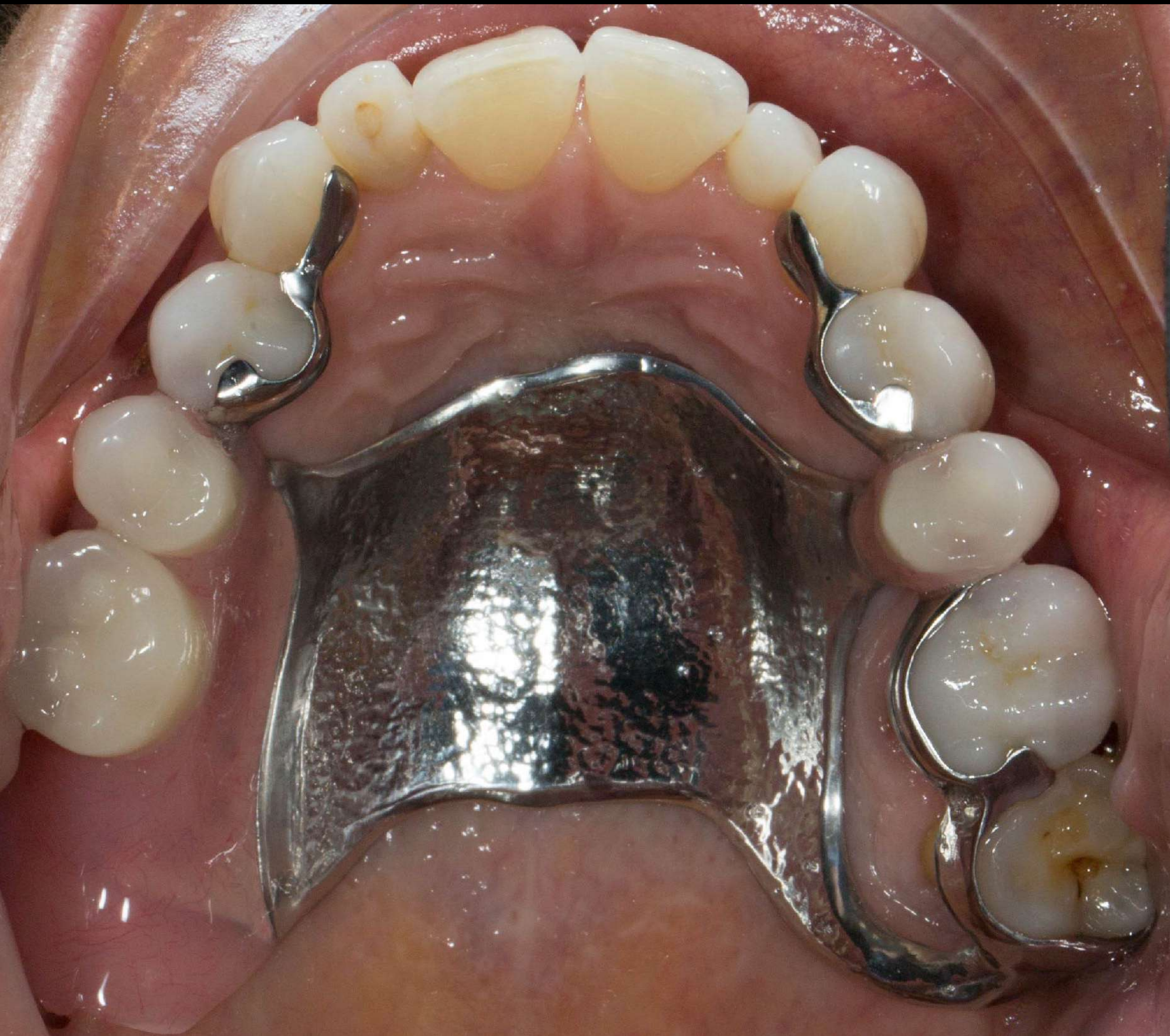




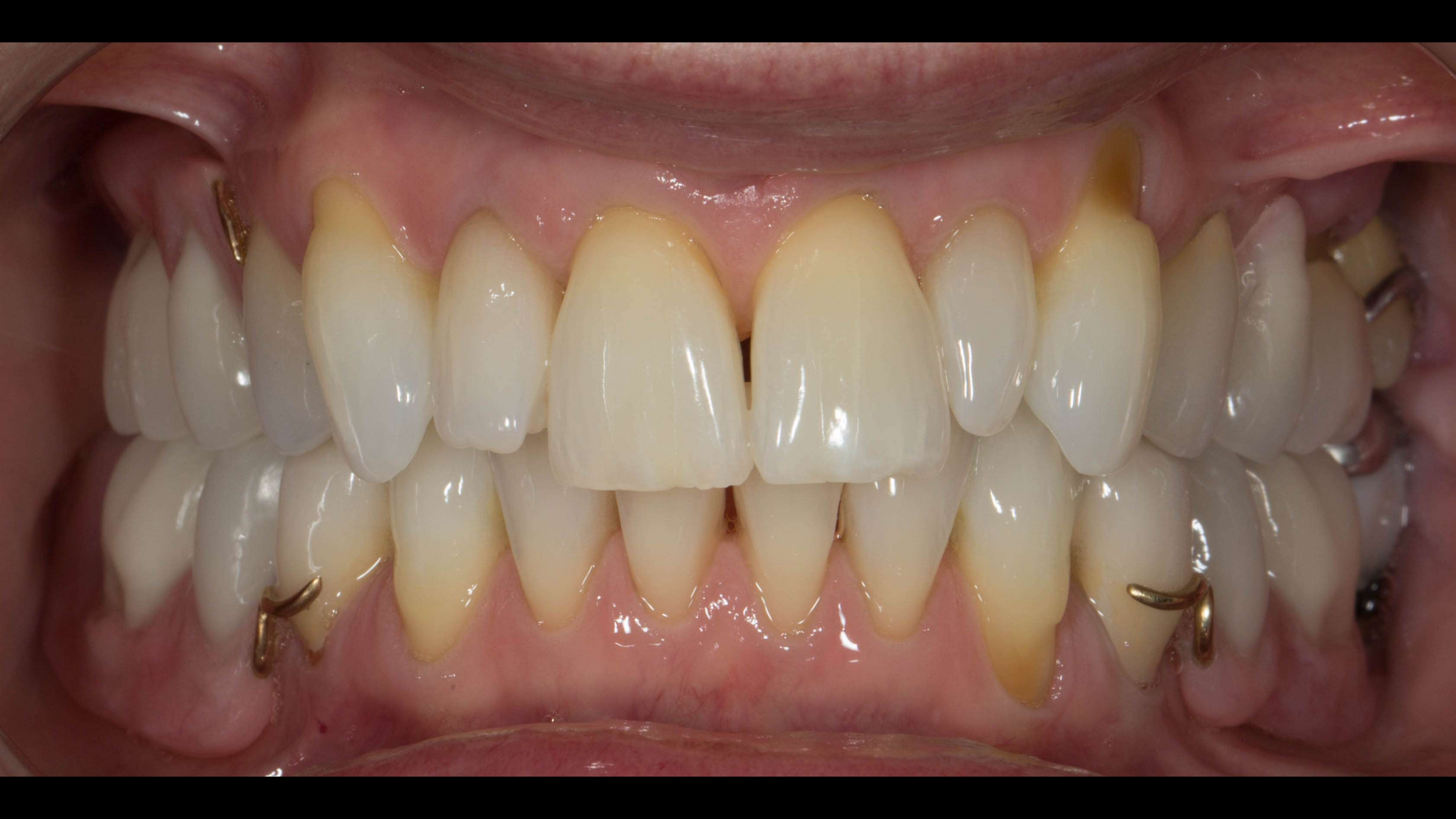




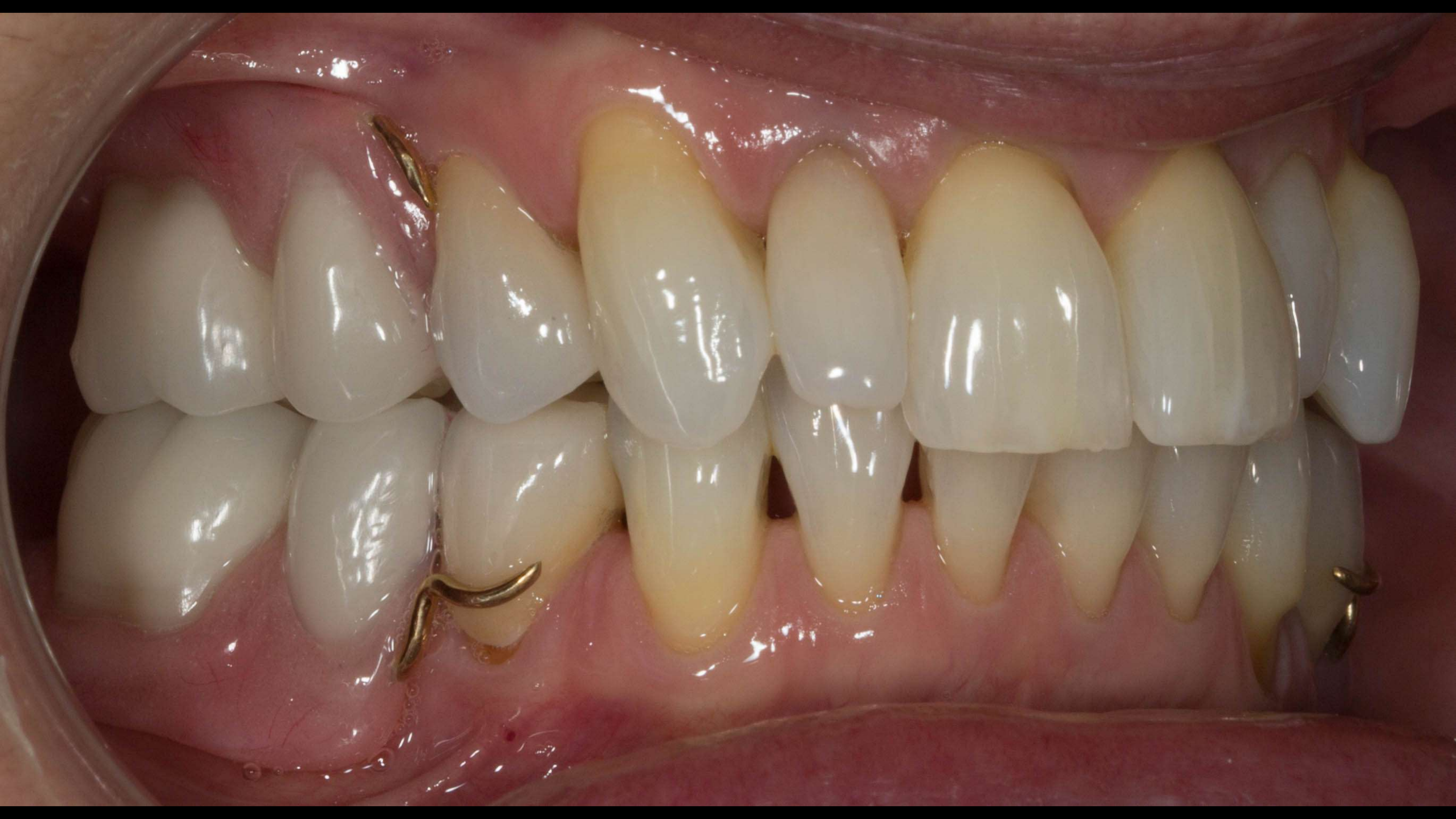




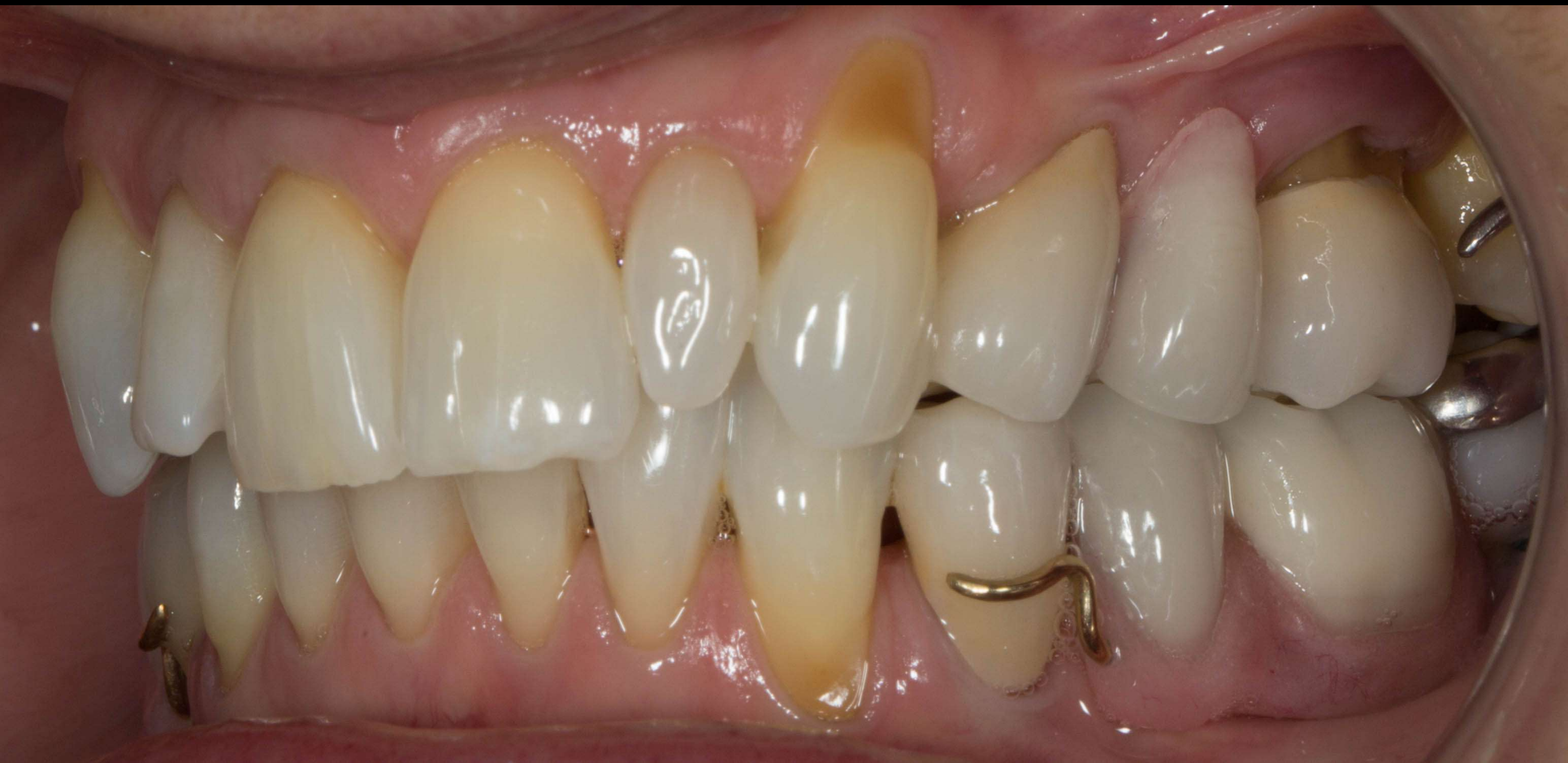




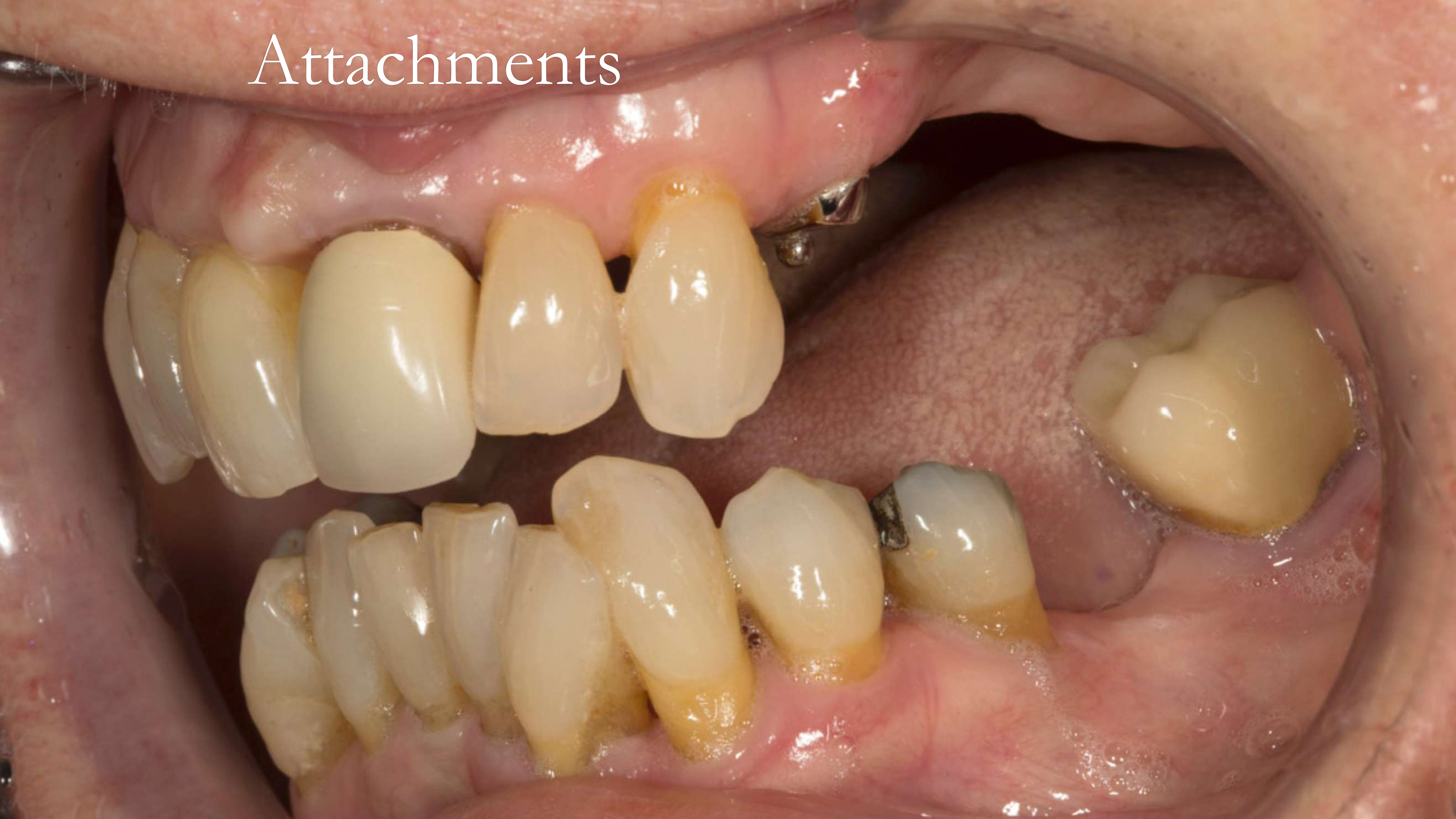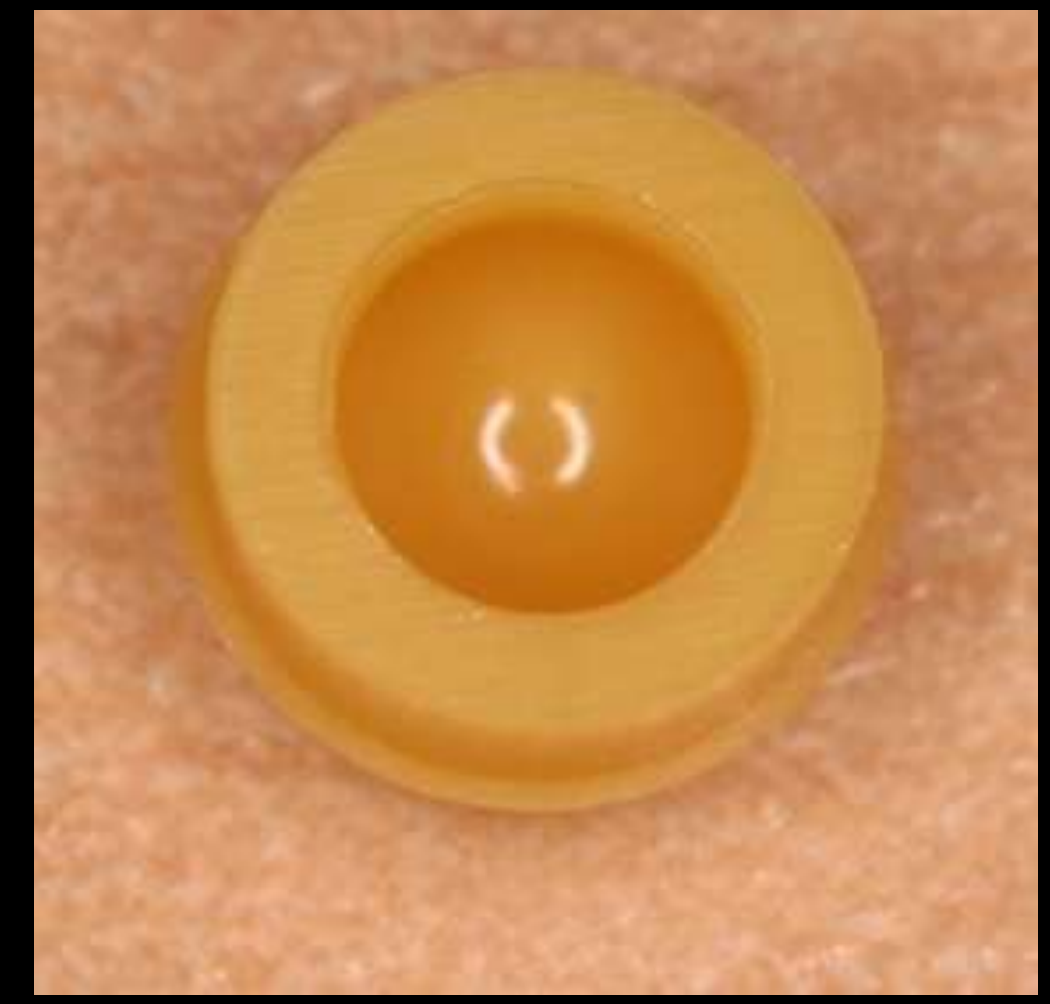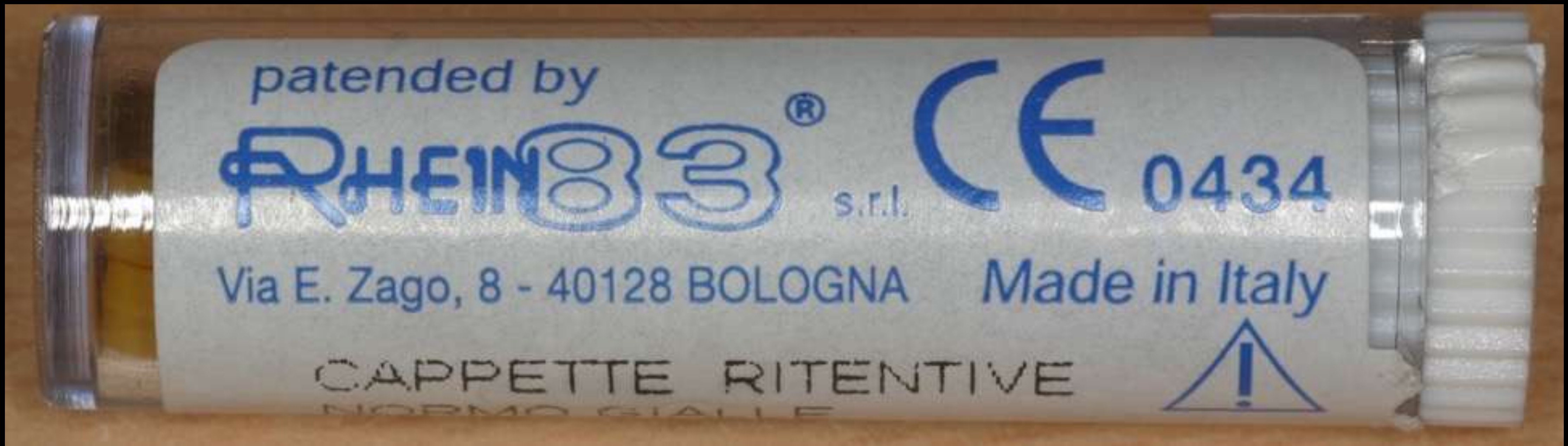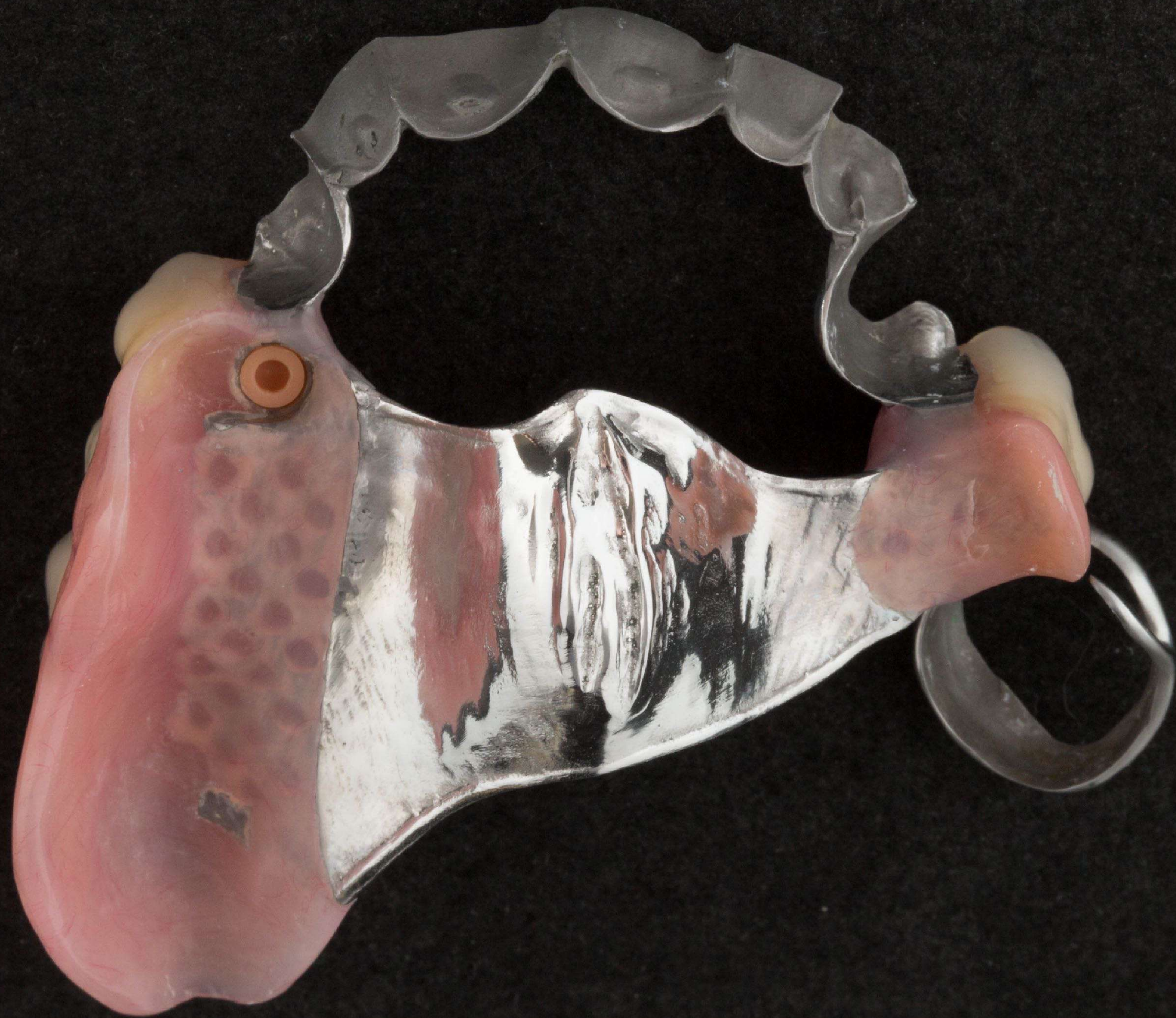# Attachments



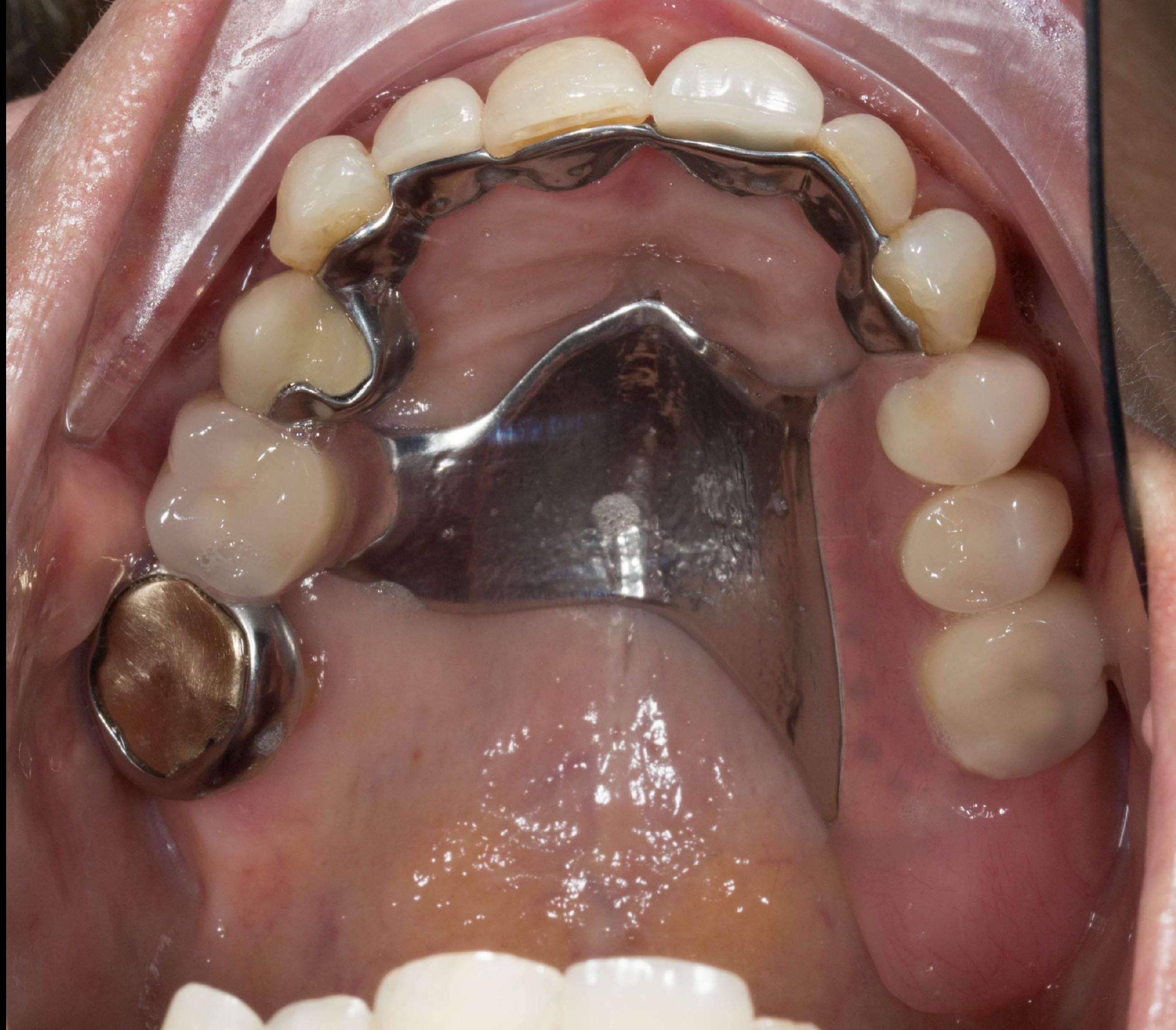




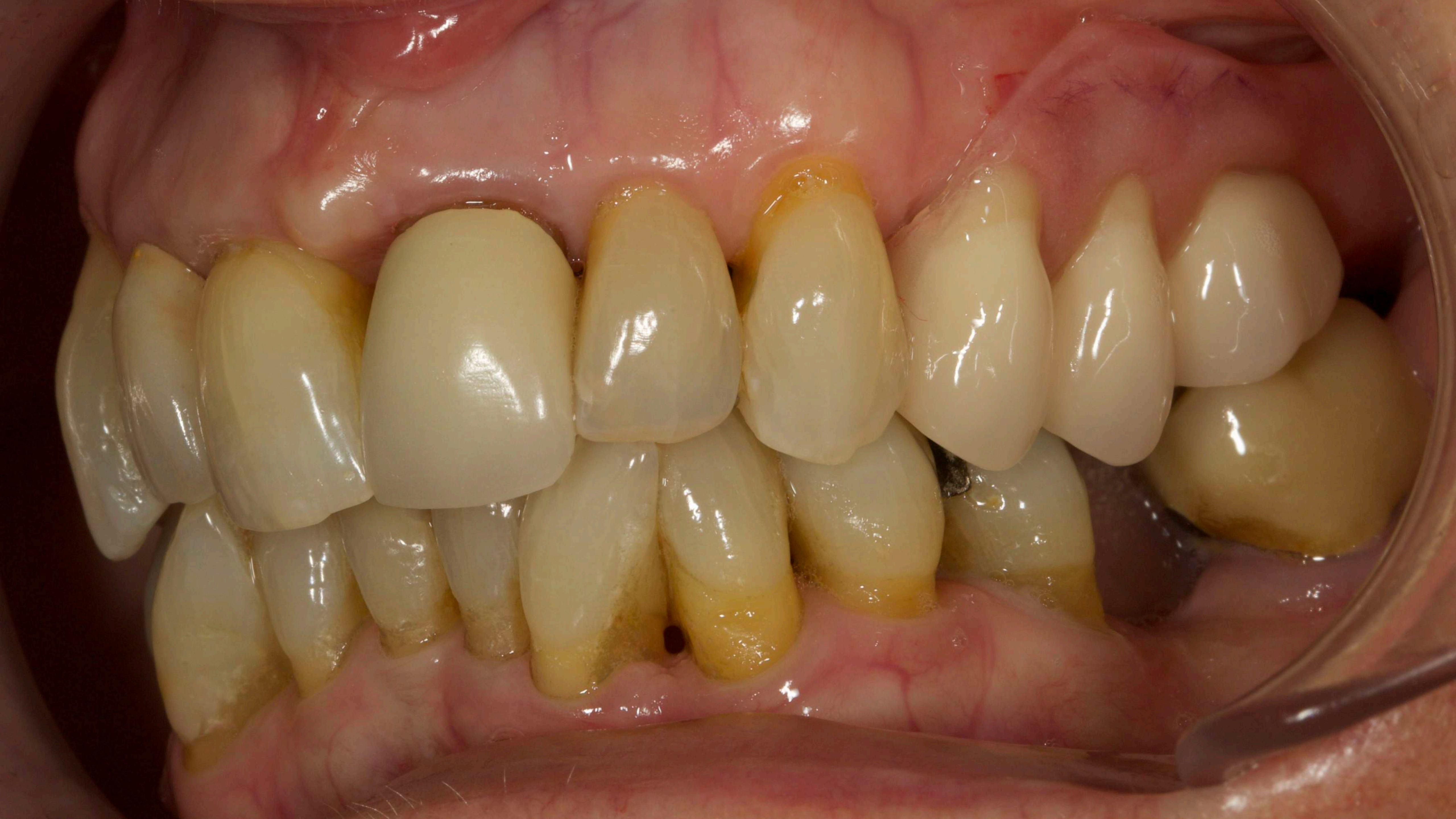




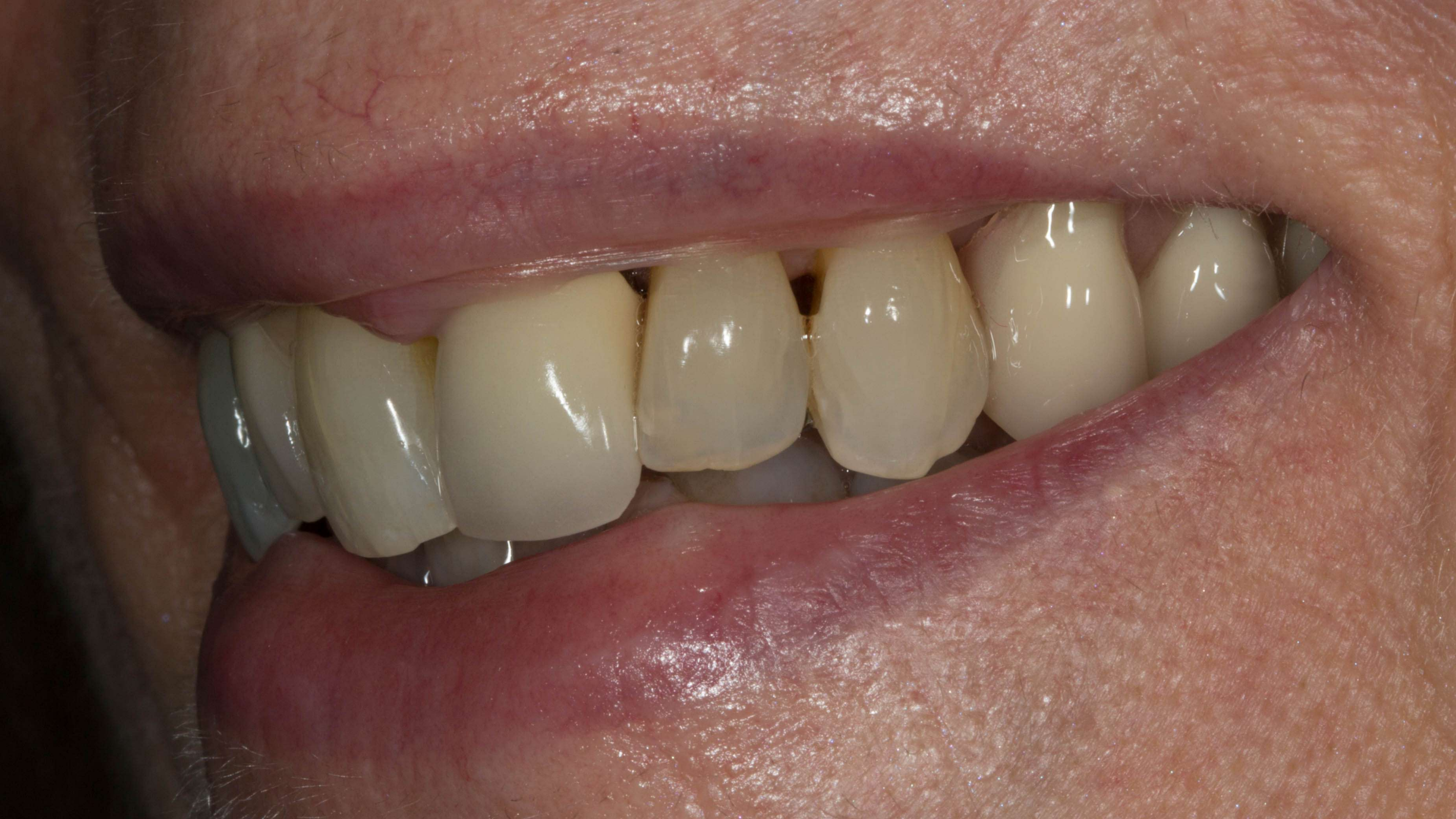













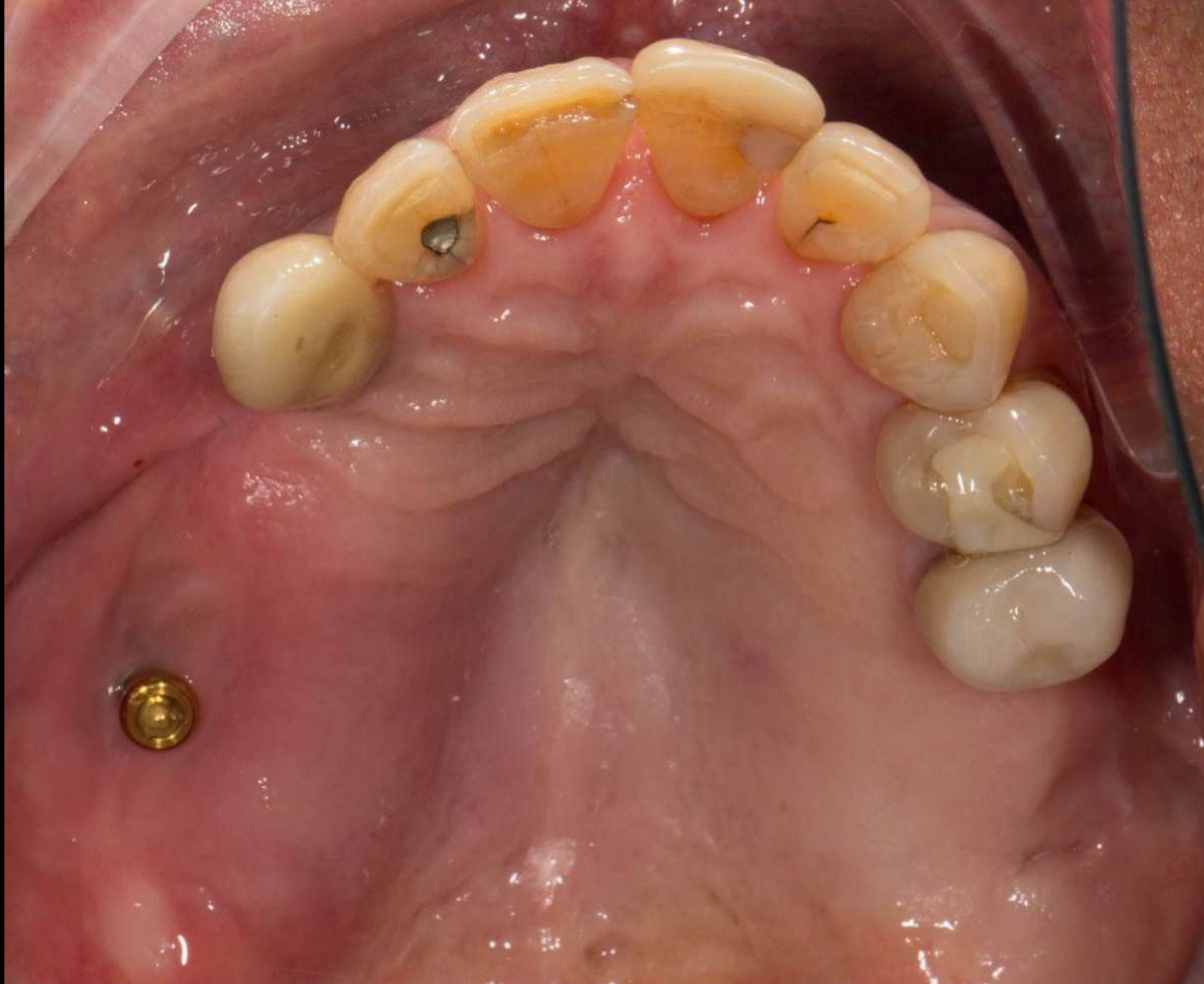Sue



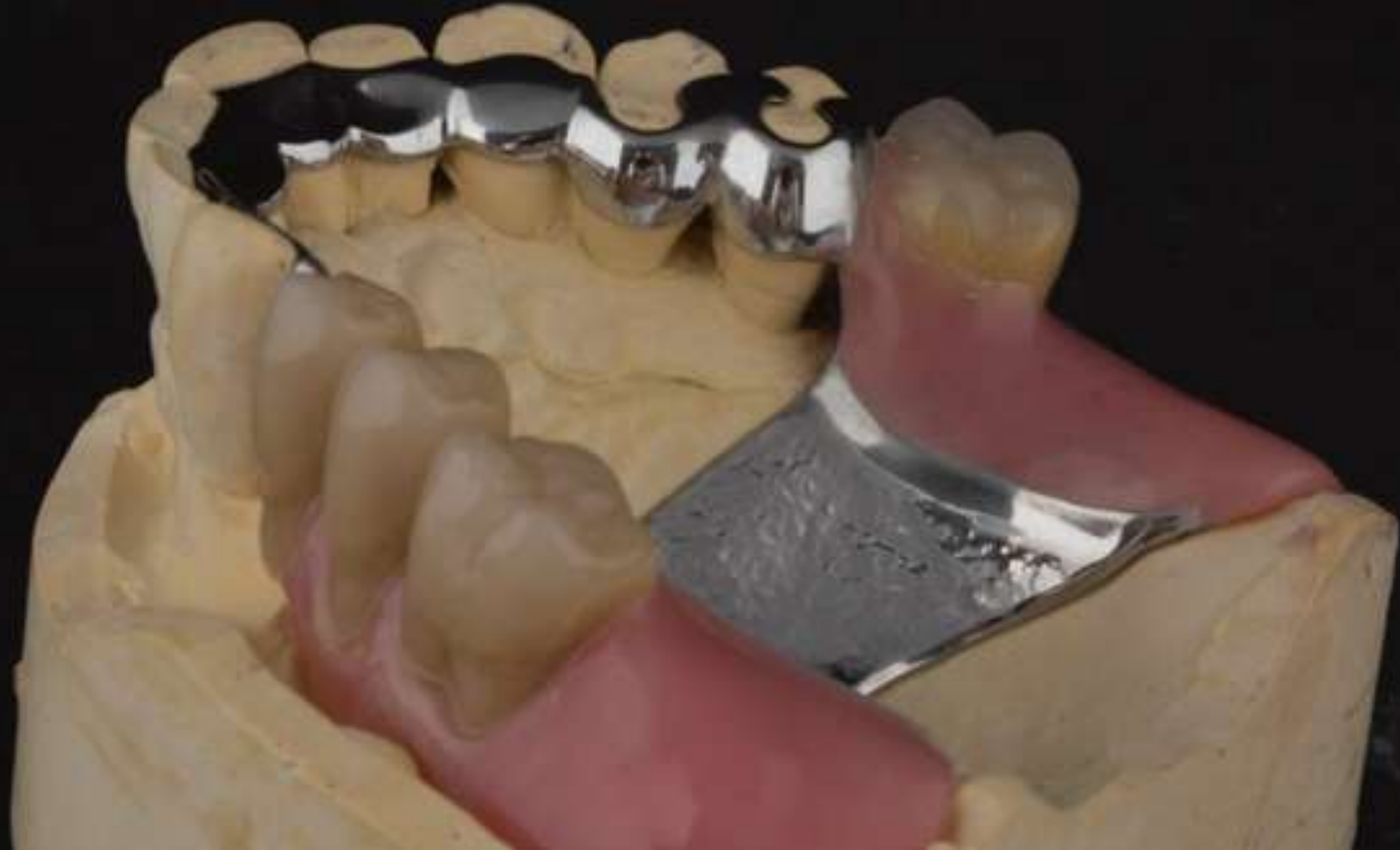Ken



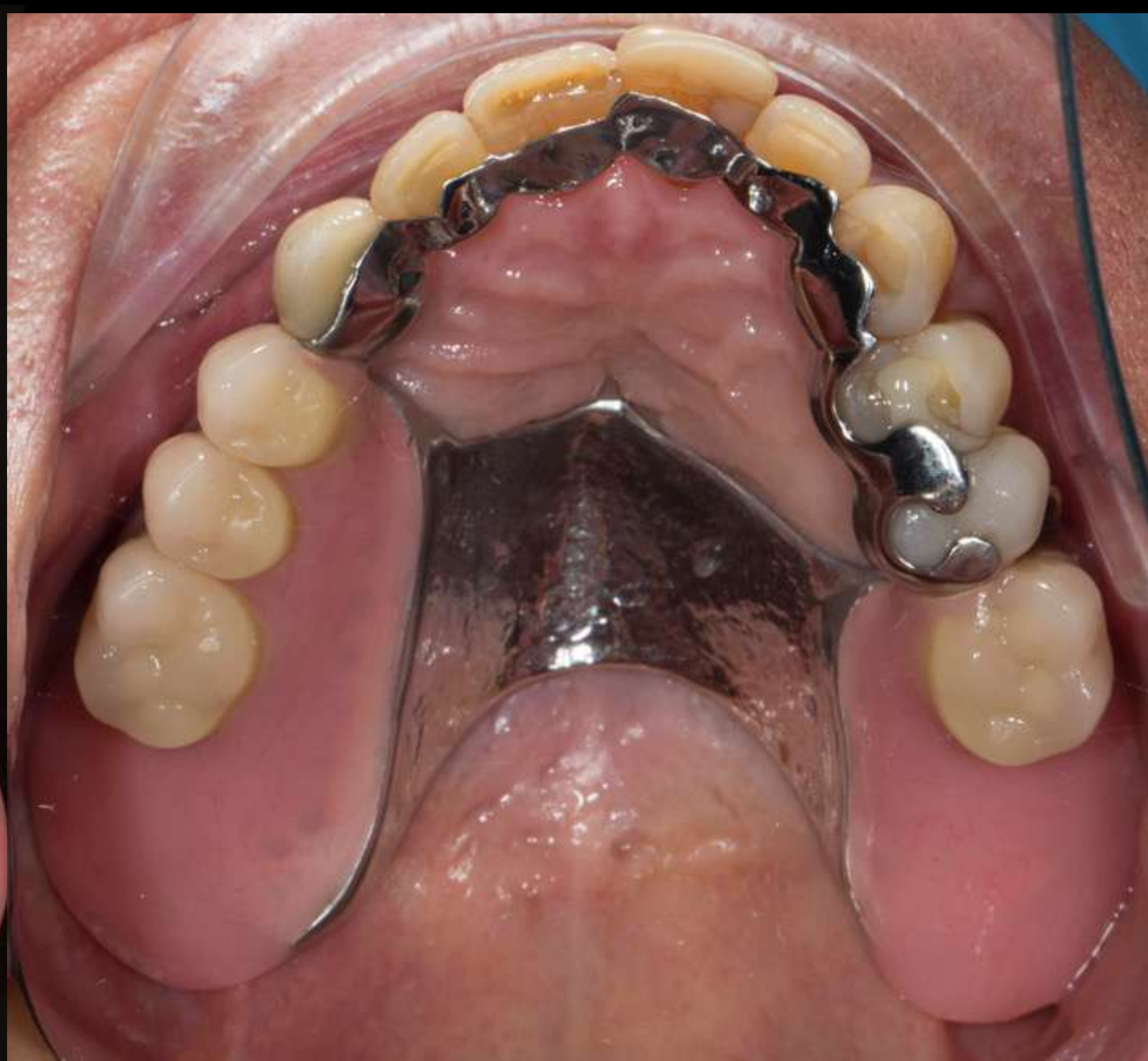
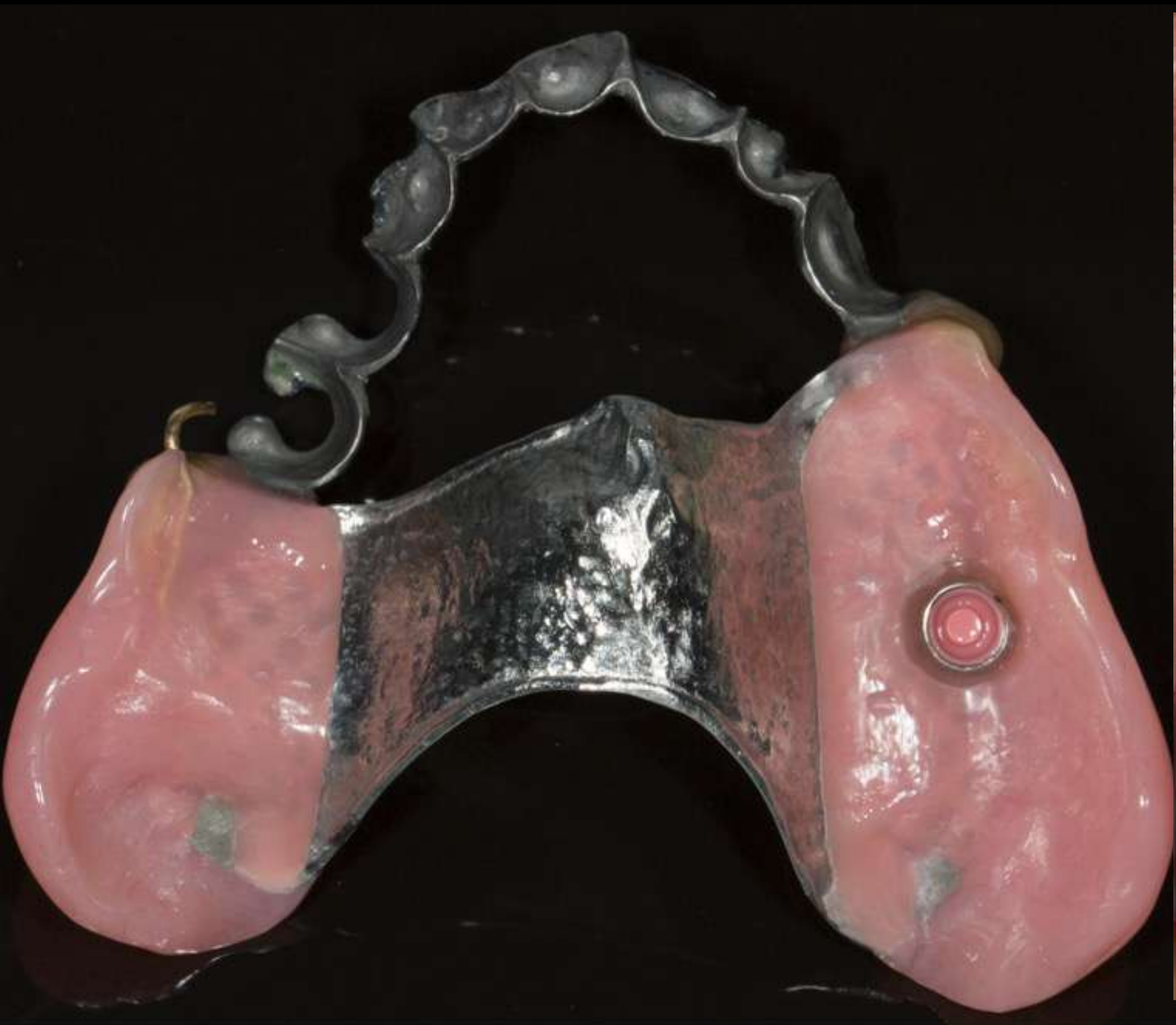




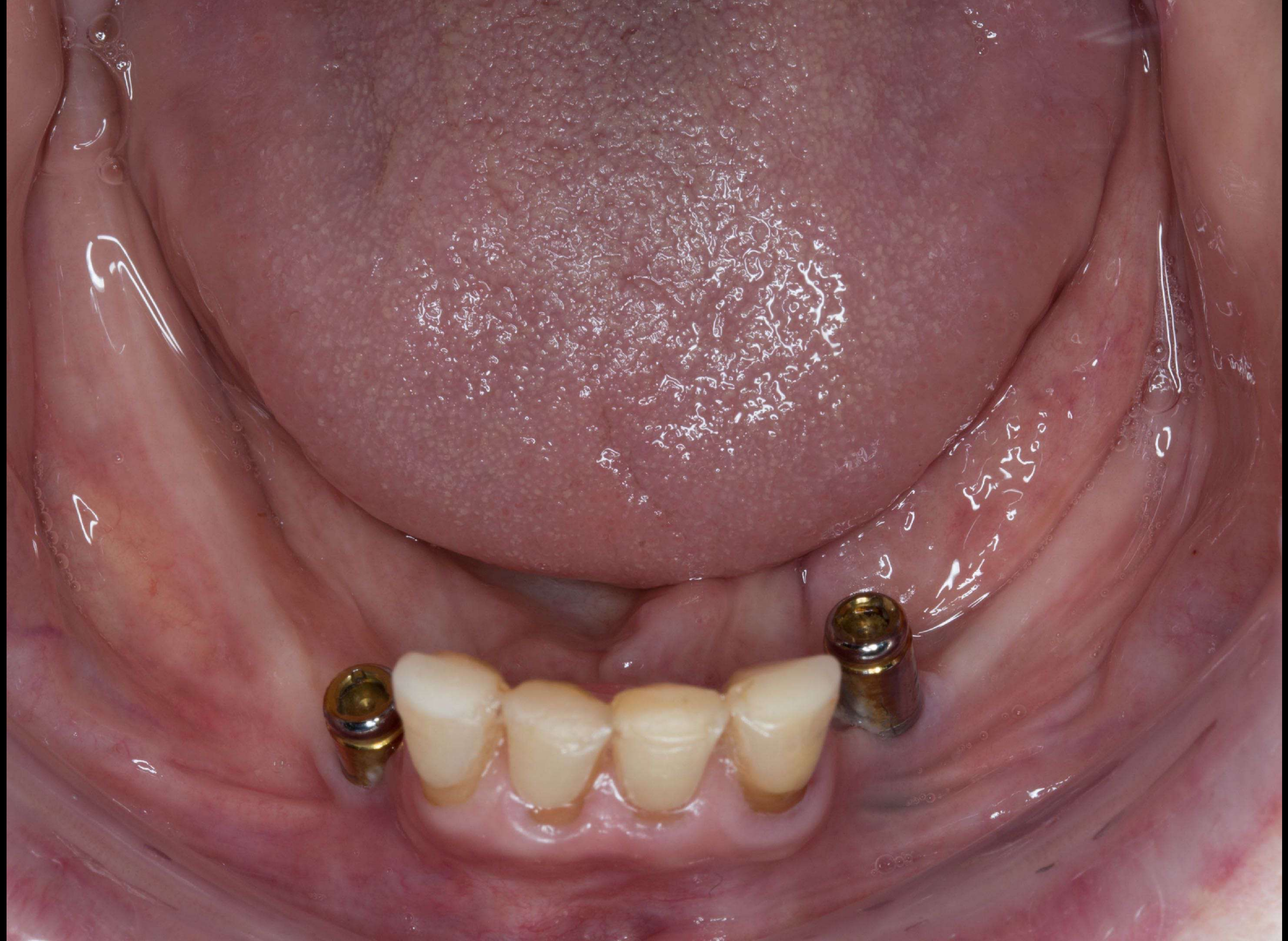

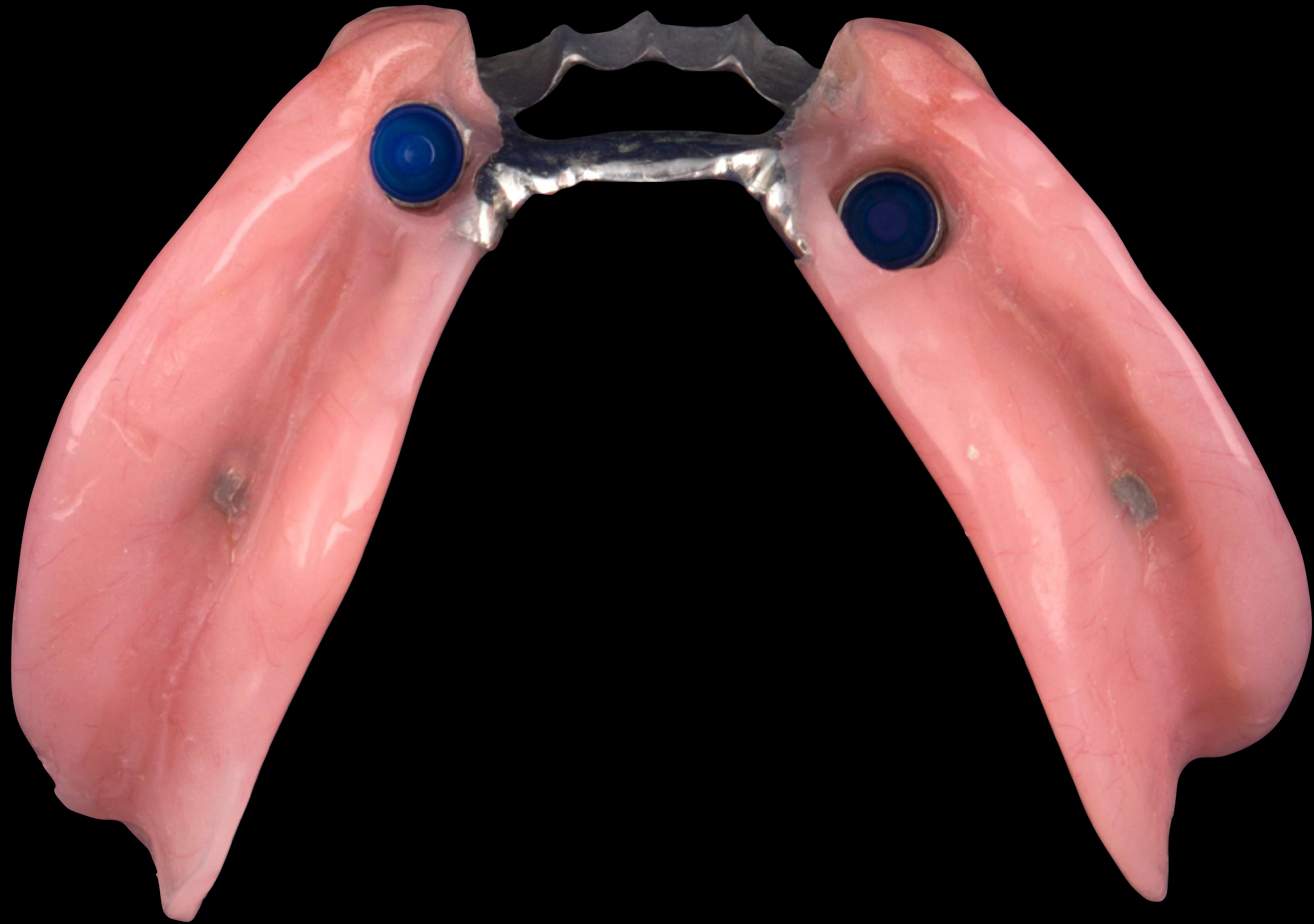







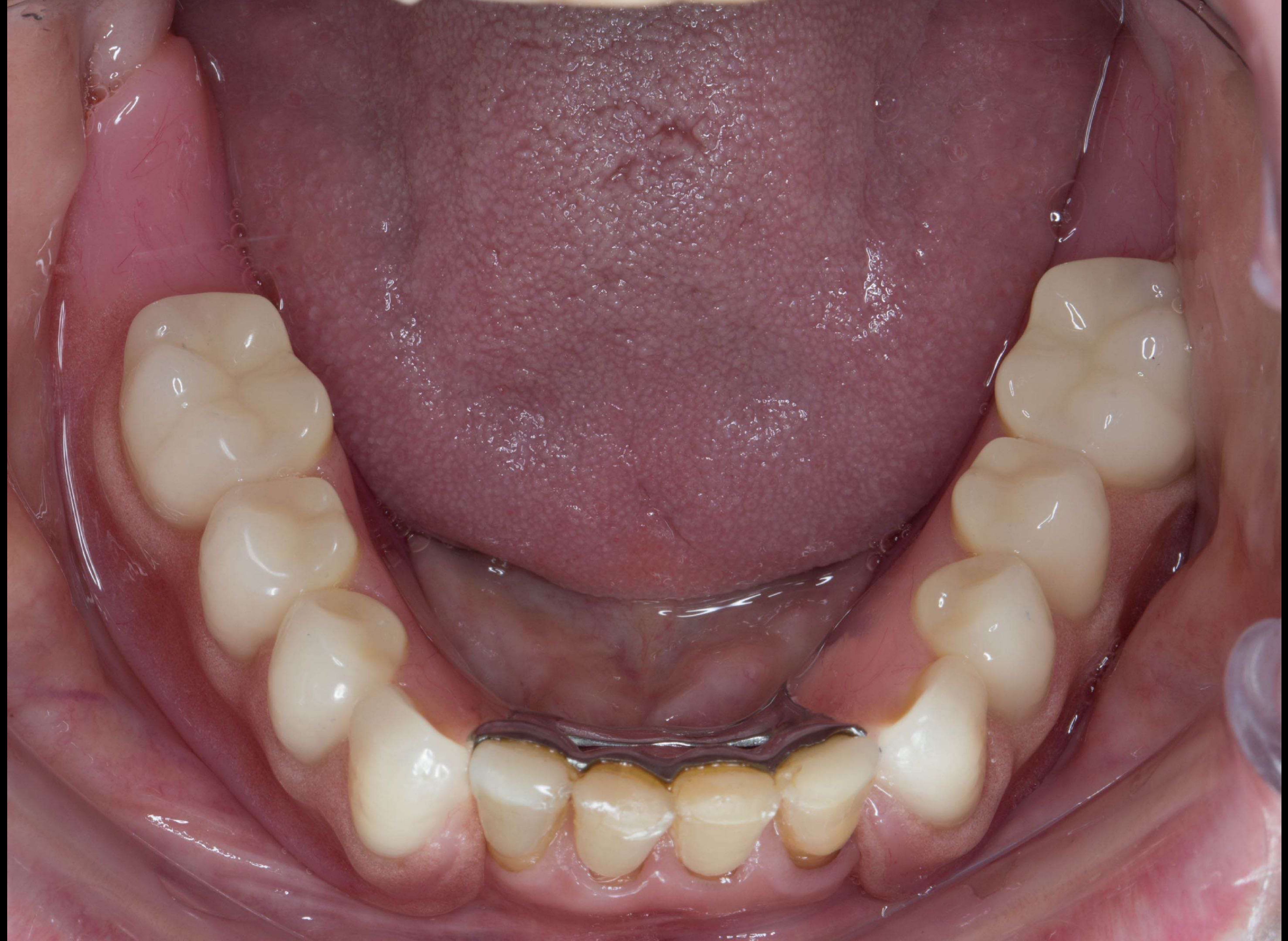










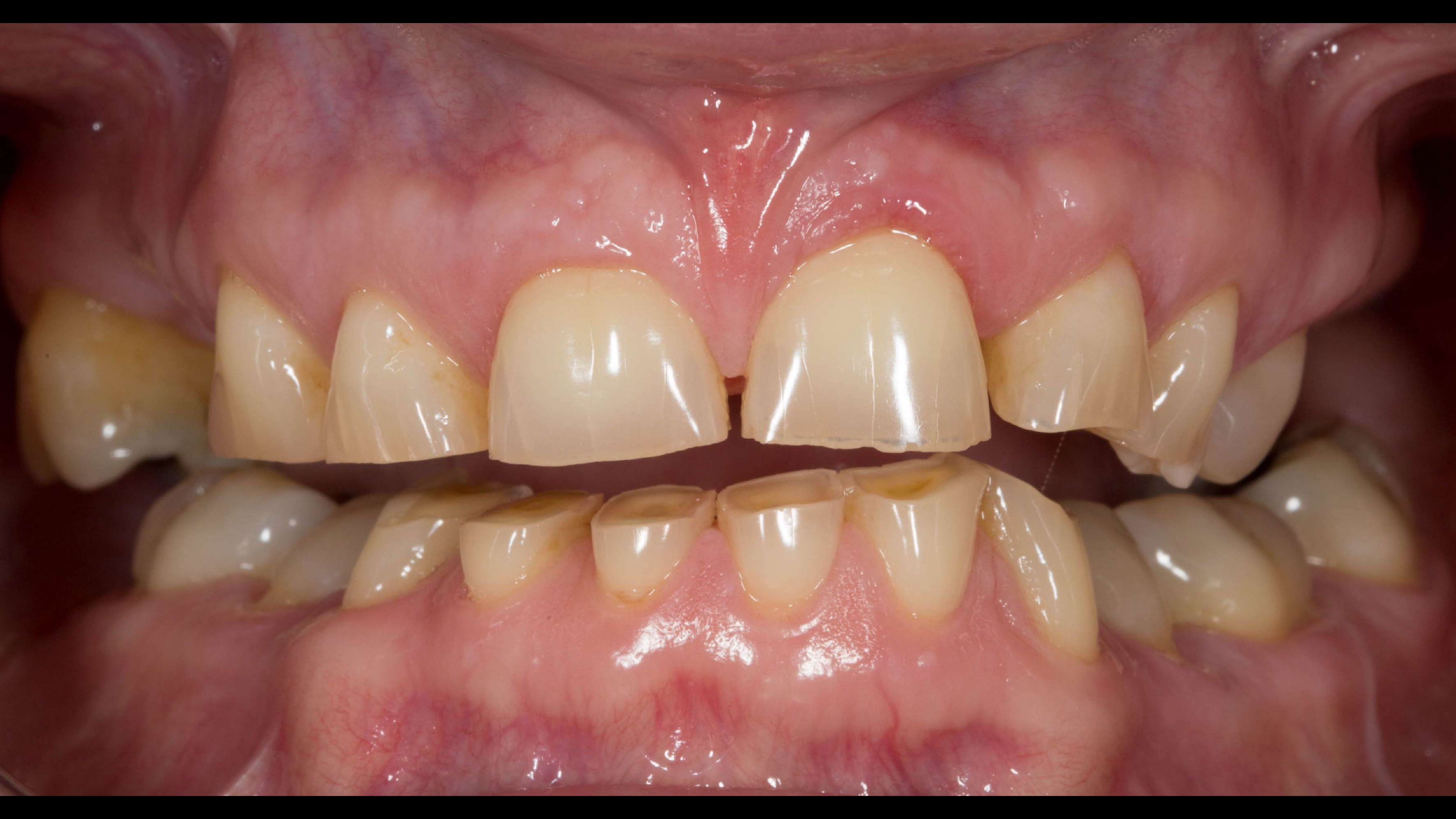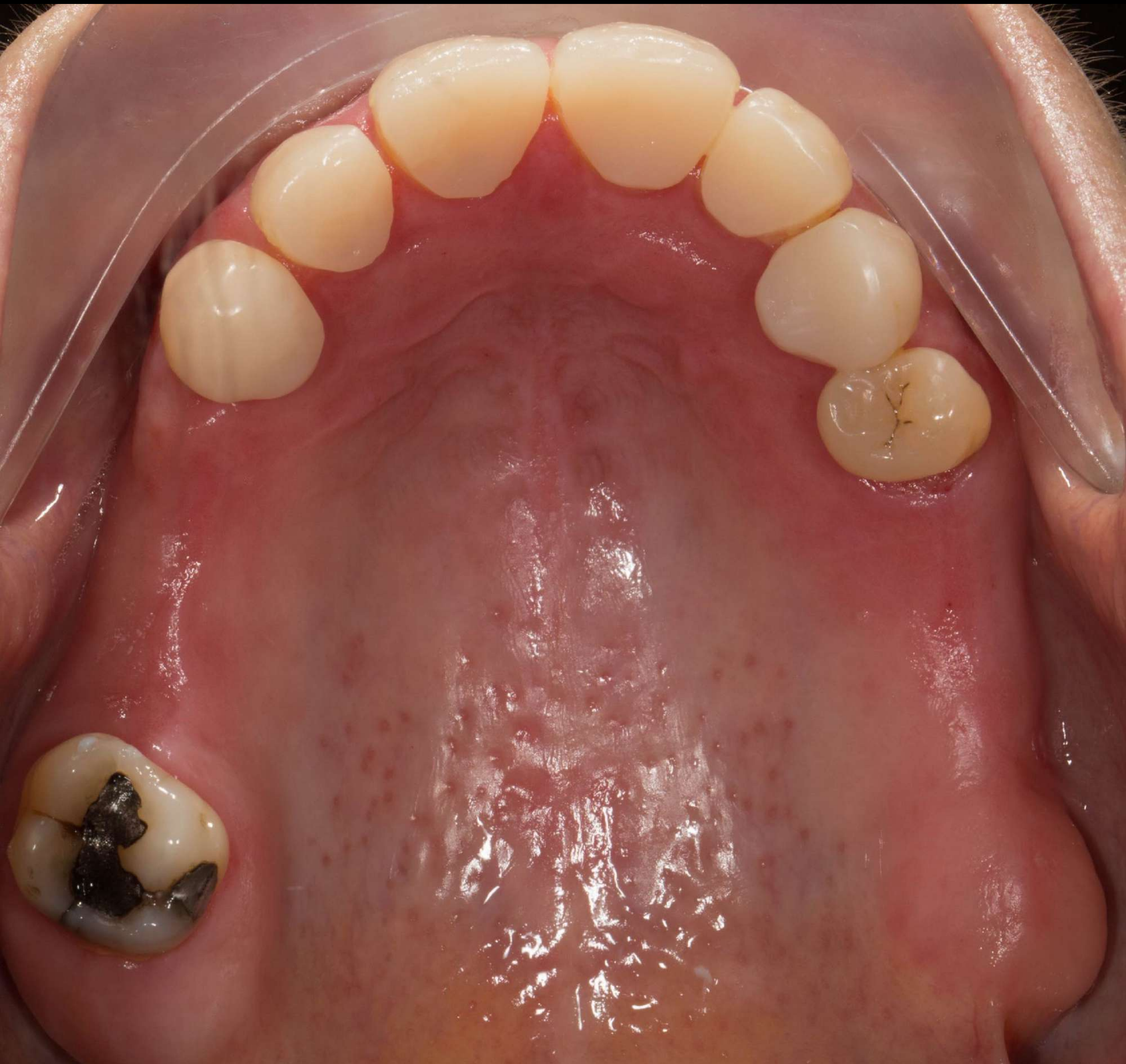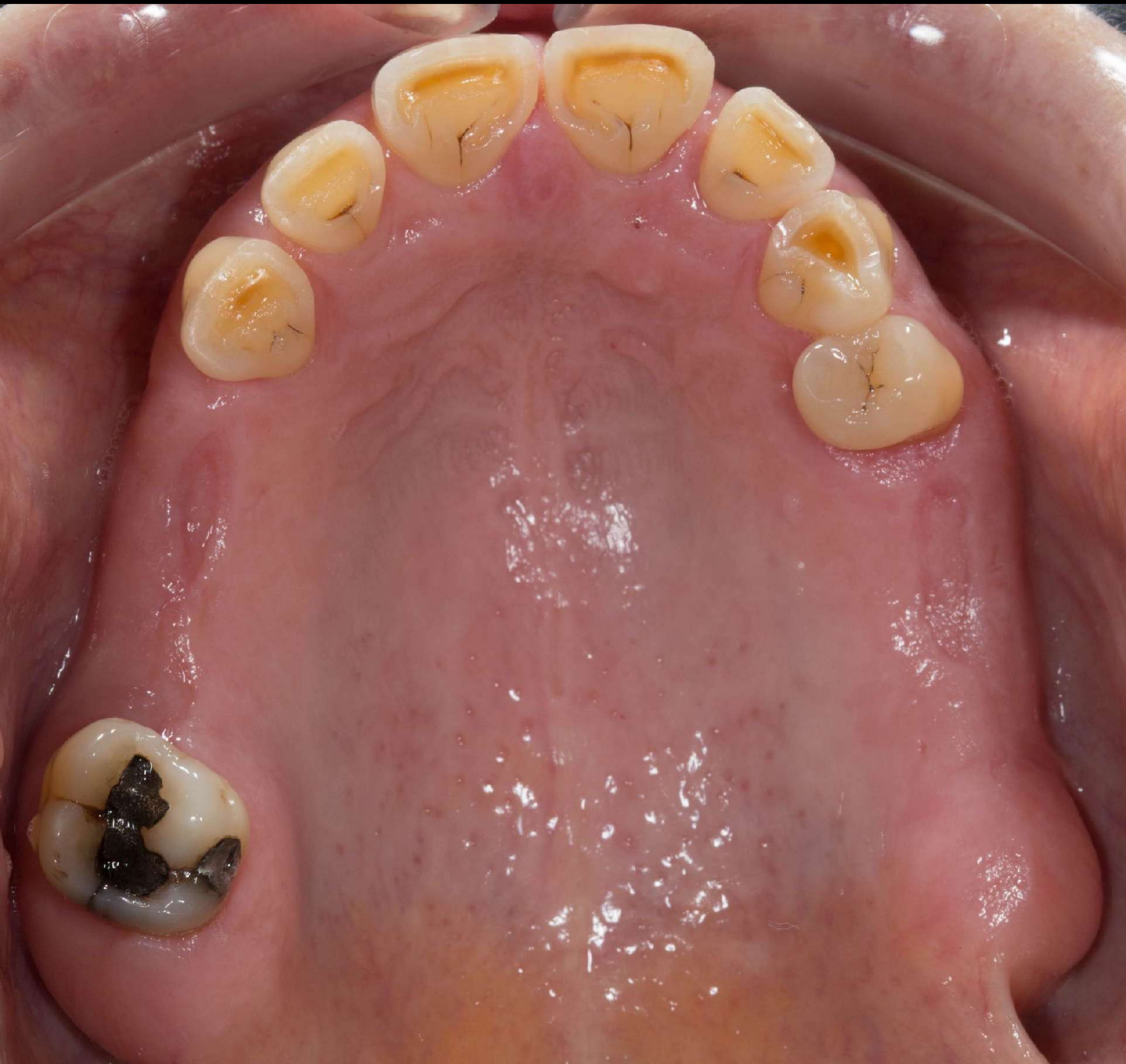# Angie the bruxist



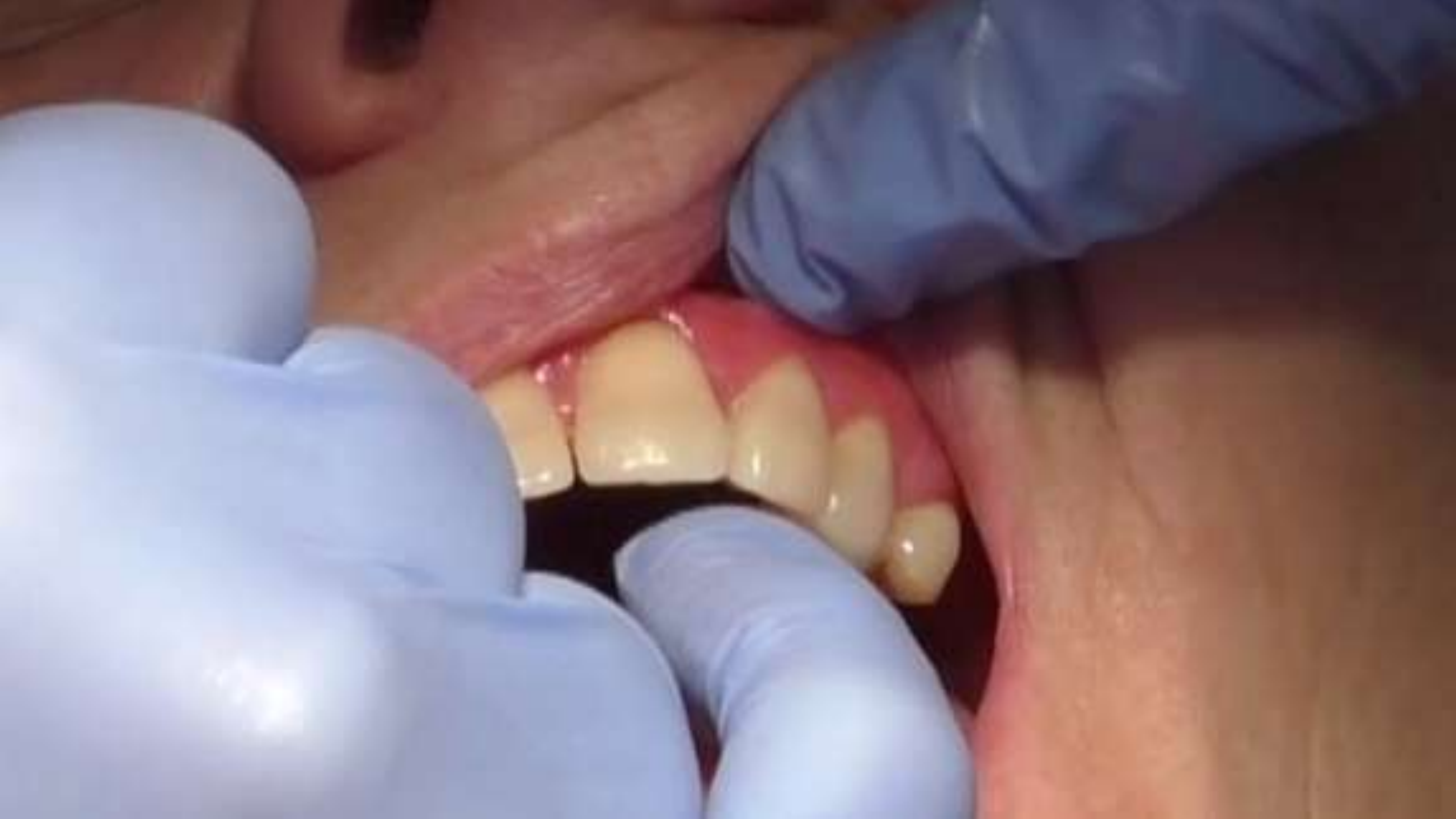




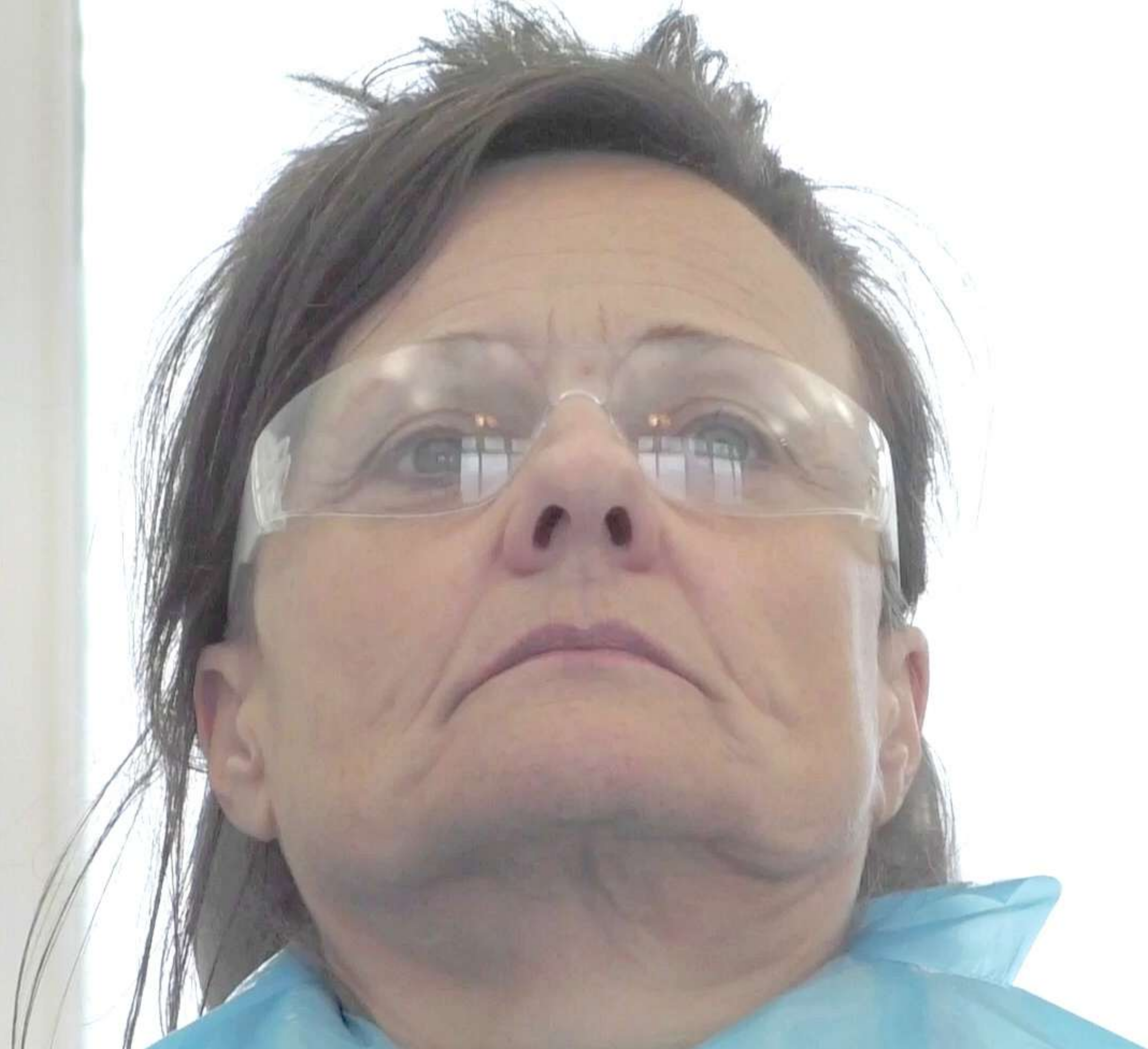






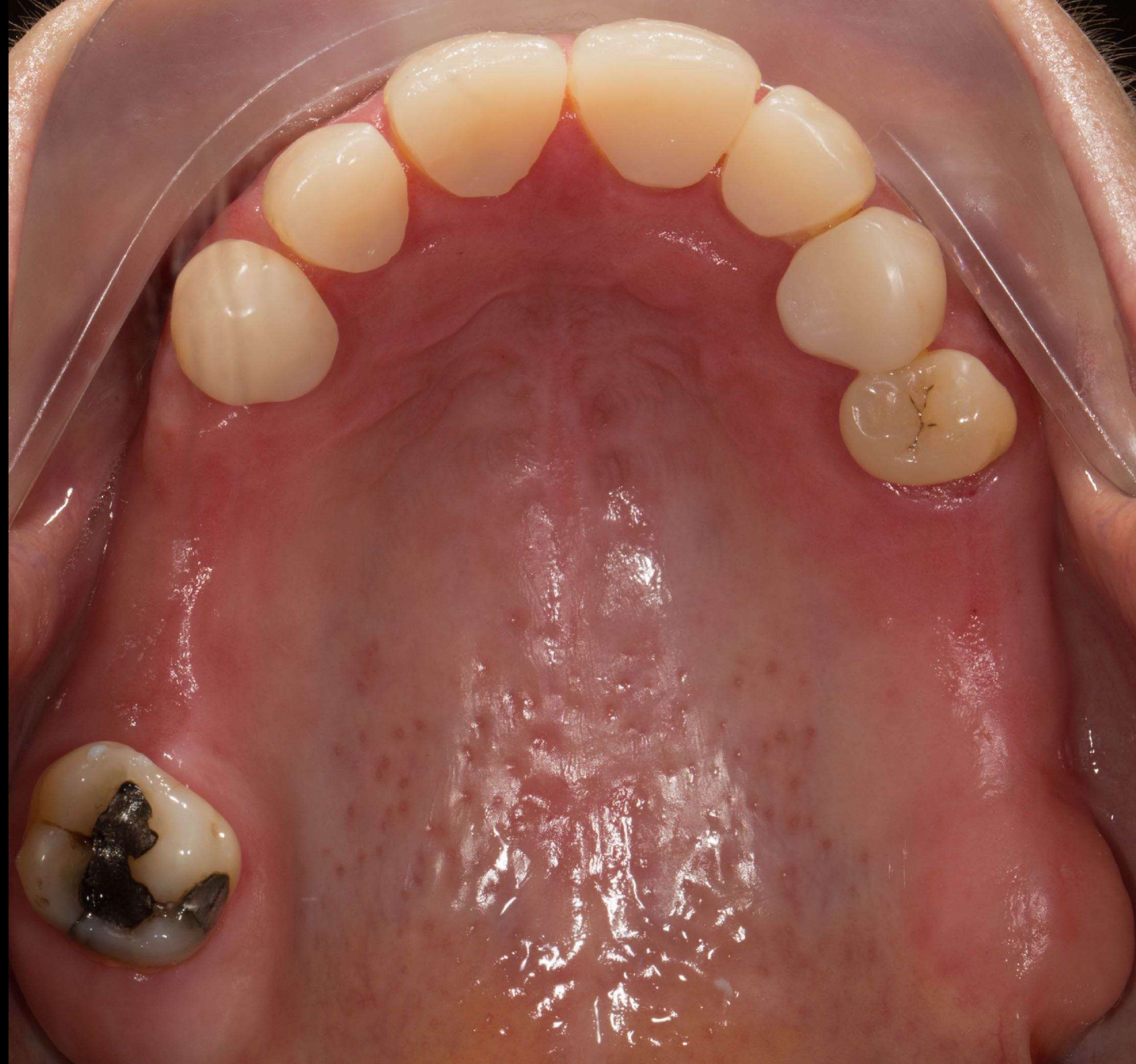




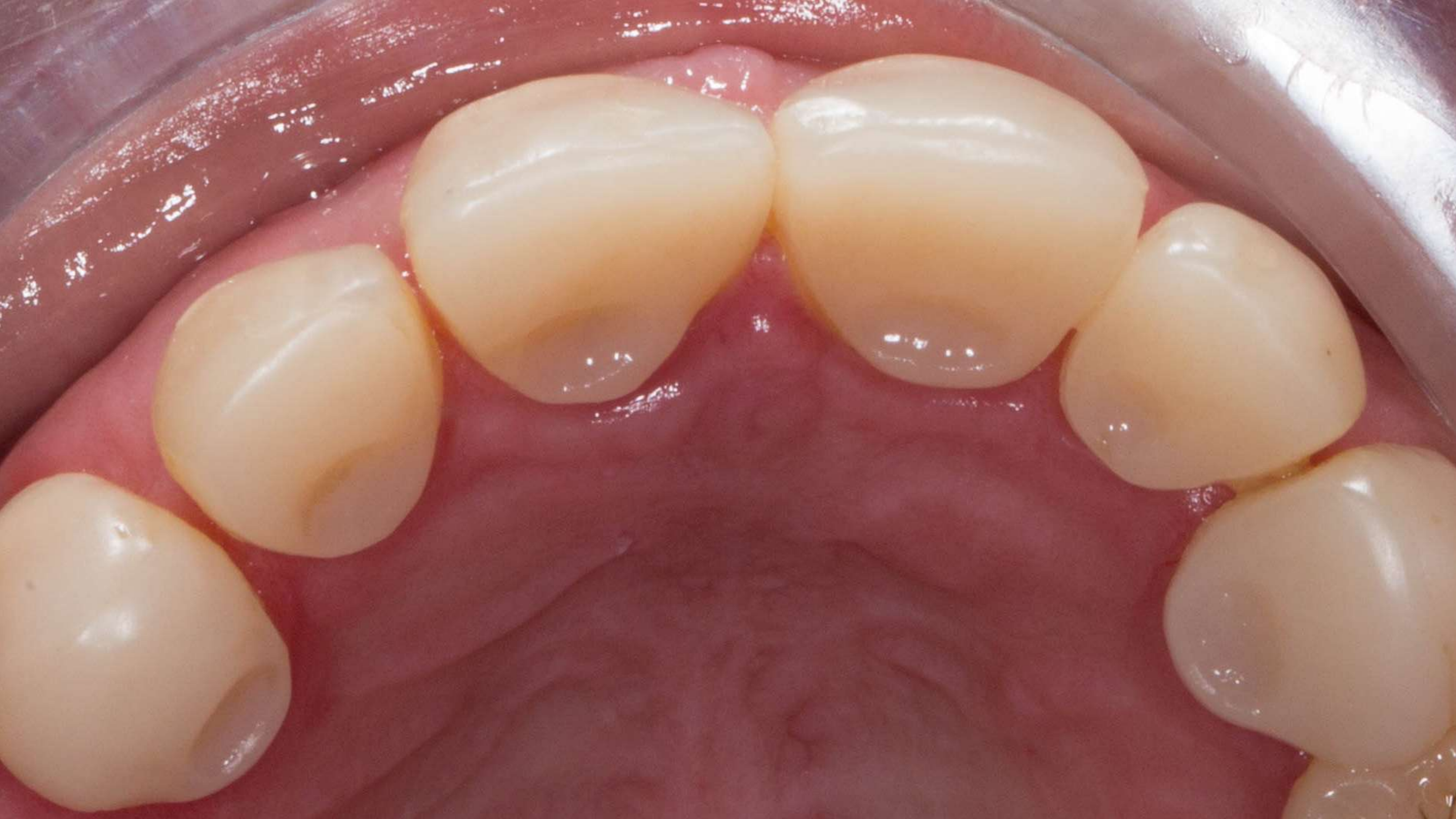
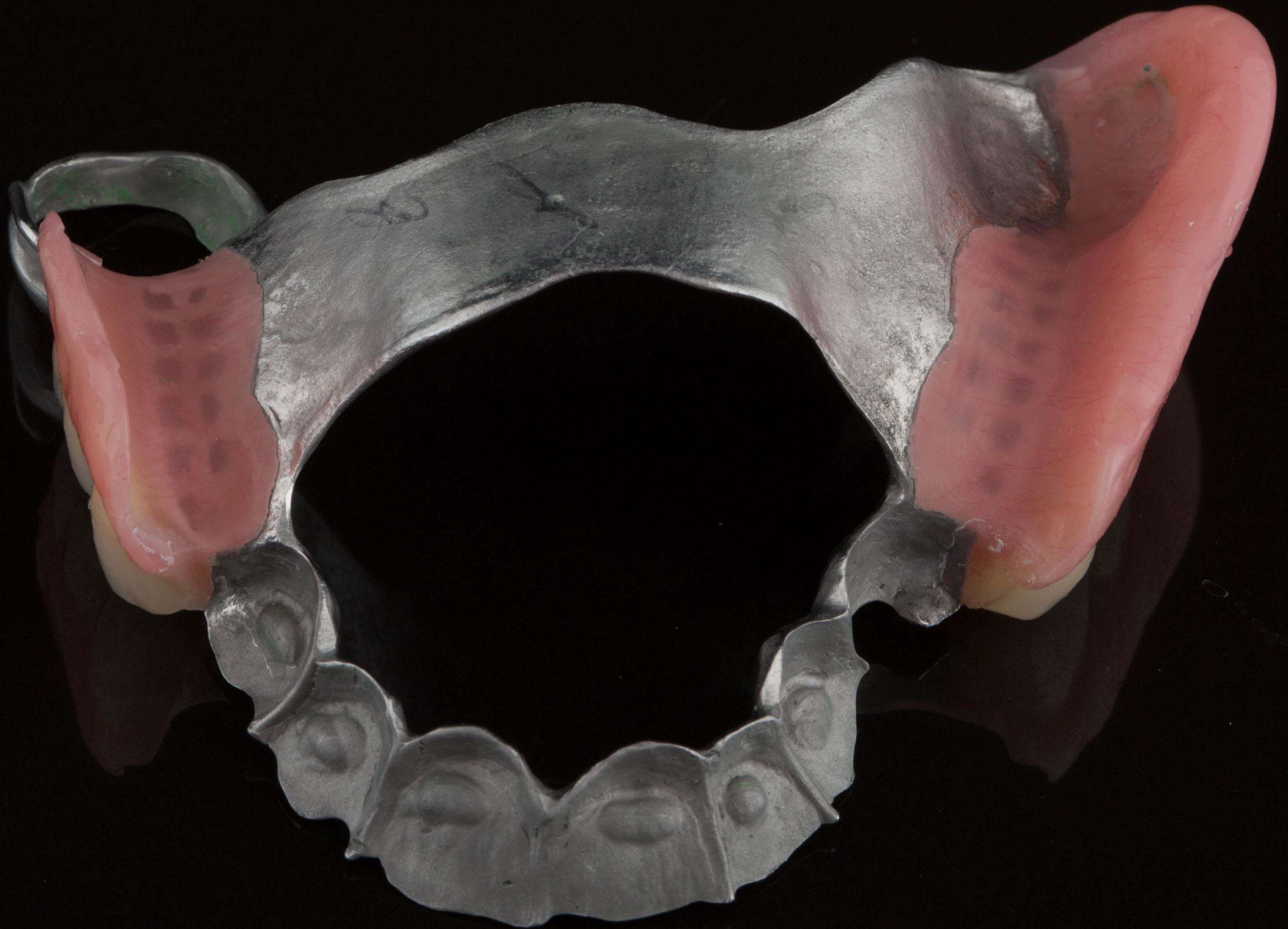Worried about  
ongoing mobility












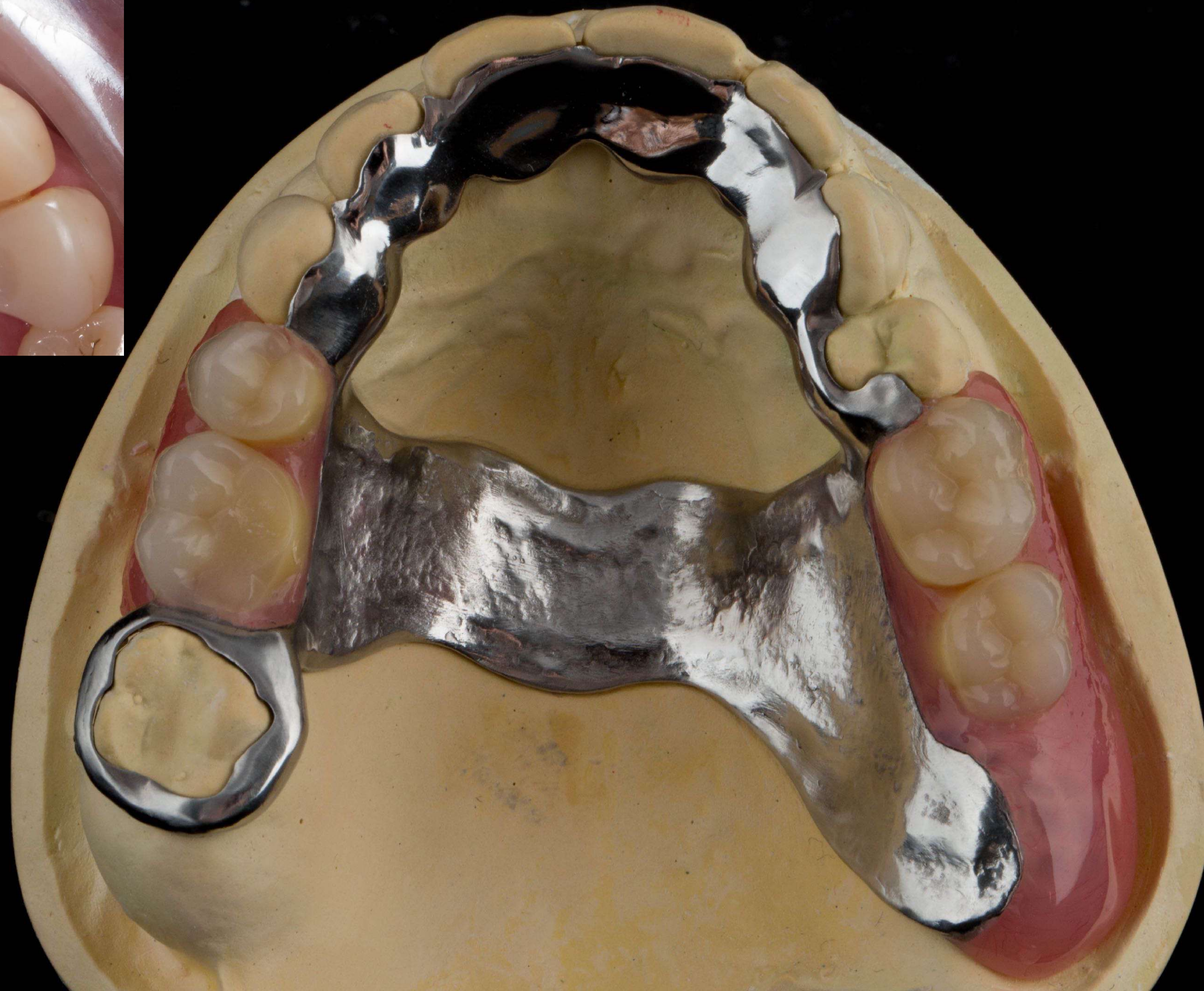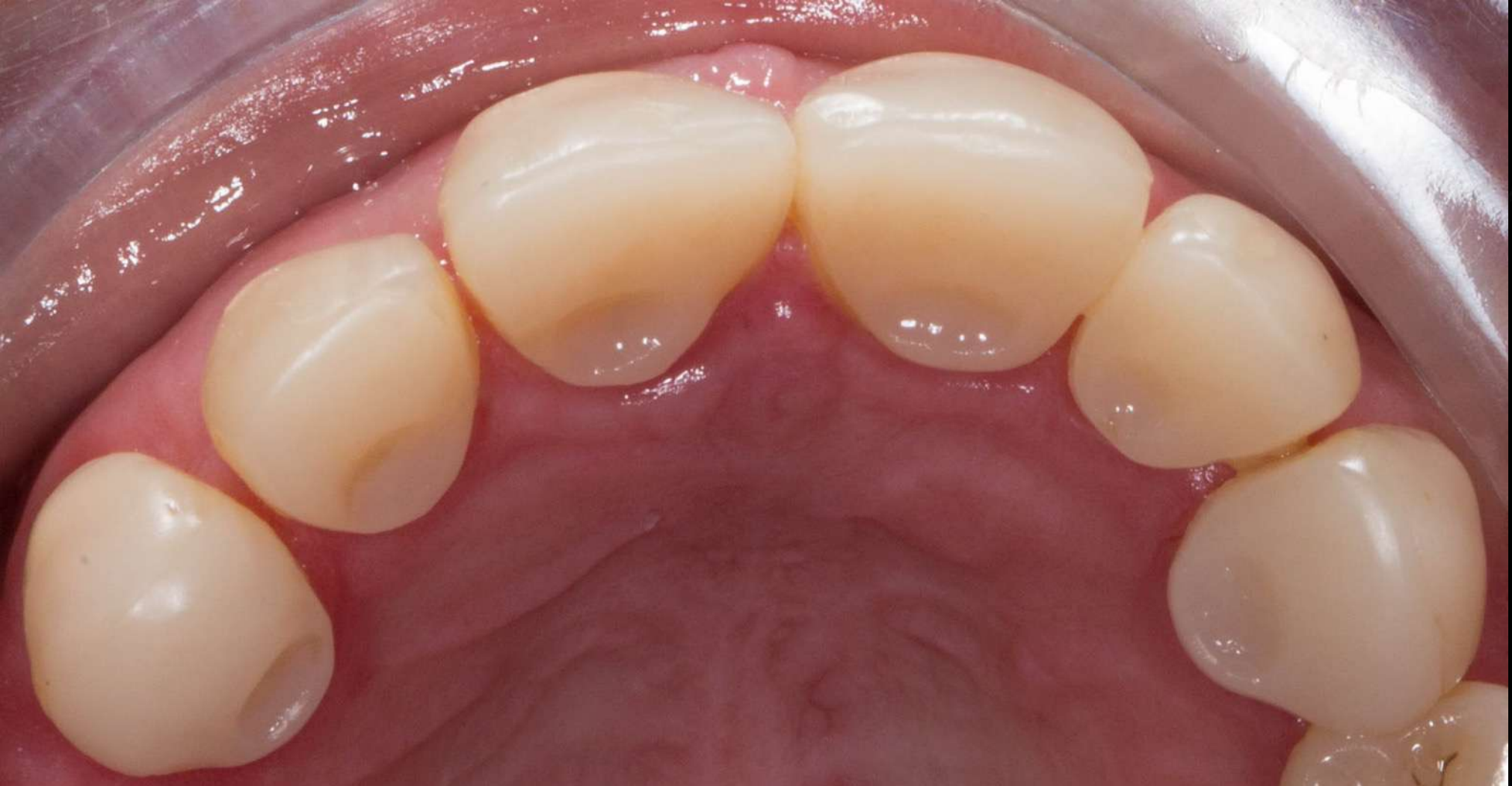




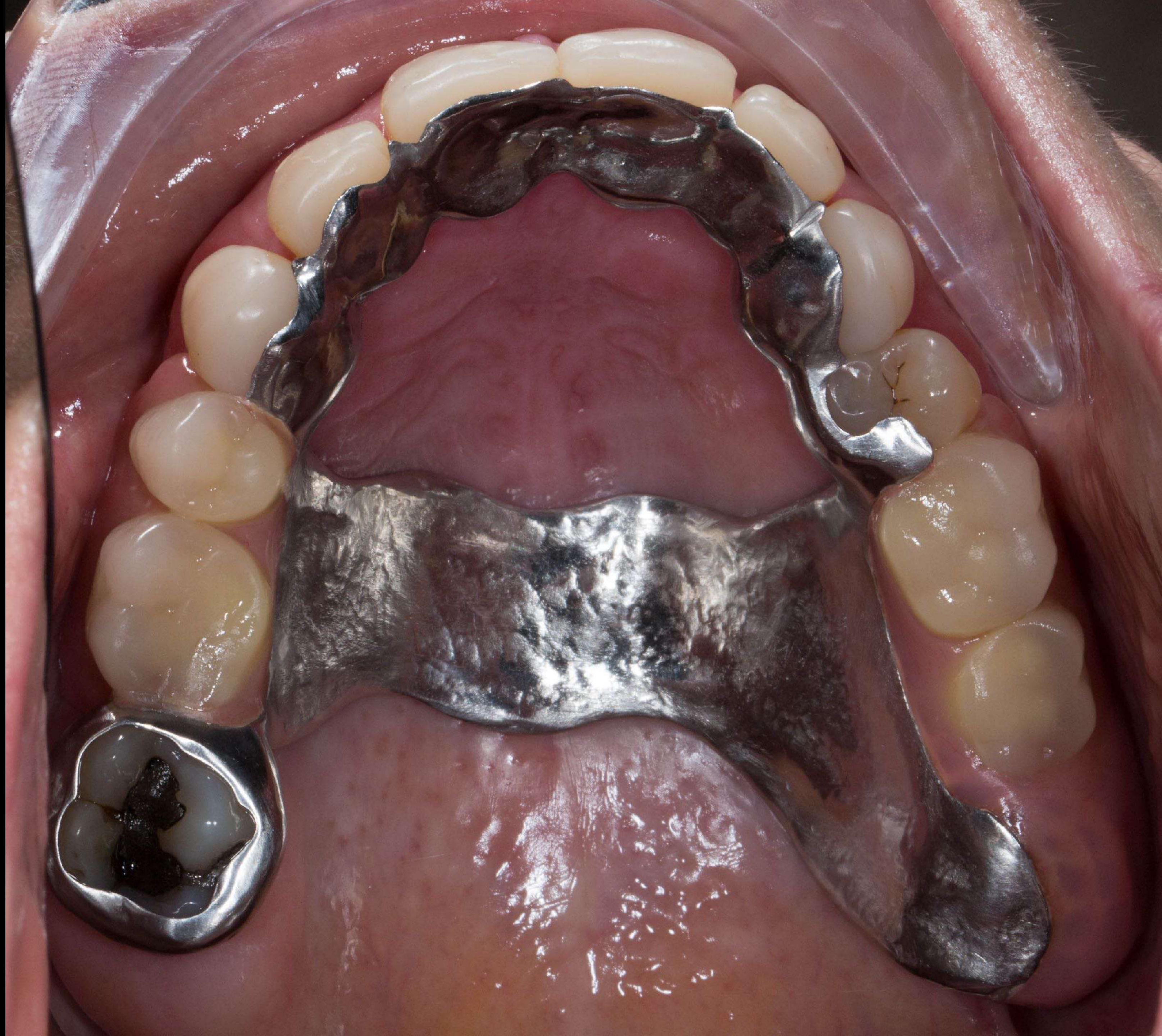








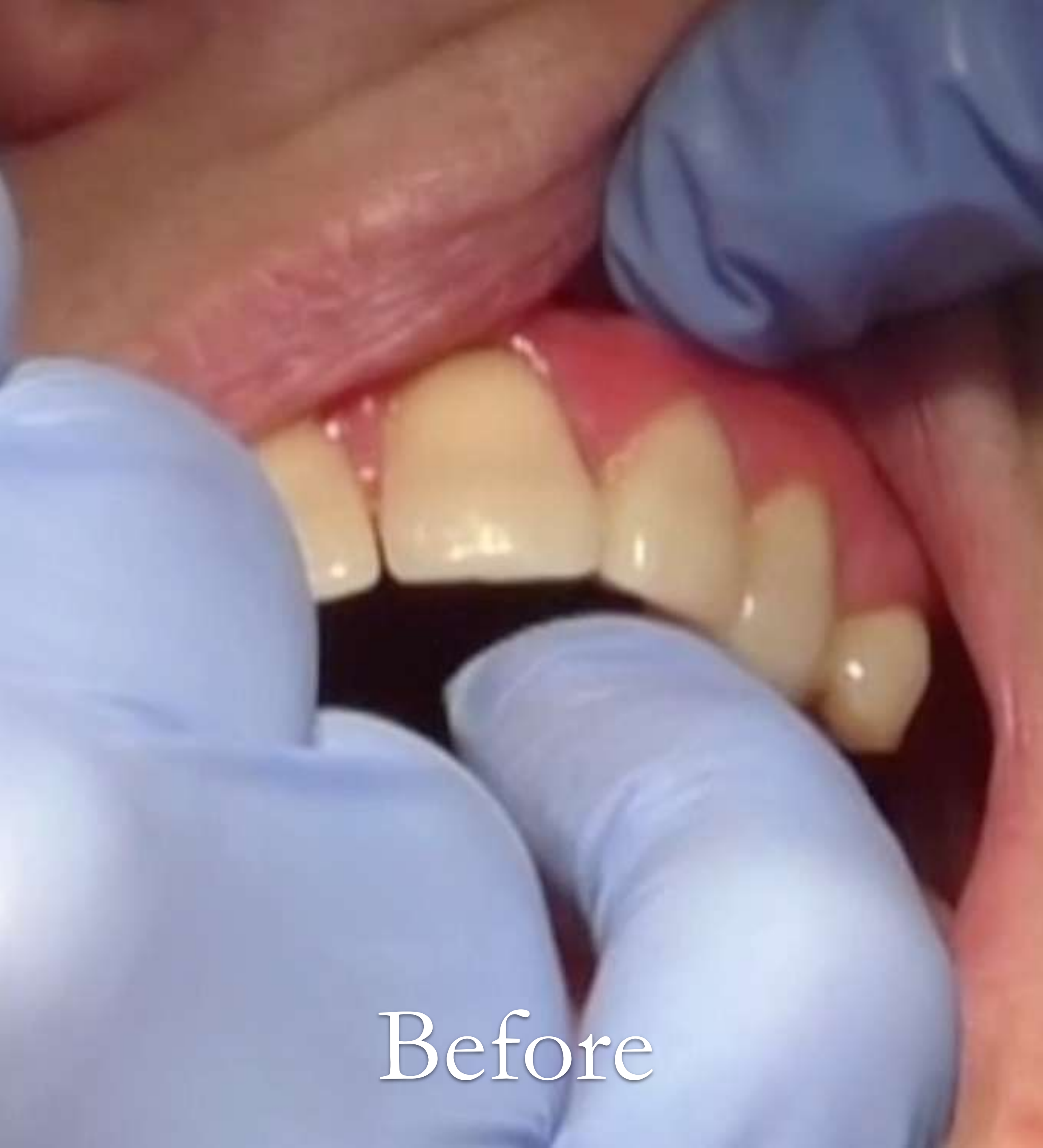




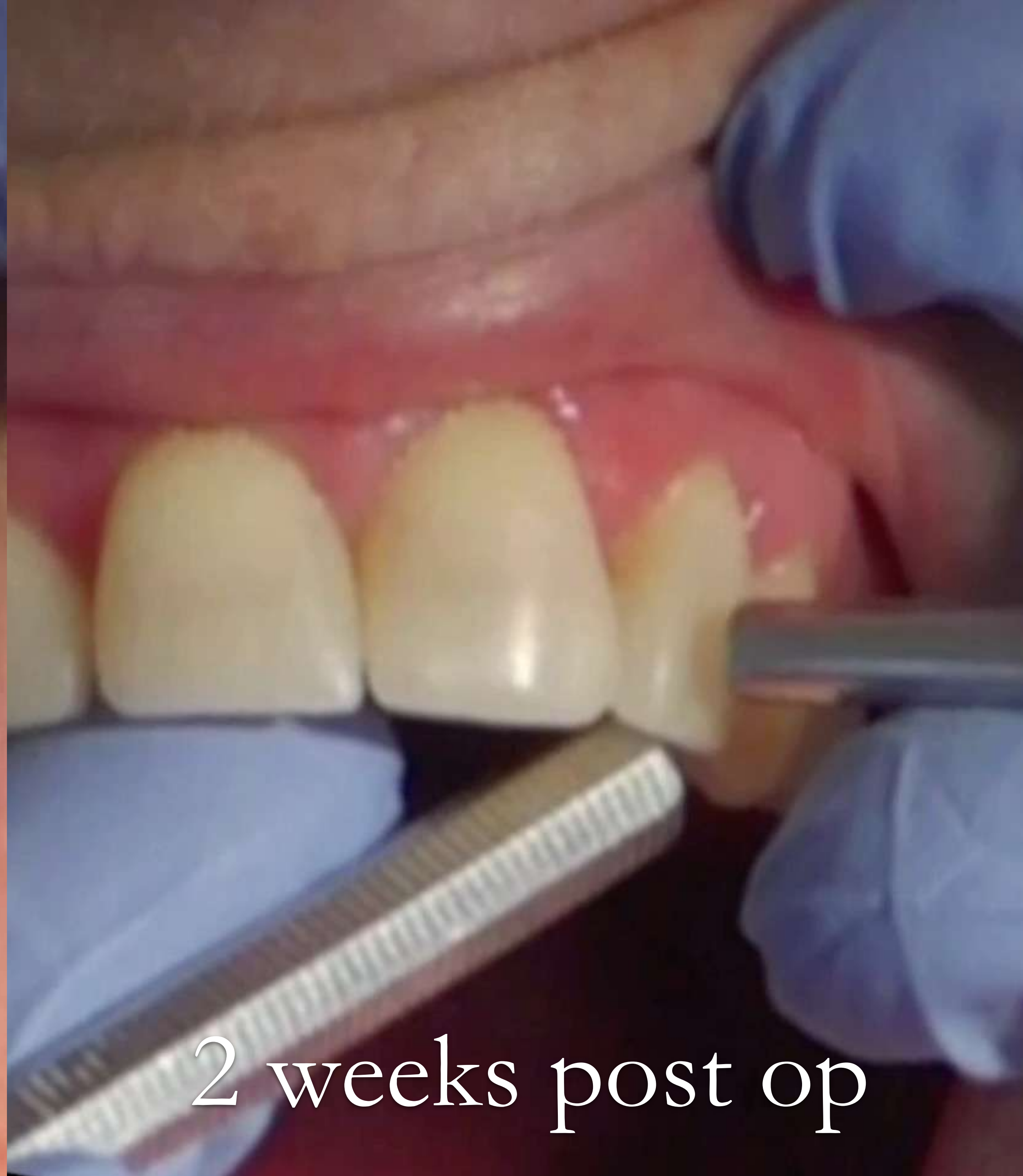





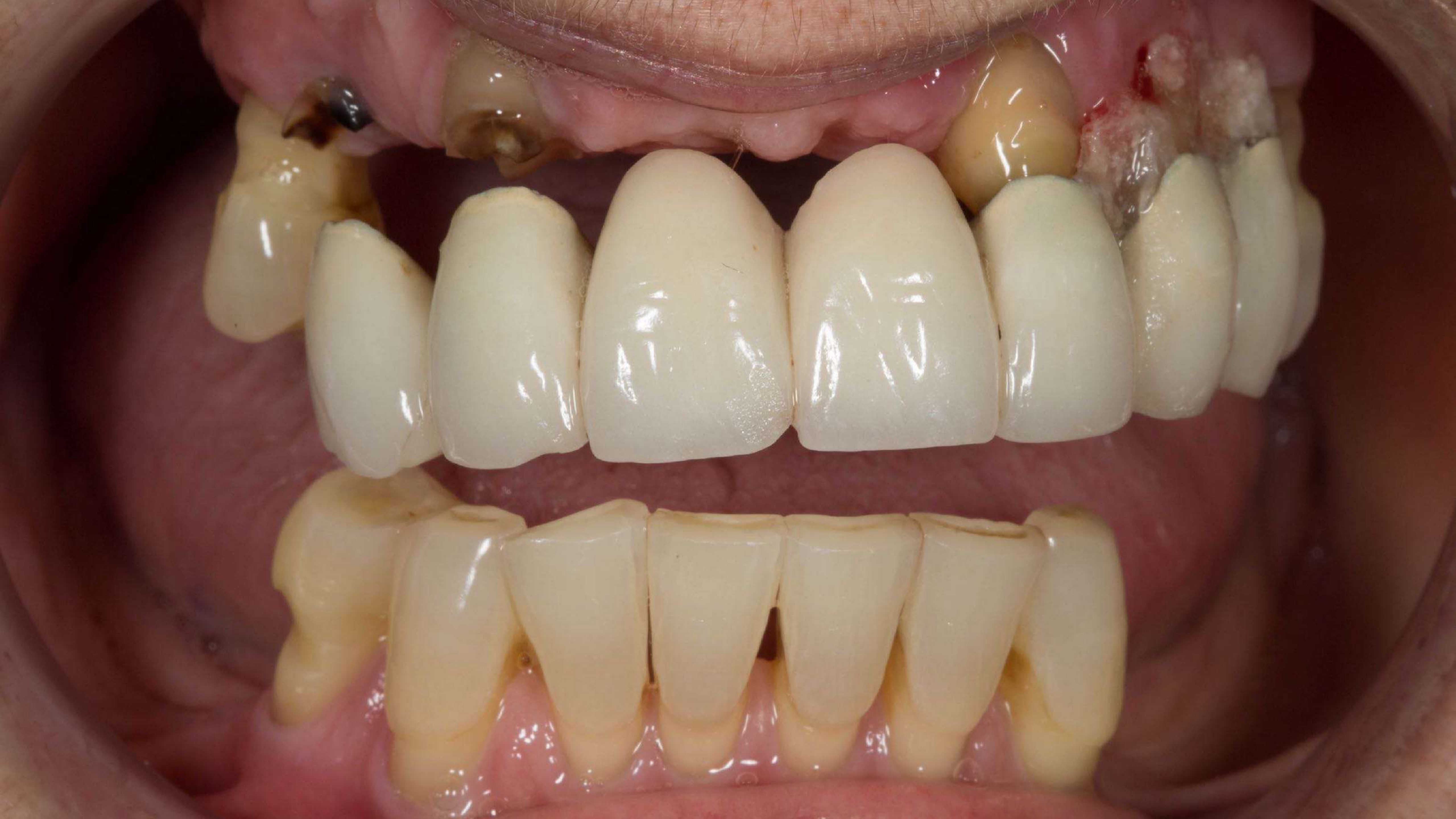Before

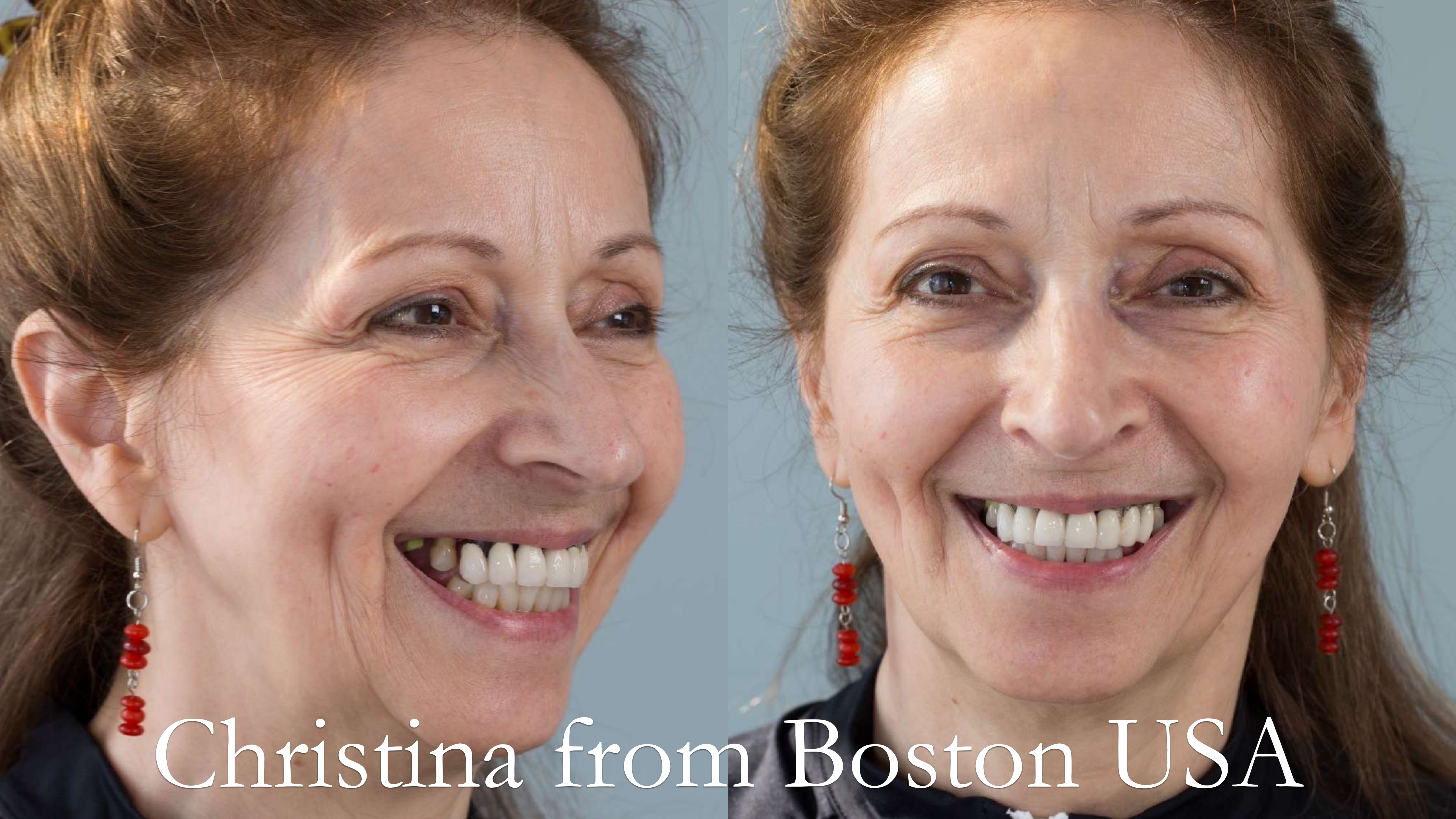

2 weeks post op










Christina from Boston USA



“I want my beautiful smile back”

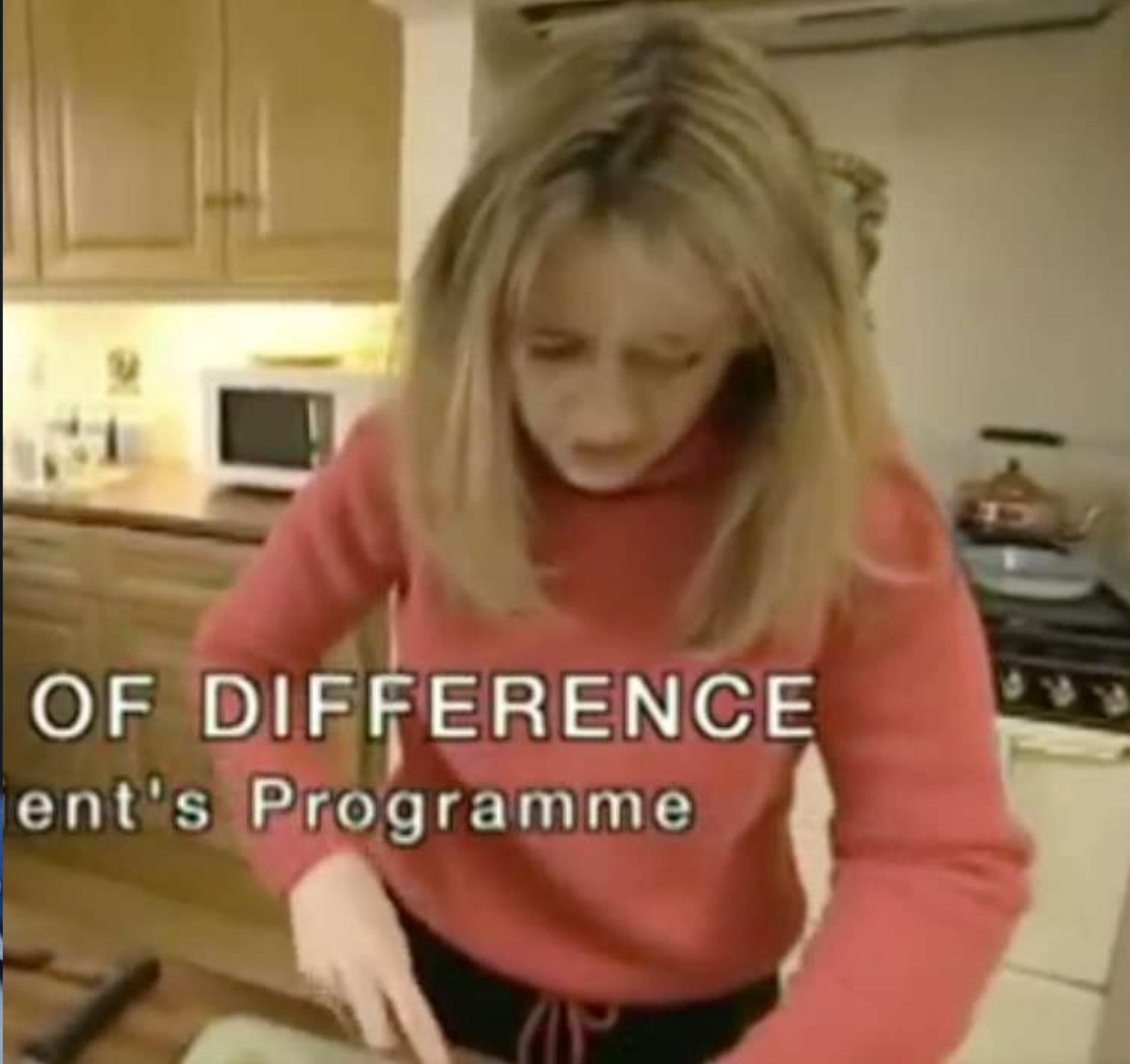



A woman with long blonde hair, wearing a red long-sleeved top, is focused on a task in a kitchen. She is leaning over a counter, possibly preparing food. In the background, another person with short grey hair, wearing a red top, is standing near a sink. The kitchen features wooden cabinets, a countertop with various items, and a window with plants. The overall atmosphere is warm and domestic.

**A WORLD OF DIFFERENCE**  
The Patient's Programme





**OF DIFFERENCE**  
ent's Programme



“You’ve got me back”

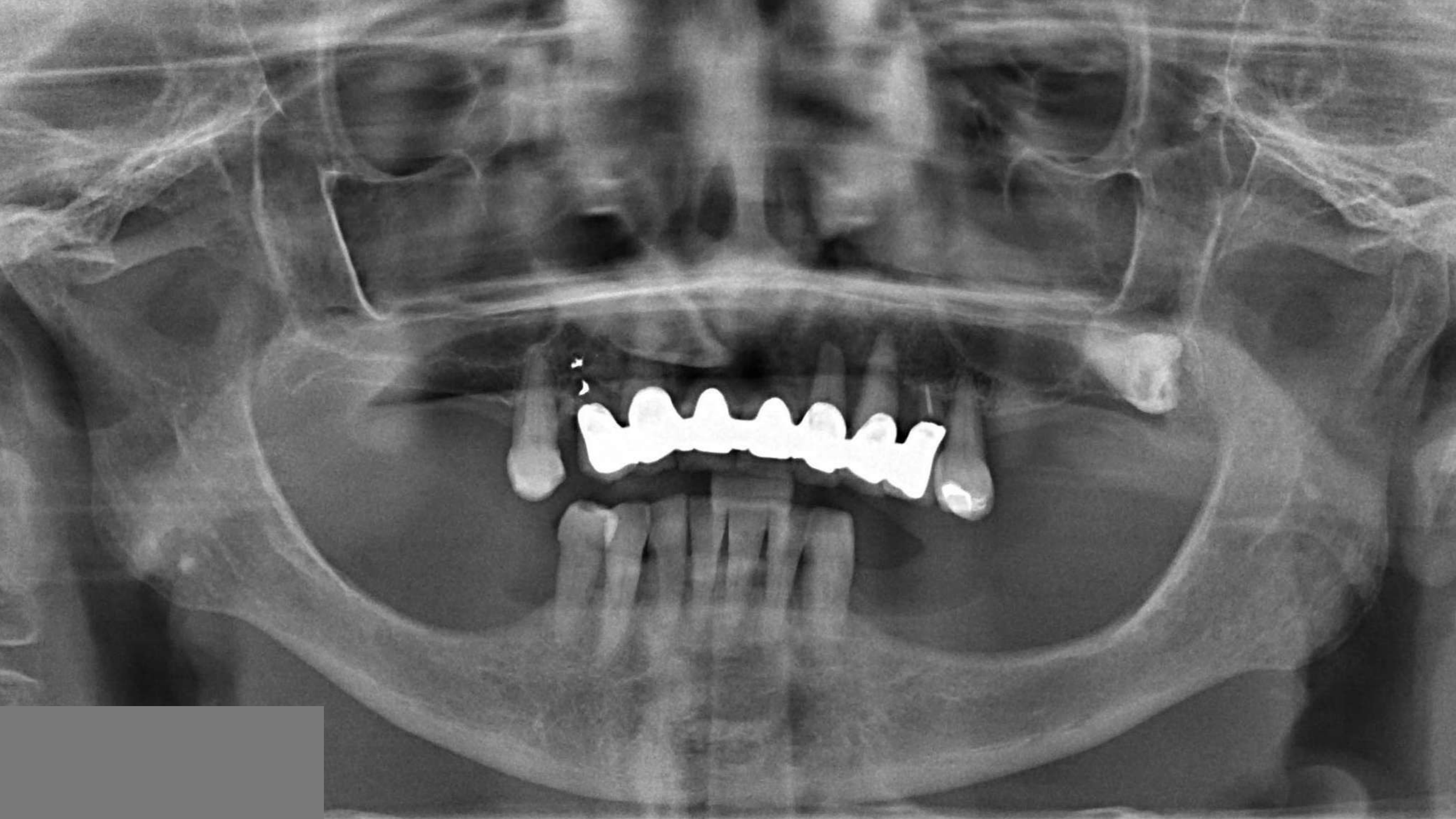
Stephanie



“I want my beautiful smile back”













# Consent letter

## Immediate C/- and -/P metal based £13K (2015)

19 January 2015  
Mrs Christina Bay  
Boston  
Massachusetts  
USA

Garstang Dental  
Referral Practice  
Ward House  
72A Victoria Road  
Garsington  
Oxford  
OX4 2DQ  
T: 01851 483007  
E: info@garstang.co.uk  
W: www.garstang.co.uk

Dear Christina

Thank you very much indeed for asking me to provide the following proposal:  
"My front conventional, I would be great if you give me a proposal and your most comprehensive plan that I could send to my dentist for his approval of my dental work, with a view to the metal frame lower partial."

I have been discussing your case with Dr John Bedford and Mr Robert Garstang my dental technician in detail.

**Medical History**  
None with relevance to treatment.

**Diagnosis from the X-ray pictures you have supplied**  
The remaining upper teeth, which support the bridge, are not variable. In addition, the upper left second molar has very little bone support and is not suitable in the long term. These teeth require replacement with an immediate denture in the first instance and a definitive denture at a later date (likely 12 months later only when your gums have settled).

2. I observe that the upper right first molar has a moderate degree of bone loss. Dr Bedford and I believe this is worth assessing, regarding its support and whether an upper complete denture, this tooth will require root treatment, if it is in good enough condition. Once I have examined you, we can coordinate with a specialist in Birmingham and discuss Dr Wasse Farnes team strategy to provide this for Garstang in the UK, during phase 1 of your treatment.

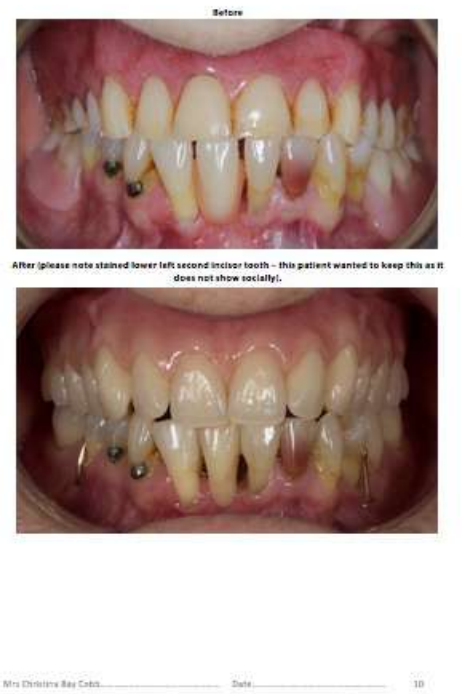3. The upper left wisdom tooth appears unerupted on the X-ray pictures supplied (I believe that this is best confirmed).

4. As John Bedford said, he requires an X-ray. The good news is that, with good home oral hygiene, brushing, and occasionally mouthwash, daily cleaning of your teeth, your remaining lower teeth should remain useful in your mouth till the end of your days. And that will make a lower removable partial denture (bridge) comfortable for the same period. It would be difficult to exaggerate the value to you of these lower teeth! I agree completely with this.

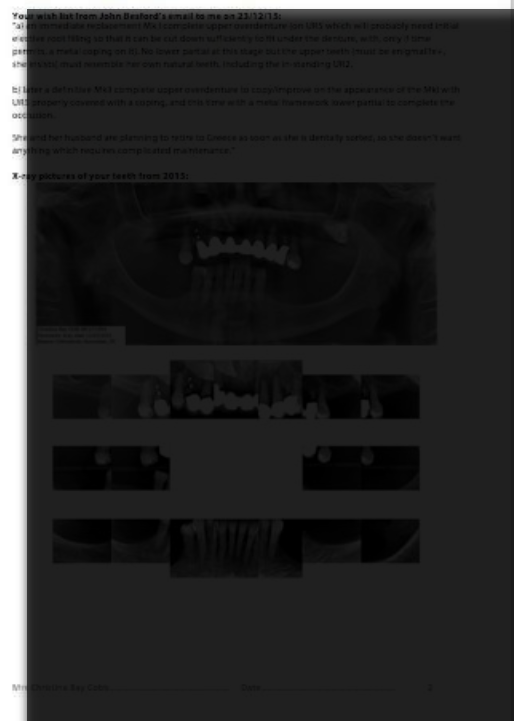
At your first visit we examine your mouth and teeth, giving you a preliminary diagnosis. This may slightly change when we propose for you. It may also be to change it to mean that the upper left first premolar requires extraction.

Dr John Bedford's email has asked that you have been to see ten dentists who have mentioned dental requests. You have been asked against this being an ethical obligation. This therefore limits your treatment options to either remaining as you are or to having a removable denture to replace the missing upper teeth in order to restore your dental appearance and chewing function.

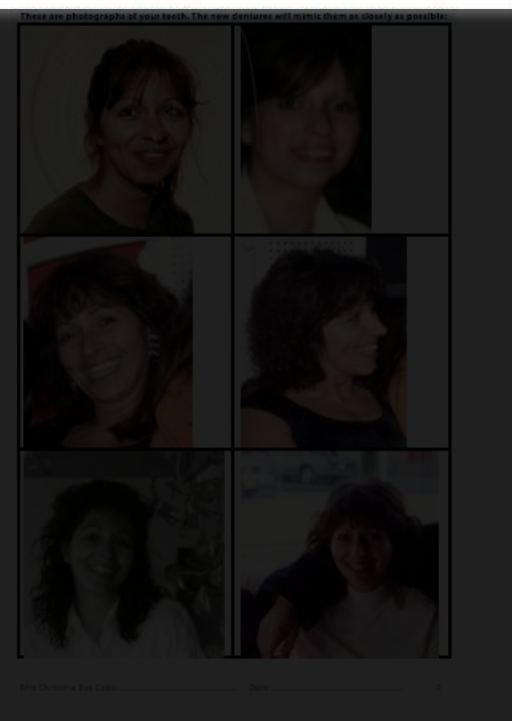
Mrs Christina Bay Date: \_\_\_\_\_ 1



Mrs Christina Bay Date: \_\_\_\_\_ 10



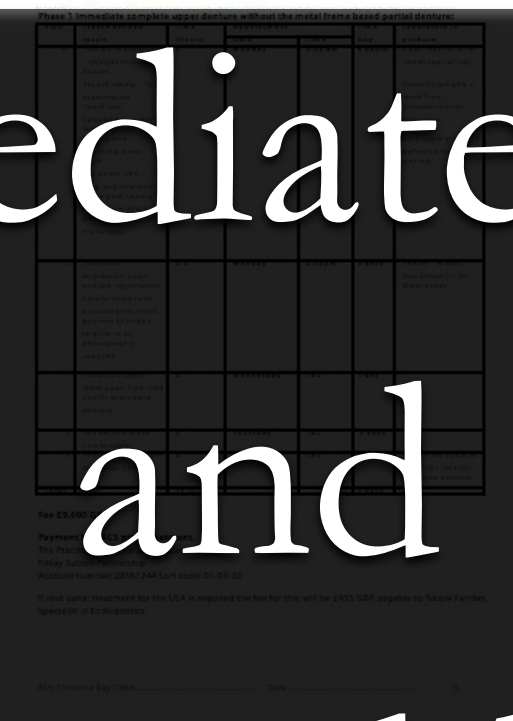Mrs Christina Bay Date: \_\_\_\_\_ 11




Mrs Christina Bay Date: \_\_\_\_\_ 12



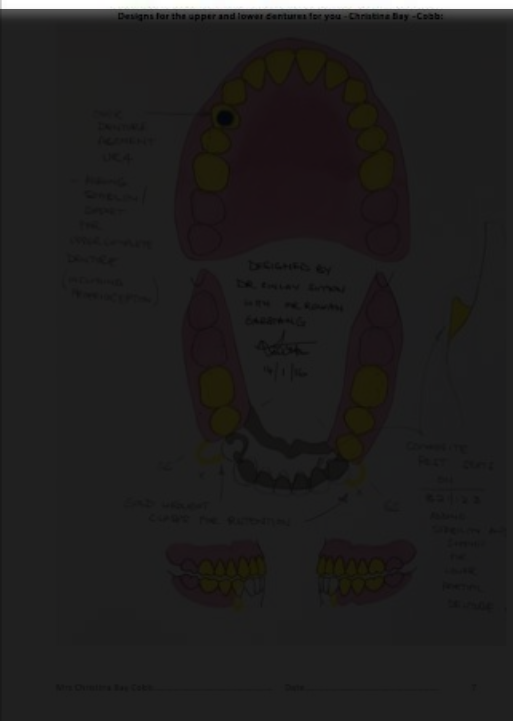Mrs Christina Bay Date: \_\_\_\_\_ 13




Mrs Christina Bay Date: \_\_\_\_\_ 14



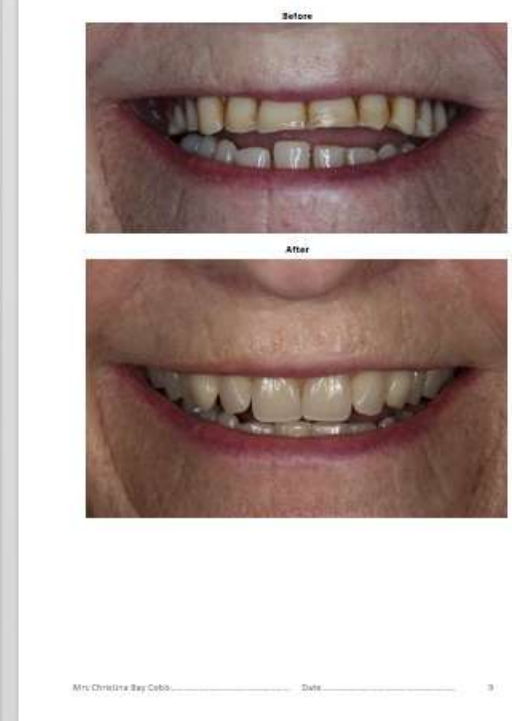Mrs Christina Bay Date: \_\_\_\_\_ 15



Mrs Christina Bay Date: \_\_\_\_\_ 16



Mrs Christina Bay Date: \_\_\_\_\_ 17



Mrs Christina Bay Date: \_\_\_\_\_ 18

Careful handling and cleaning of the dentures is required, because they can break if dropped on to a hard surface.

Reason and I will design the dentures in such a way that helps to protect the remaining upper natural teeth so that they last for as long as possible. However, in the event of a lower tooth in fact, the denture will be designed in such a way that allows an addition to the denture.

The dentures will be retained by clasps and will not damage the teeth when the denture is taken on and off. The denture will be designed with a very specific gap to maintain an air space and as such the amount of 'wiggle' required from the clasps will be minimal. I will teach you how to do this in and out only. These clasps and some of the metal work may be slightly visible when you are broadly, in and out but they will not detract from your smile.

Some of the natural teeth will require a small amount of grinding and small white composite fillings placed, to allow the denture to fit optimally. These fillings and the grinding will not damage the teeth.

Learning to speak with dentures may take 6-8 weeks to adapt. Please note that our patients have always adapted to them and their speech normalises with time.

Learning to chew satisfactorily with a denture usually requires at least 6-8 weeks, and occasionally a little longer.


**General**

Patients regularly ask how long their dentures will survive. Unfortunately, this is impossible to predict. As dentures are not an ideal service I cannot guarantee how long the work will provide and last. It is very important to understand that Reason and I produce everything to the best possible standard and possible cost, using the highest quality materials and using our expertise. However, as with all things involving moving parts, things wear out, break, chips, cracks etc and will be eventually. I cannot predict how long the replacement or repairs will last as everyone's mouth is unique and some people are heavier than others on their teeth.

I would be very grateful if you could kindly sign the bottom of each page acknowledging that you have read, understood and agree to the terms of this letter. This can be done at visit 1.

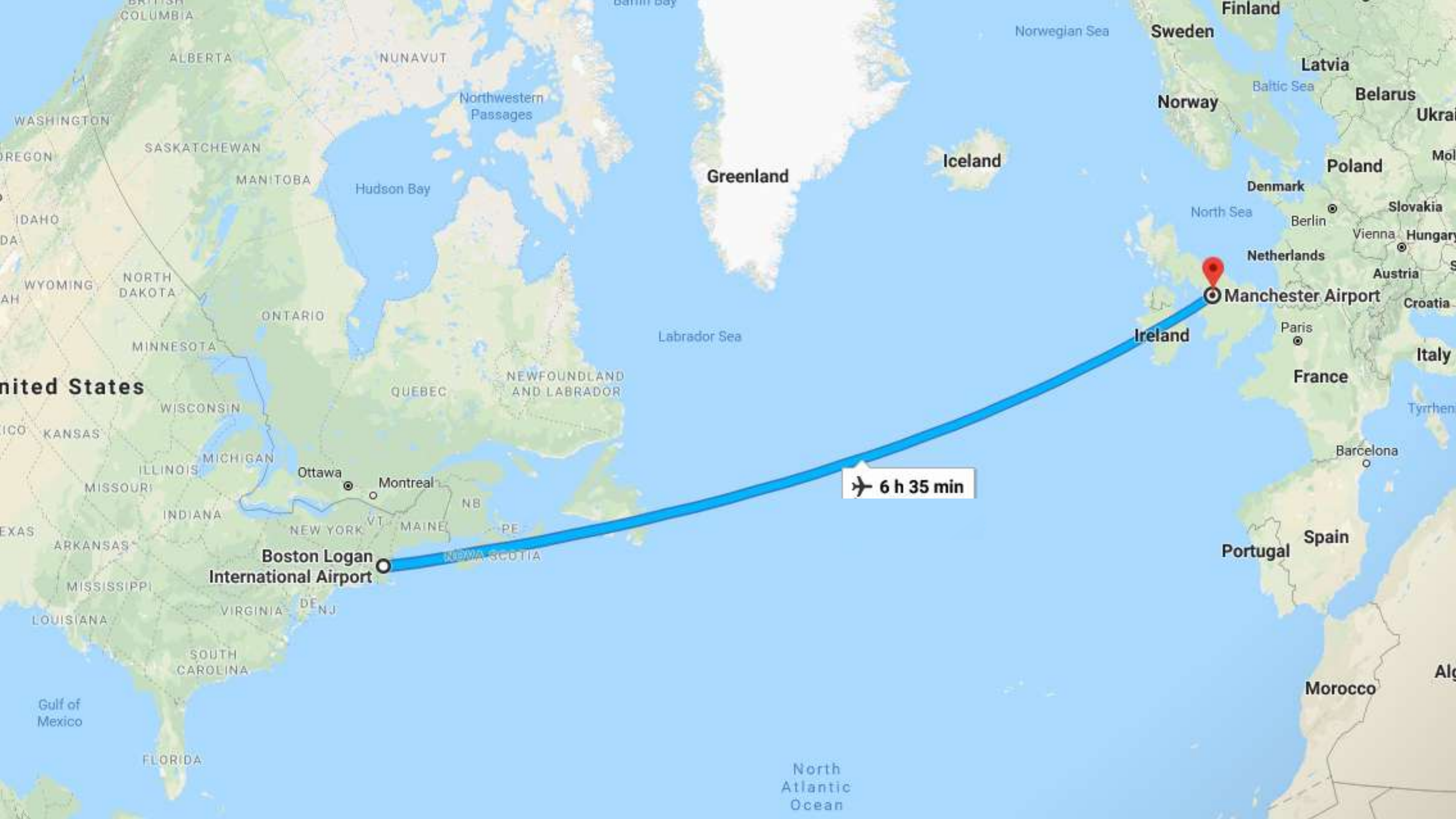
If during treatment there should be any changes in your medical history, including cessation of any medication that you may be taking, would you please inform us immediately.

If you have any questions, please do not hesitate to contact me.

With kind regards,  
Yours sincerely,  
  
Dr Peter Gutter  
BDS, DDPD (UK), MRD, MRCSEd, MRD RCSEd, PhD, FDS (Rest Dent) RCSEd  
Regional Consultant in Restorative Dentistry, Accredited, Consultant in Restorative  
General Dental Council Number 55652

Mrs Christina Bay Date: \_\_\_\_\_ 19





**Boston Logan International Airport**

**Manchester Airport**

✈ 6 h 35 min

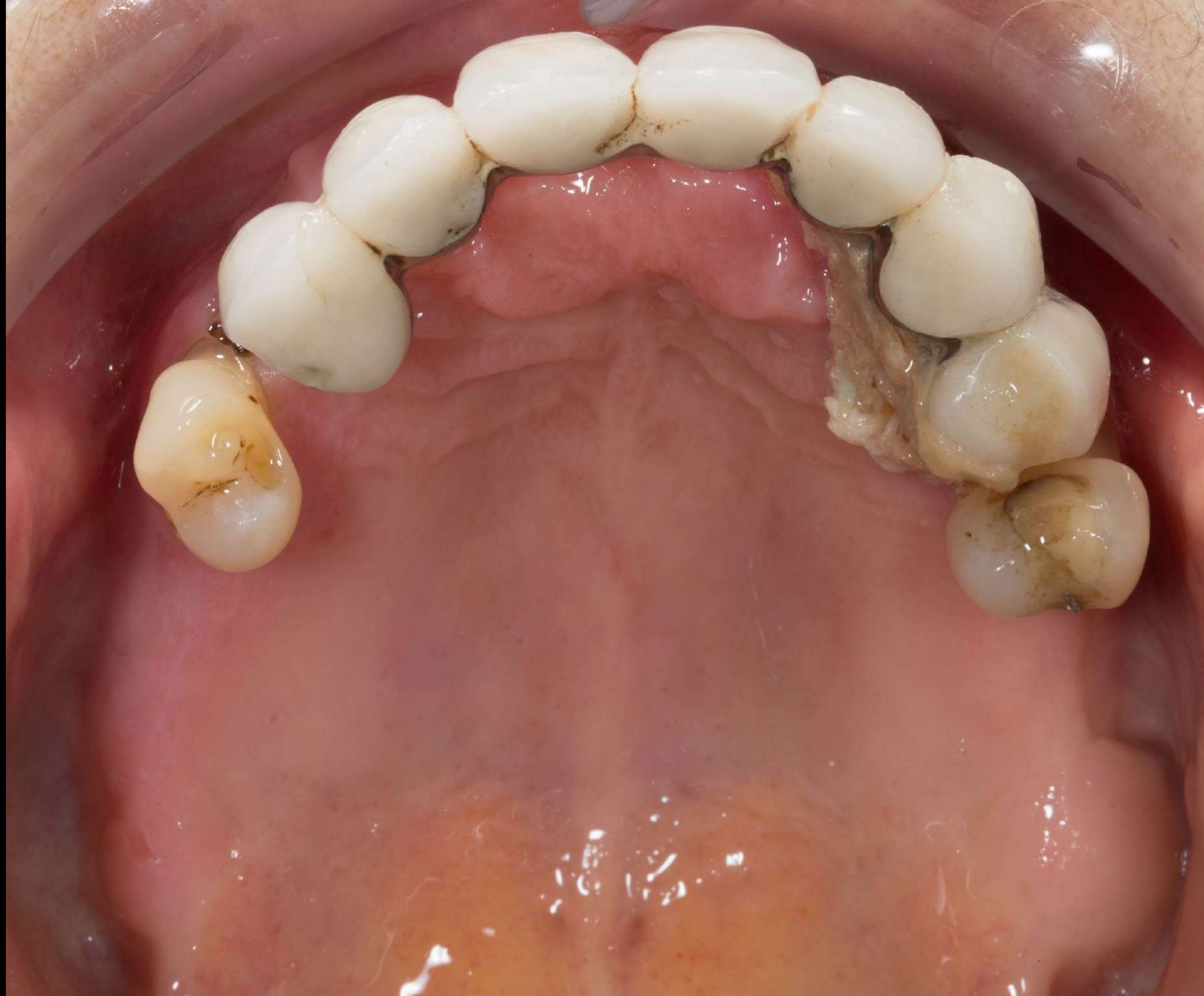



Day 1

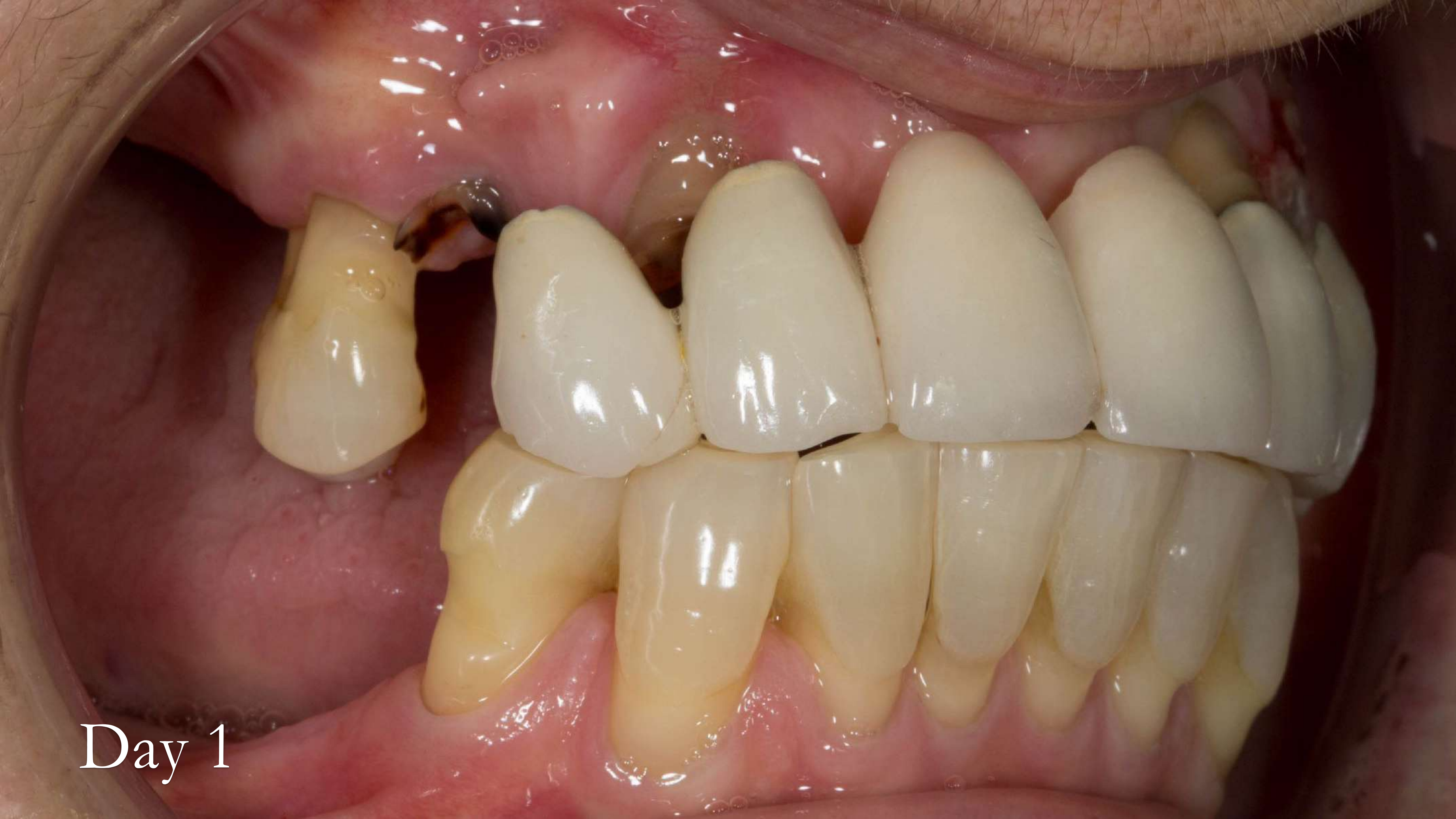





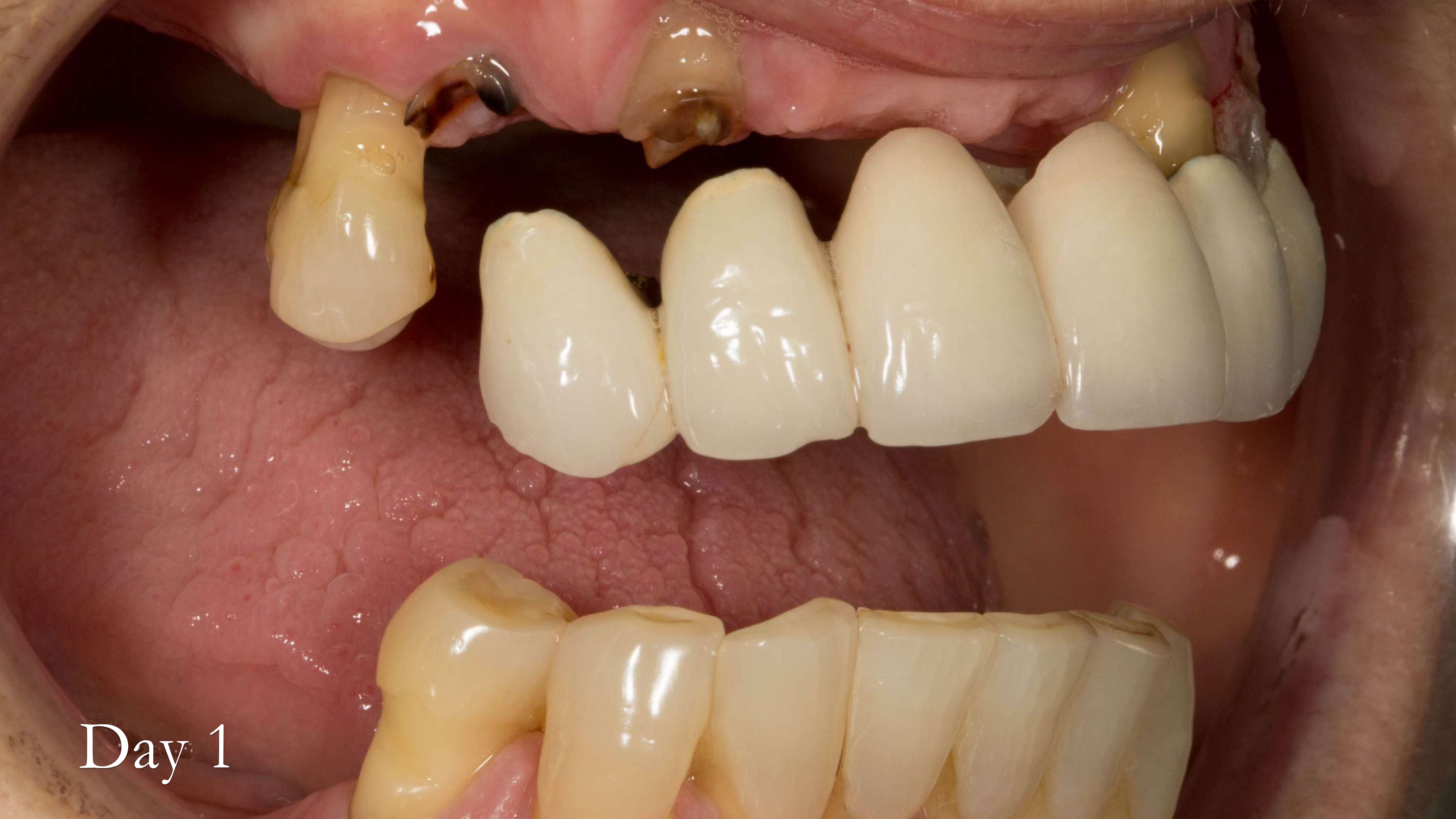Day 1





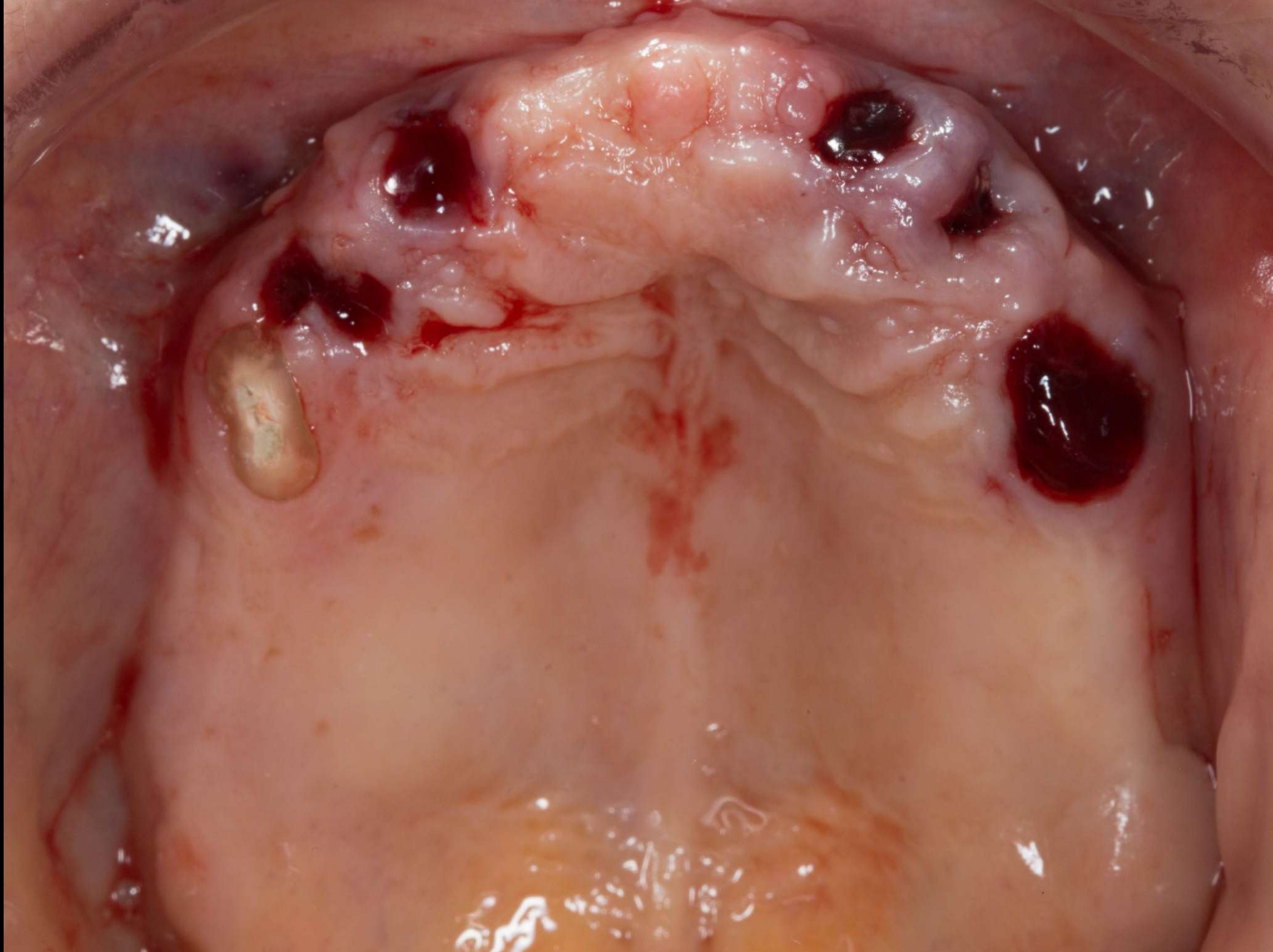
Day 1





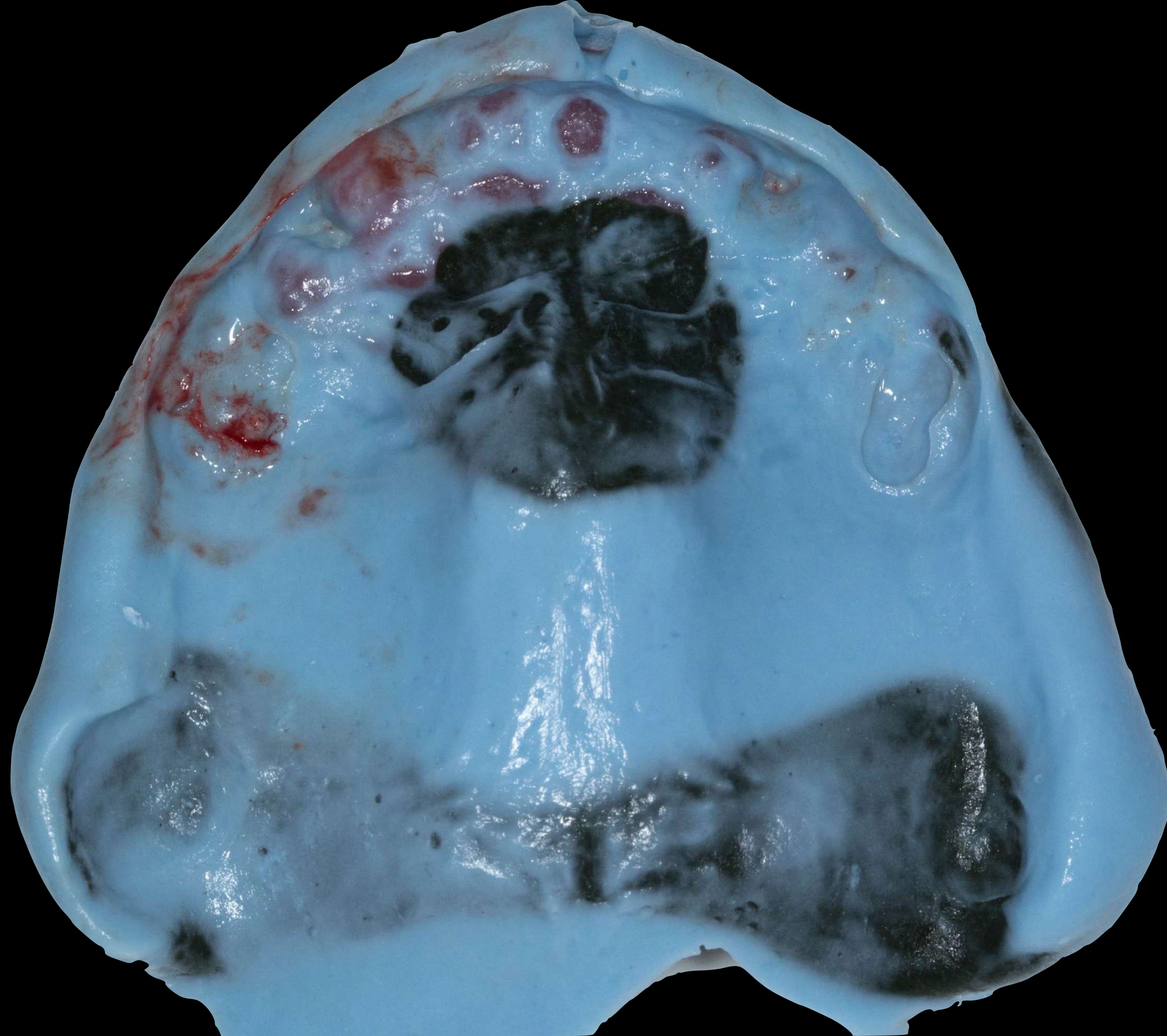
Day 1





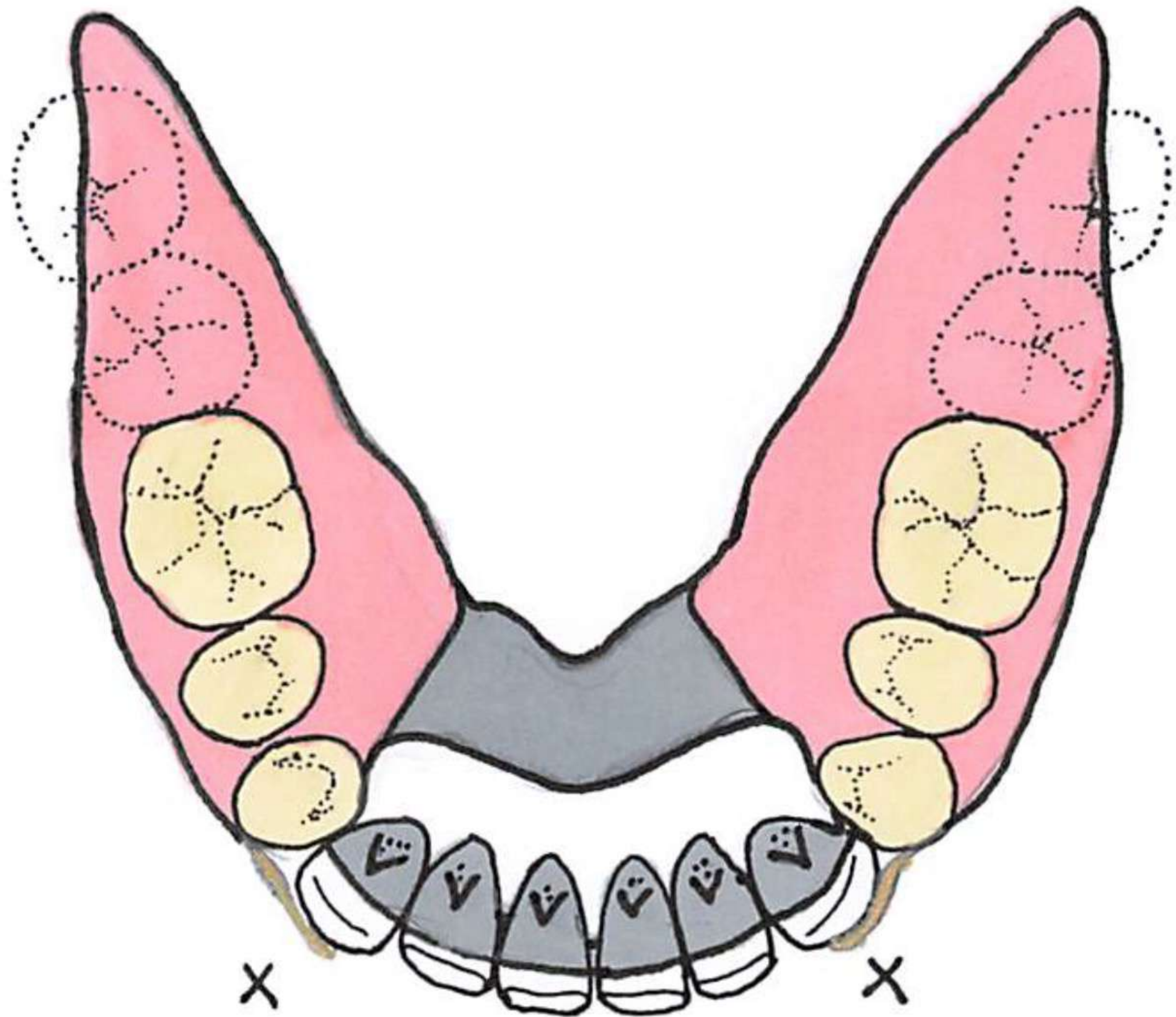
Day 1





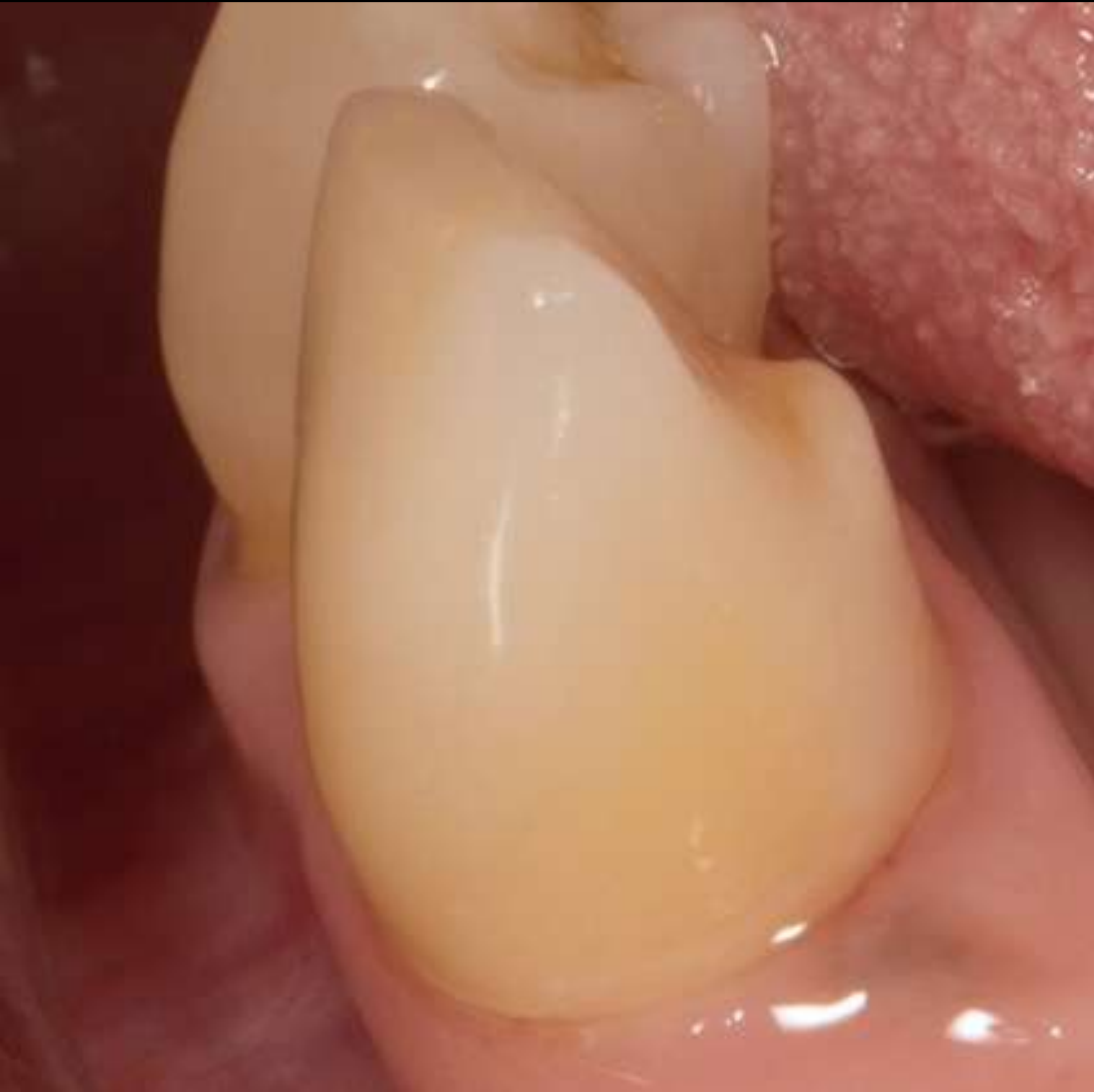Day 1







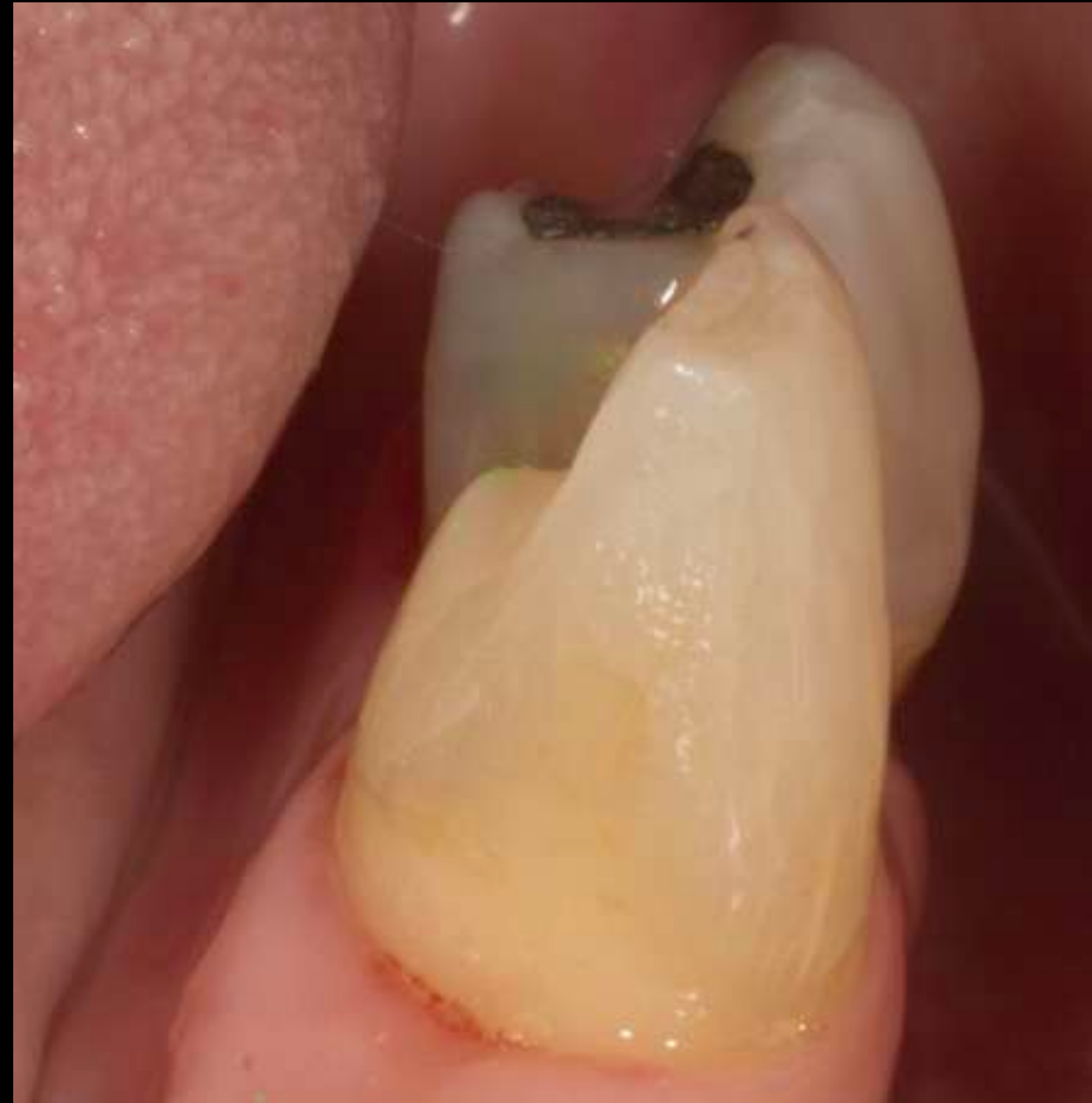PBZ crown





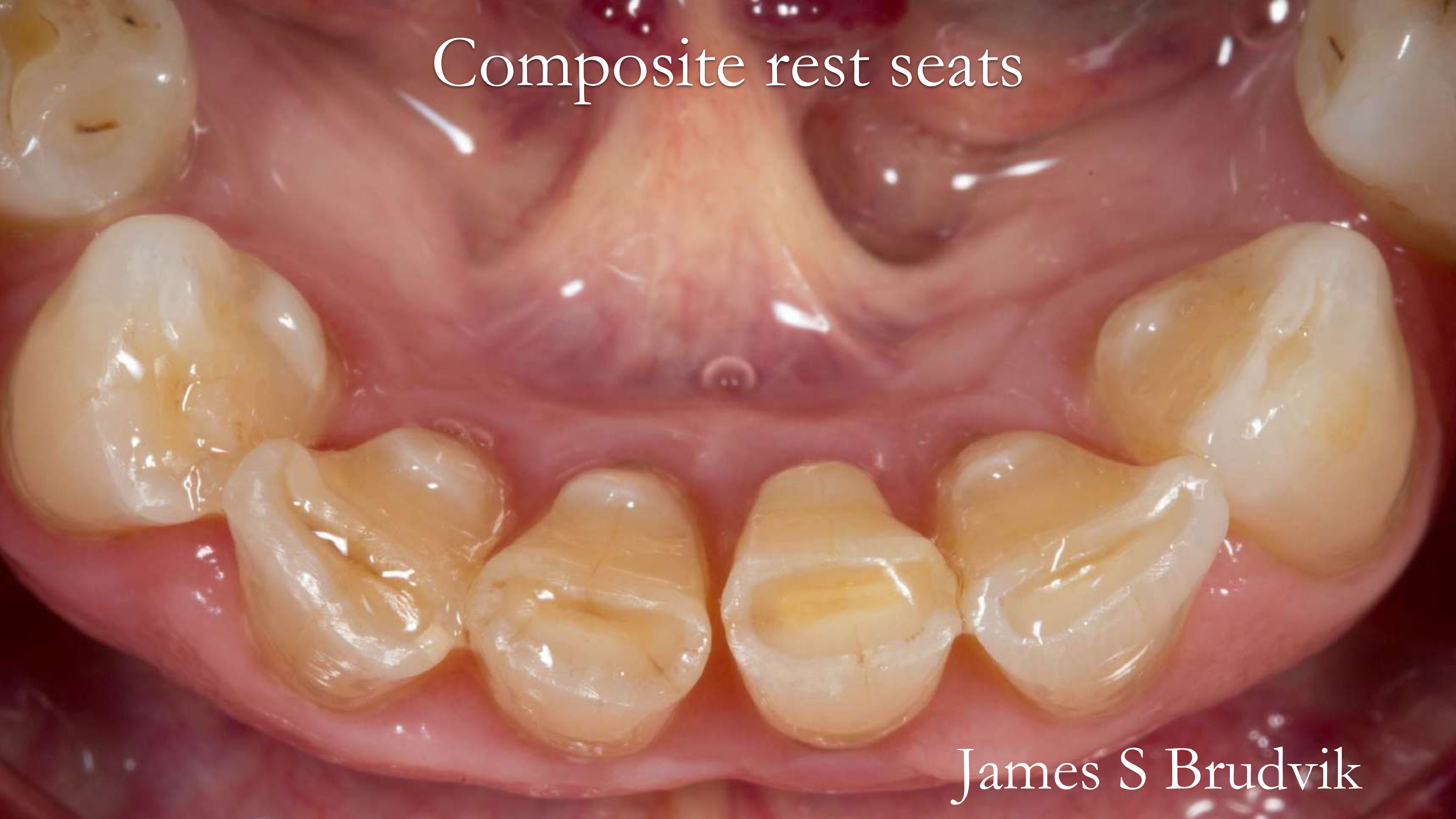PBZ crown

Composite



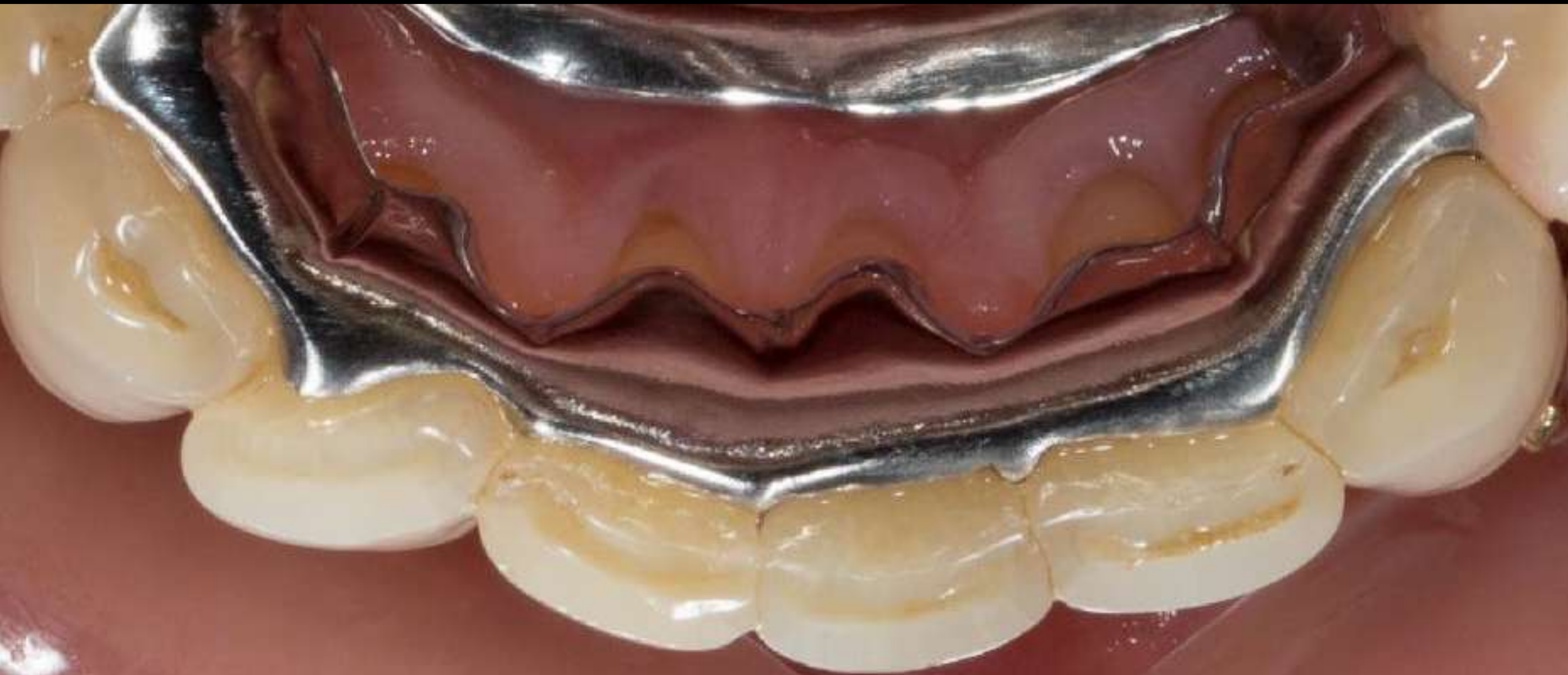

# Composite rest seats

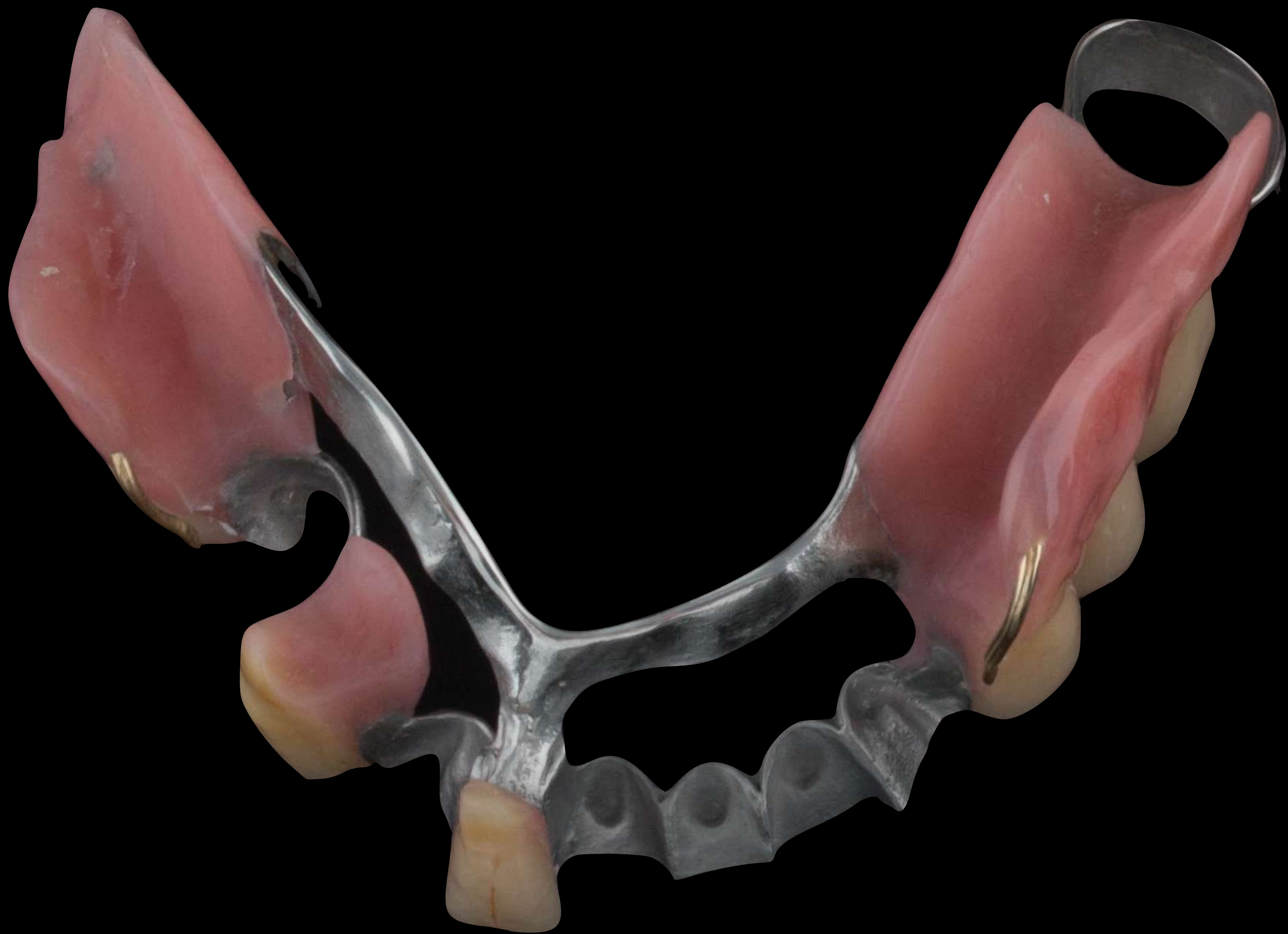

James S Brudvik

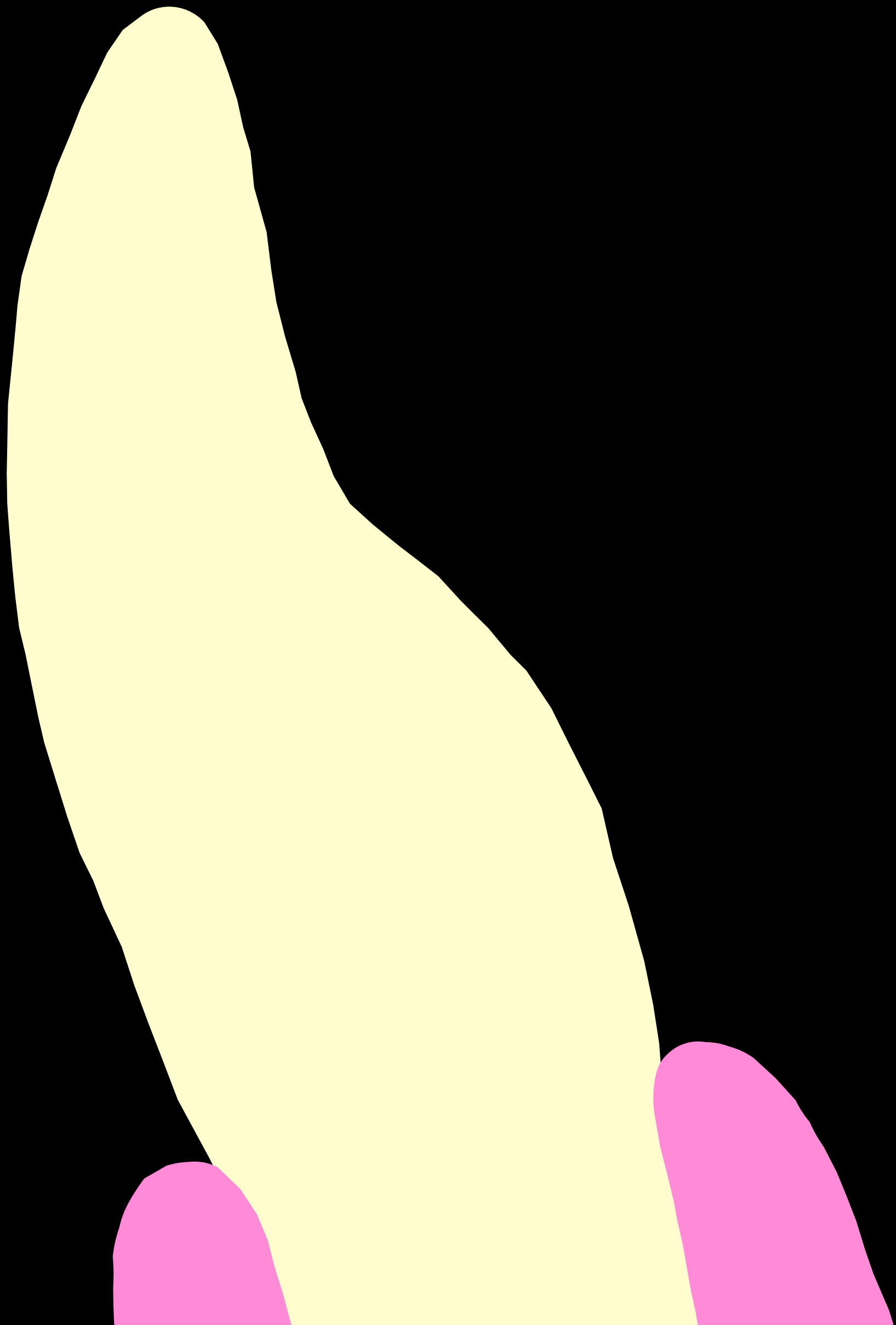









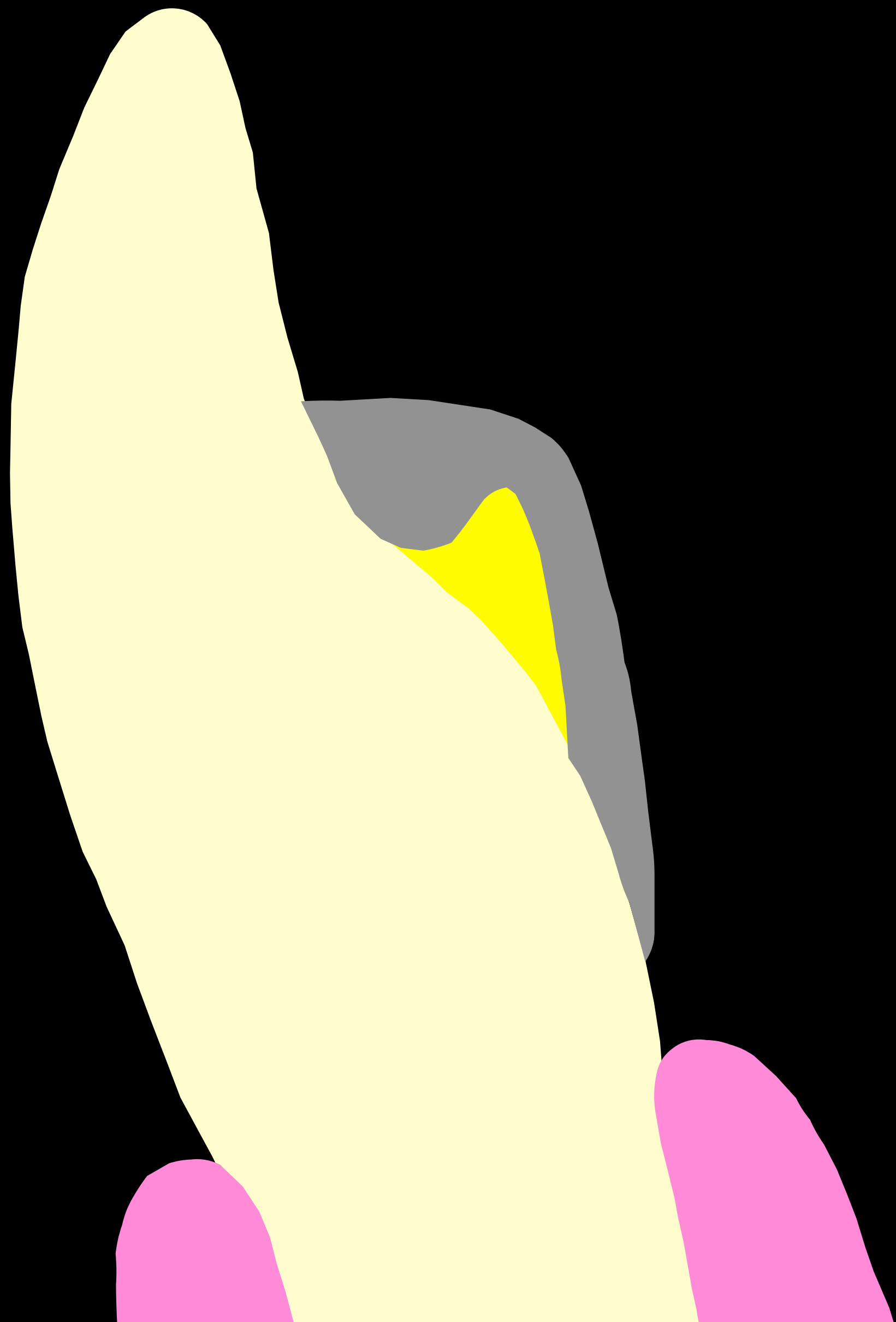




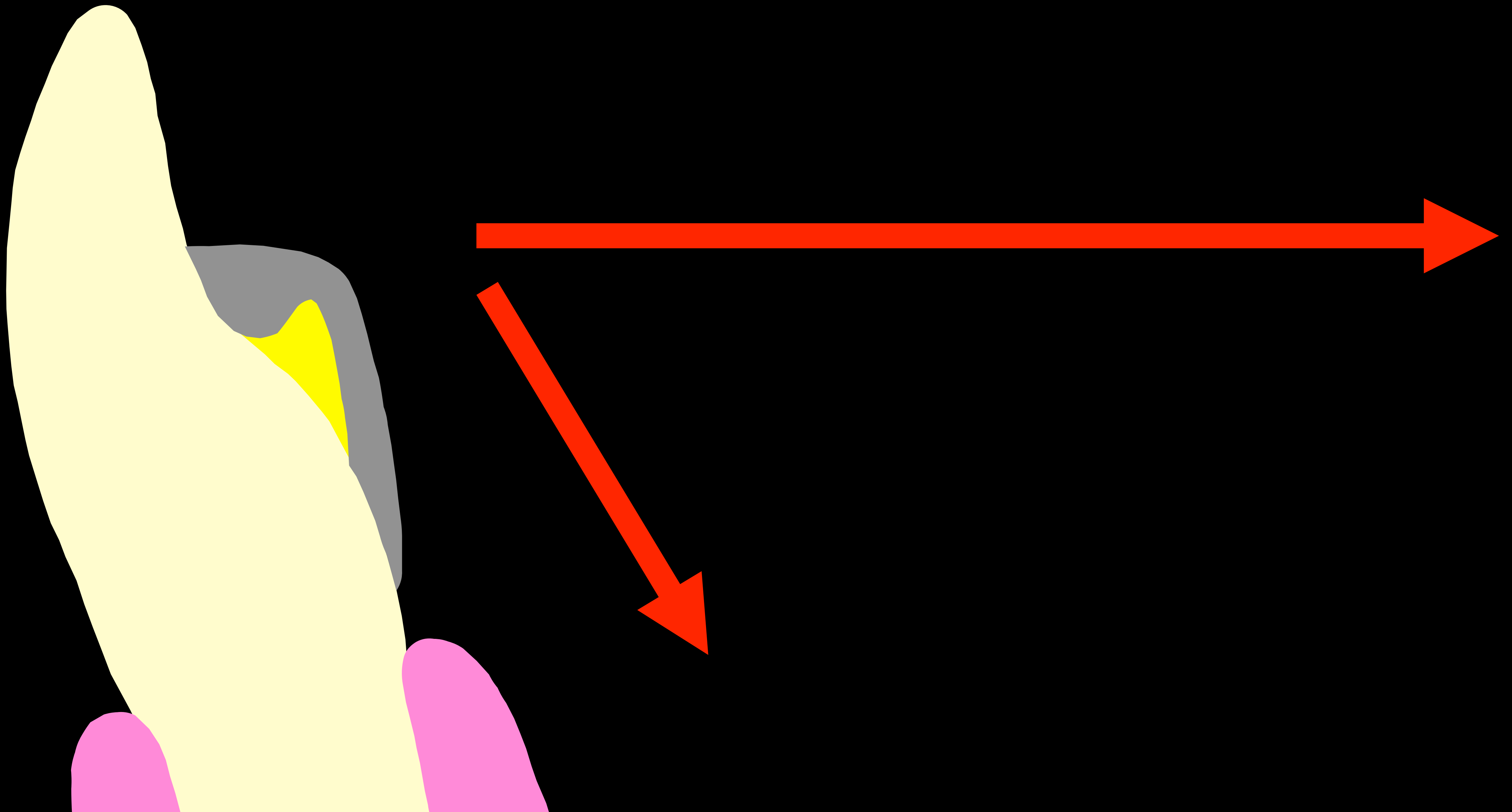




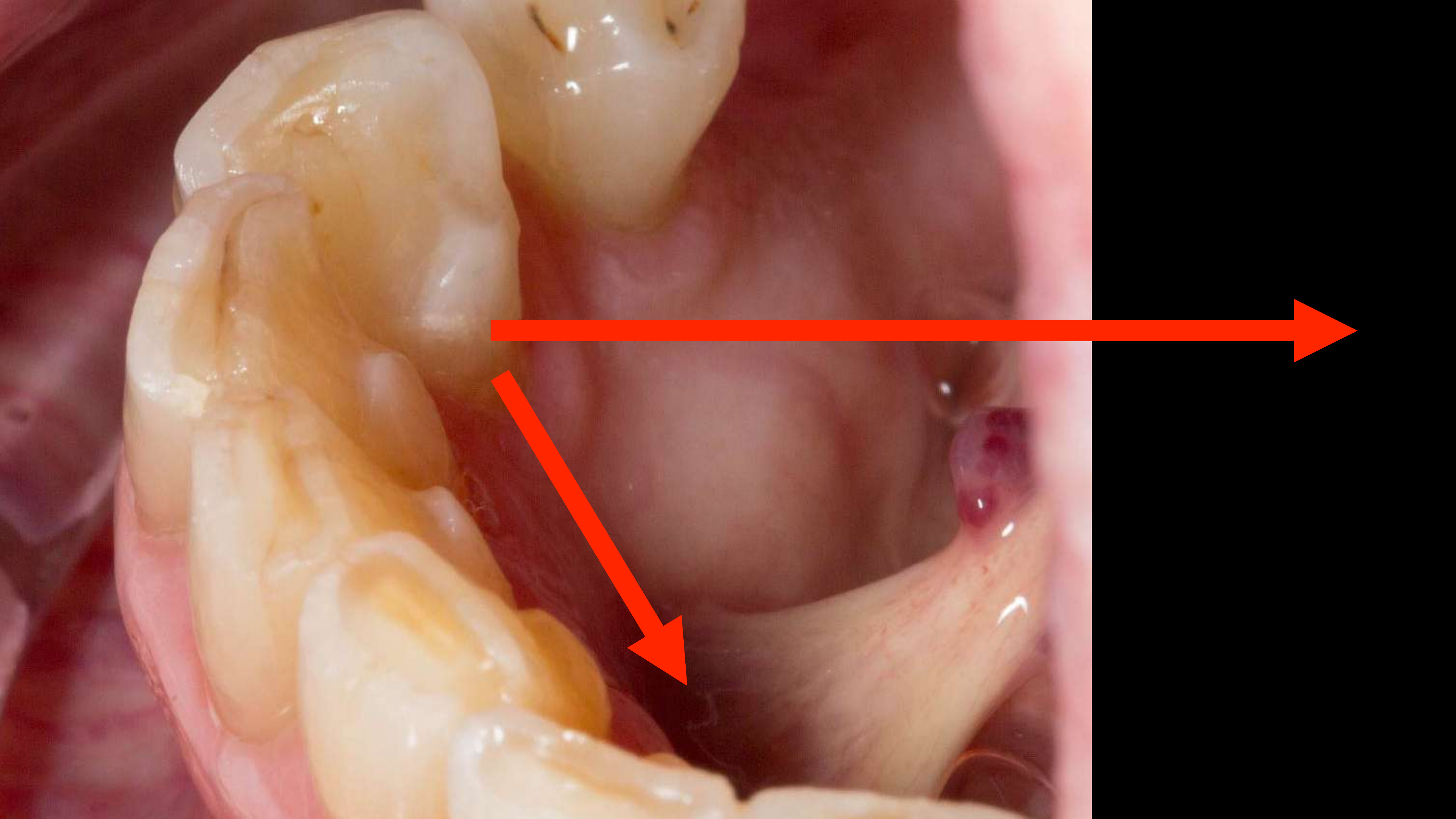



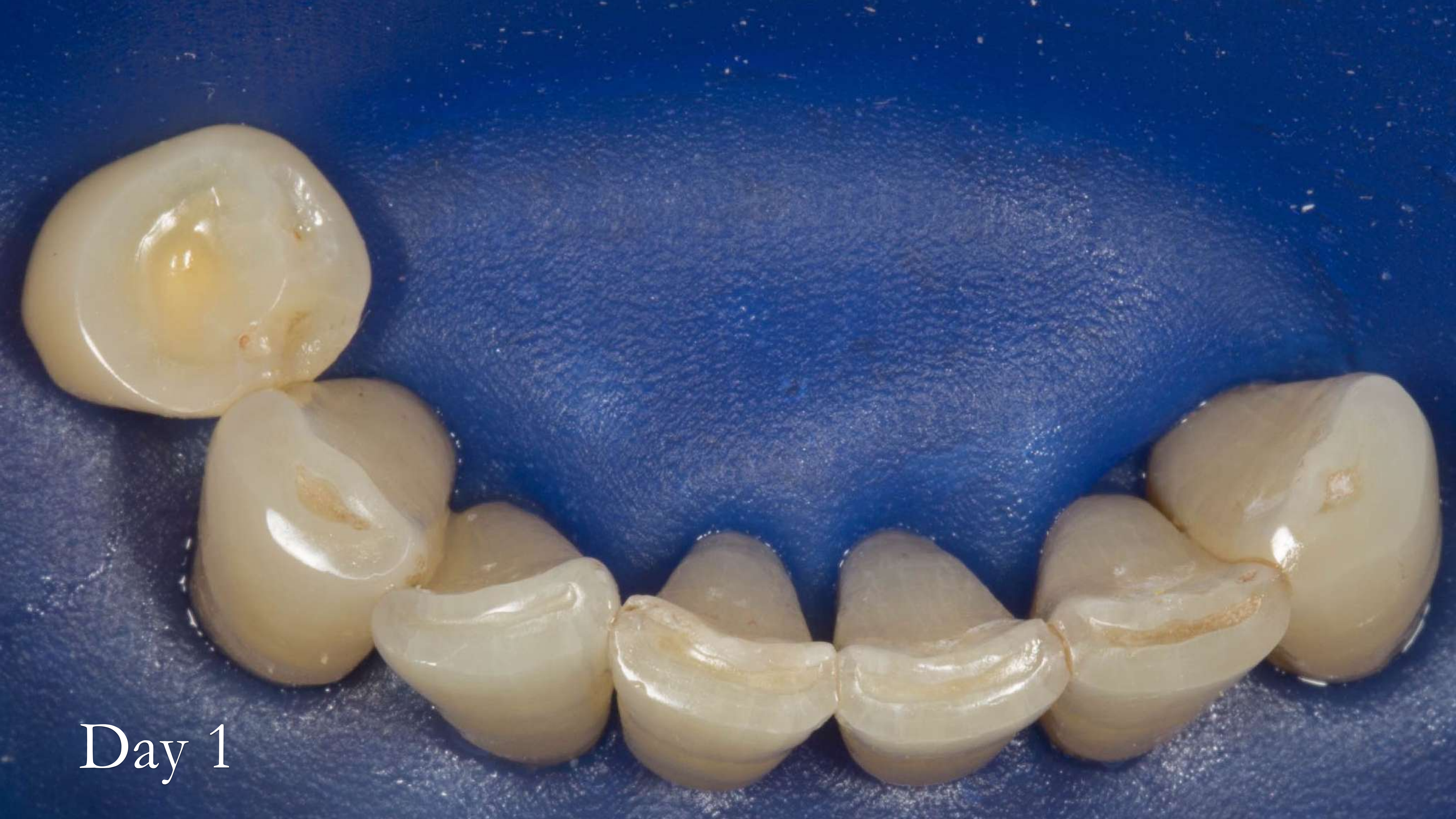






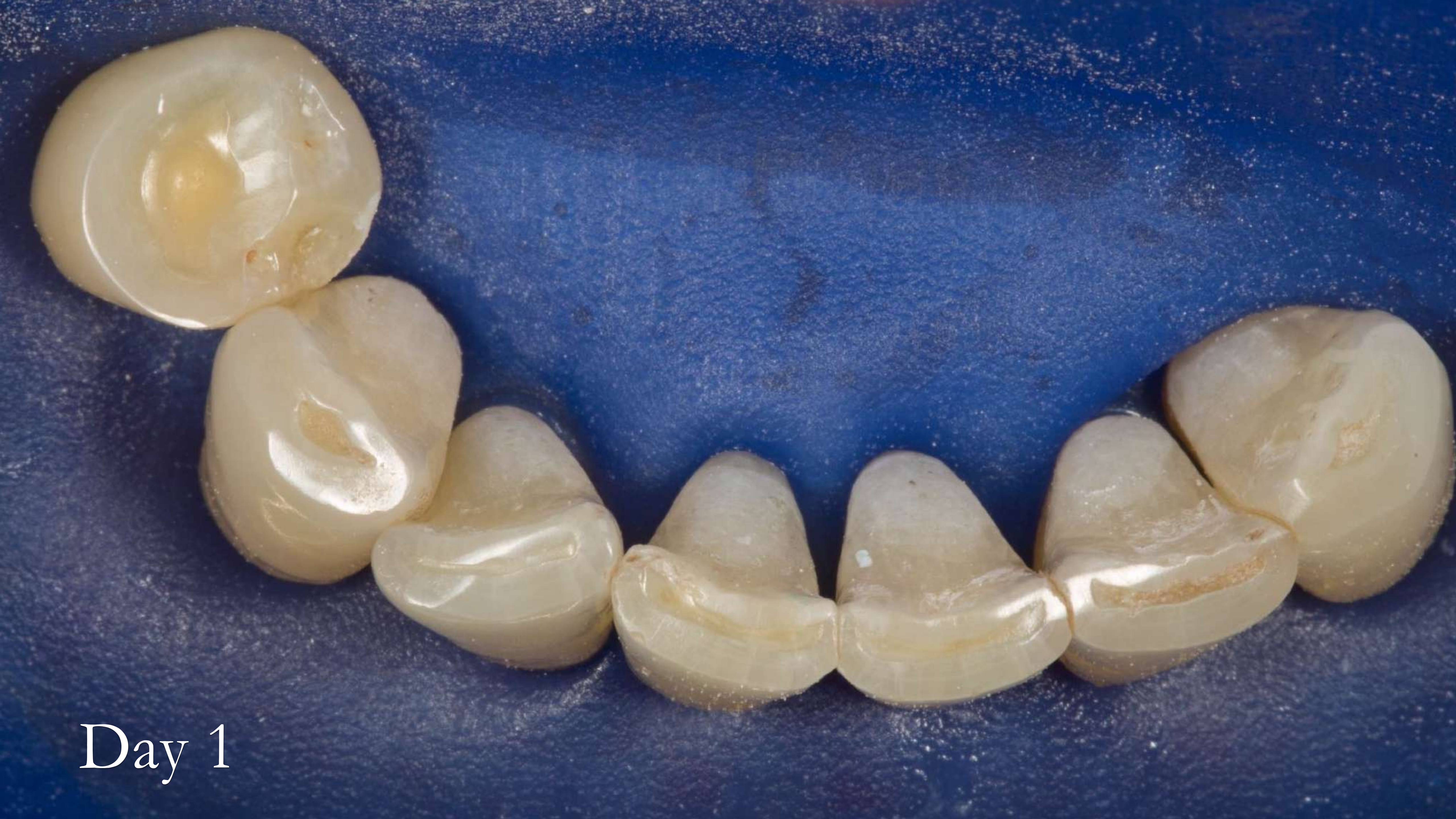





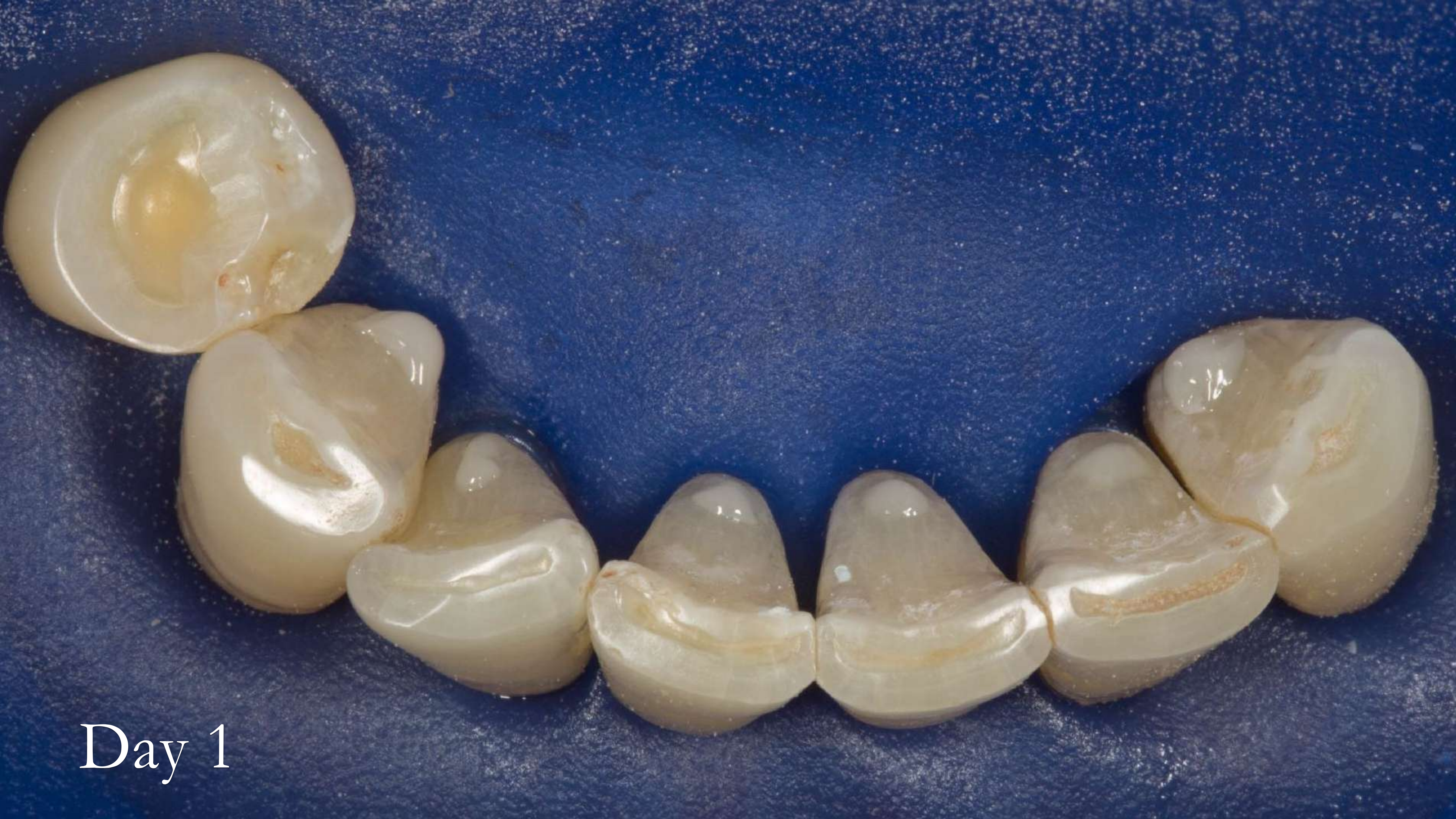Day 1





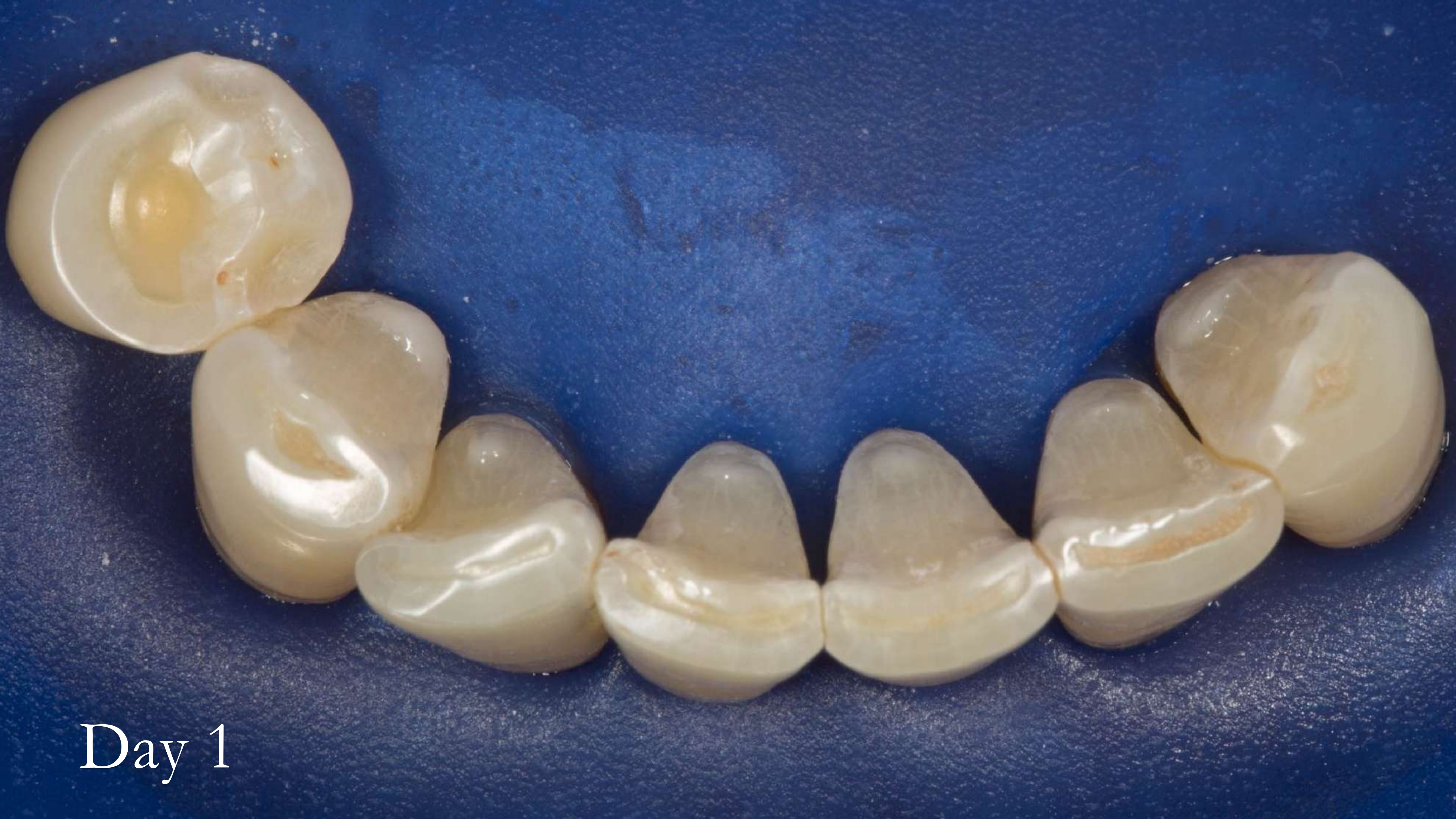Day 1





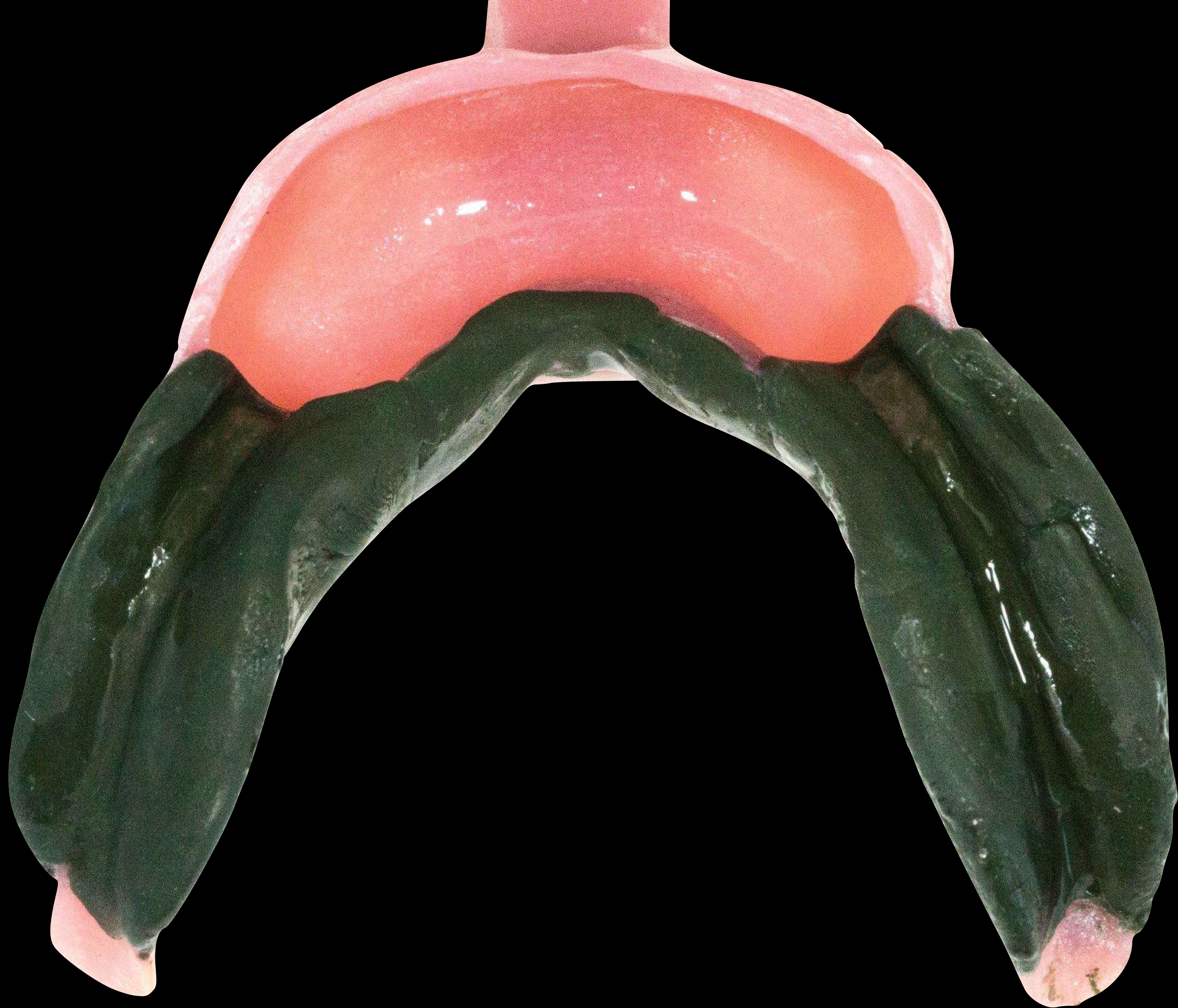Day 1





Day 1





Day 1



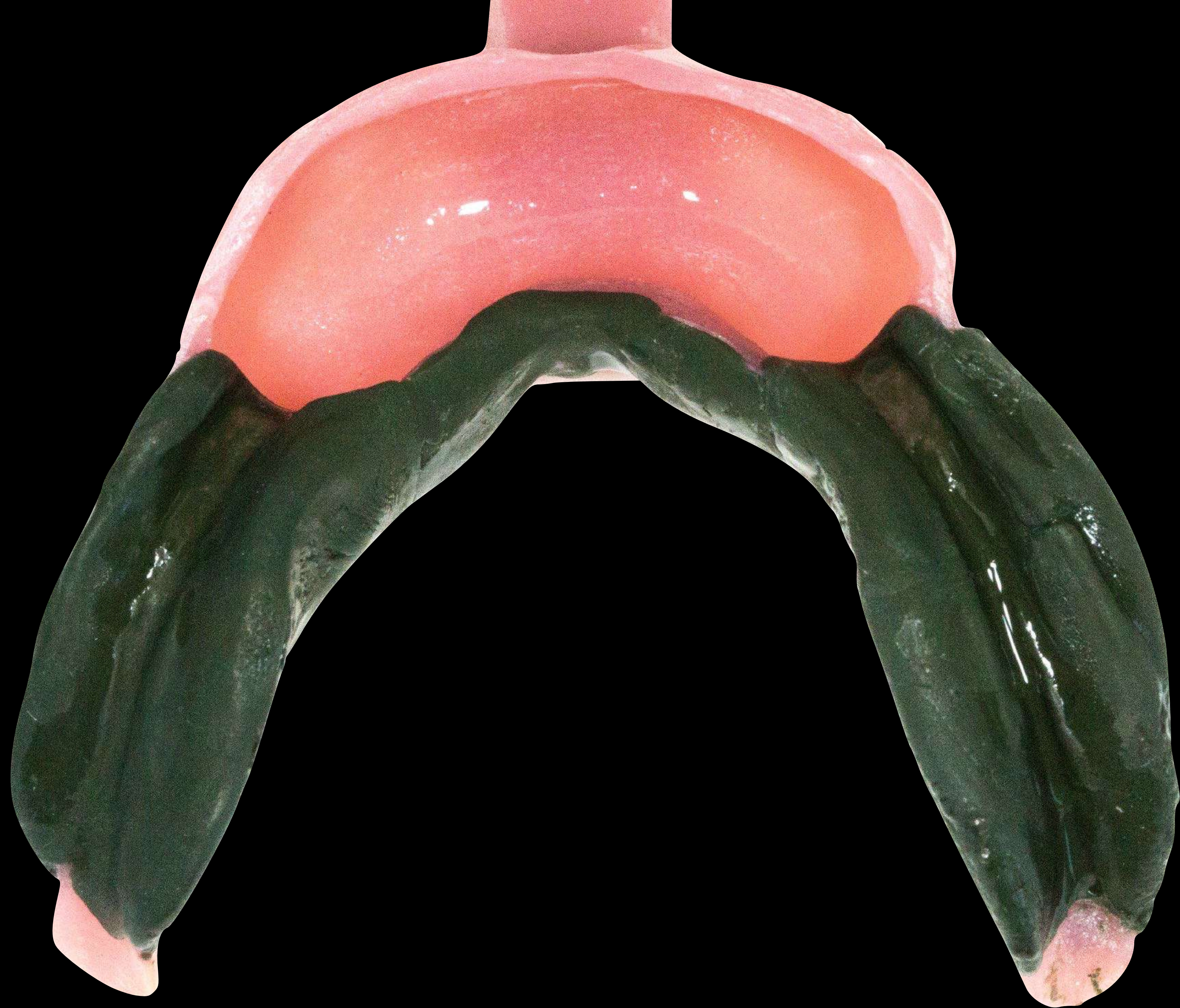There is an easier way!





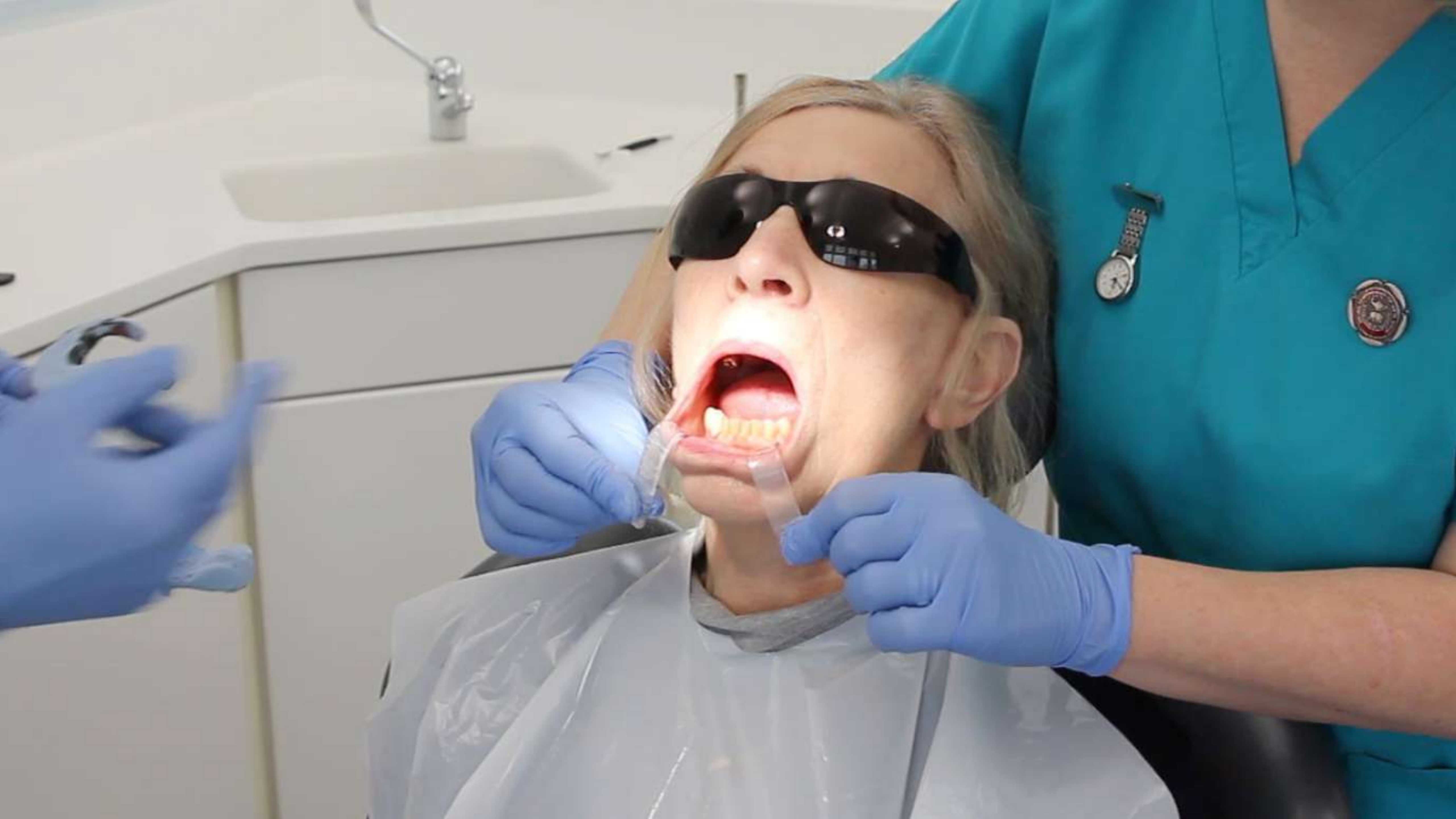




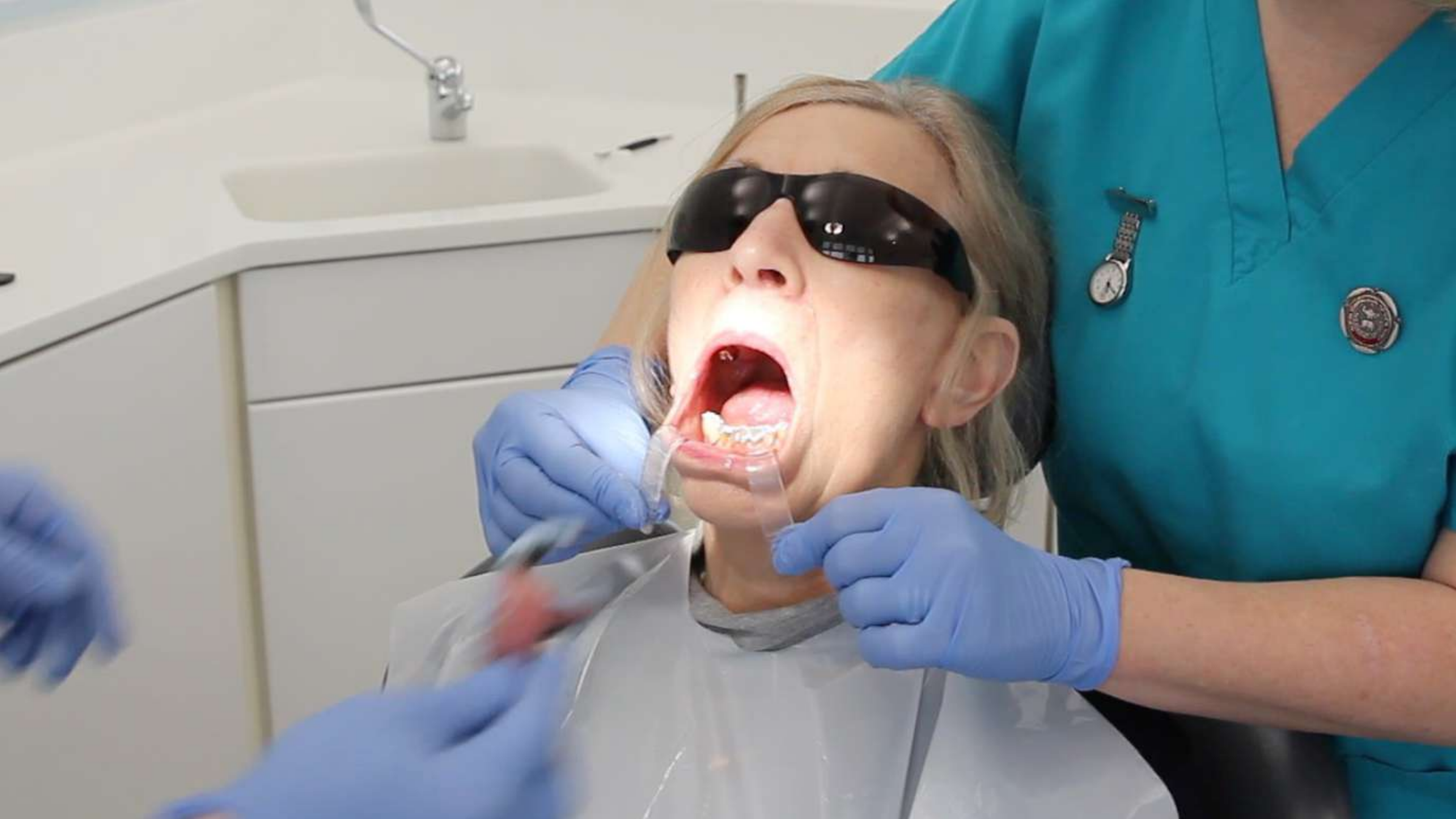
Day 1

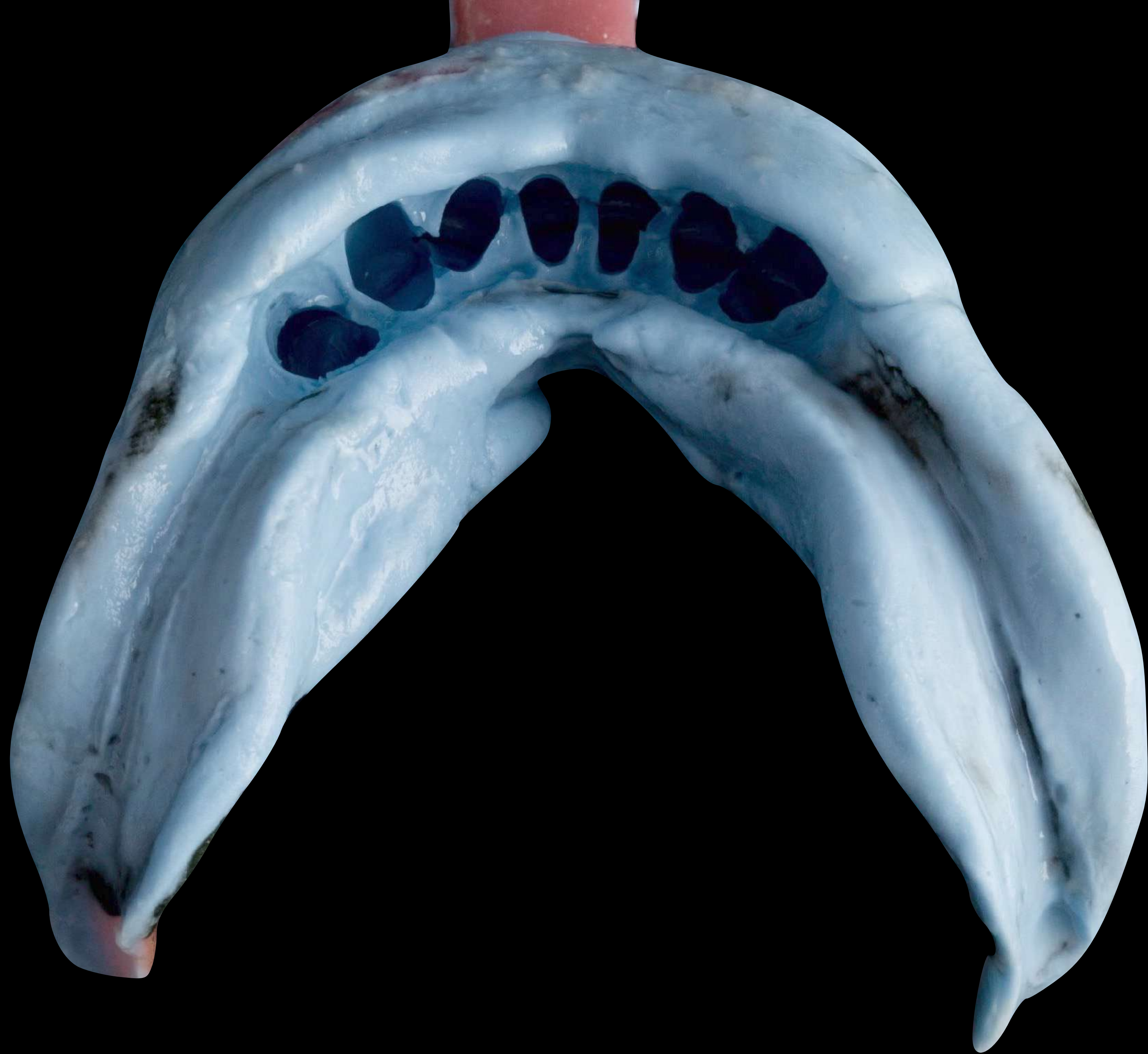











Day 1





Day 1








Day 3



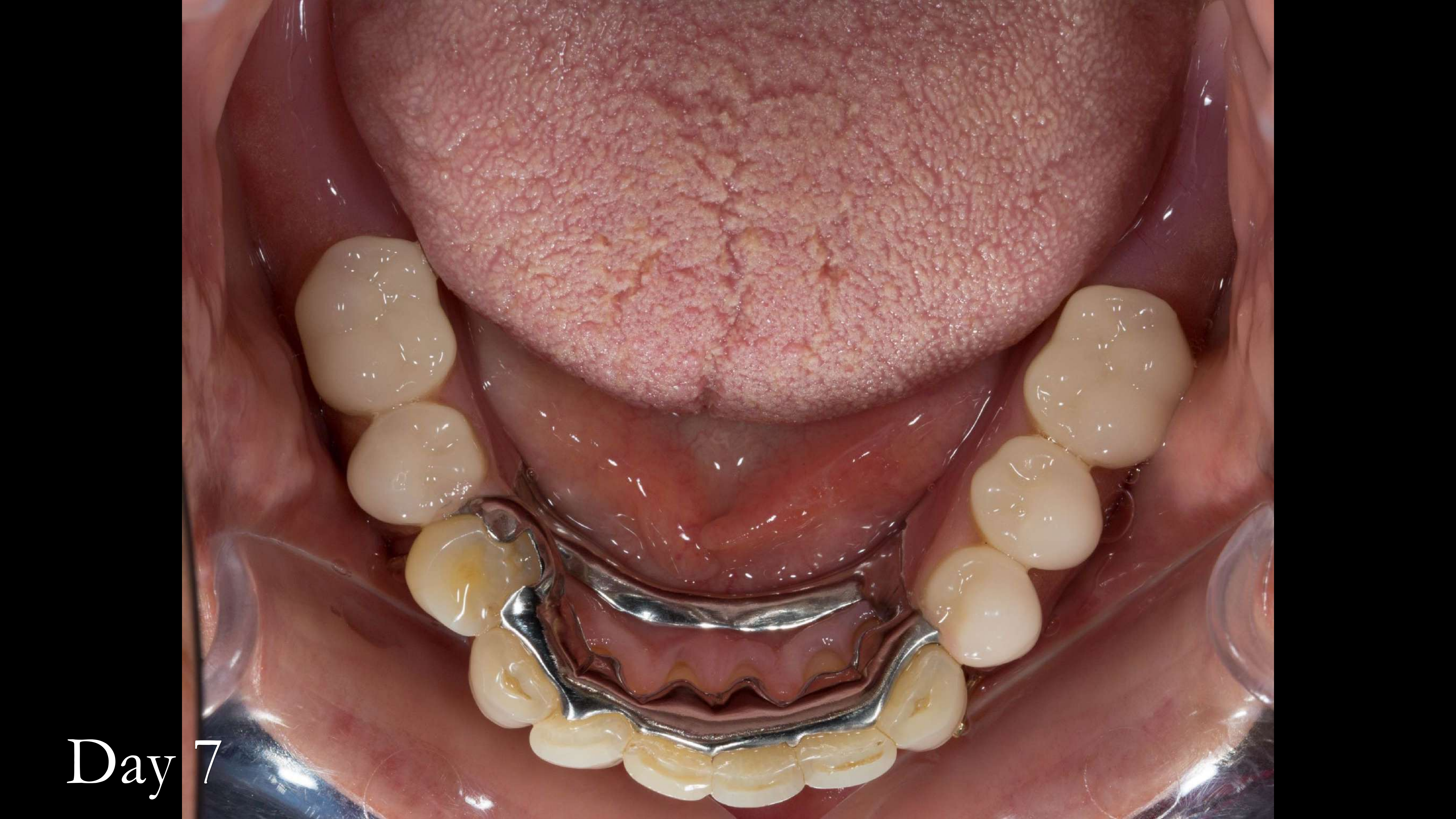



Day 3

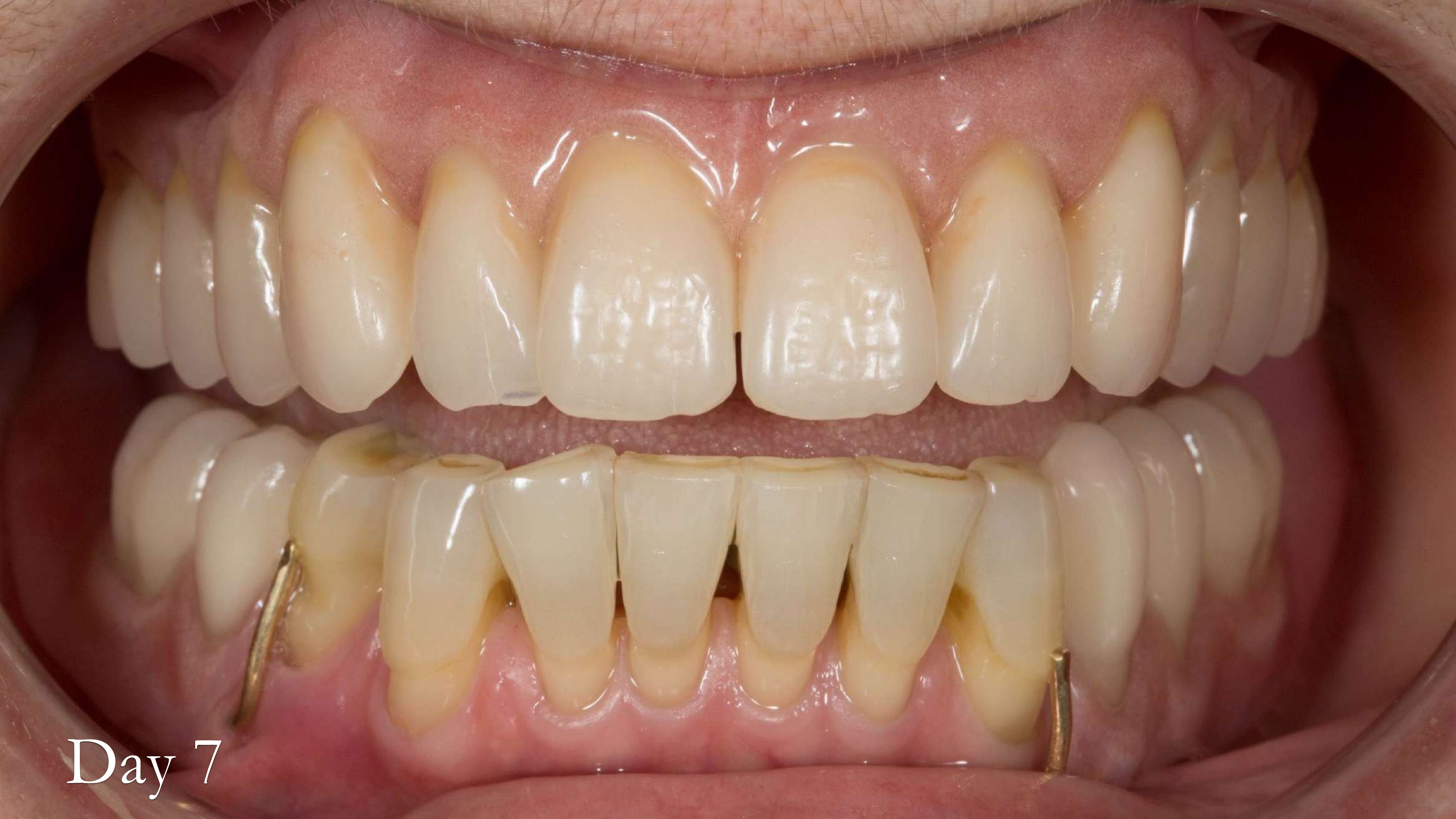





Day 7





Day 7





Day 7

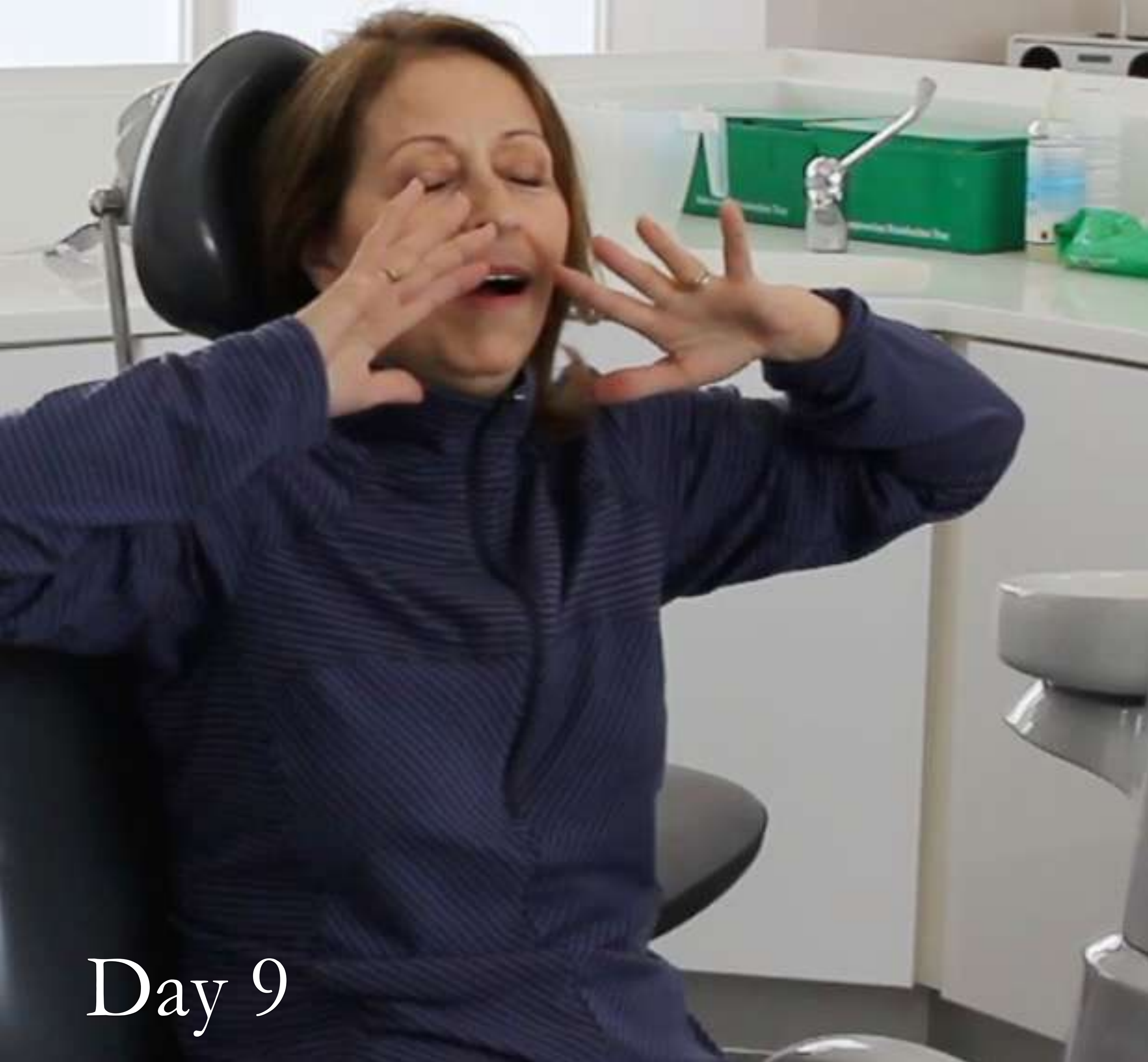





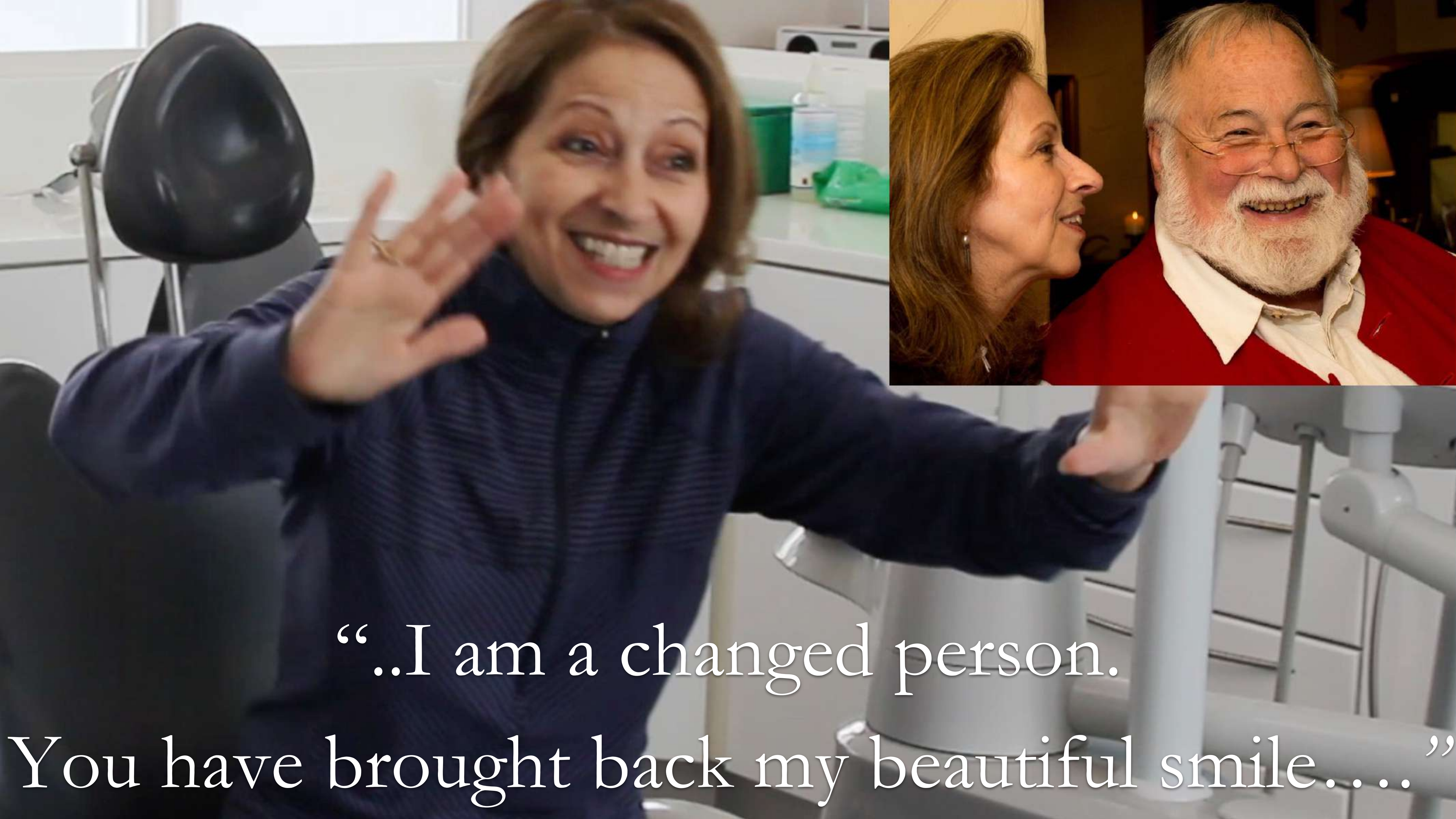Day 8





Day 9





“..I am a changed person.  
You have brought back my beautiful smile.....”



Call to action





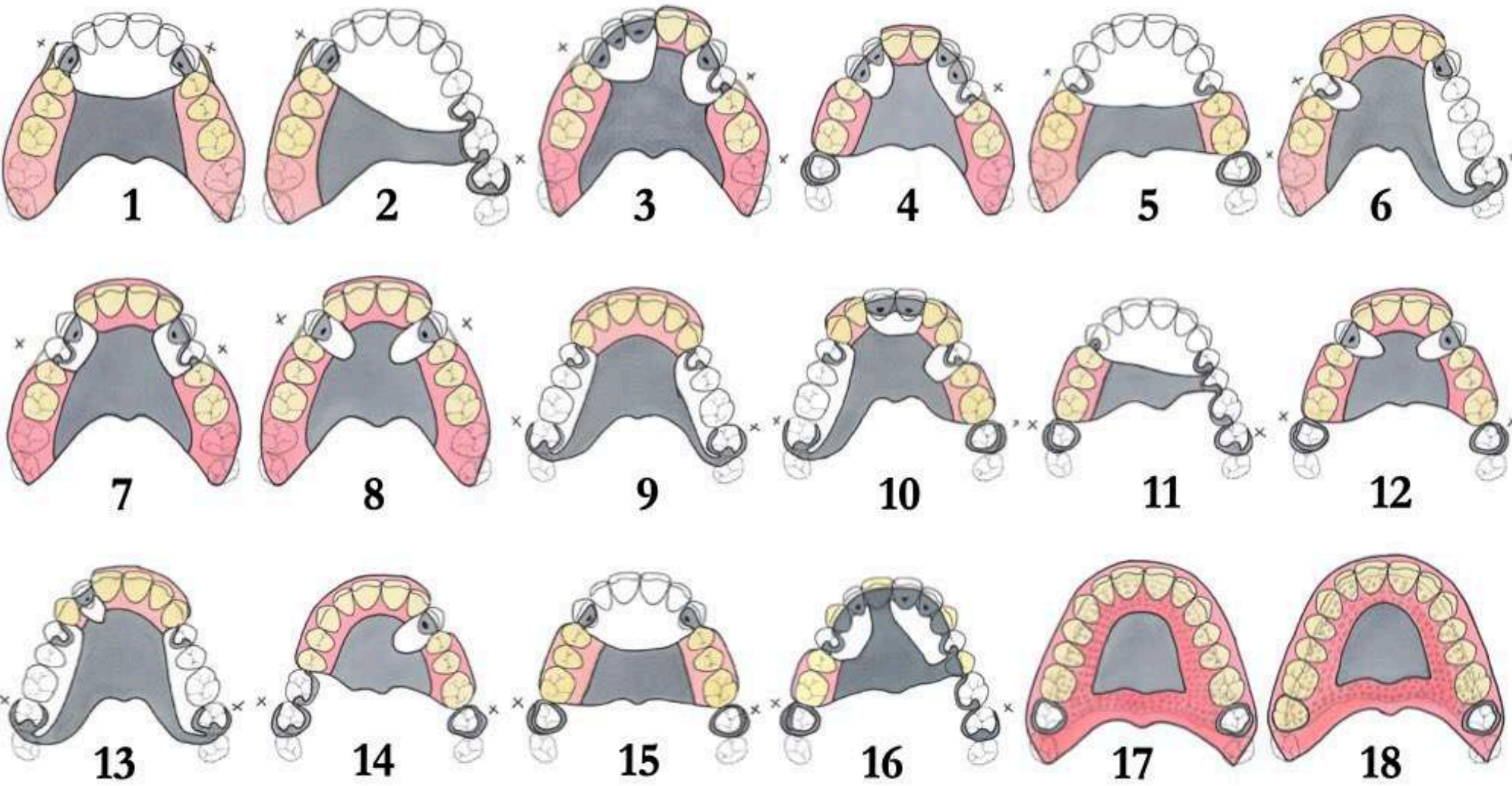
1. Use the designs



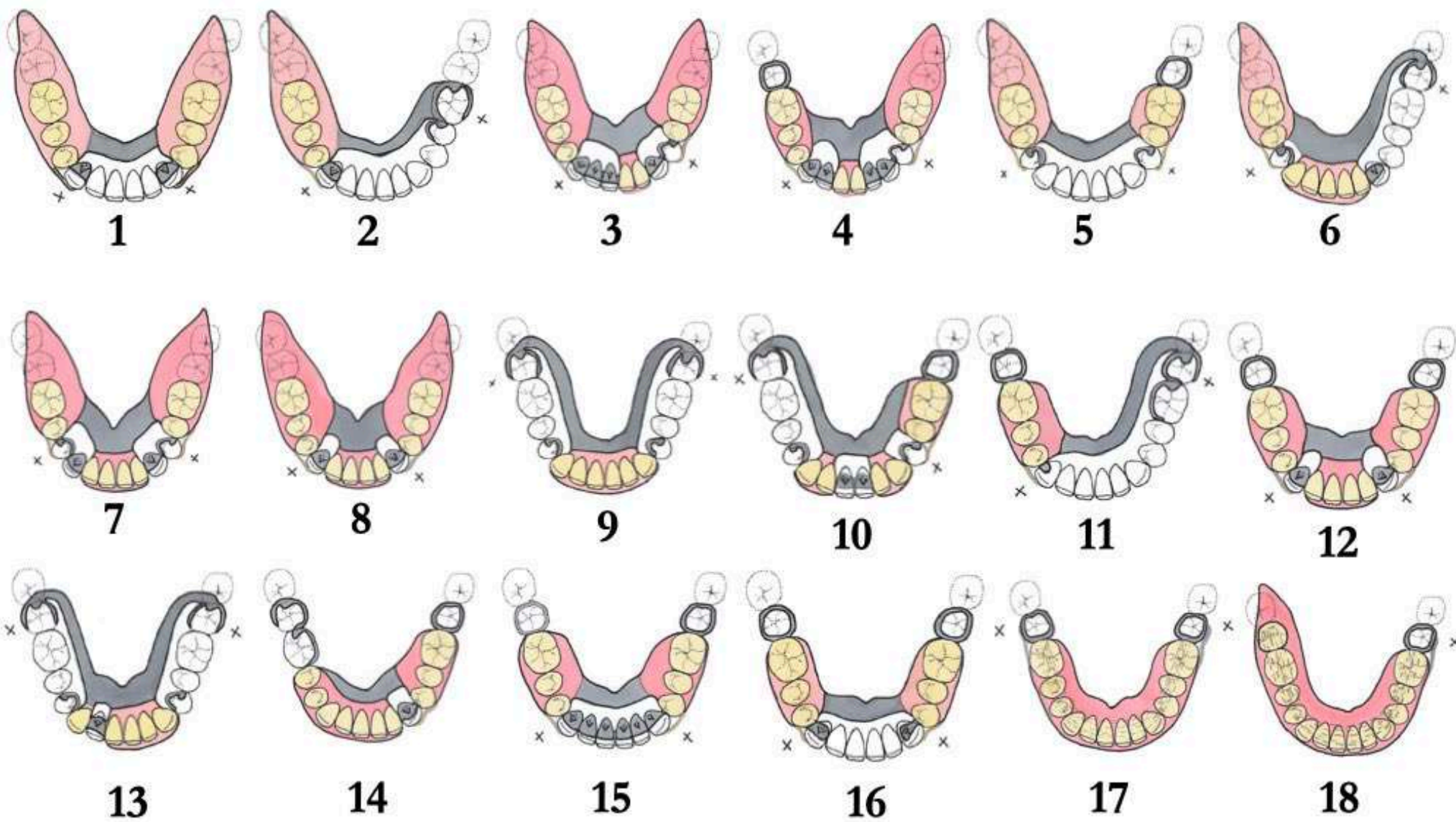


Scandinavian universal designs for **many** patterns of tooth loss  
REMAINING TEETH HAVE **GOOD** PROGNOSIS

Uppers

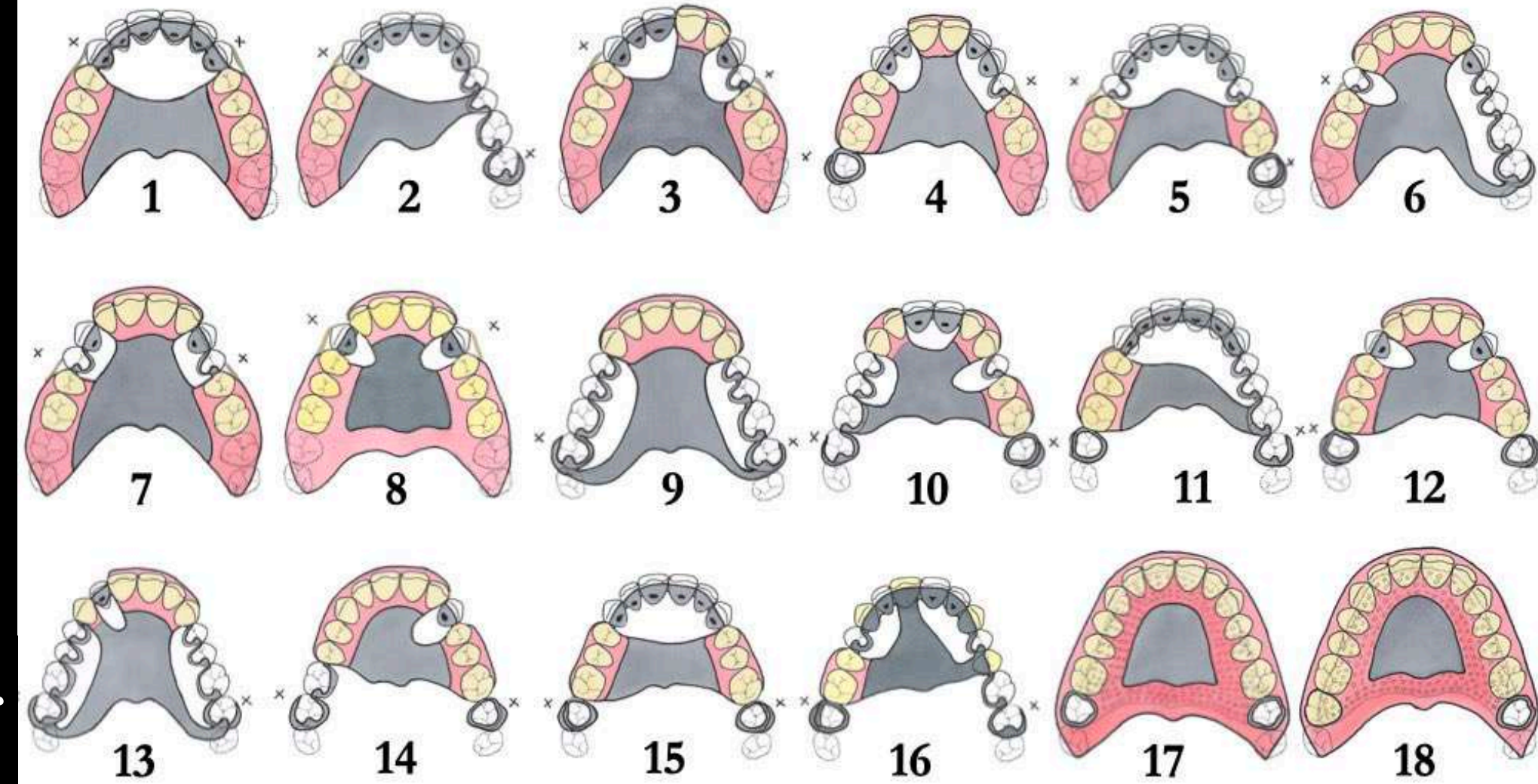


Lowers

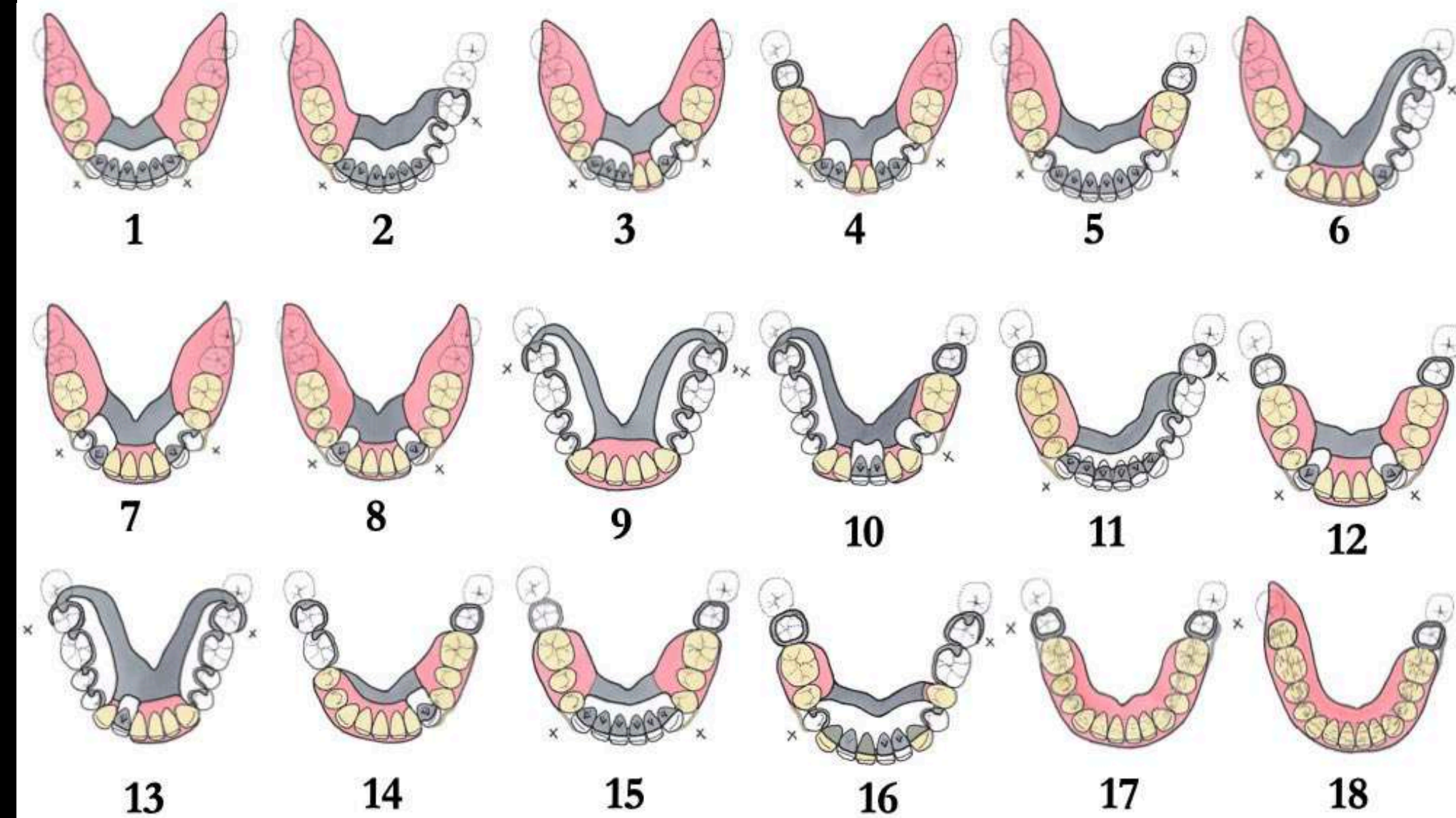


Scandinavian universal designs for **many** patterns of tooth loss  
REMAINING TEETH HAVE **DUBIOUS** PROGNOSIS

Uppers



Lowers



[finlaysutton.co.uk/resources](http://finlaysutton.co.uk/resources)



1. Use the designs

2. Dentures v Implants





1. Use the designs

2. Dentures v Implants

3. Visit the Schottlander stand





Lecture slides:

[finlaysutton.co.uk/resources](http://finlaysutton.co.uk/resources)

