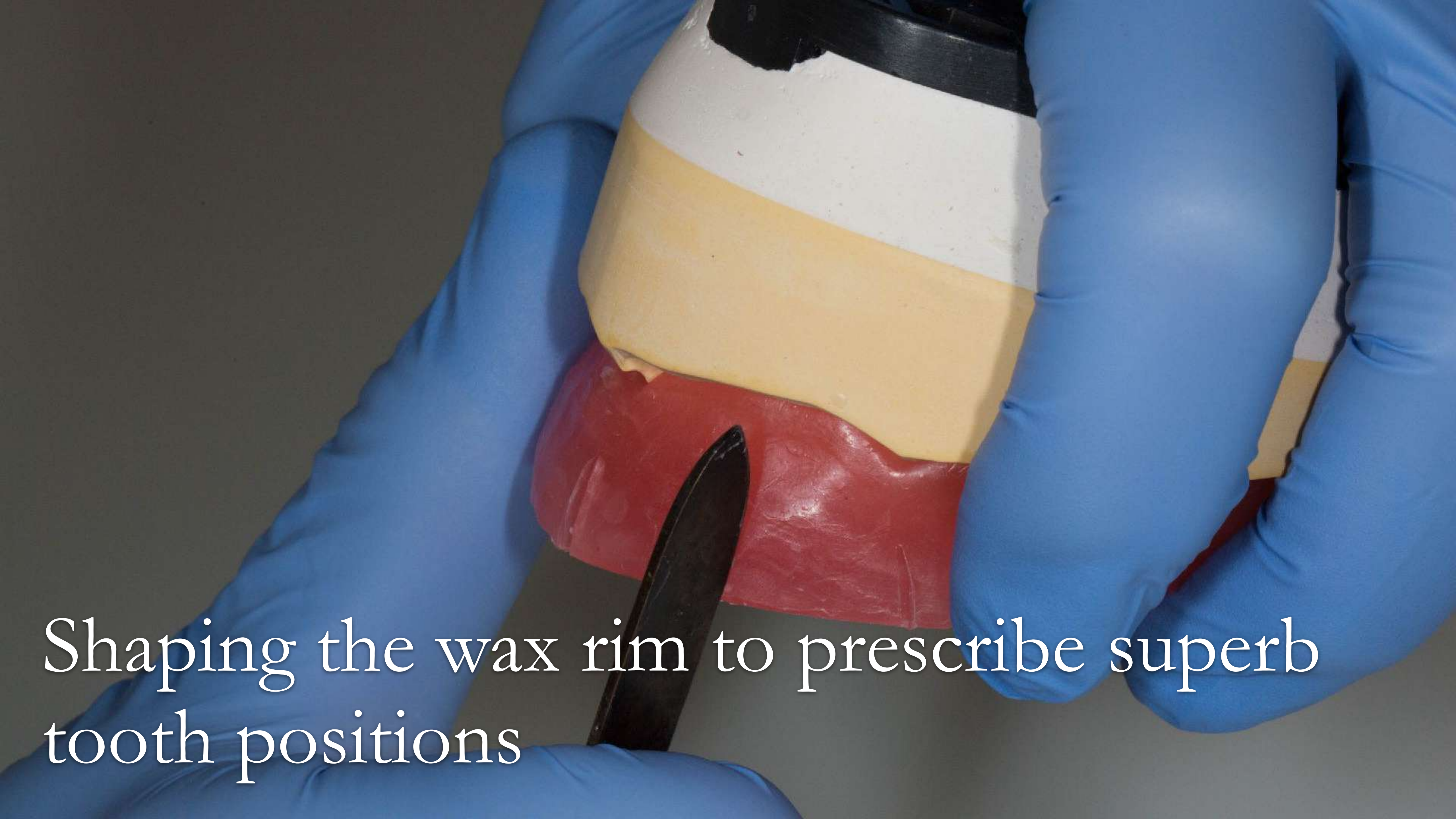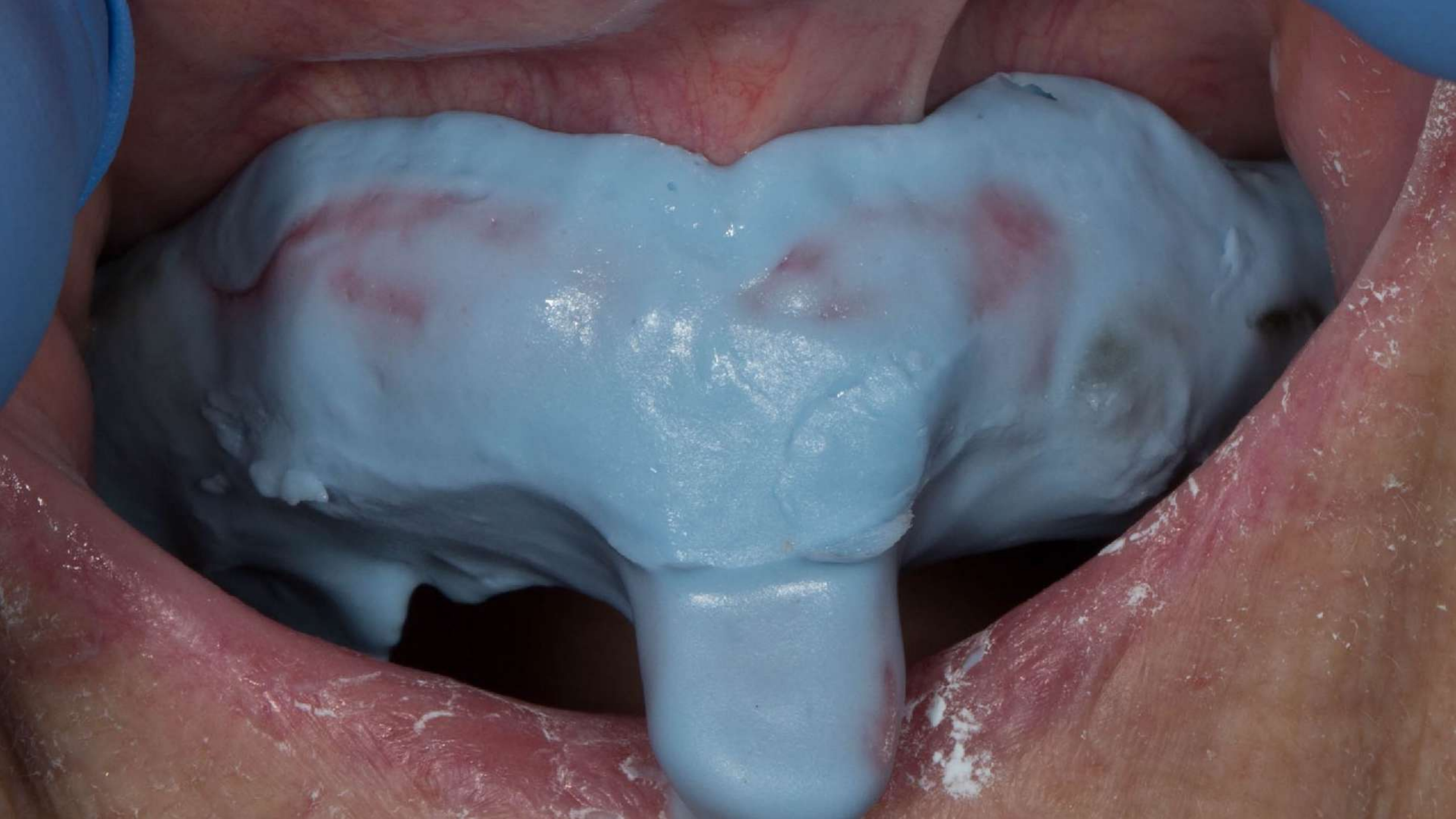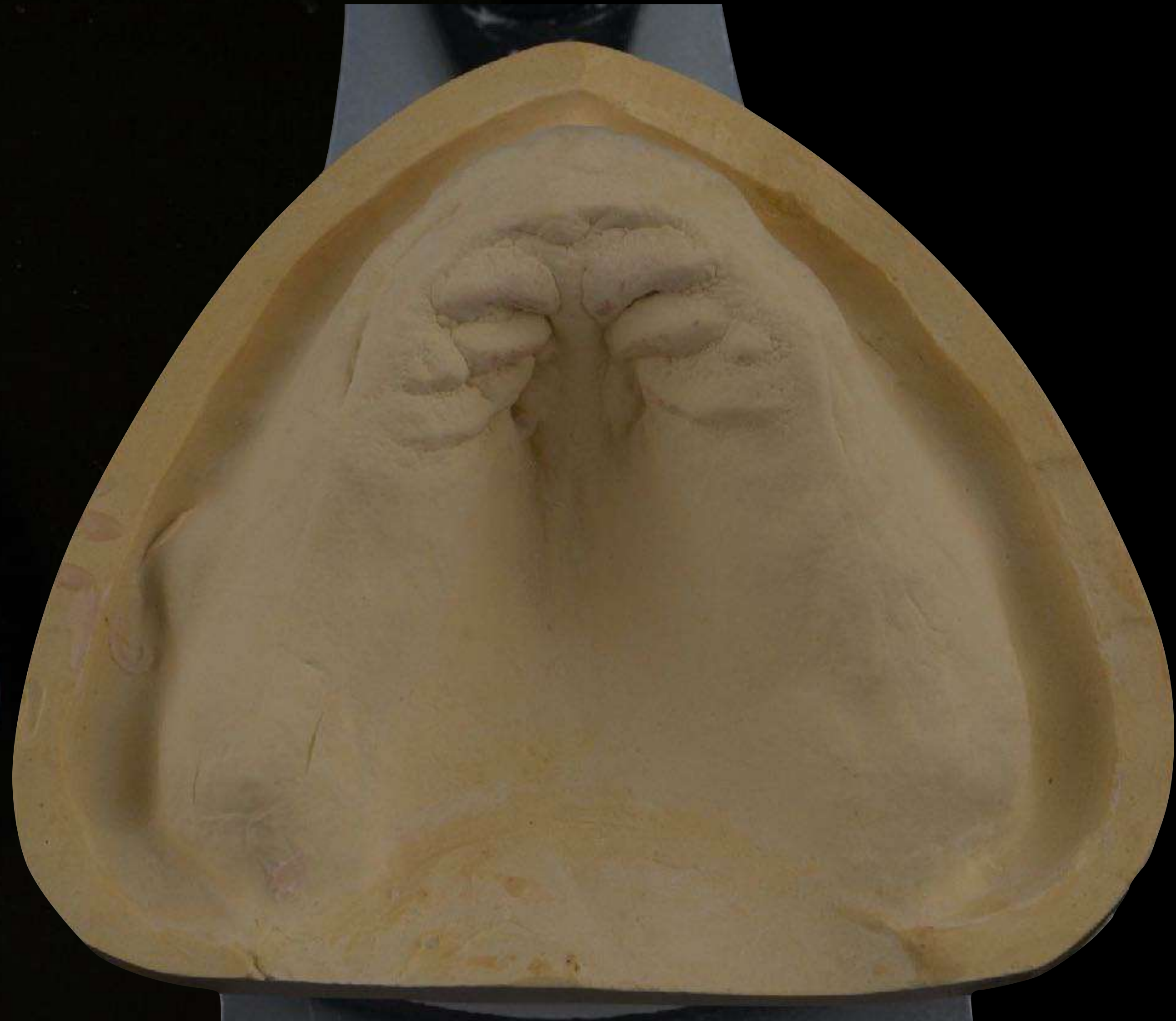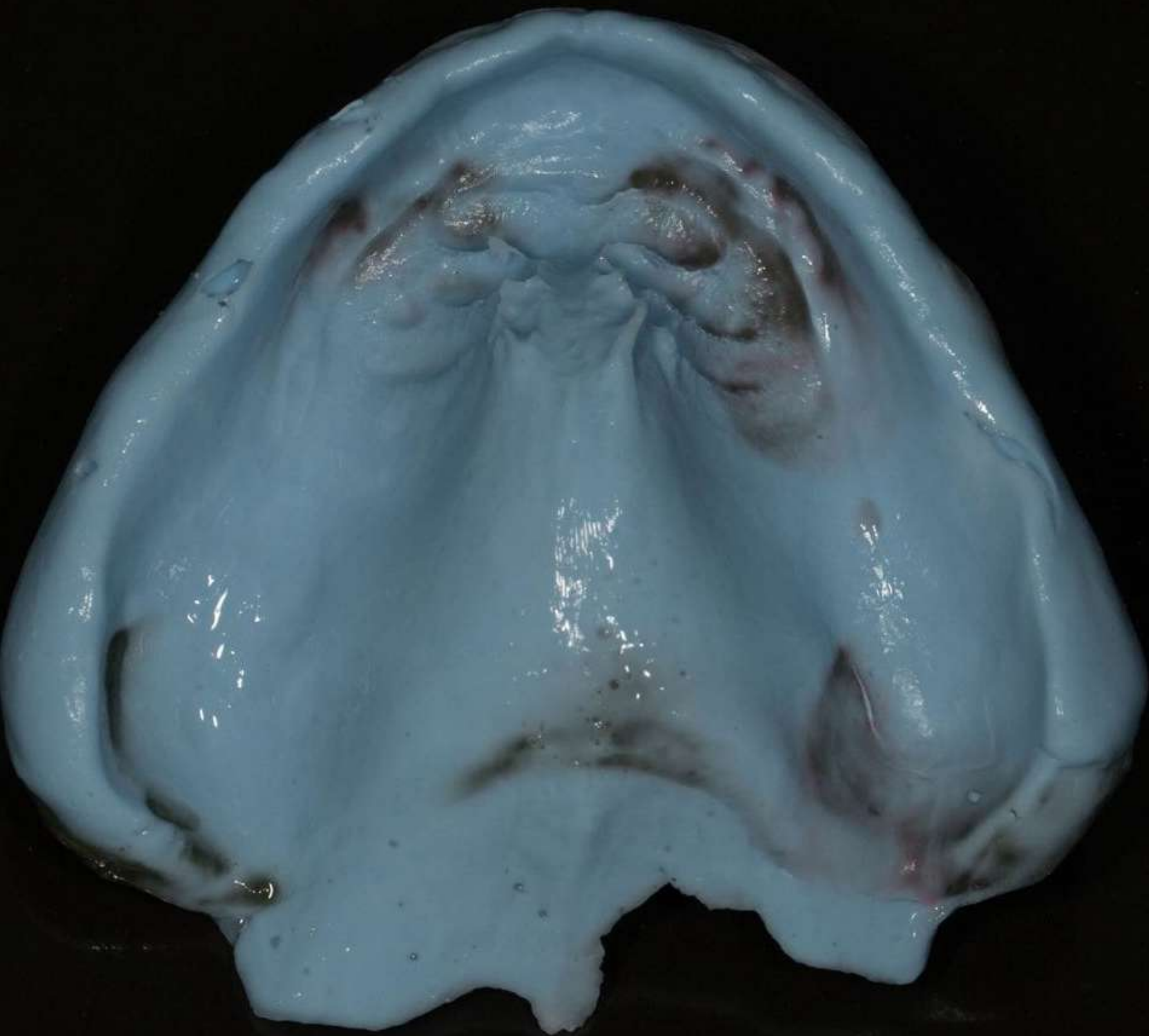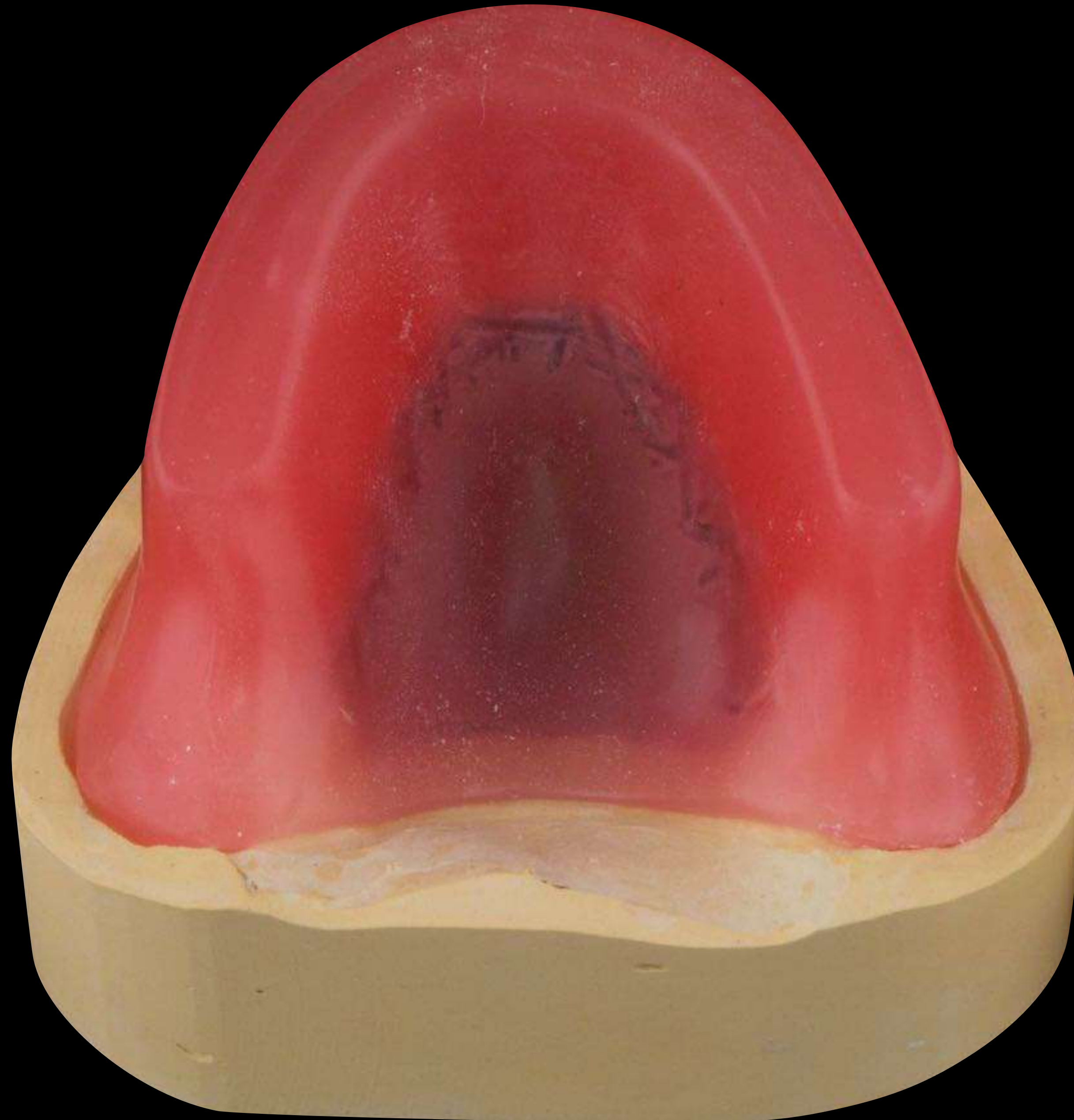


Shaping the wax rim to prescribe superb
tooth positions

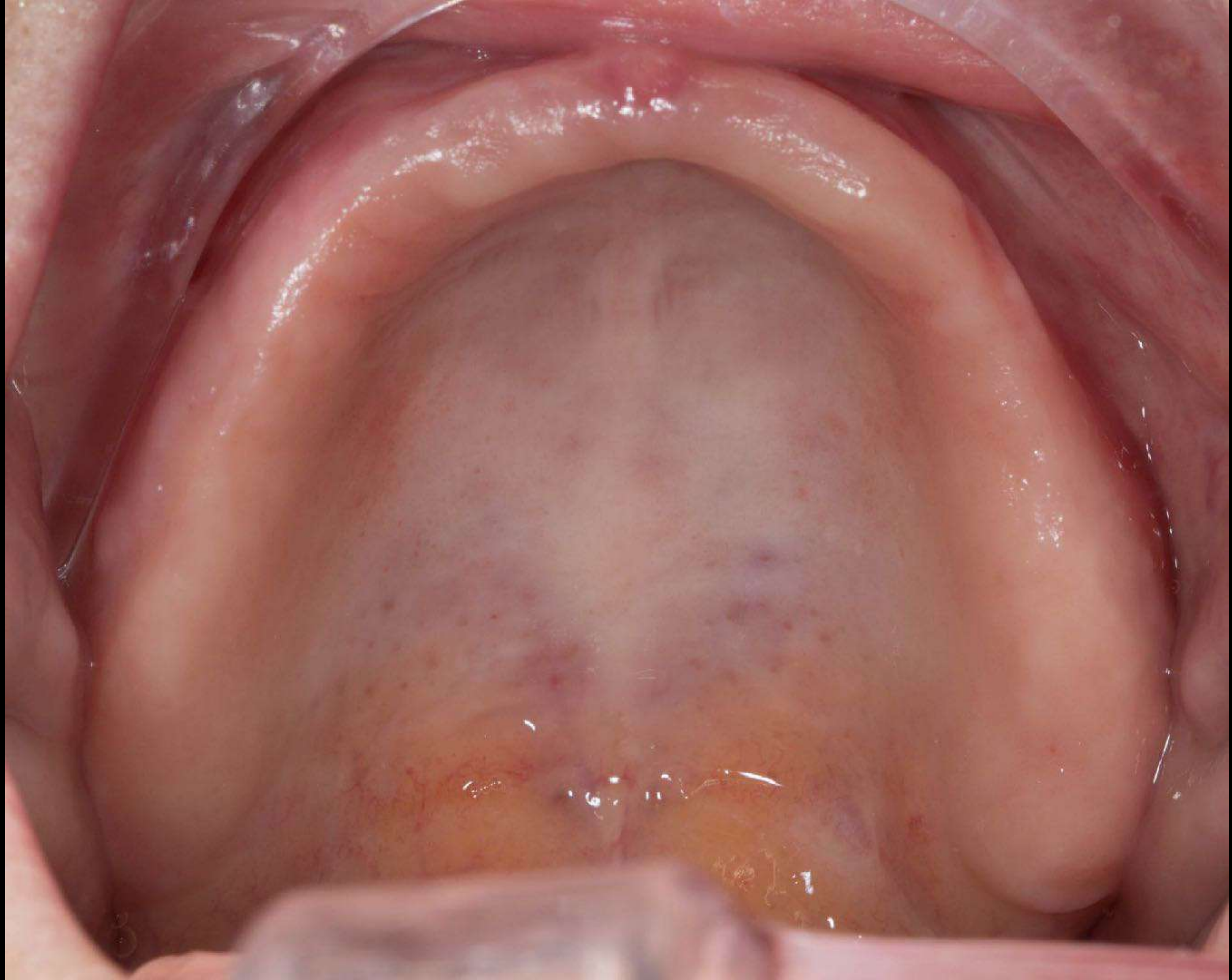


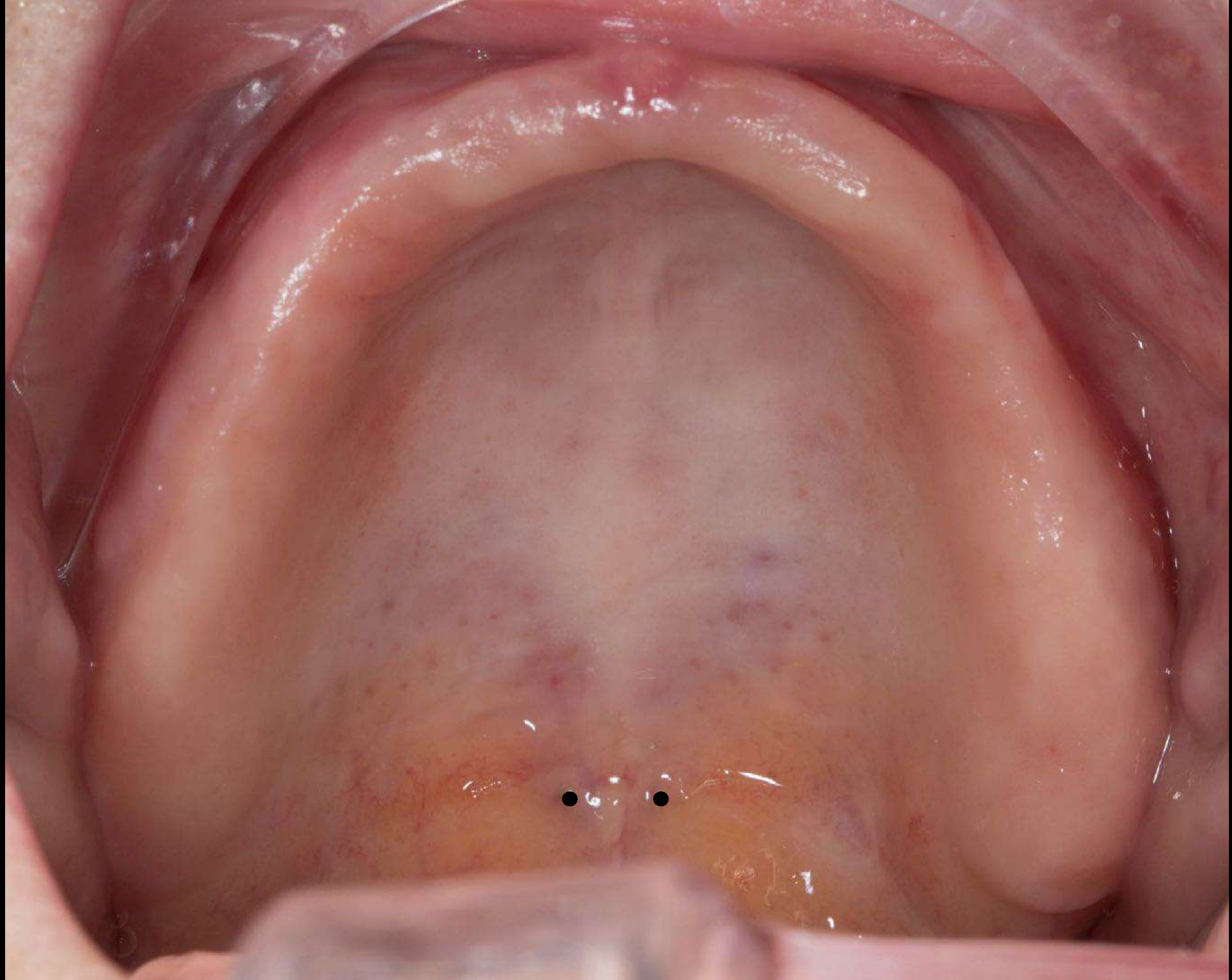


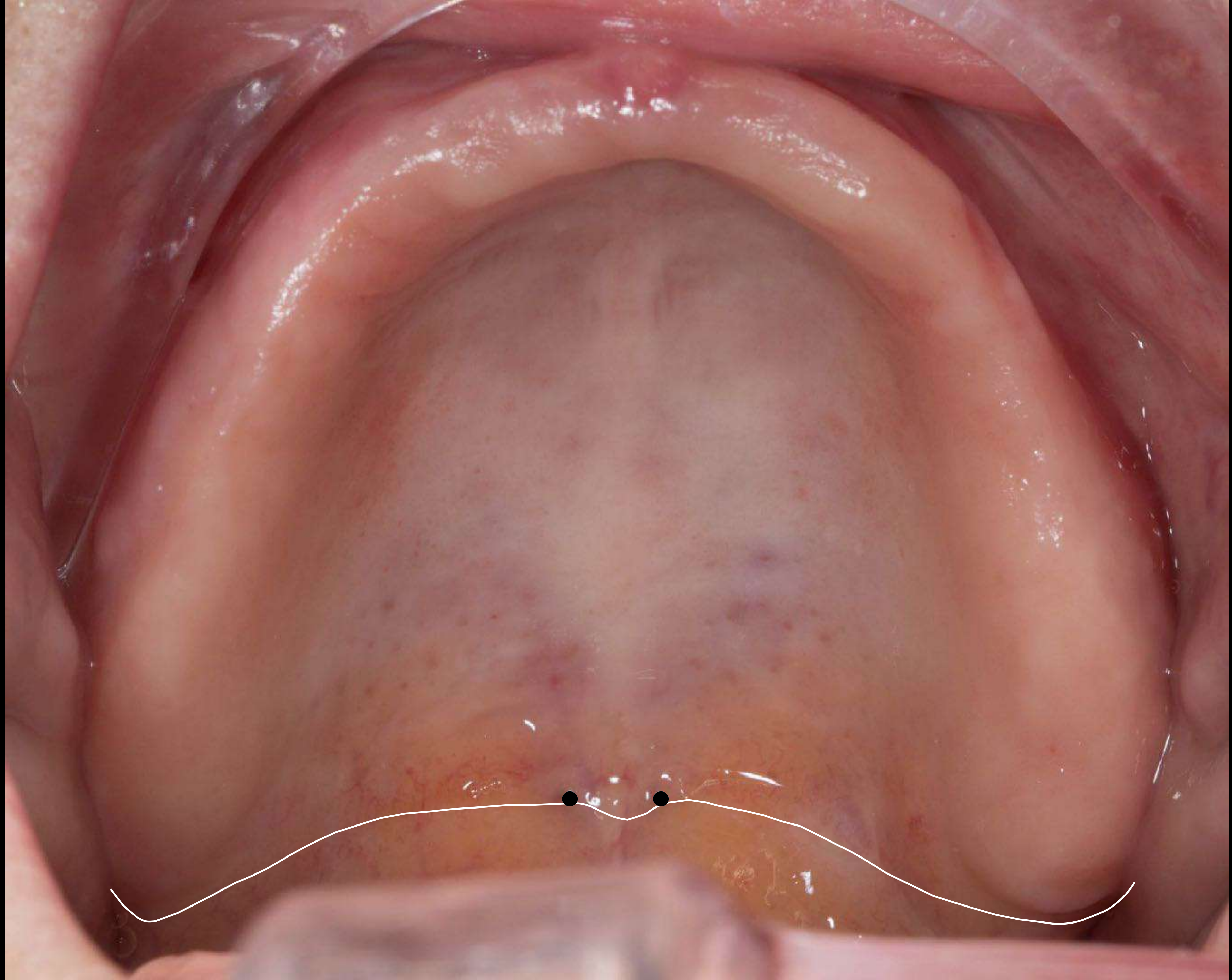
Registration stage

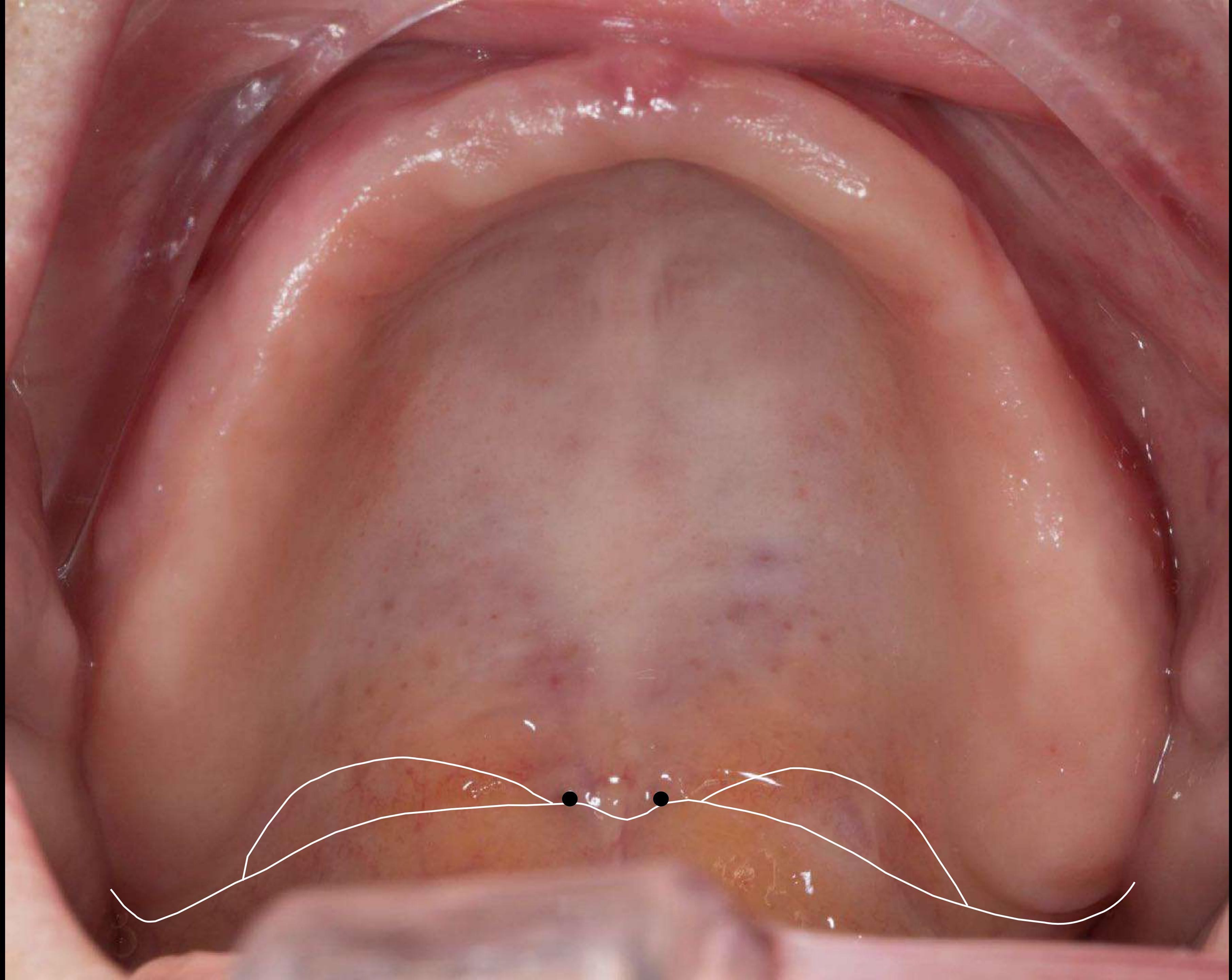


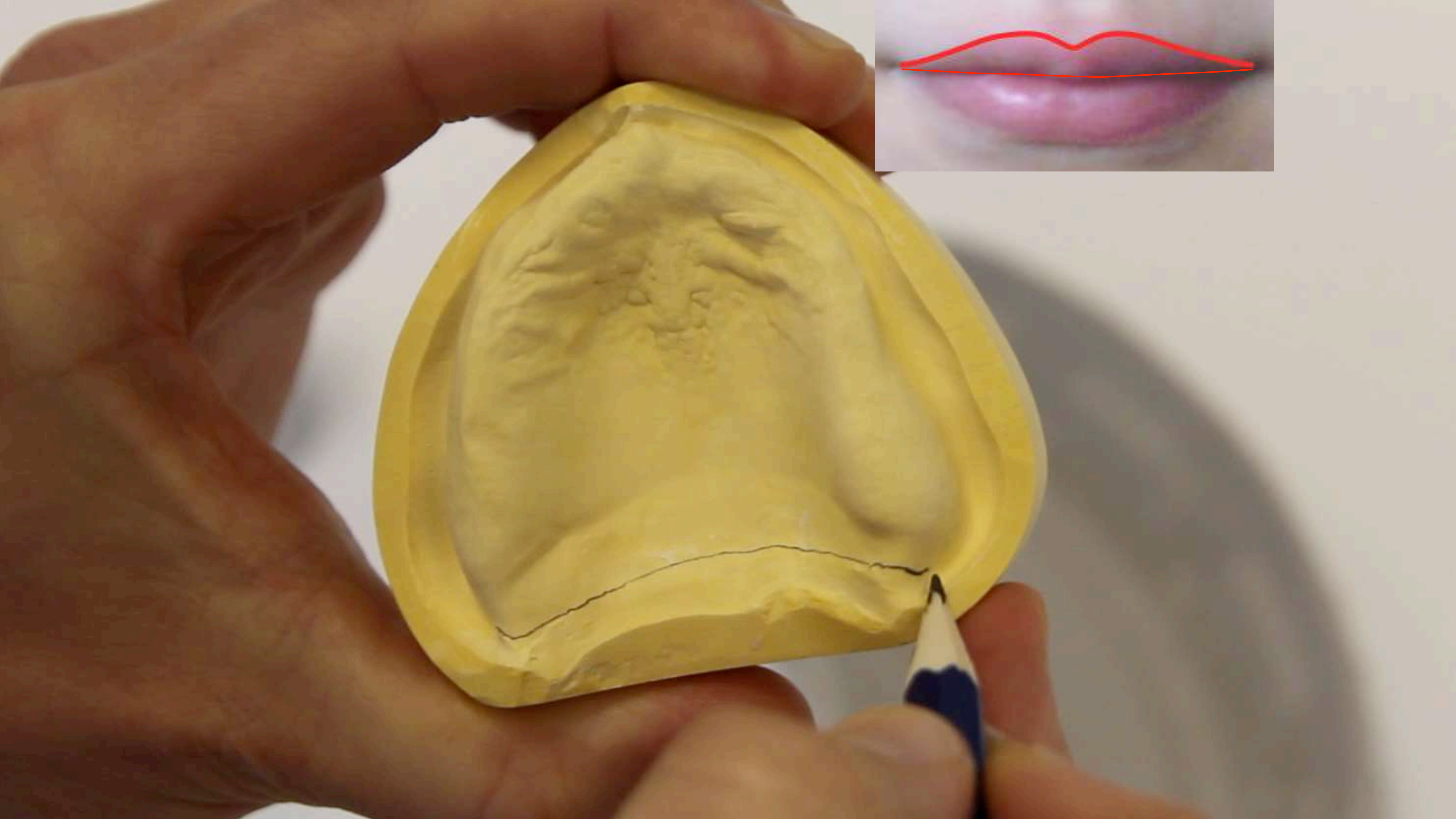
Wax rim

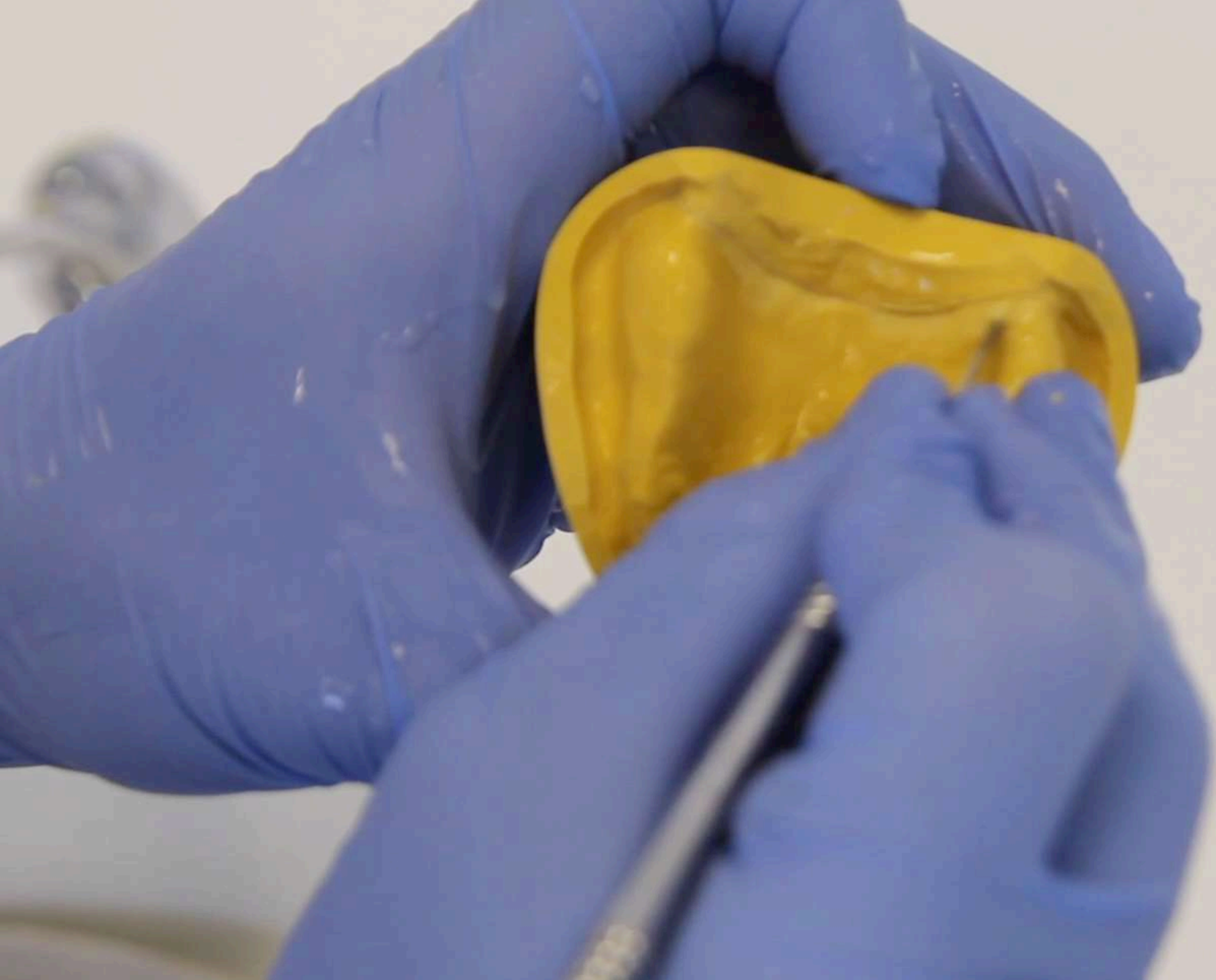


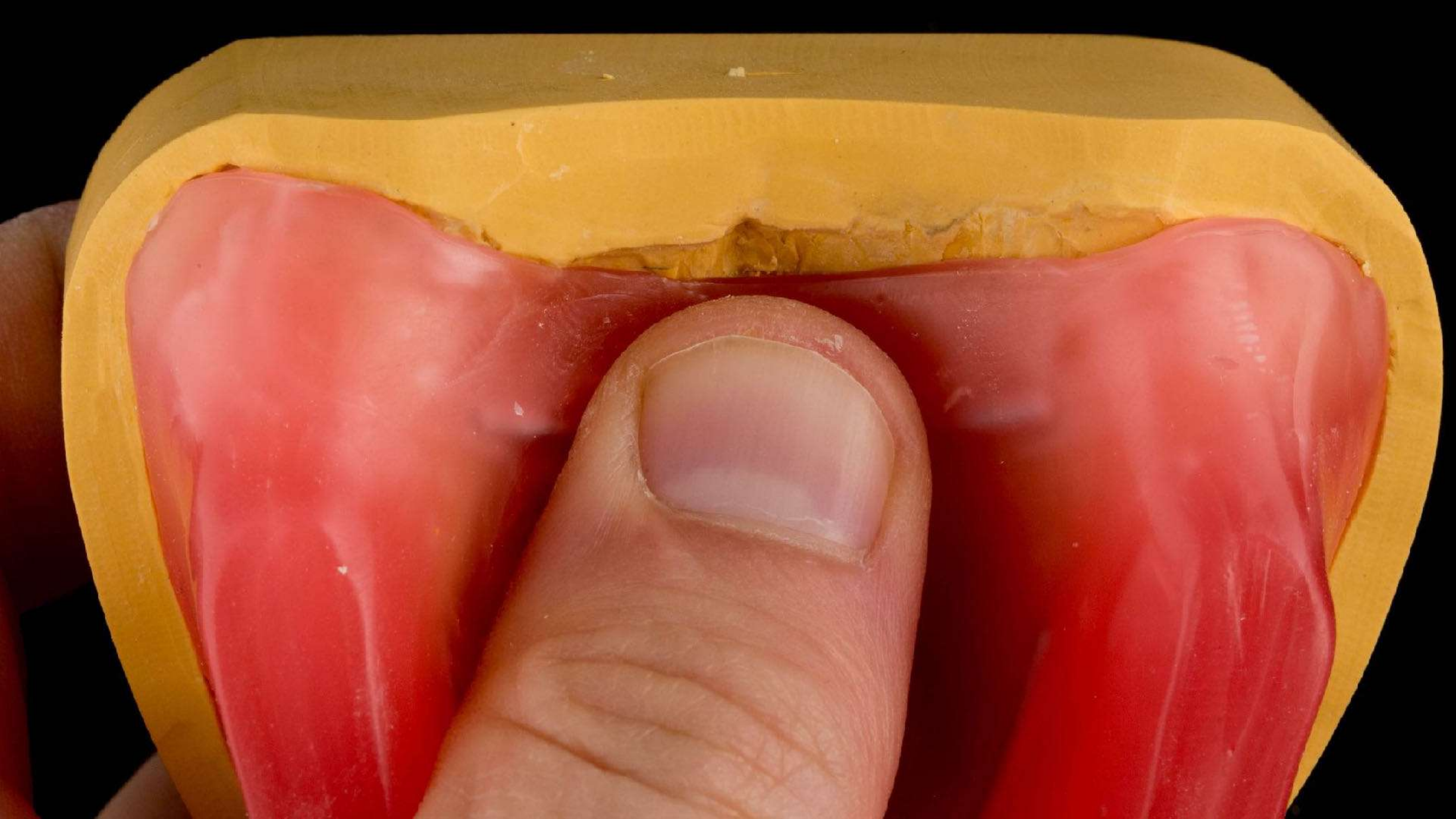
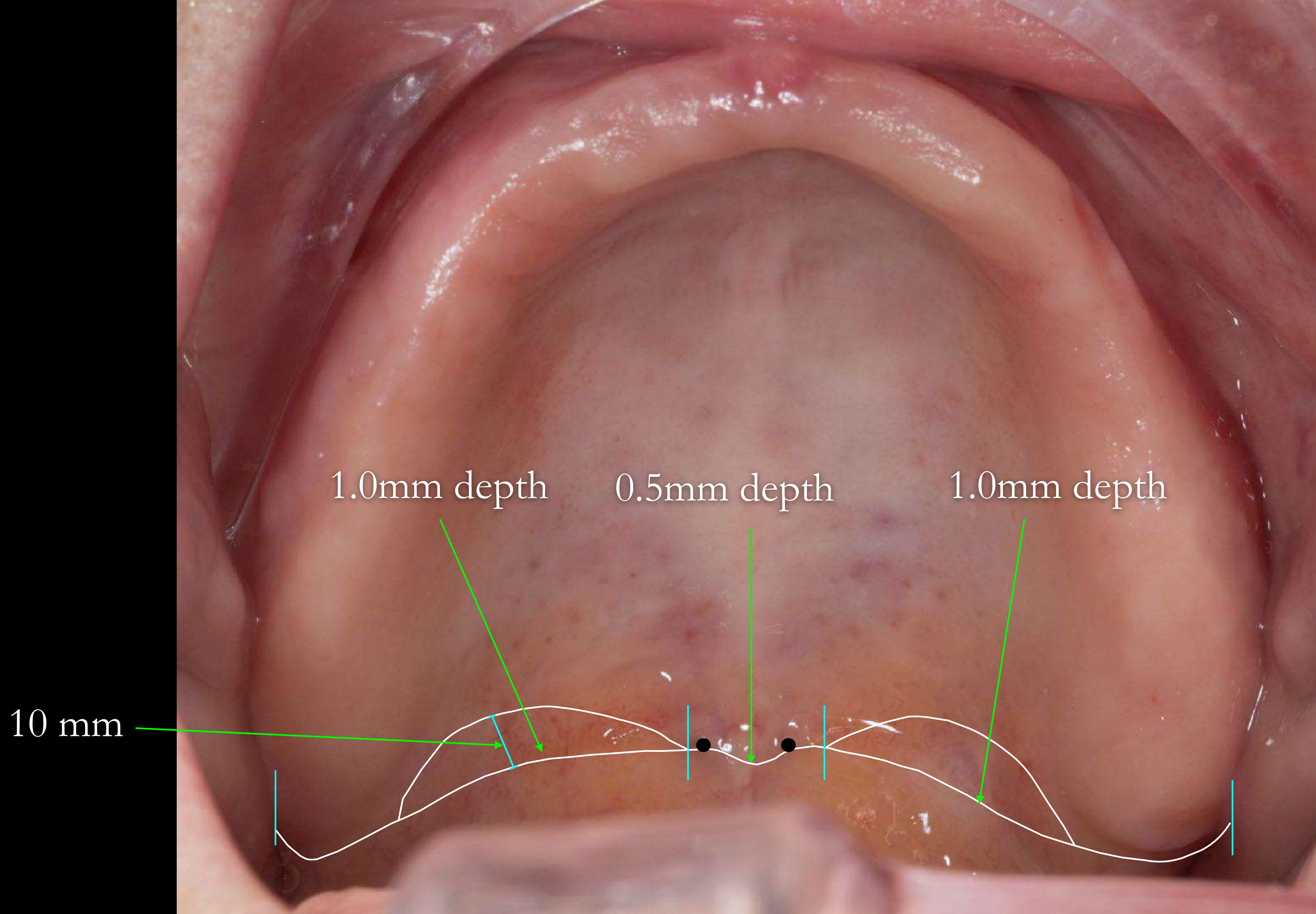












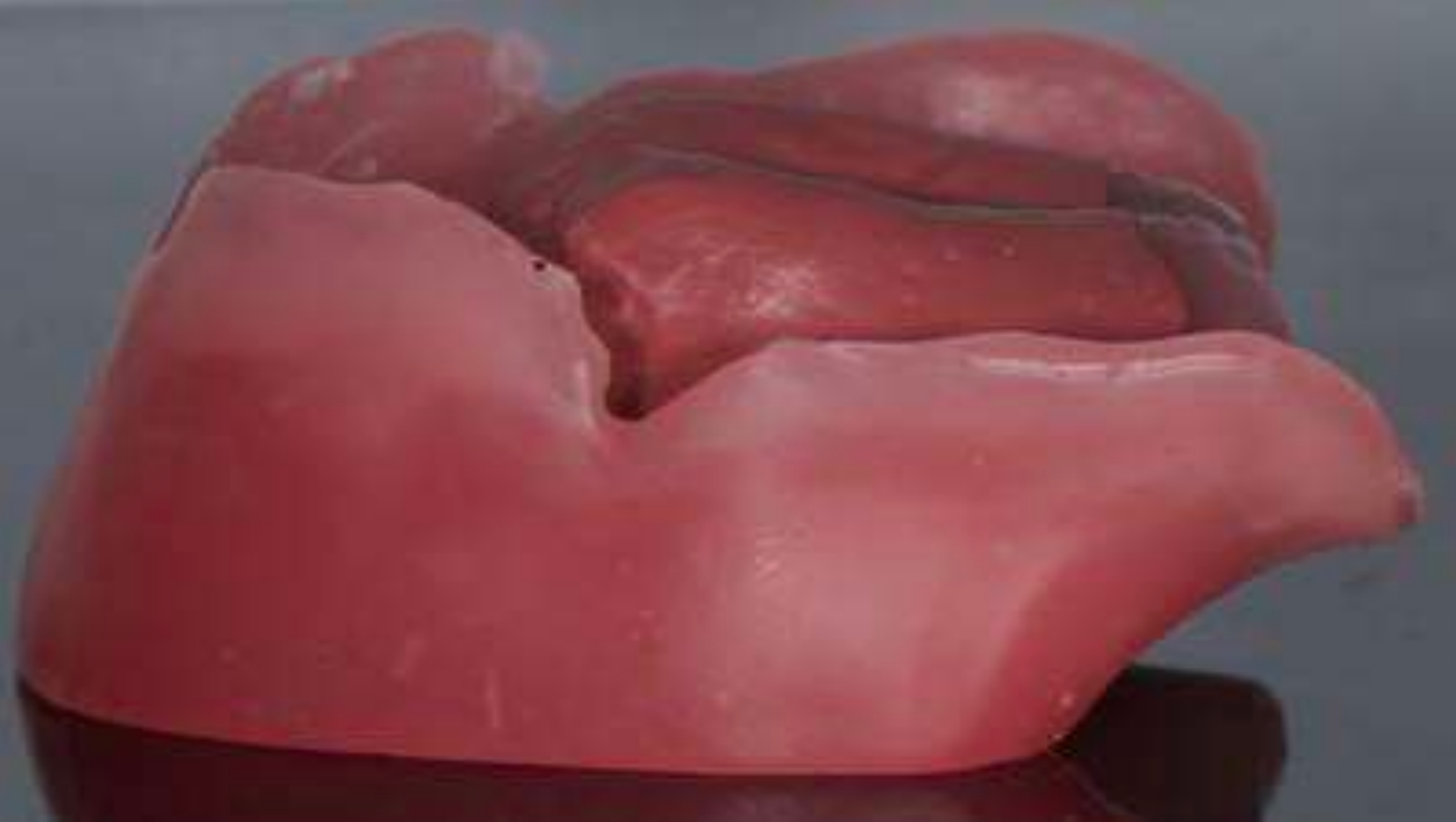1.0mm depth

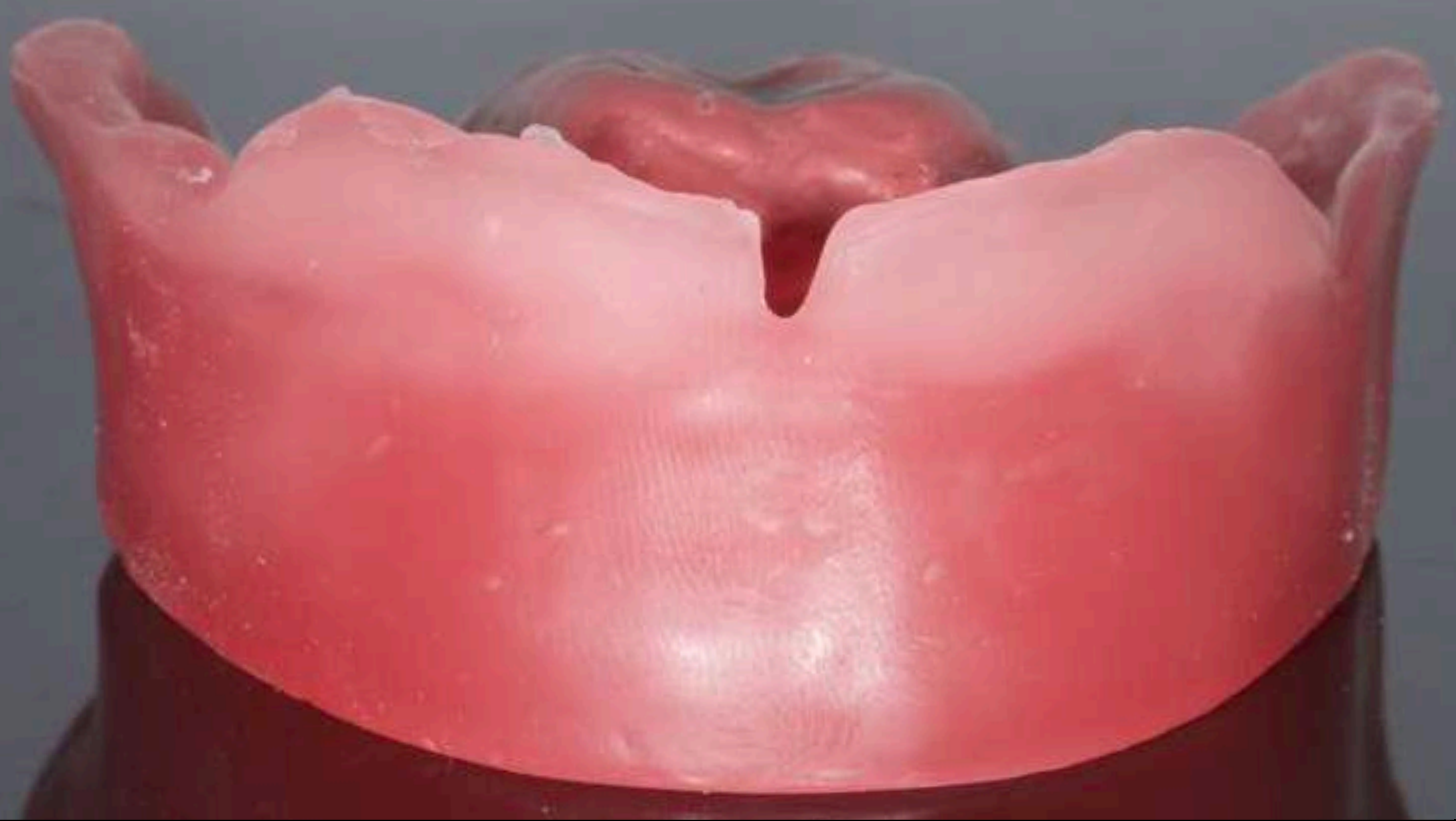
0.5mm depth

1.0mm depth

10 mm





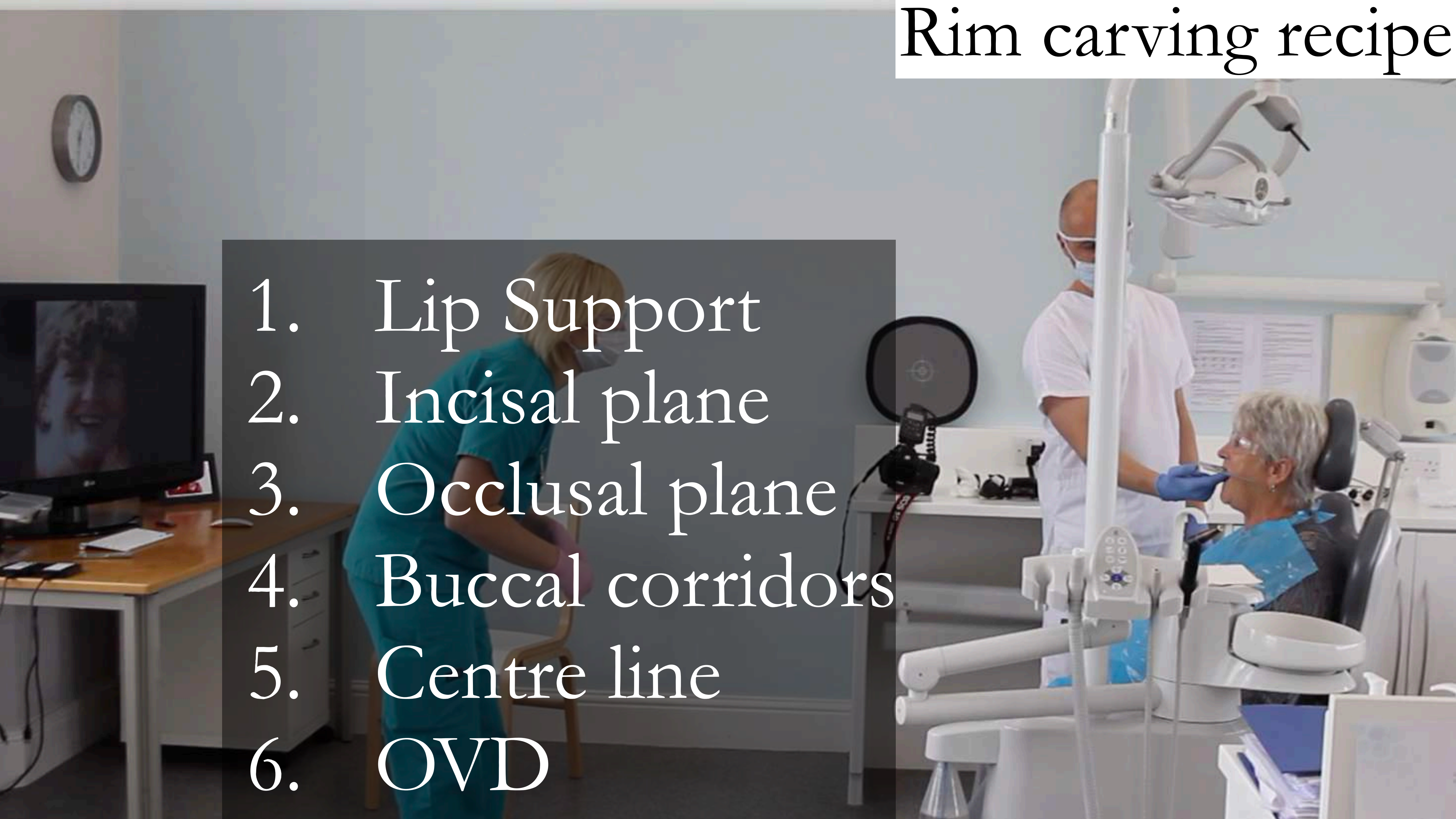


Rim carving recipe

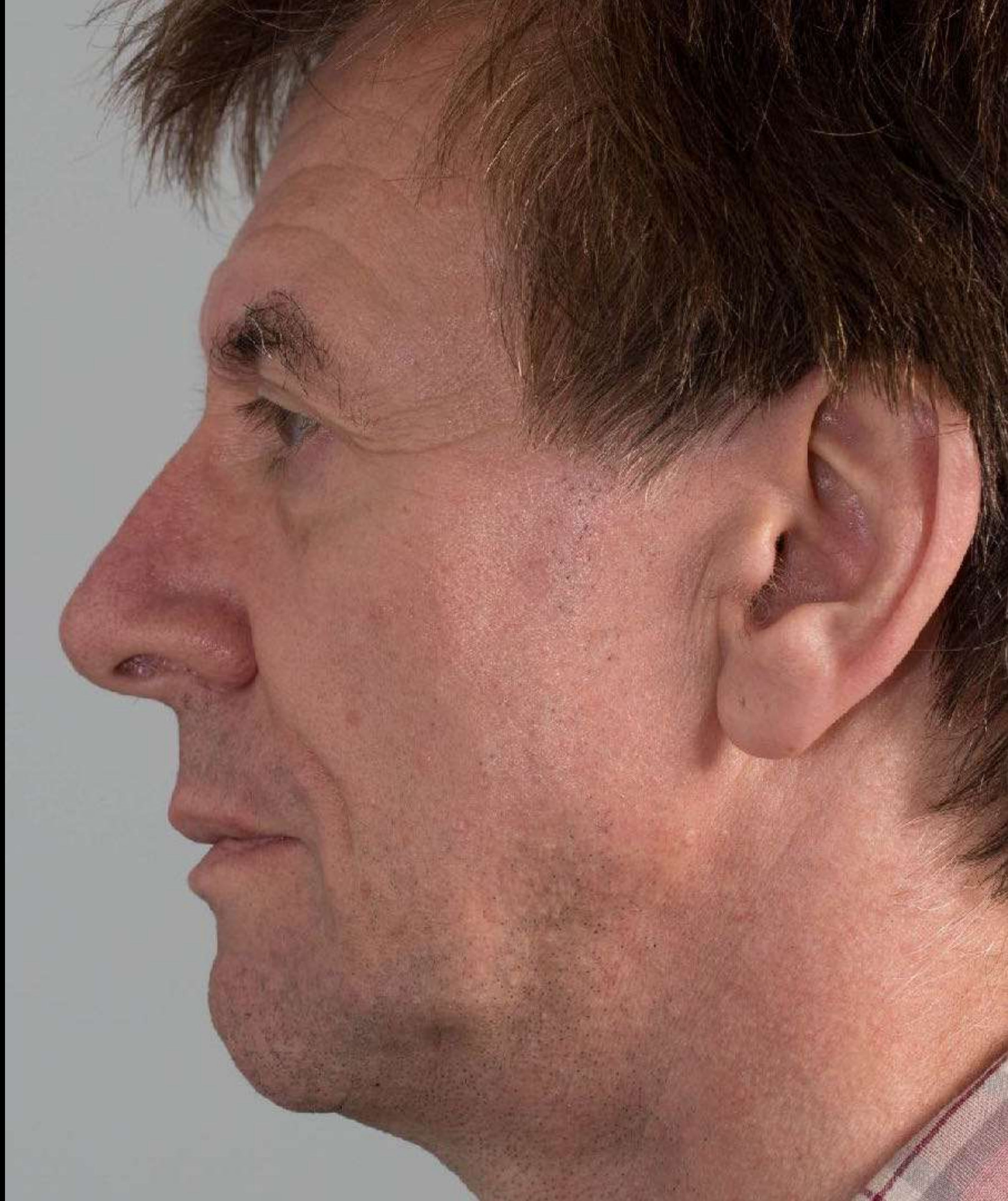


Rim carving recipe

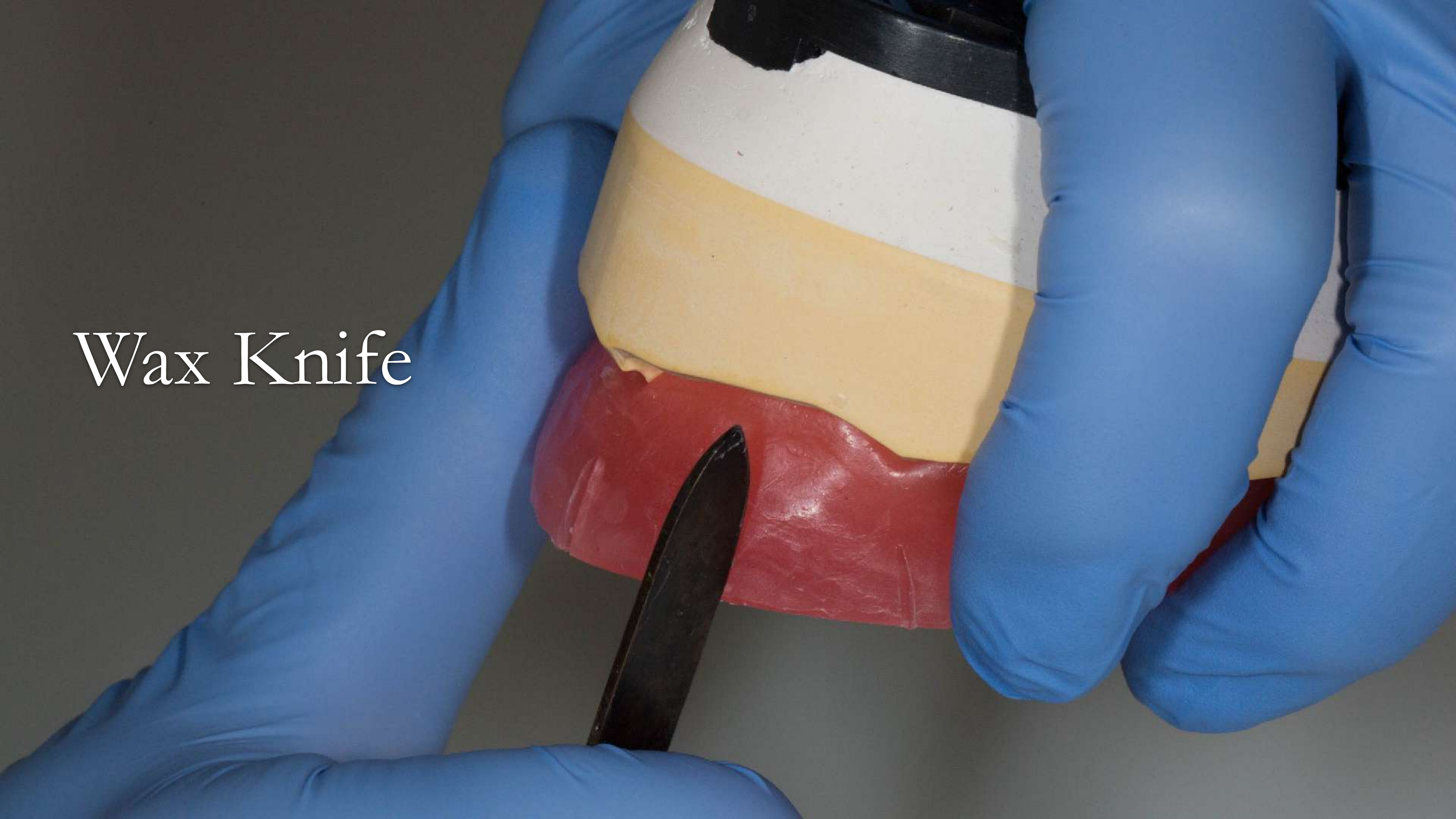
1. Lip Support
2. Incisal plane
3. Occlusal plane
4. Buccal corridors
5. Centre line
6. OVD



1. Lip Support

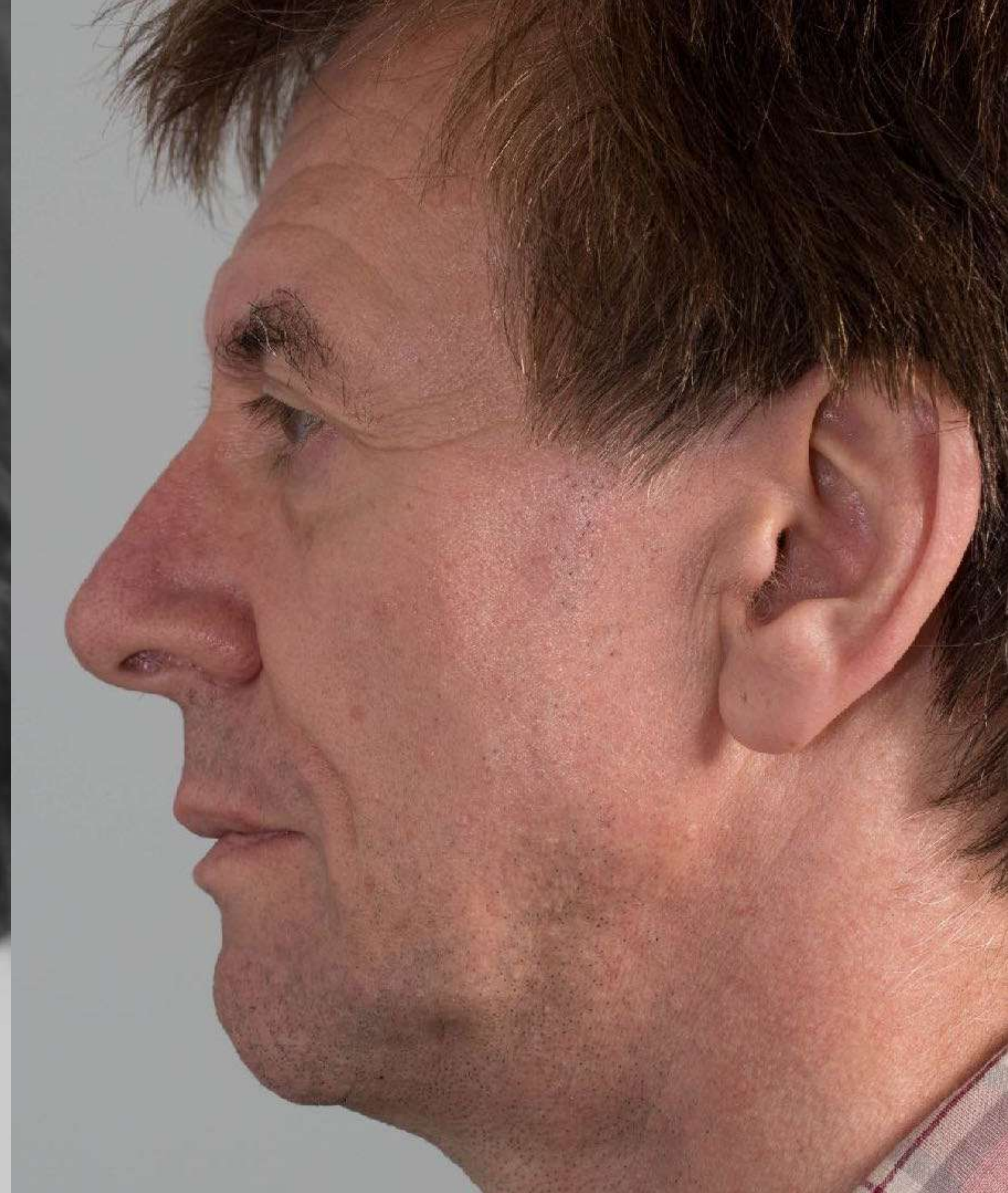

Wax Knife

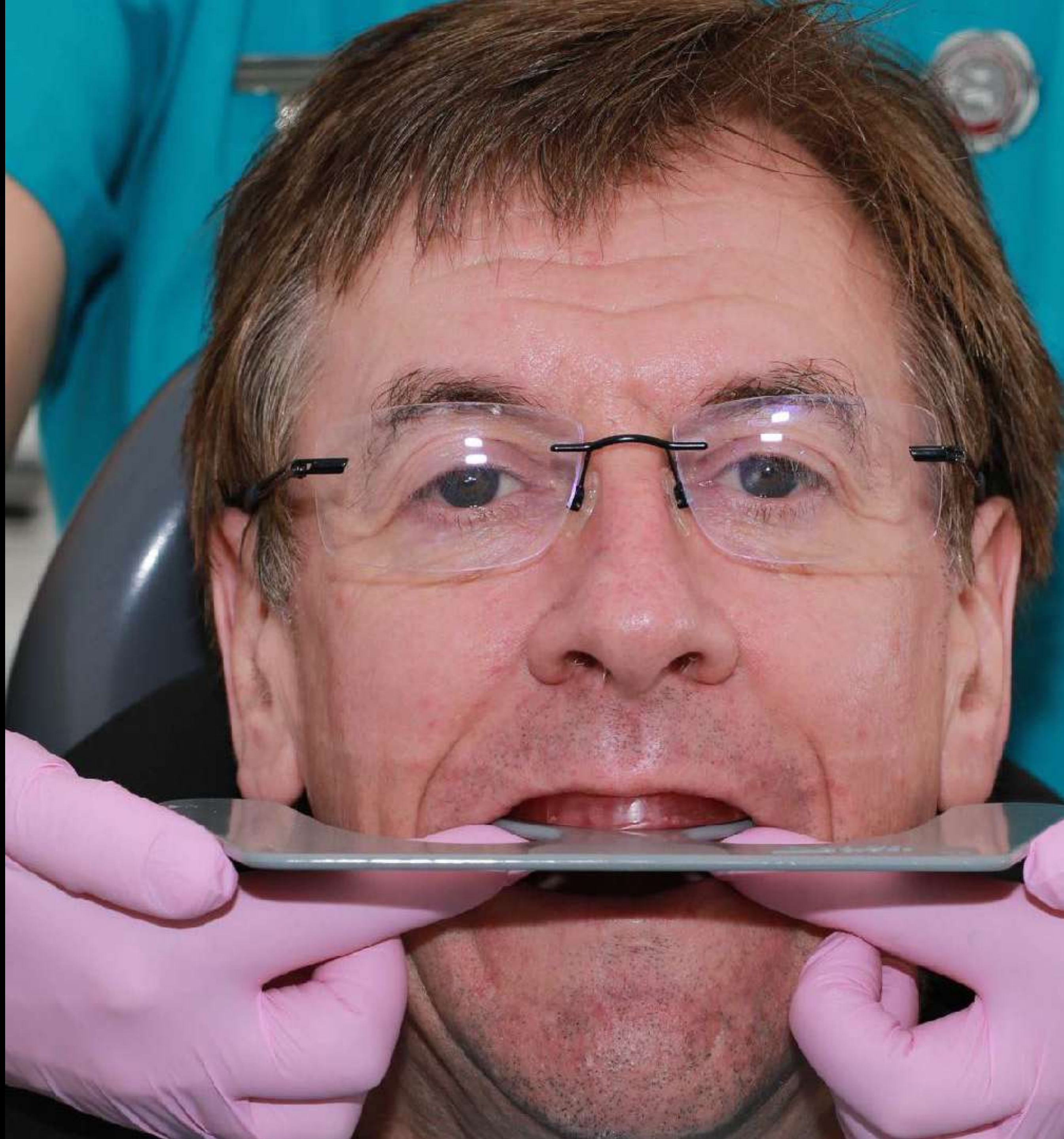



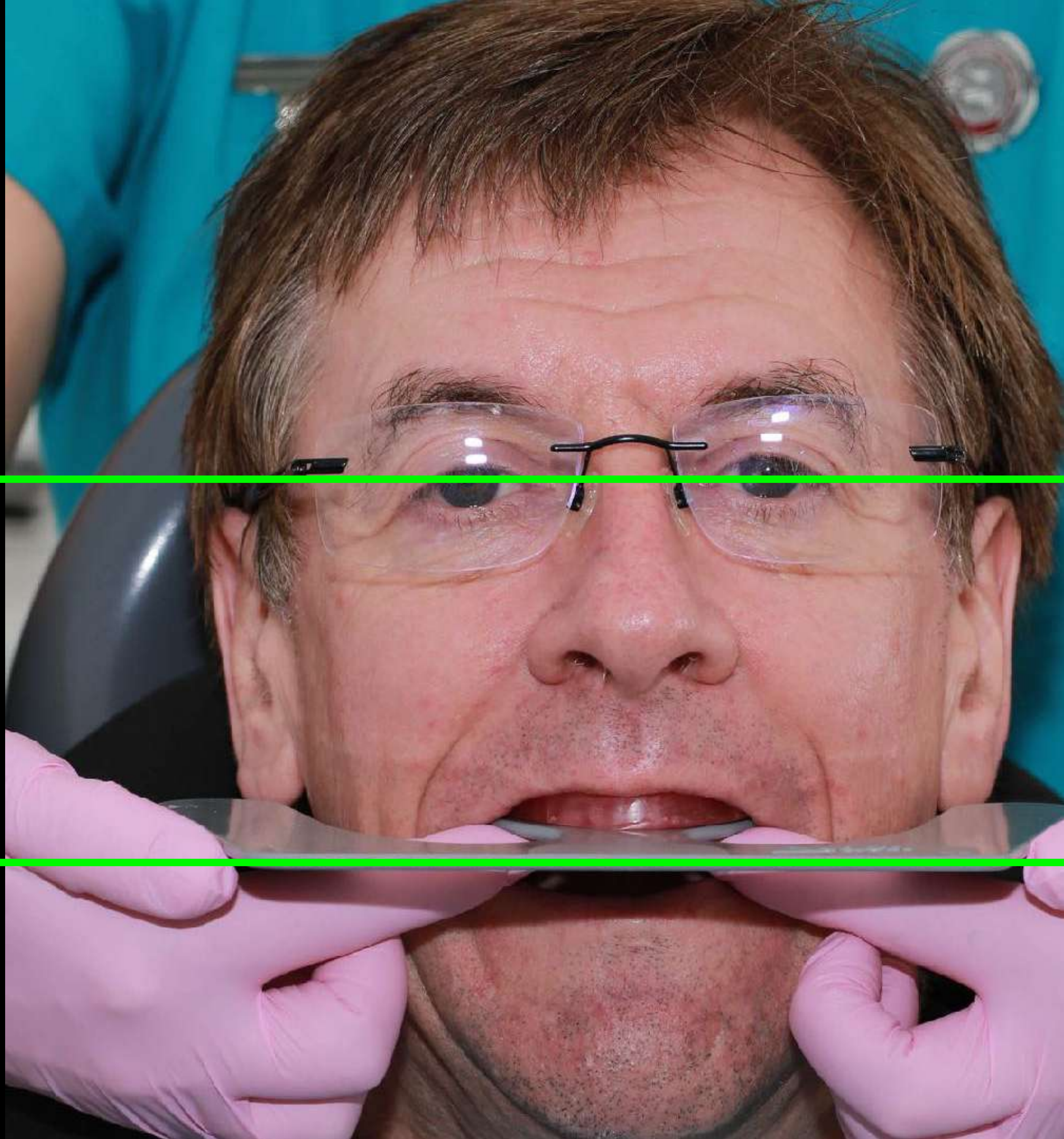
1. Lip Support



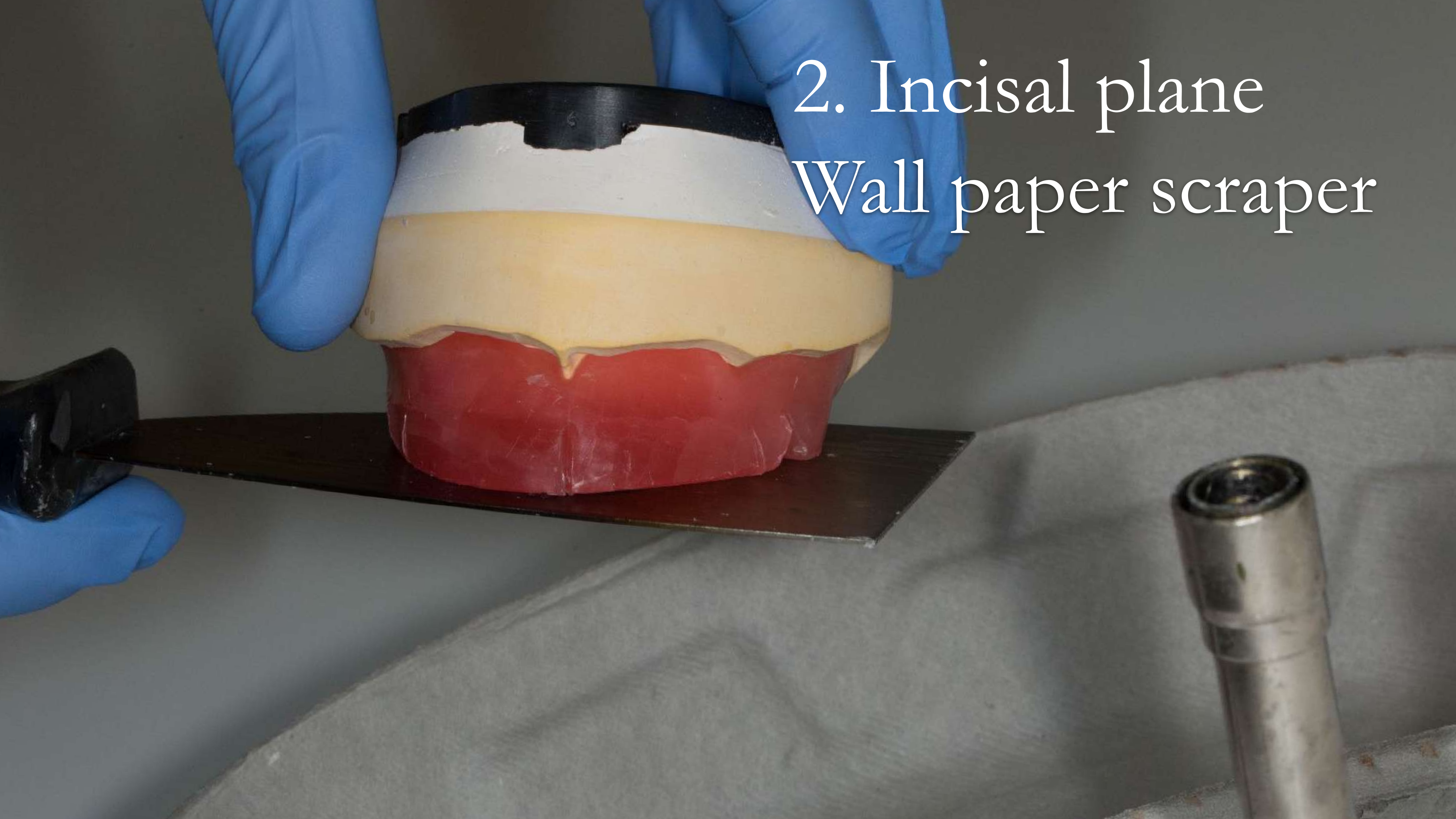2. Incisal plane



2. Incisal plane

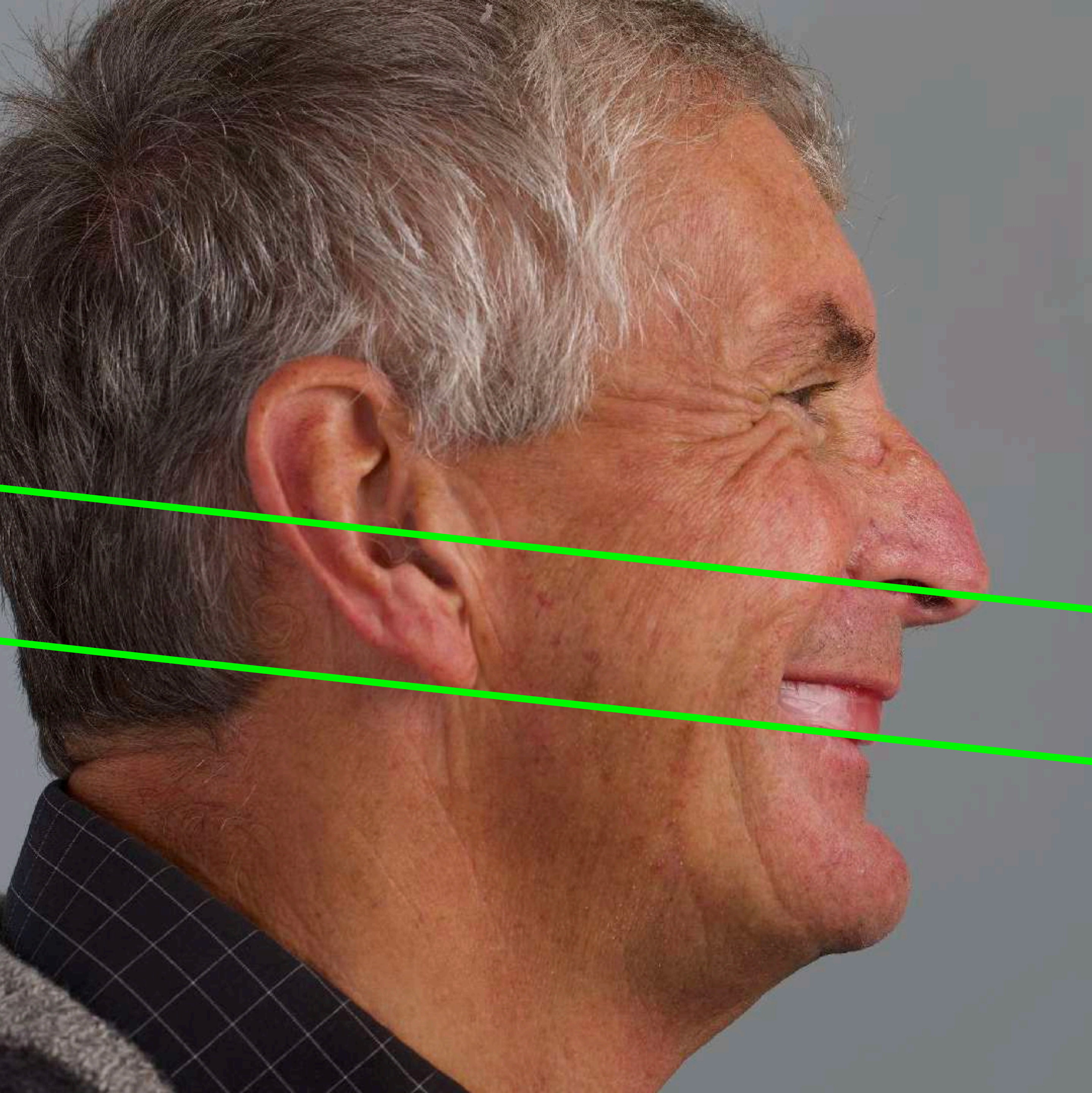


2. Incisal plane Wall paper scraper



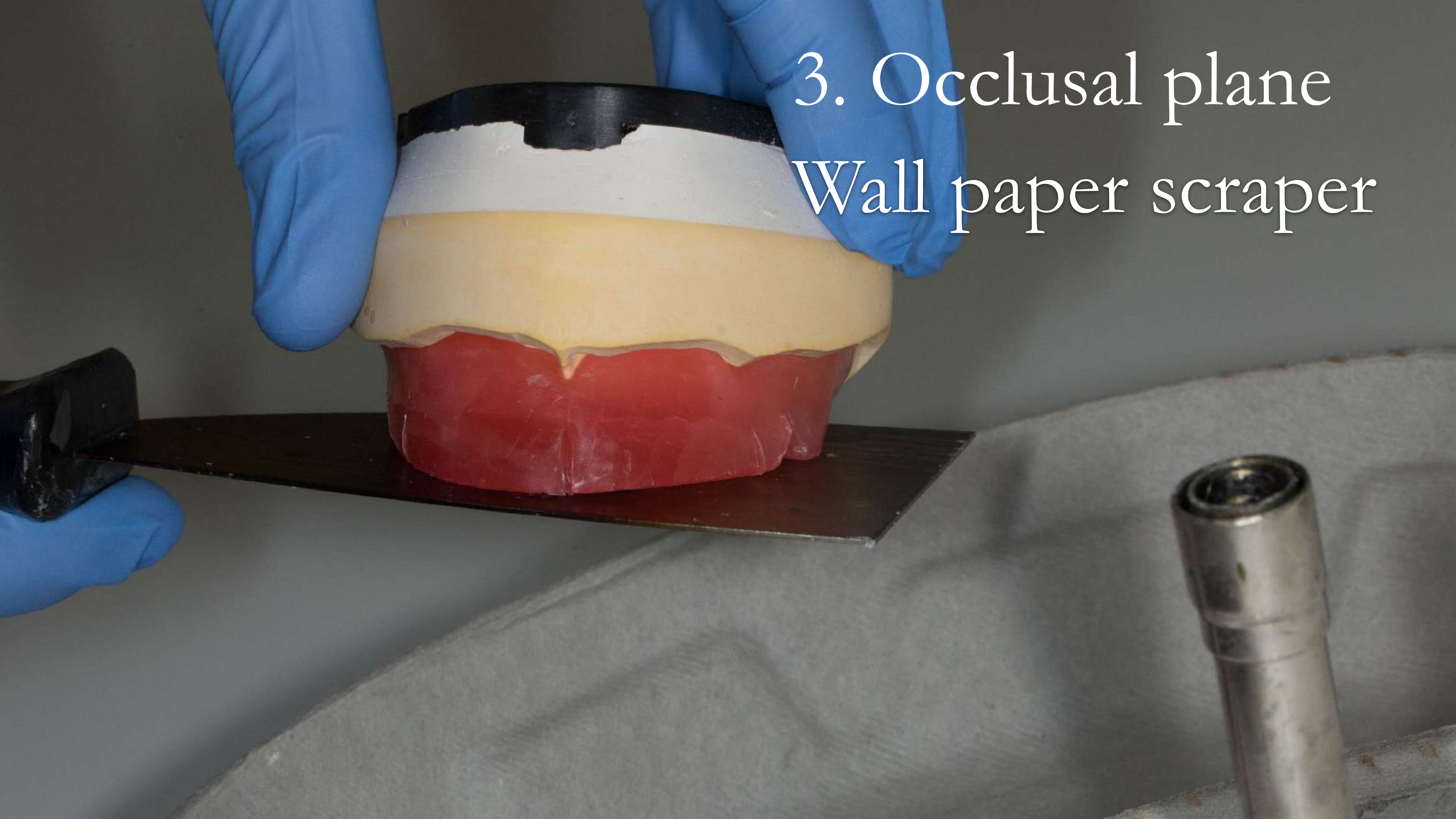


3. Occlusal plane



3. Occlusal plane

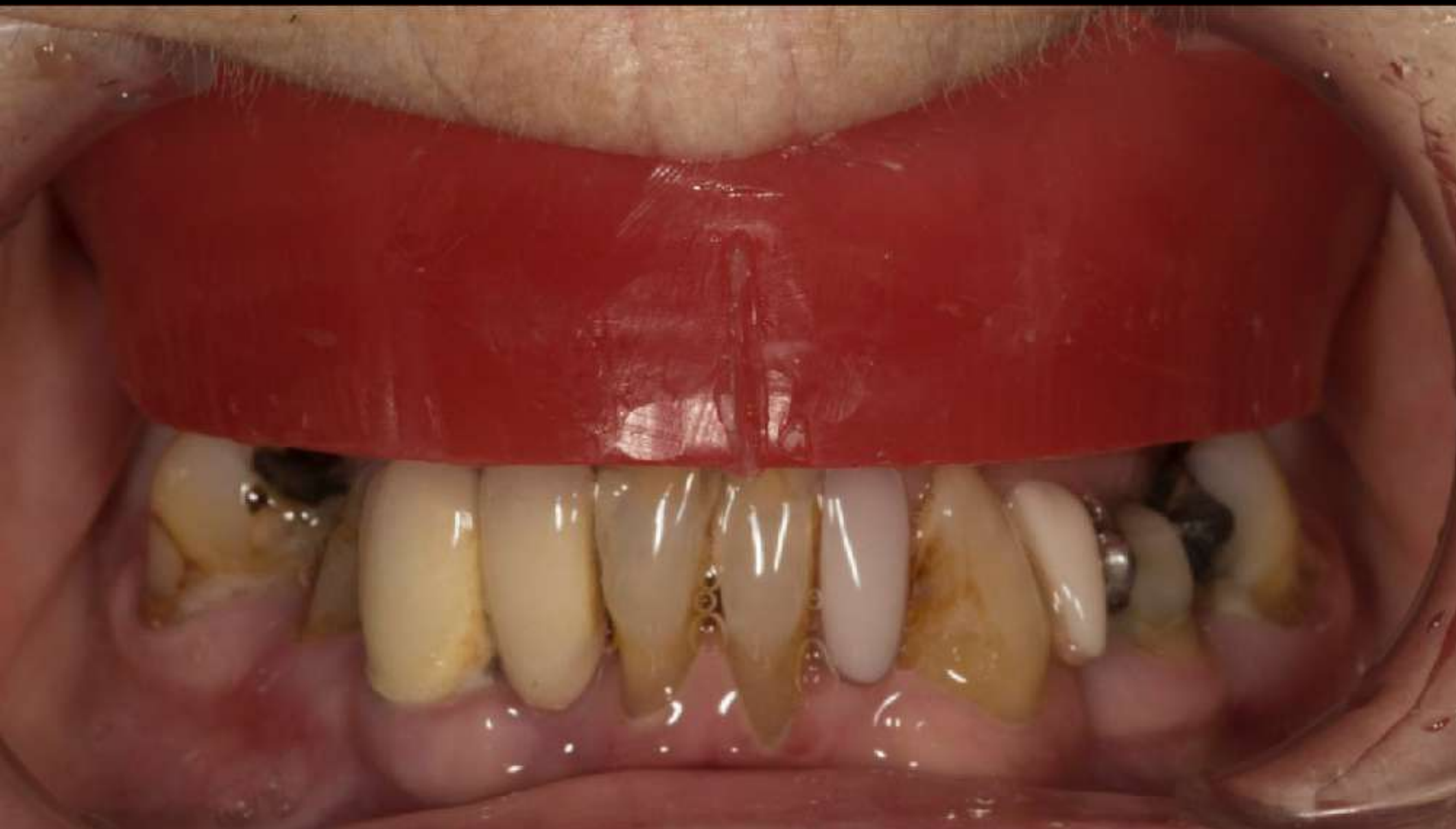3. Occlusal plane Wall paper scraper

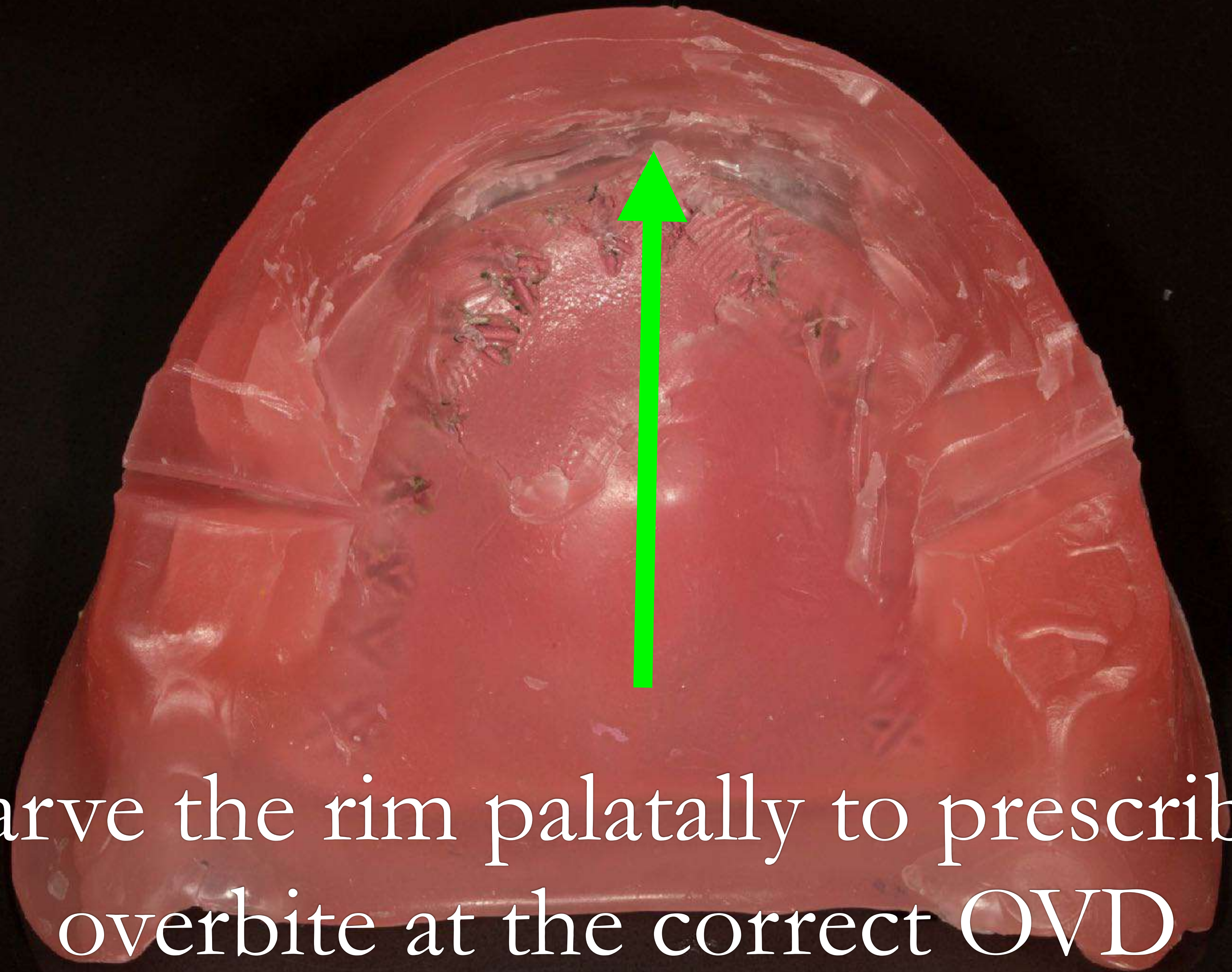




4 & 5 Buccal corridors and centre line

6. Occlusal Vertical Dimension





6. Carve the rim palatally to prescribe an overbite at the correct OVD



Teeth apart

A close-up photograph of a dental wax rim on a maxillary model. The wax is a reddish-pink color and is being shaped around a row of natural teeth. The teeth are slightly separated, as indicated by the text 'Teeth apart'.

6. Carve the rim palatally to prescribe an overbite at the correct OVD

A close-up photograph of a dental wax rim being fitted onto a patient's teeth. The wax is a reddish-pink color and has a textured surface. The teeth are visible below the rim, showing some wear and discoloration. The text "Teeth together" is overlaid in white at the top of the image.

Teeth together

6. Carve the rim palatally to prescribe an overbite at the correct OVD

The “must have” photo for Rowan



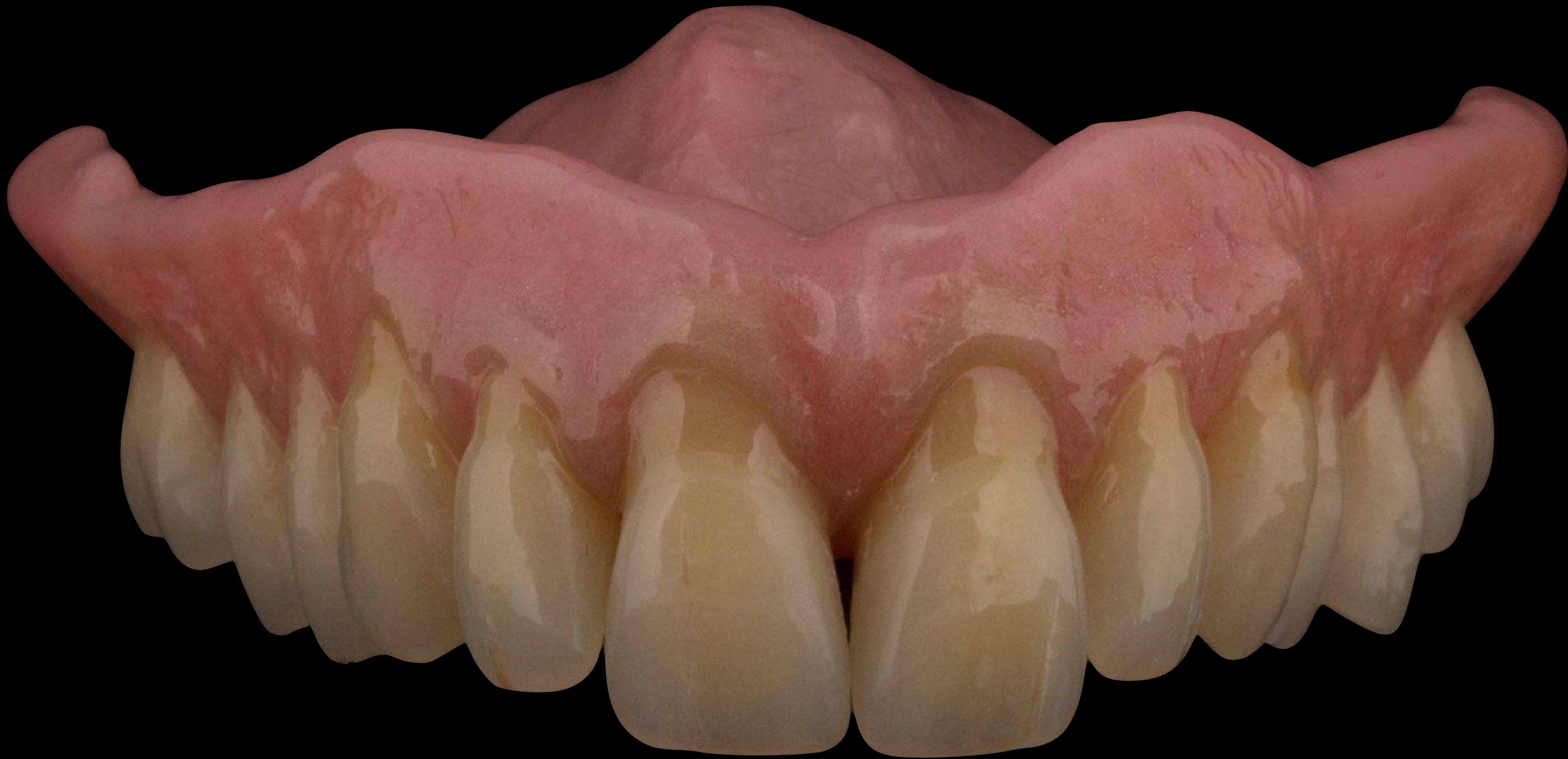

Before

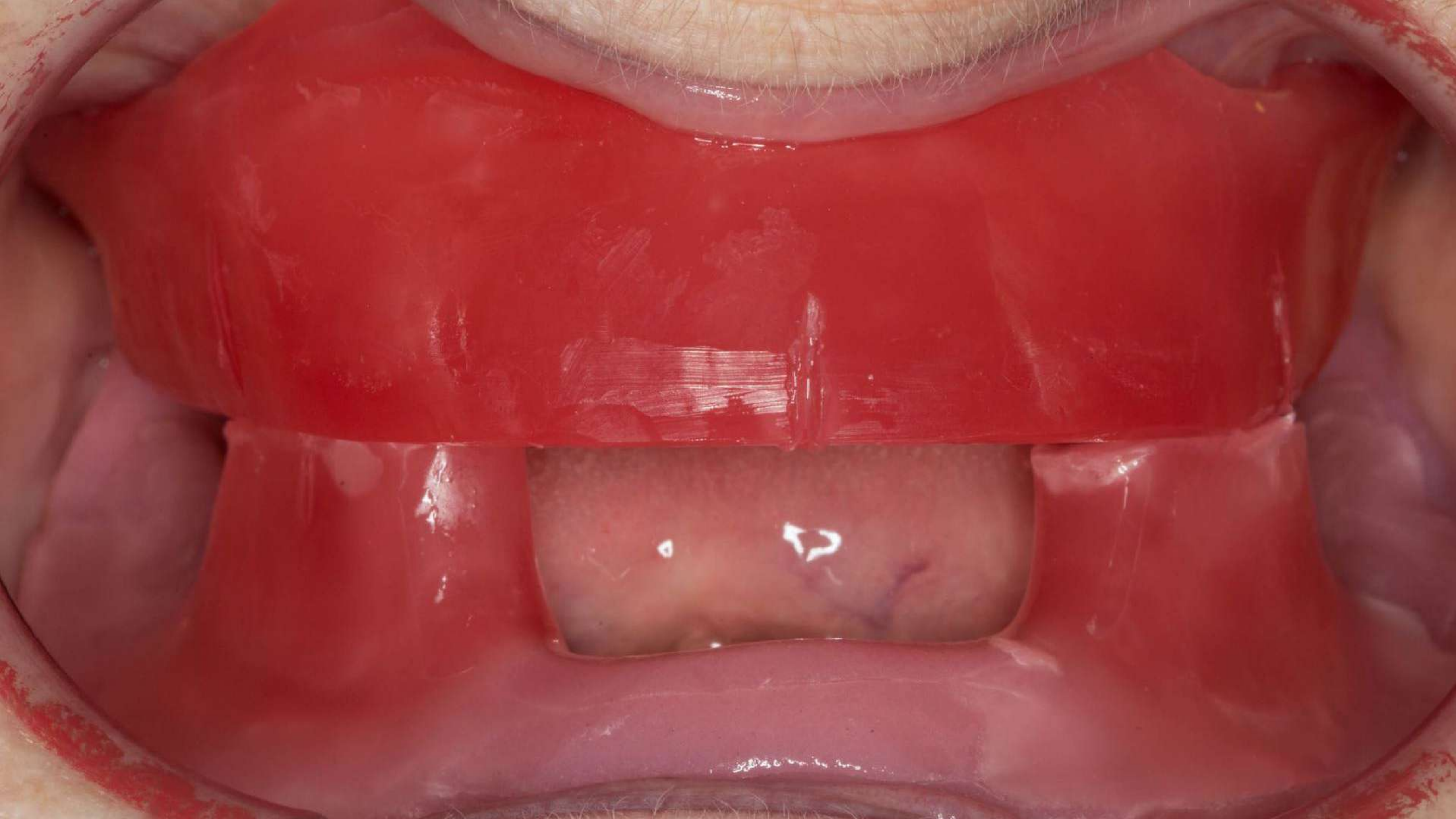


After

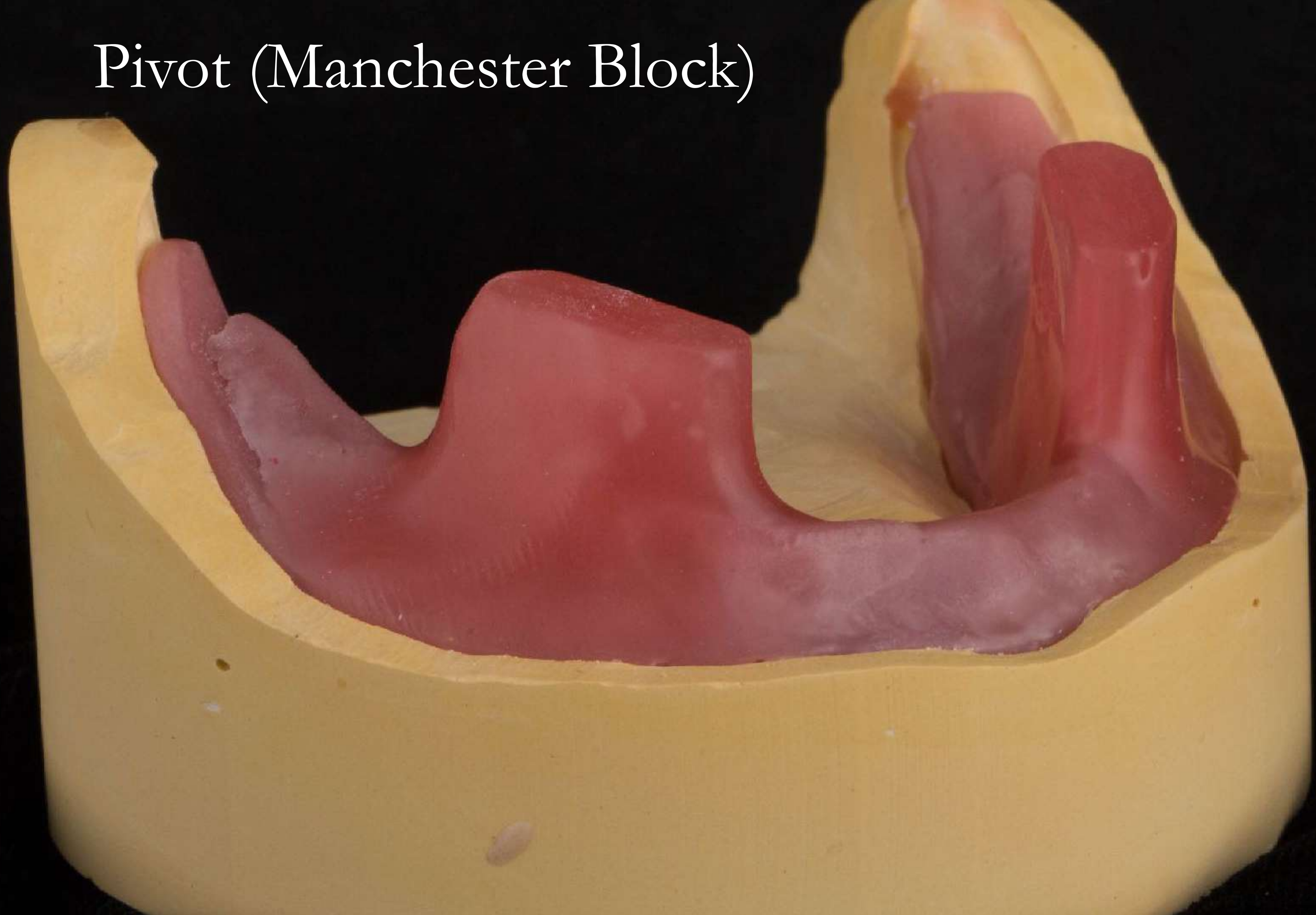


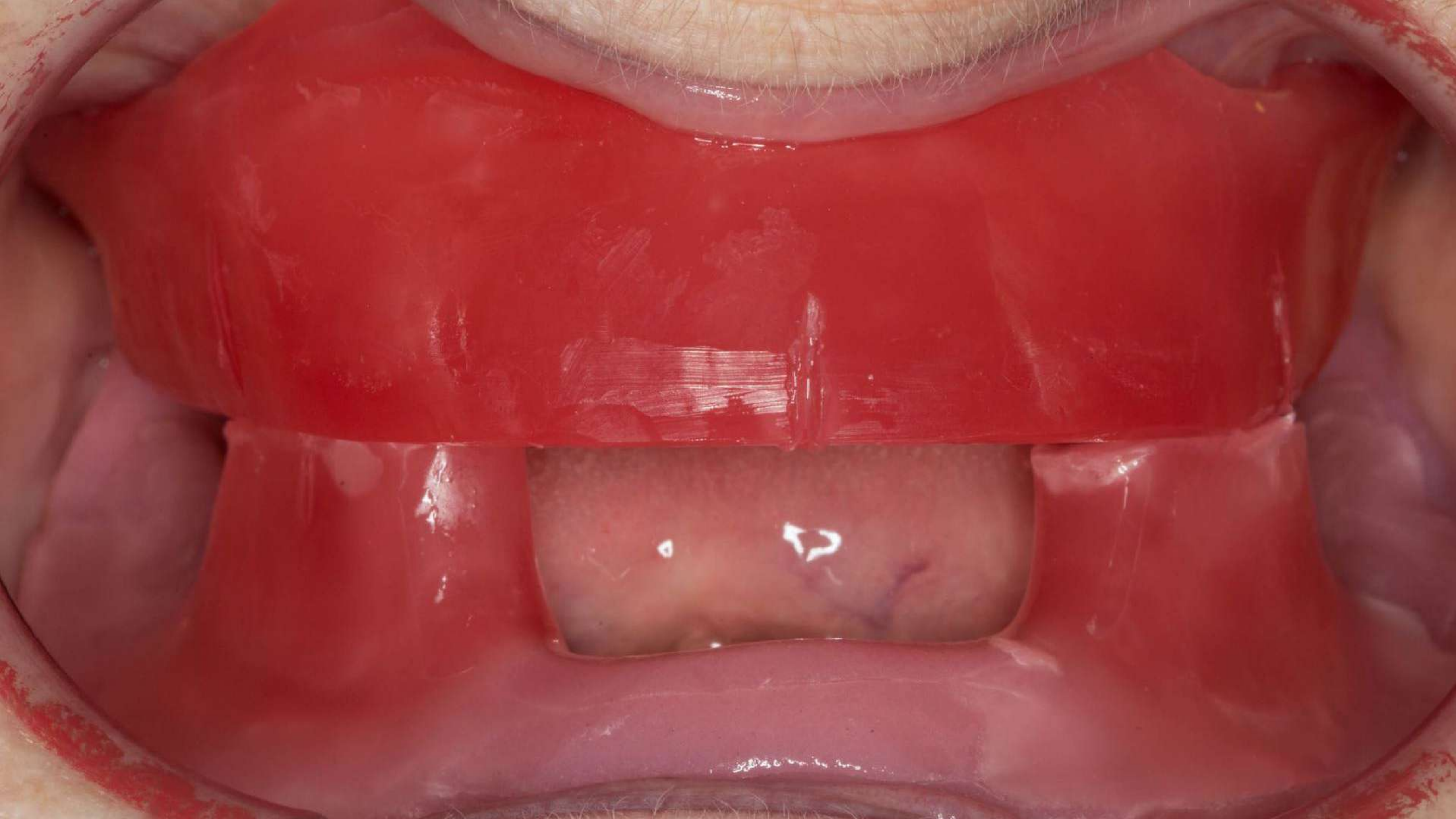


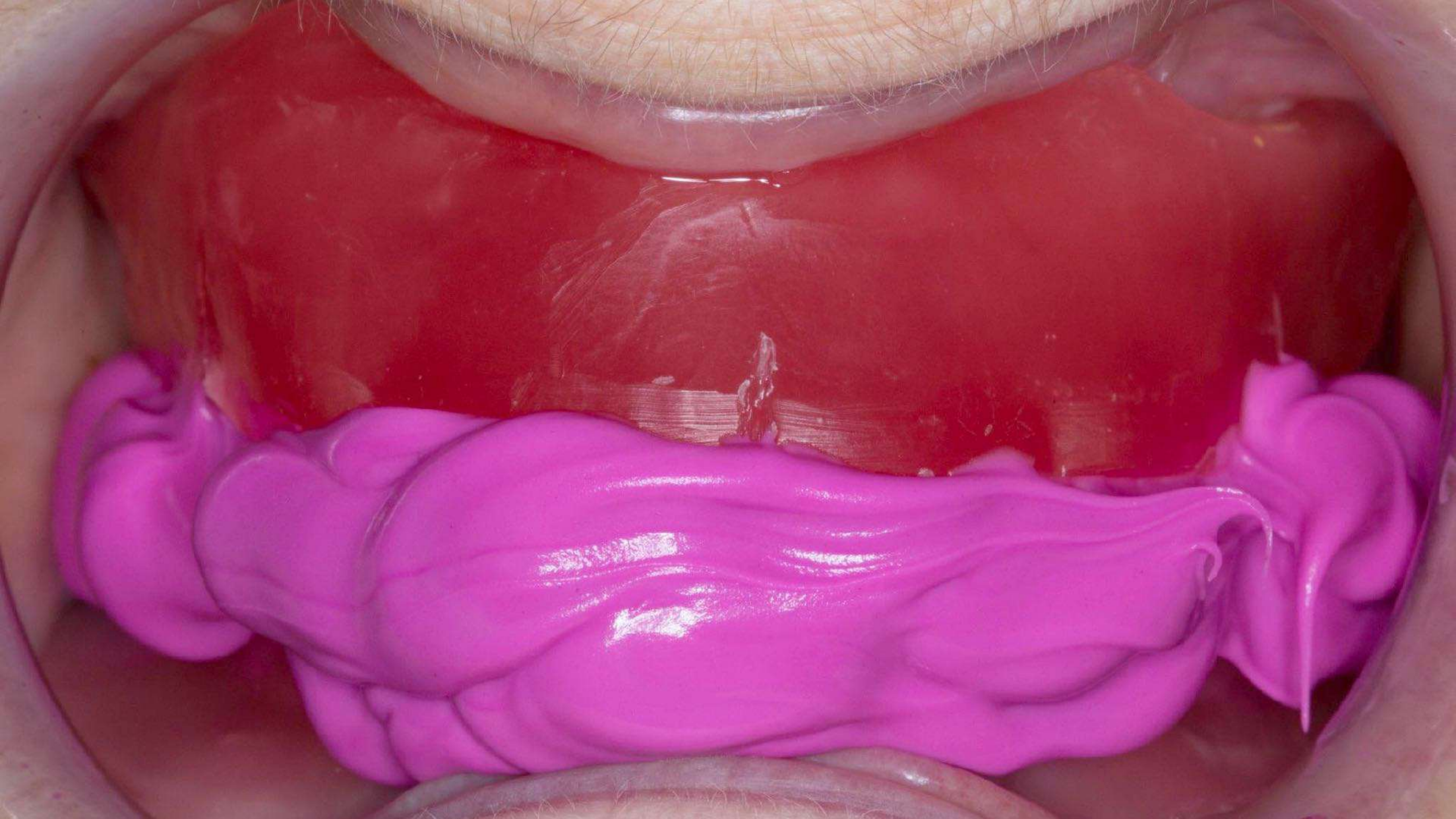
Schottlander Enigmallife + K24B




Pivot (Manchester Block)



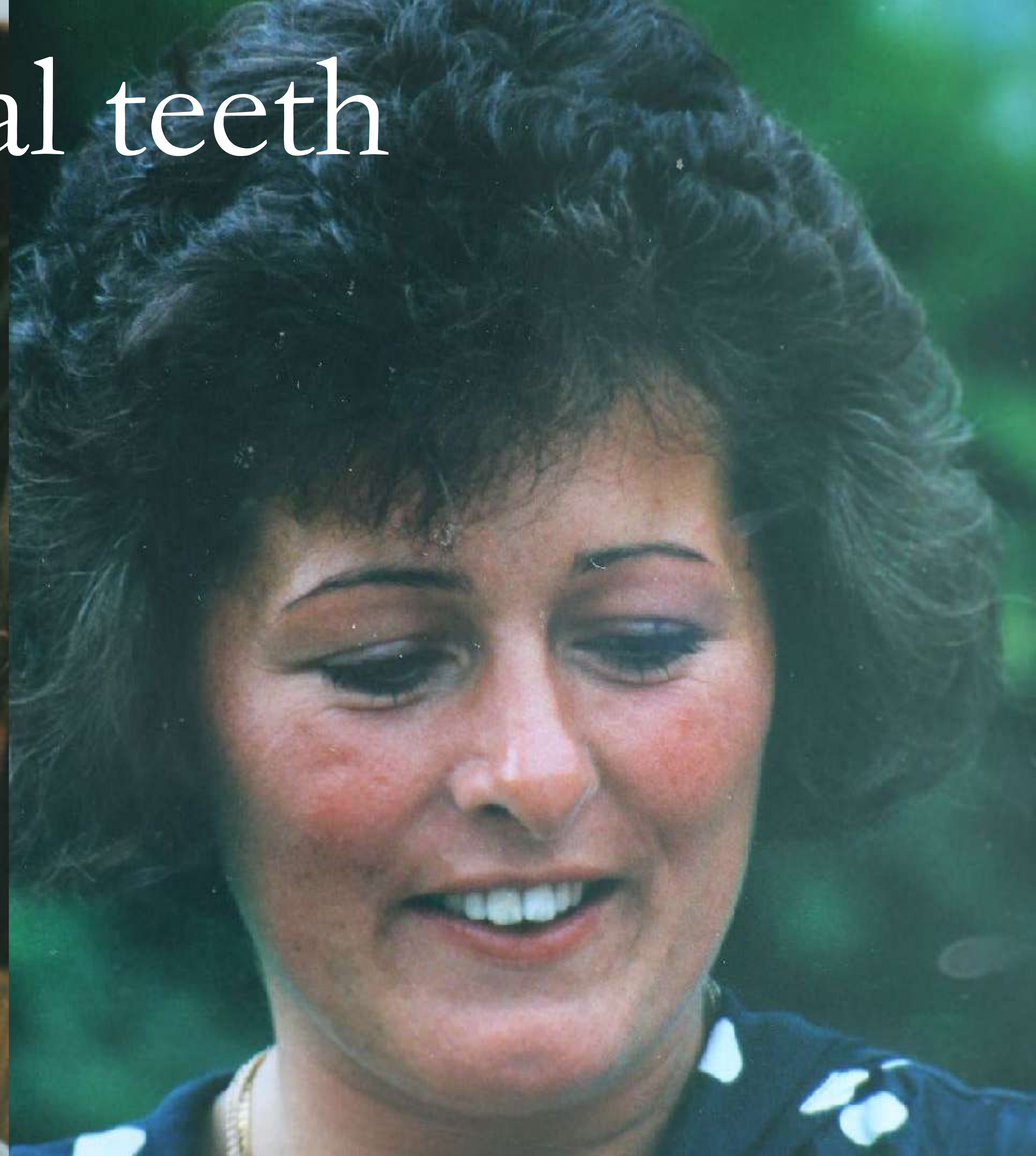






Diane

Natural teeth



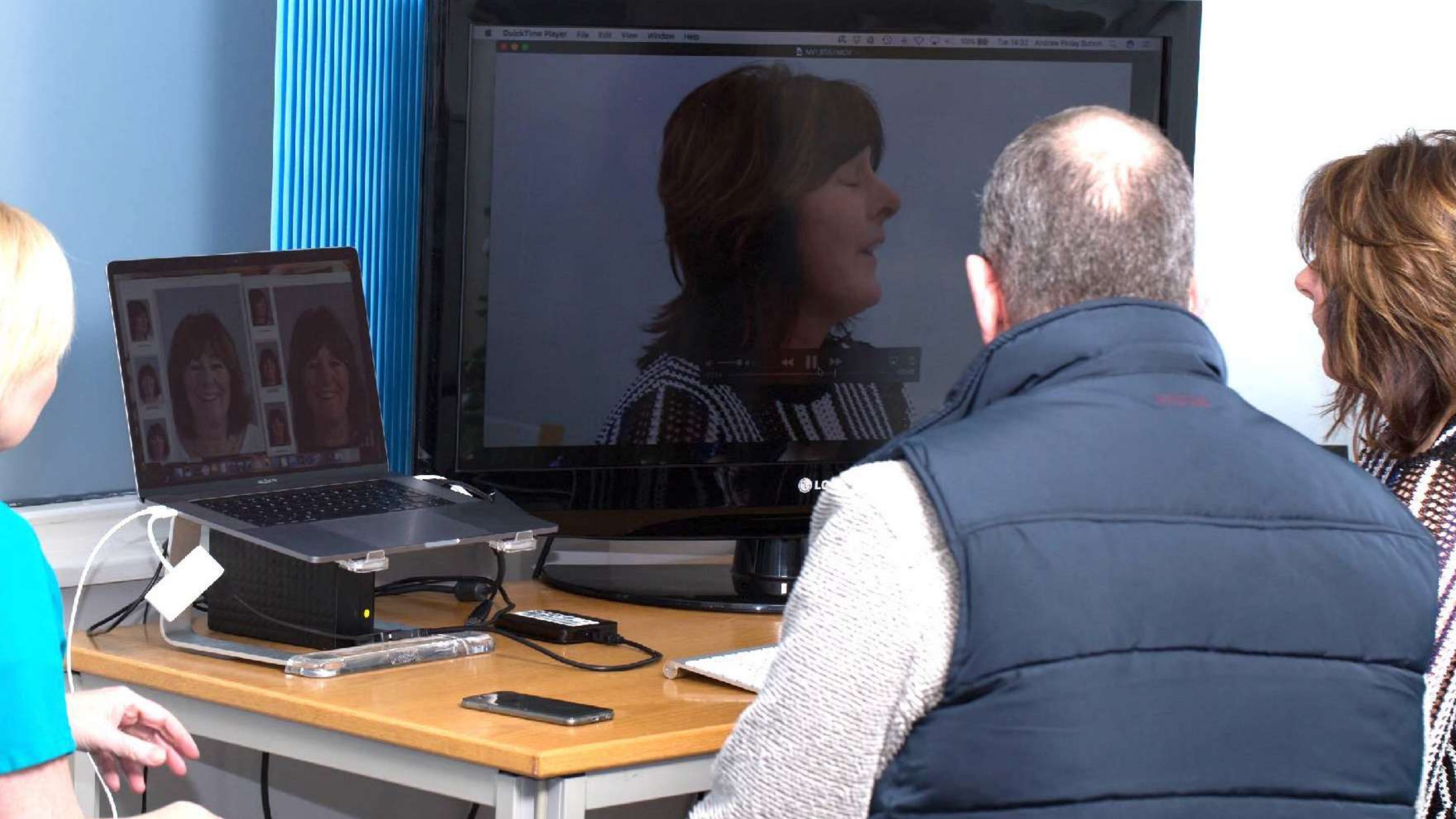

Try in





Try in 2





Try in 1



Try in 2



