



How to give your patients

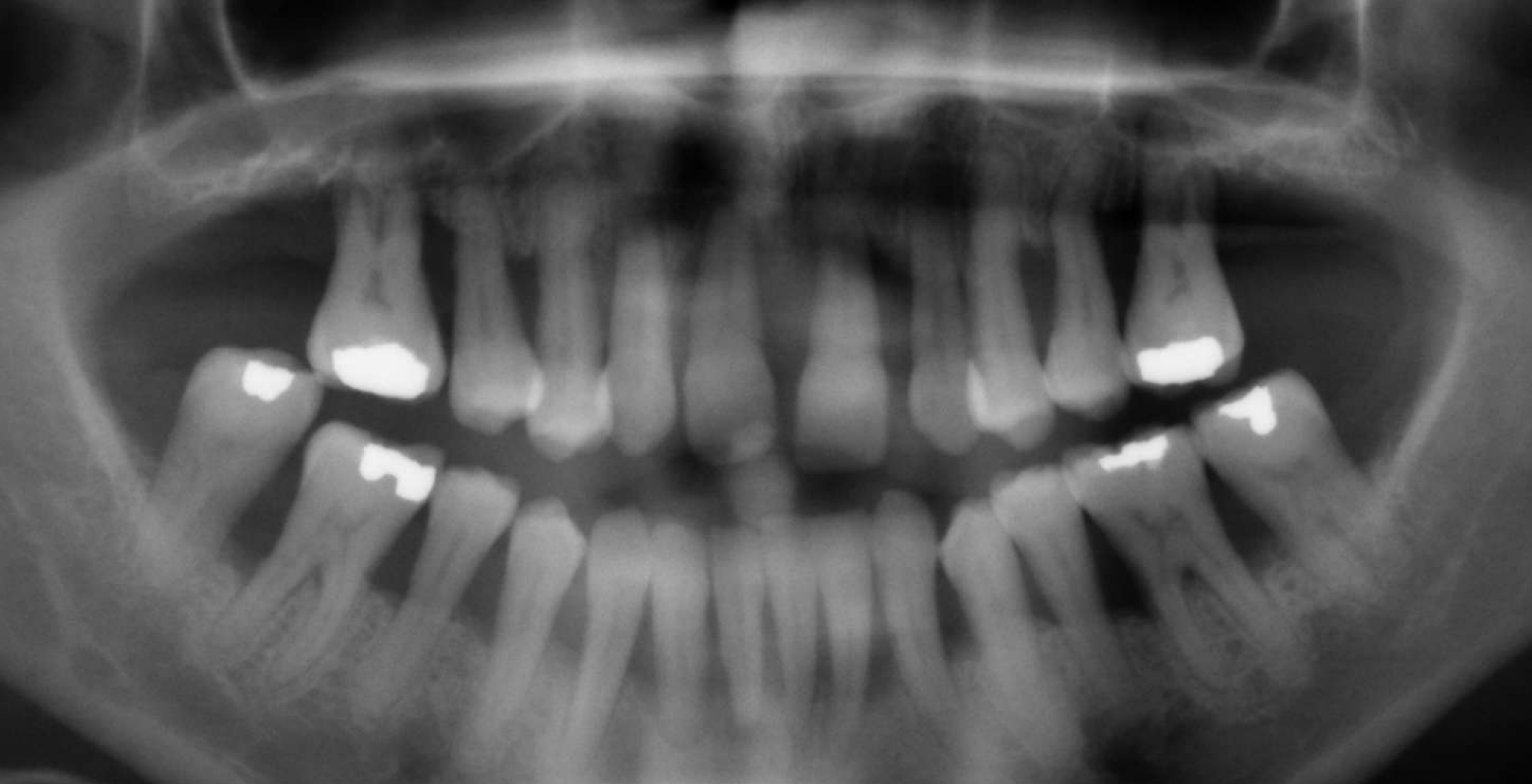
superb

immediate dentures

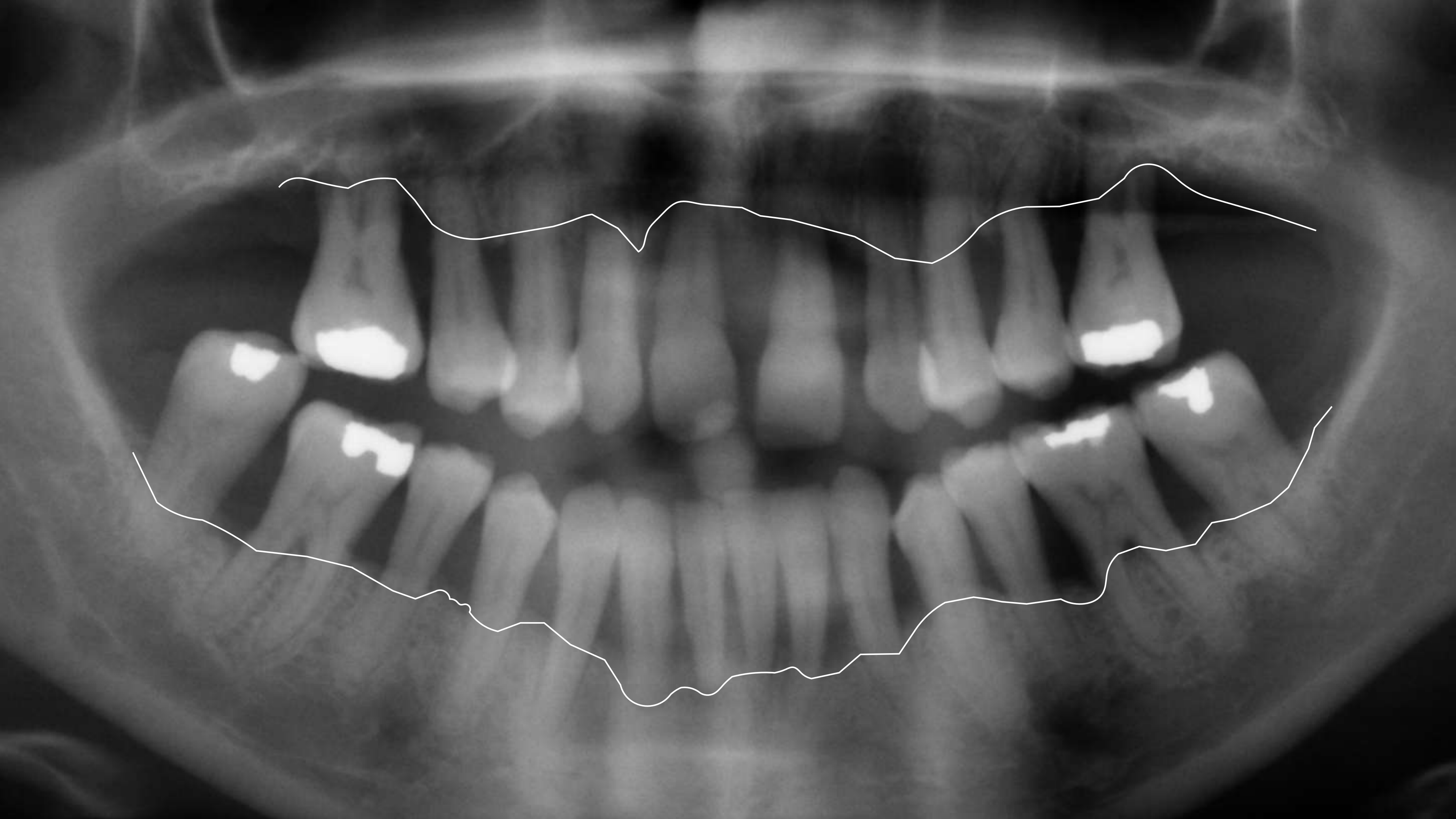
Finlay Sutton

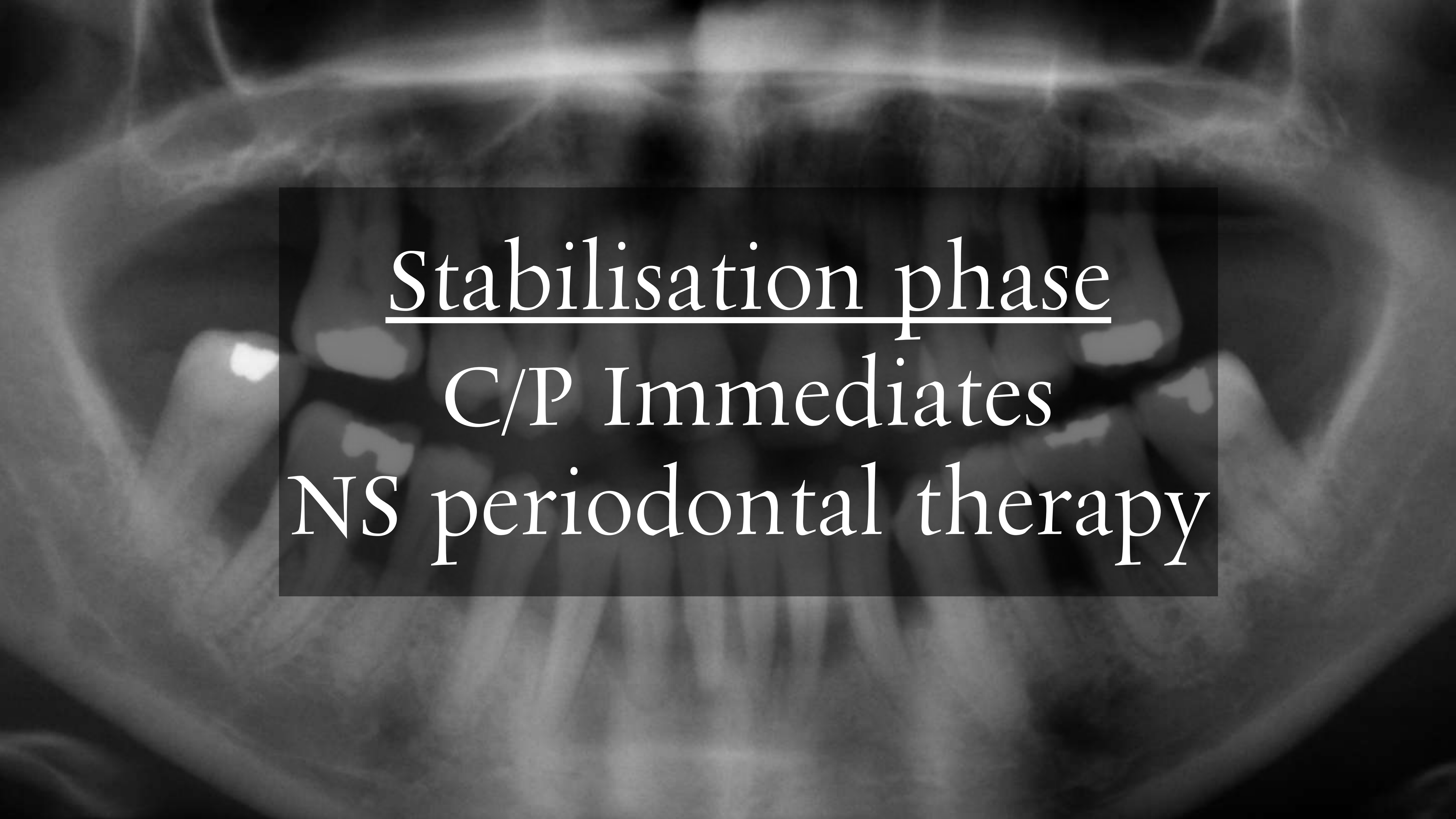
Donna



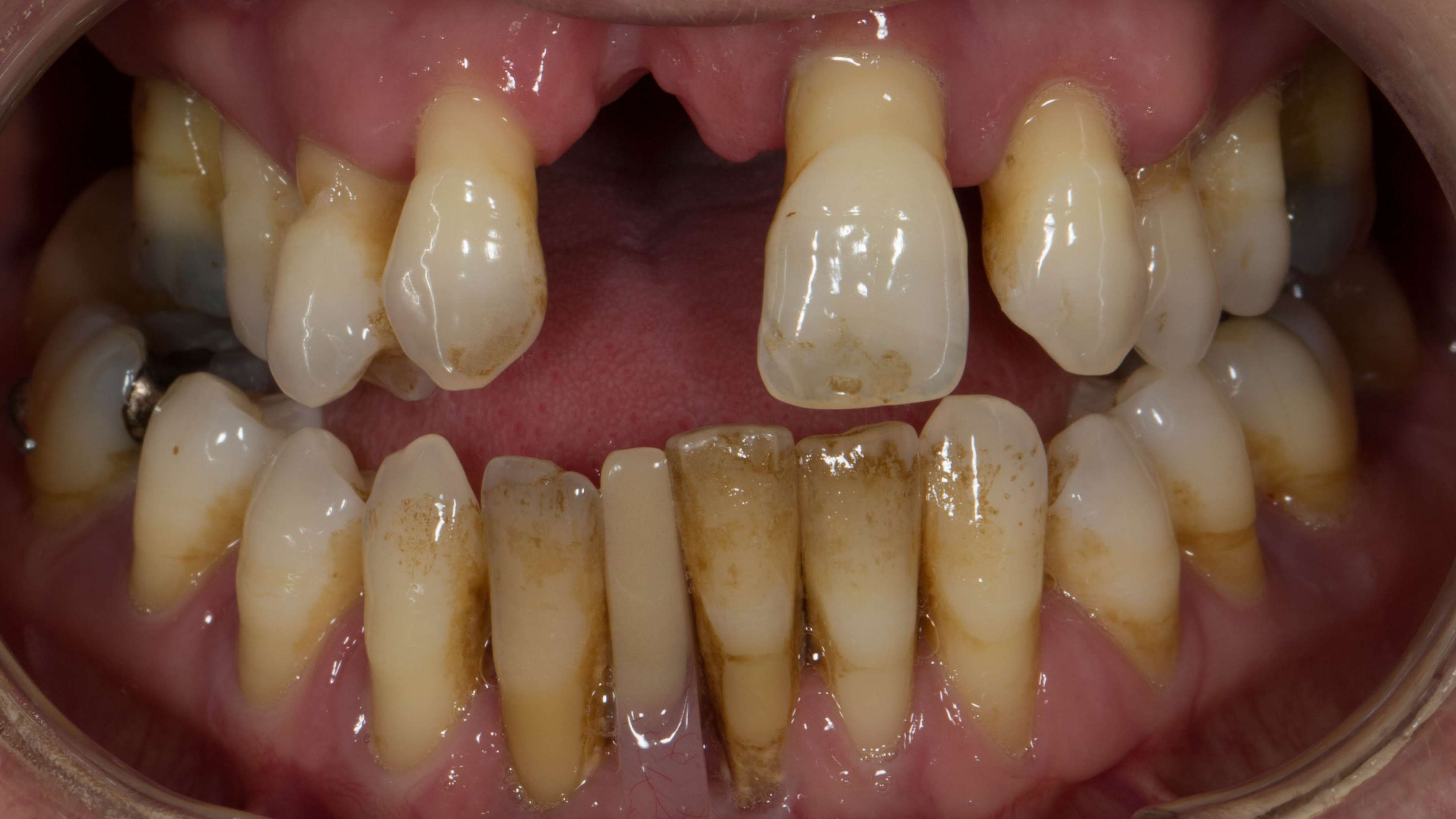

Generalised Periodontitis stage 4 (very severe) Grade C (rapid progression)

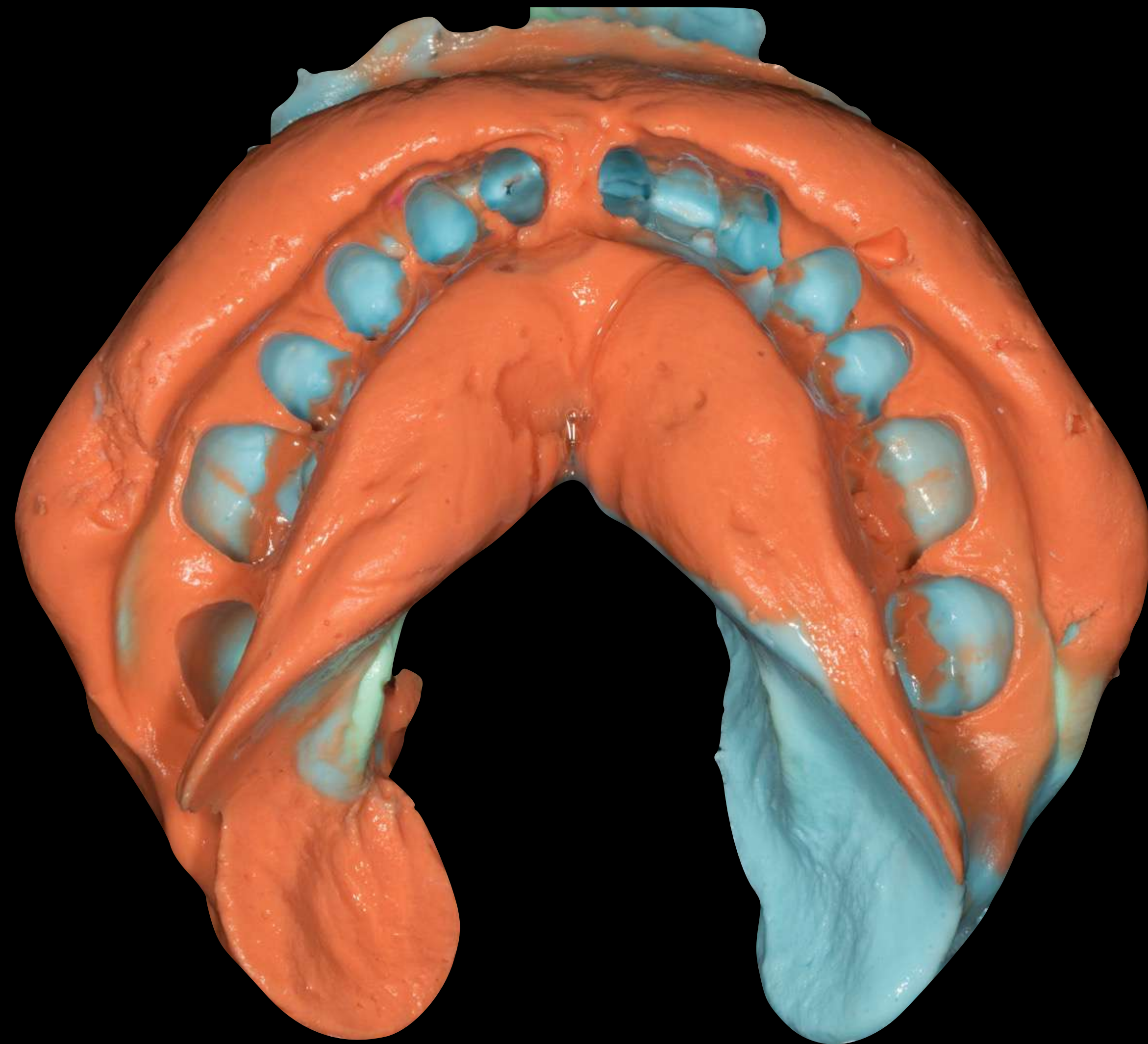
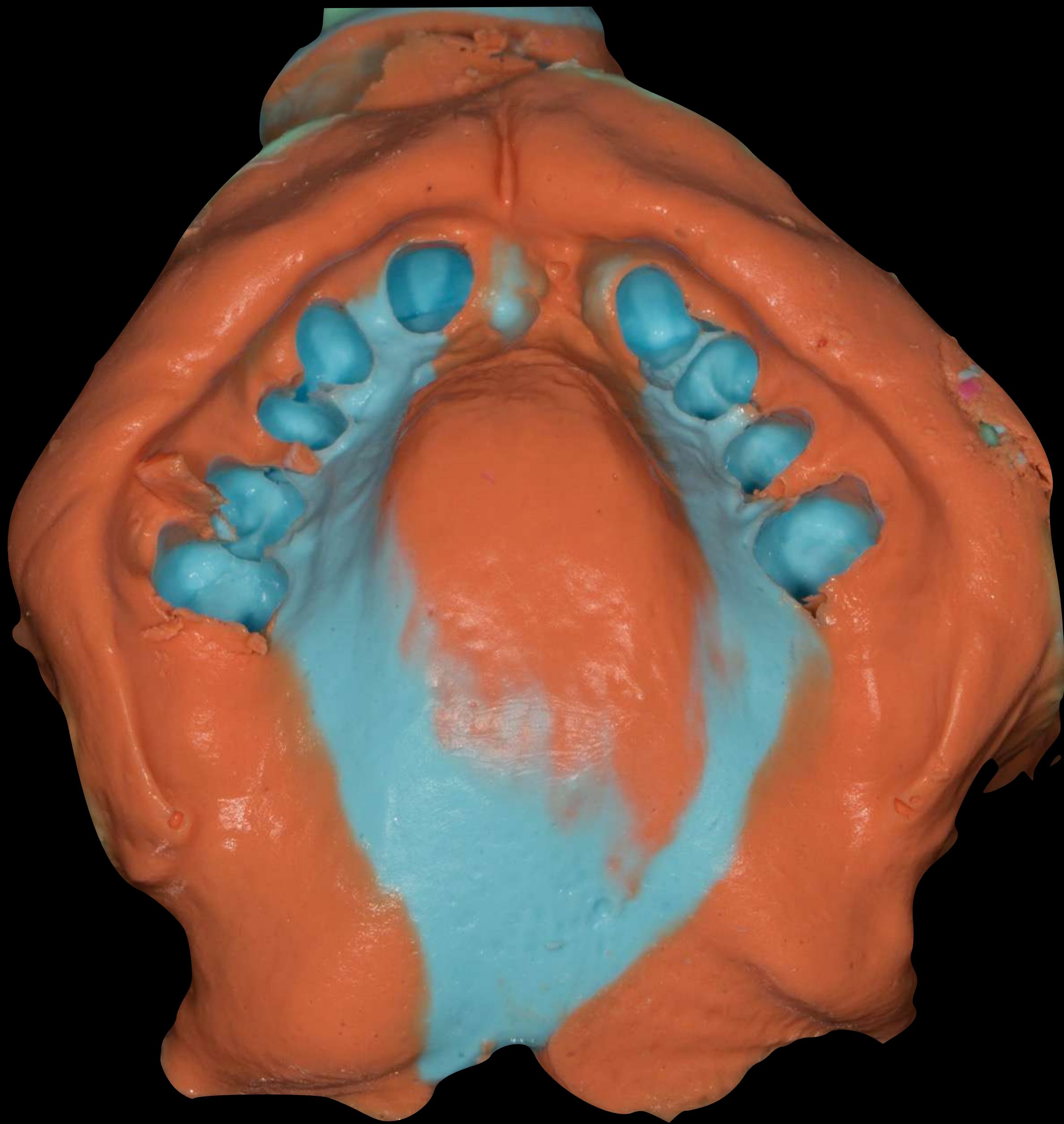




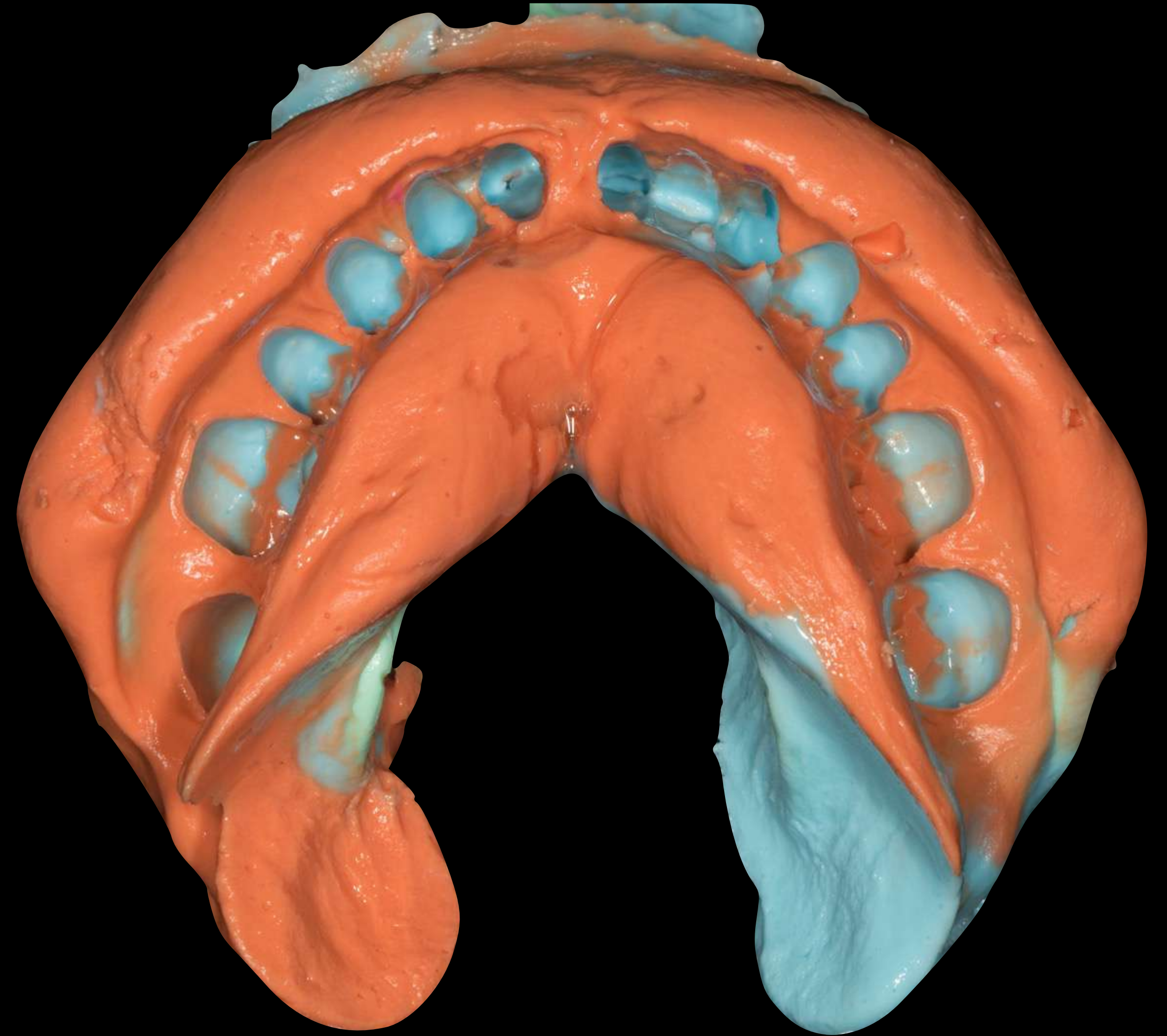
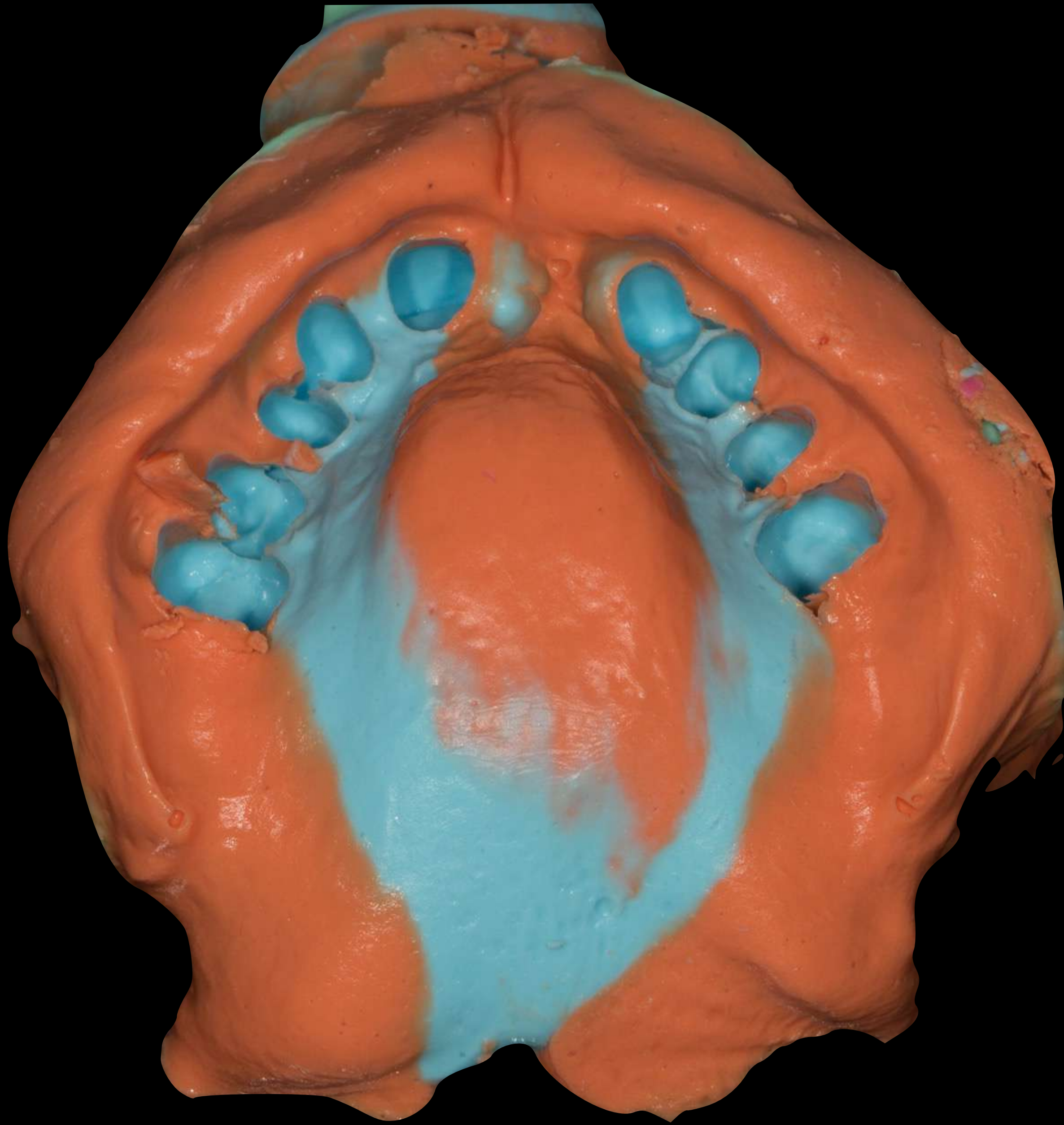
Stabilisation phase  
C/P Immediates  
NS periodontal therapy



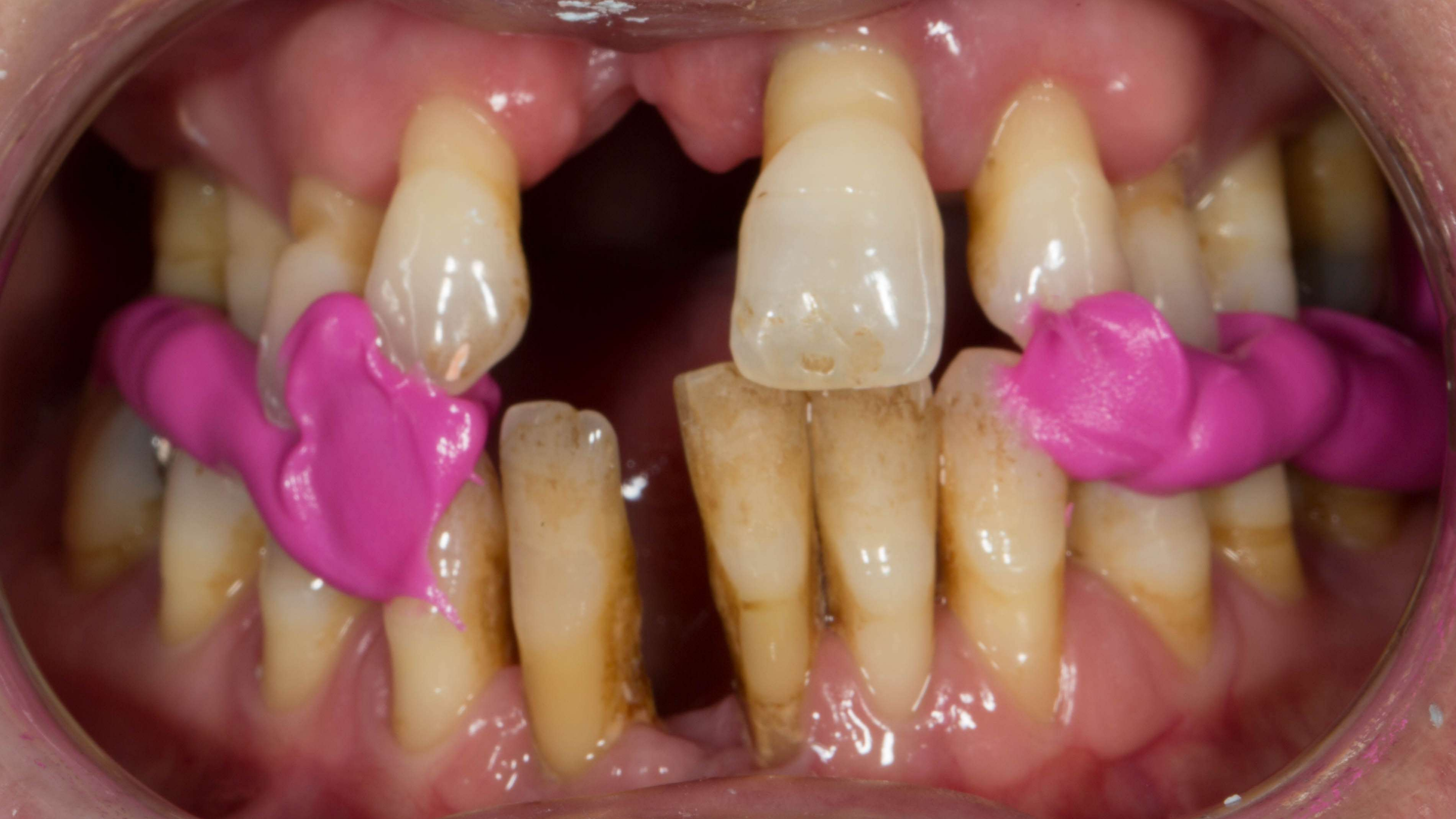Ivoclar Vivadent – AccuDent XD



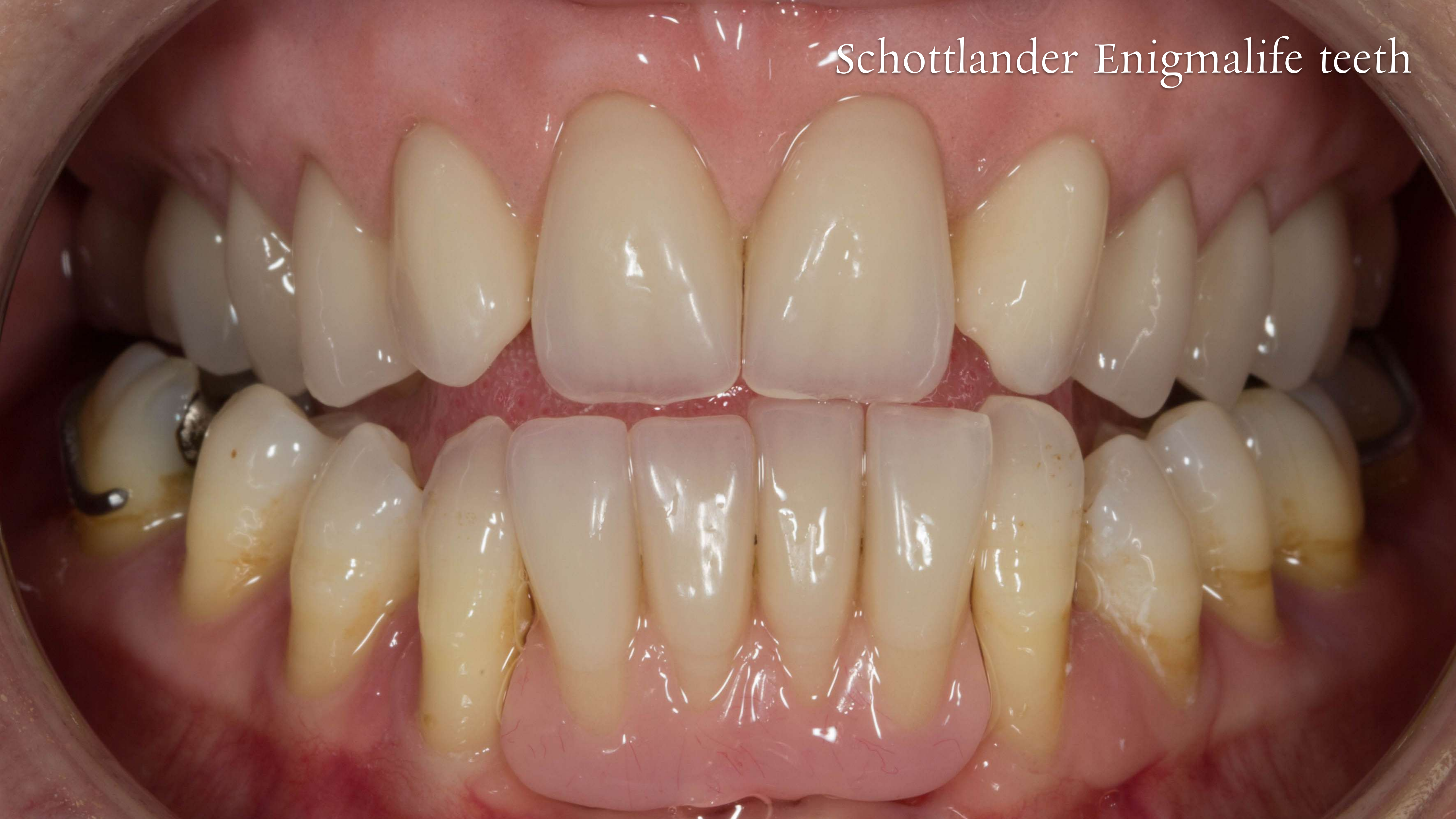Zhermack - Tropicalgin - Base  
Neocolloid - Injectable







Schottlander Enigmalive teeth





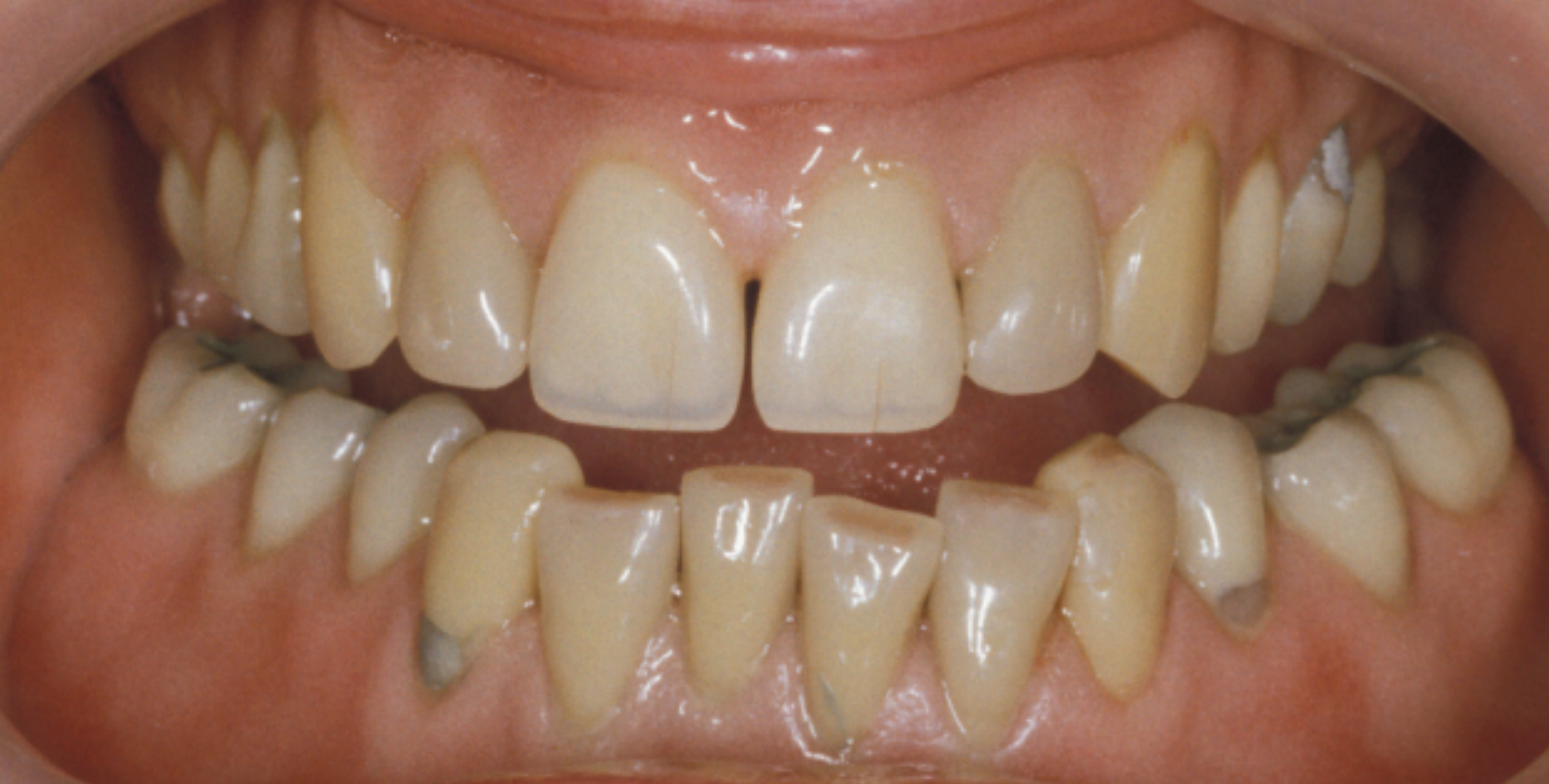

I love doing this

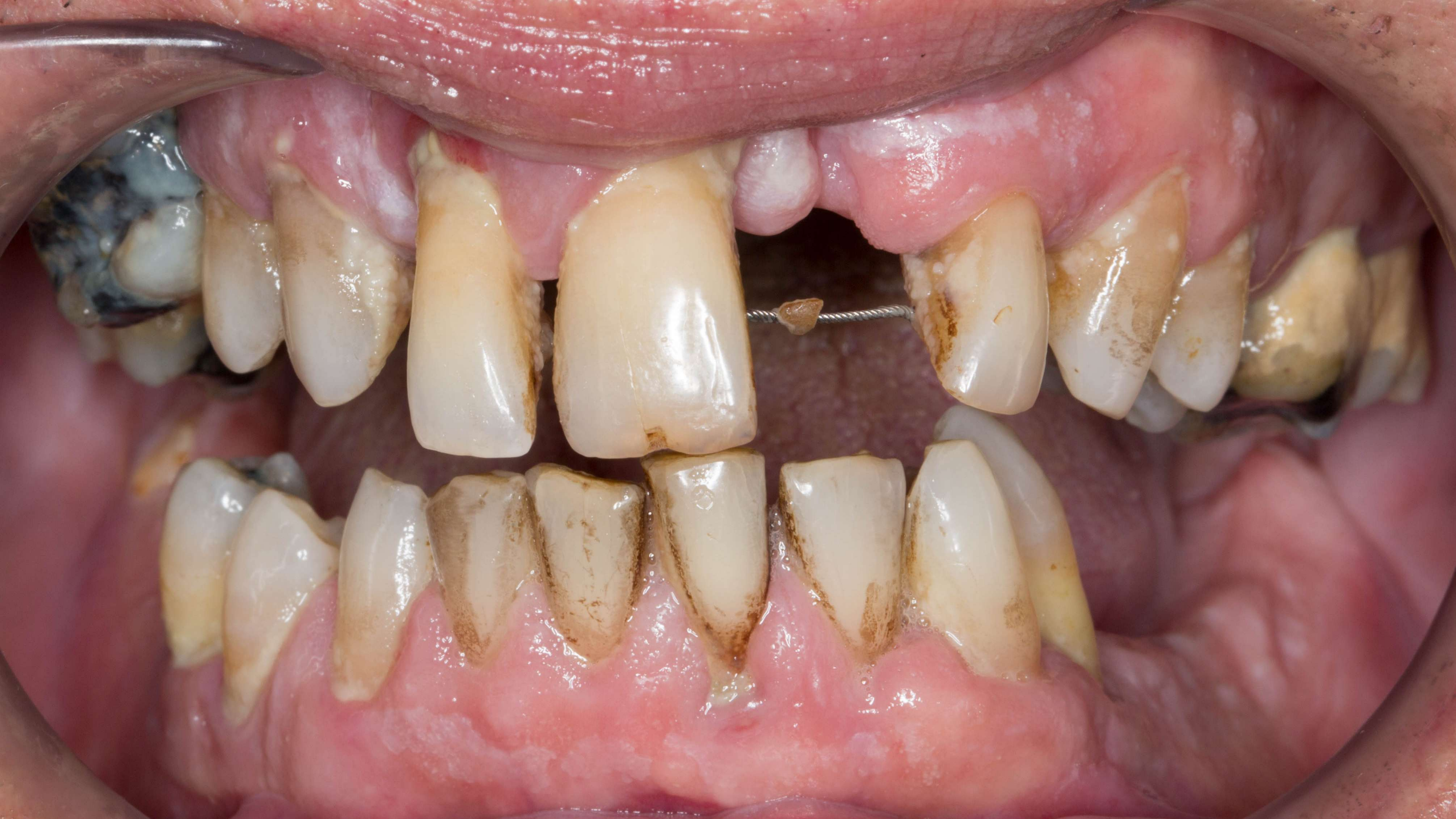



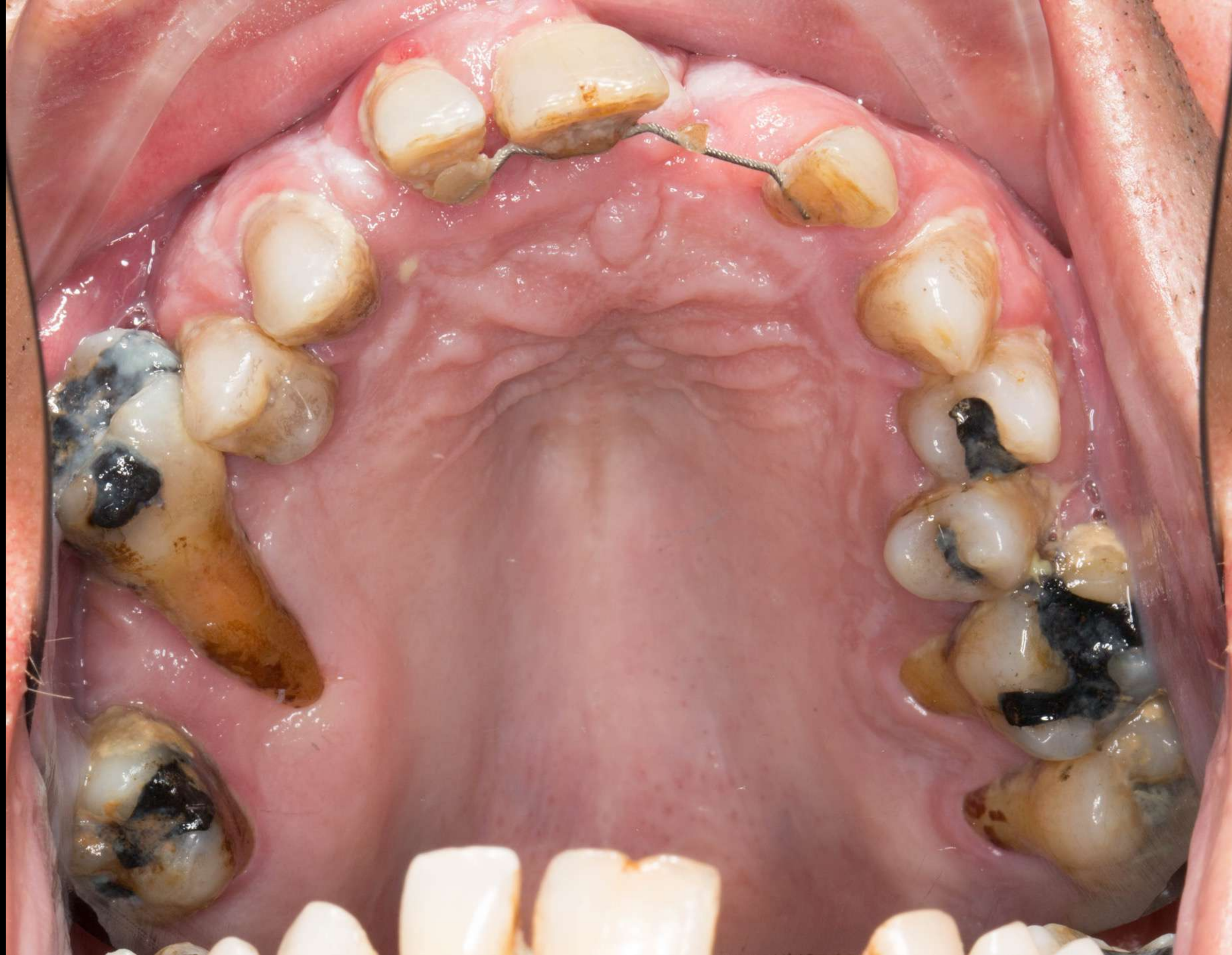*My mentor*



Set up and fillings by John Besford, gum contouring, colouring and processing by Andrew Taylor

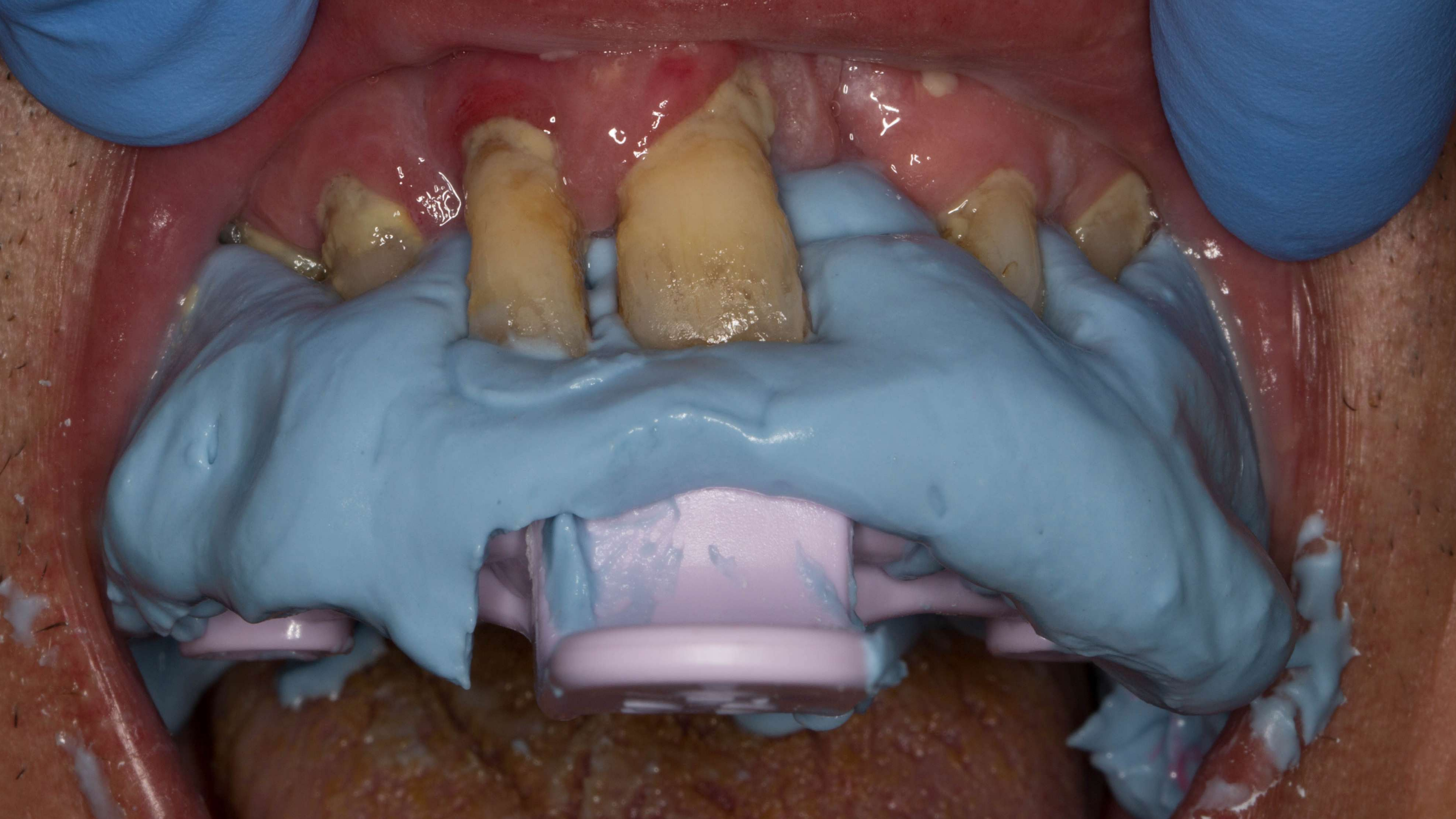

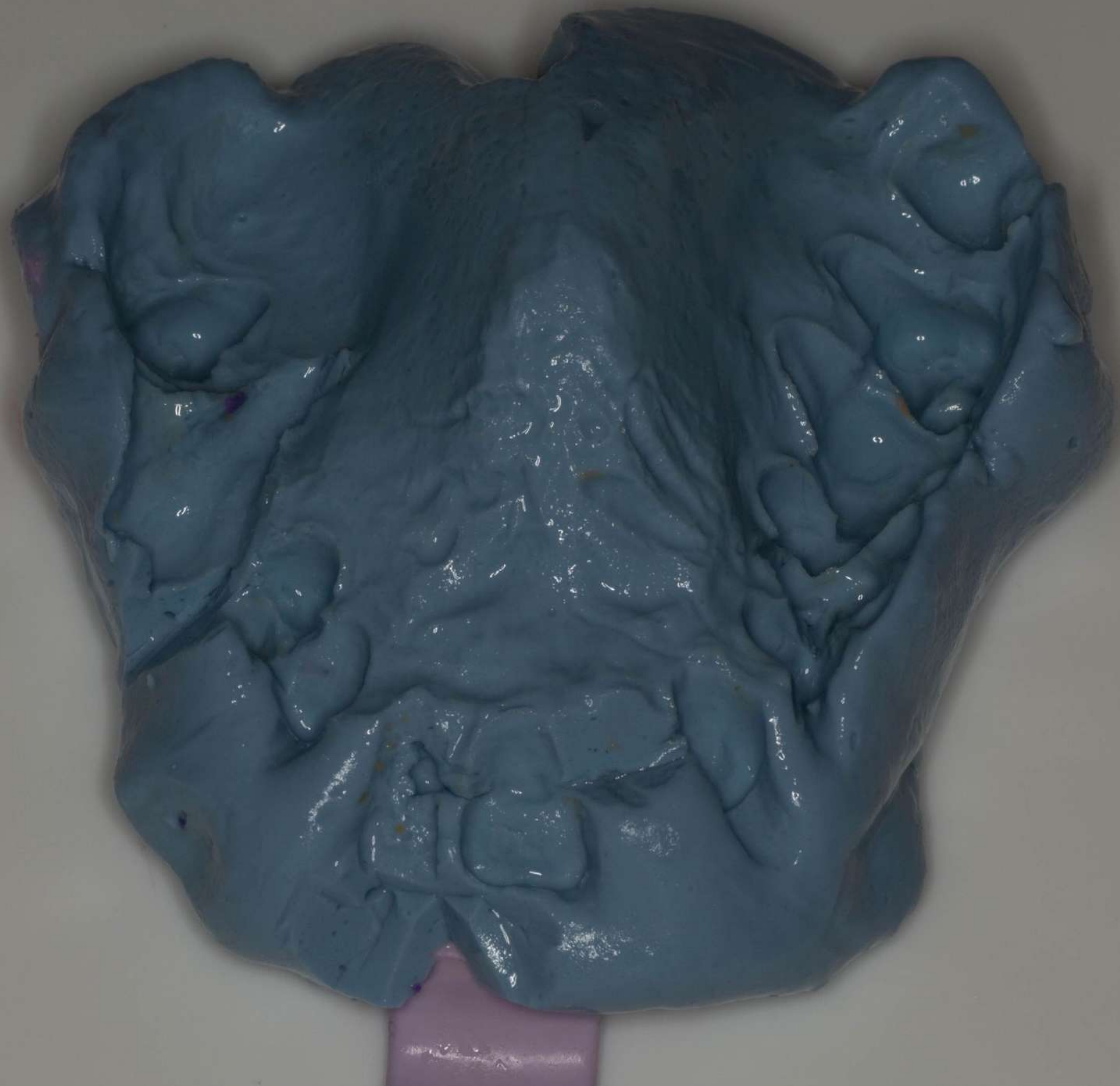



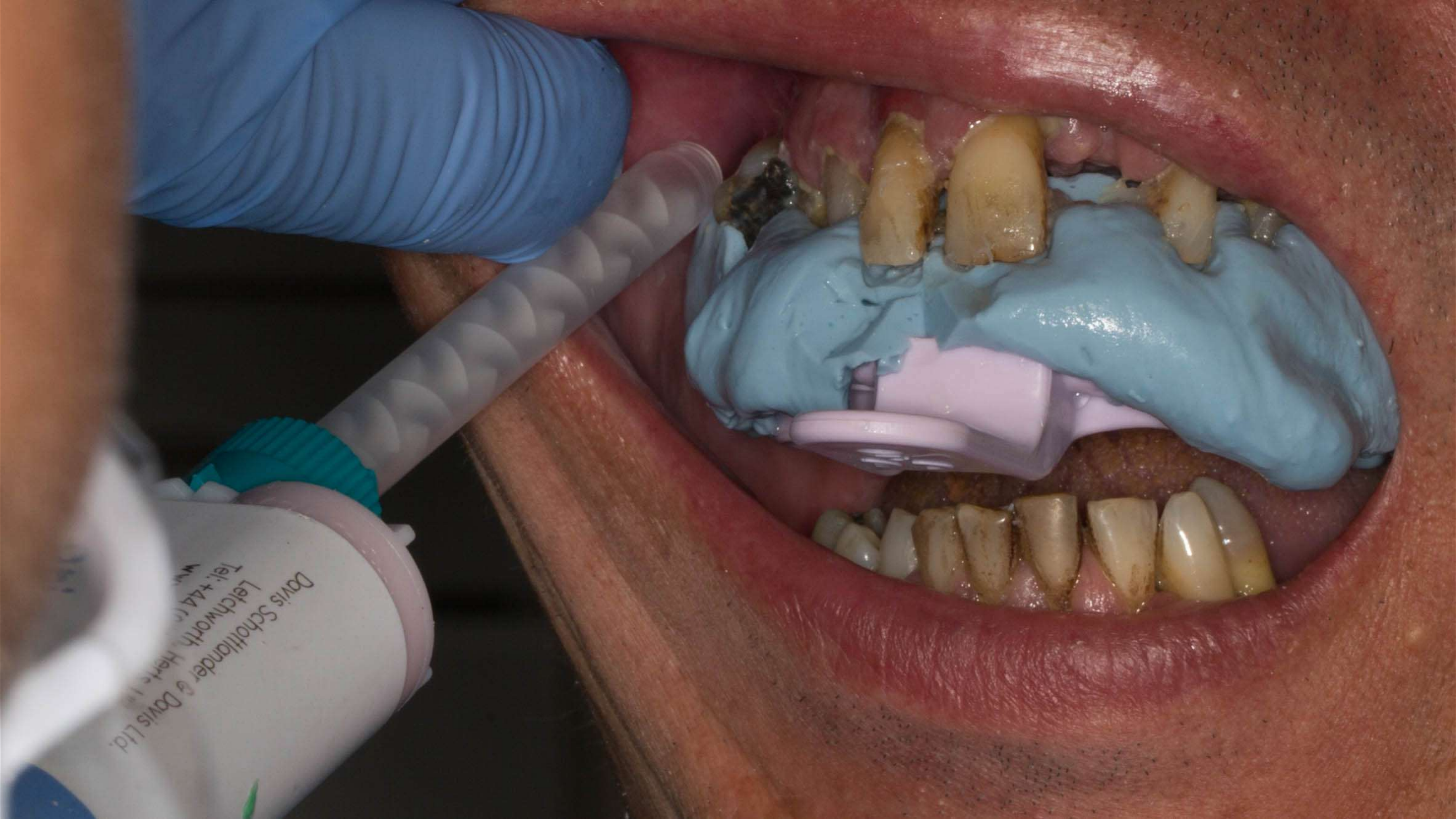
# Kerr Red Cake Compound

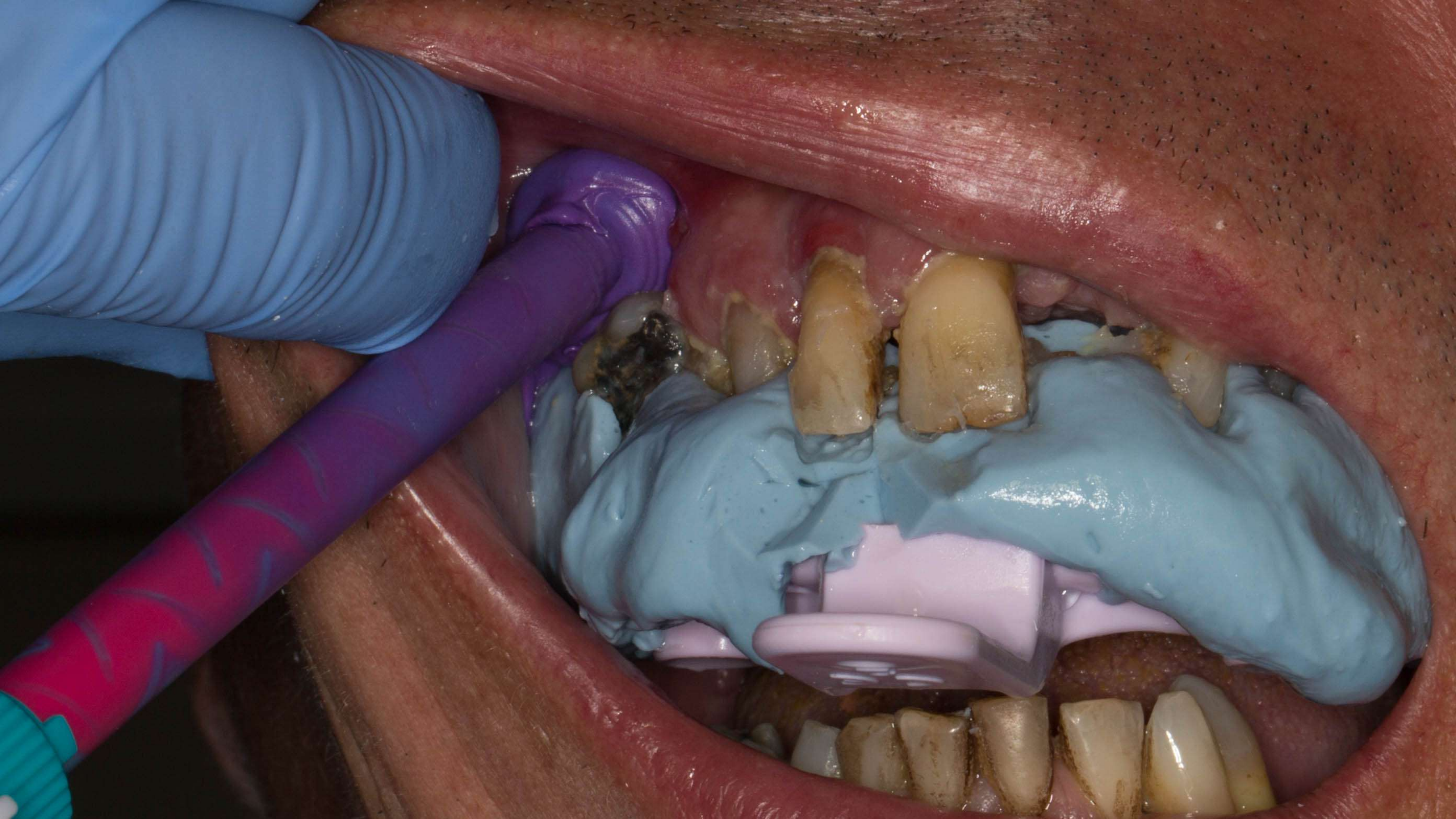


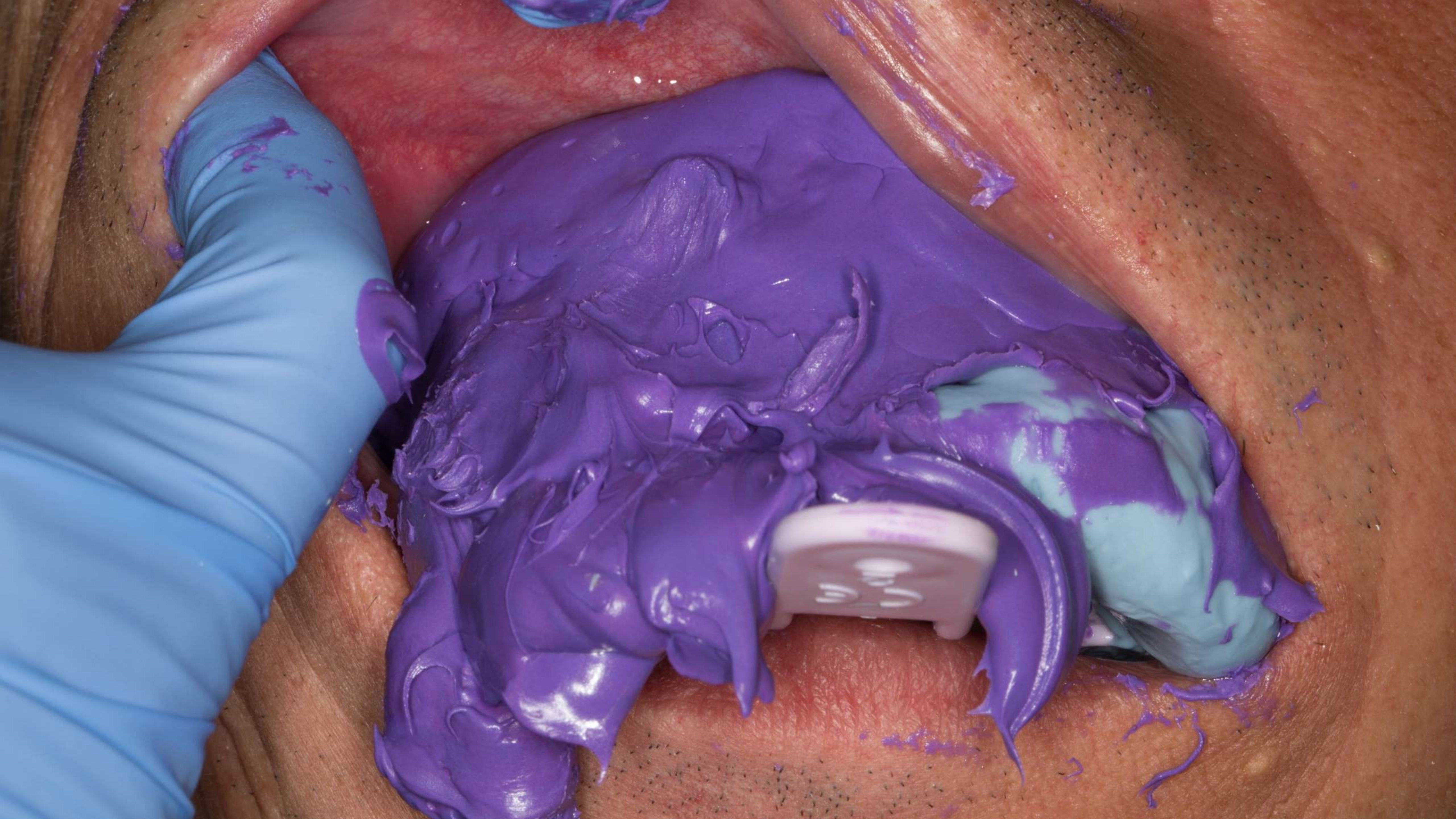


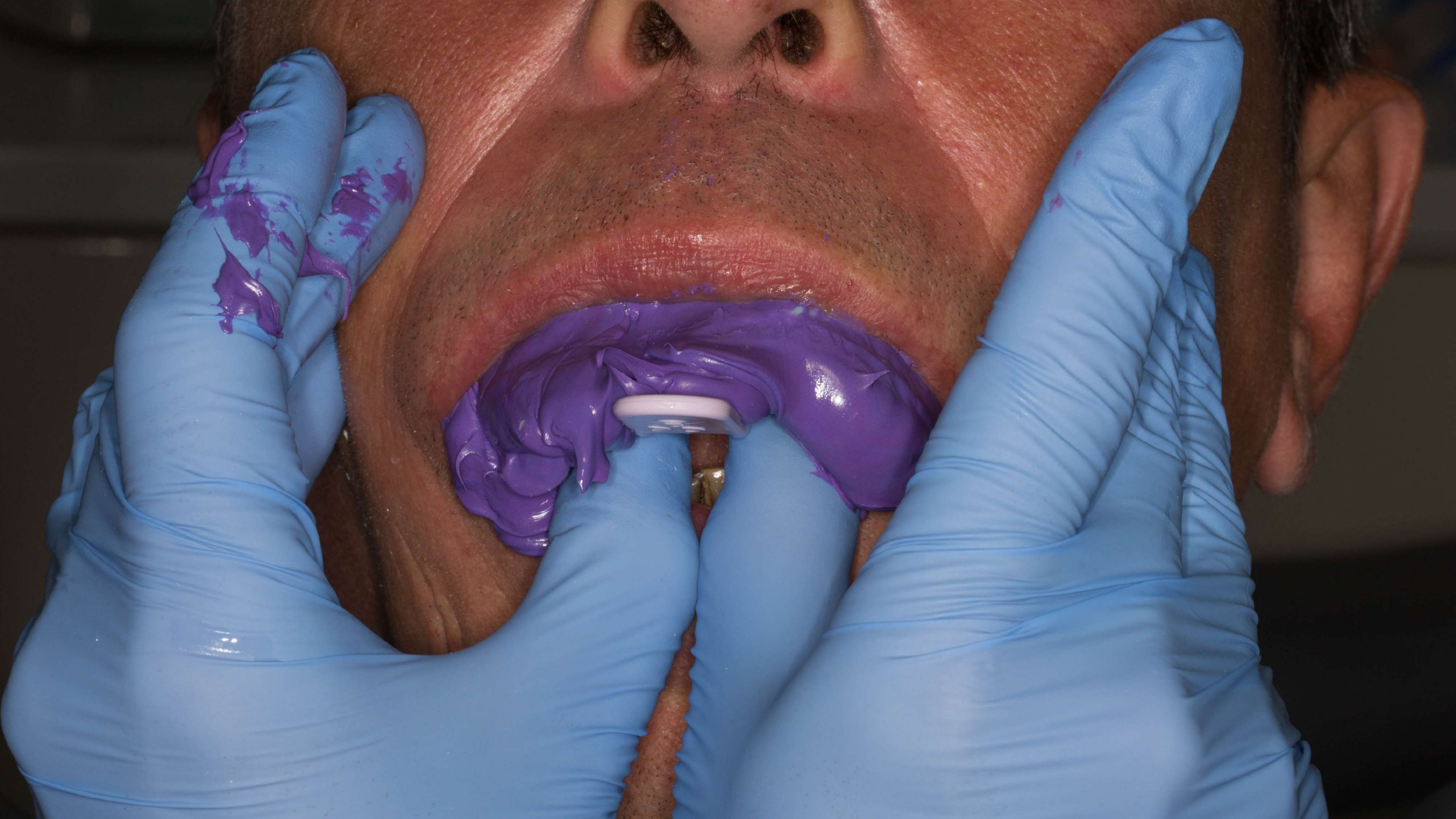

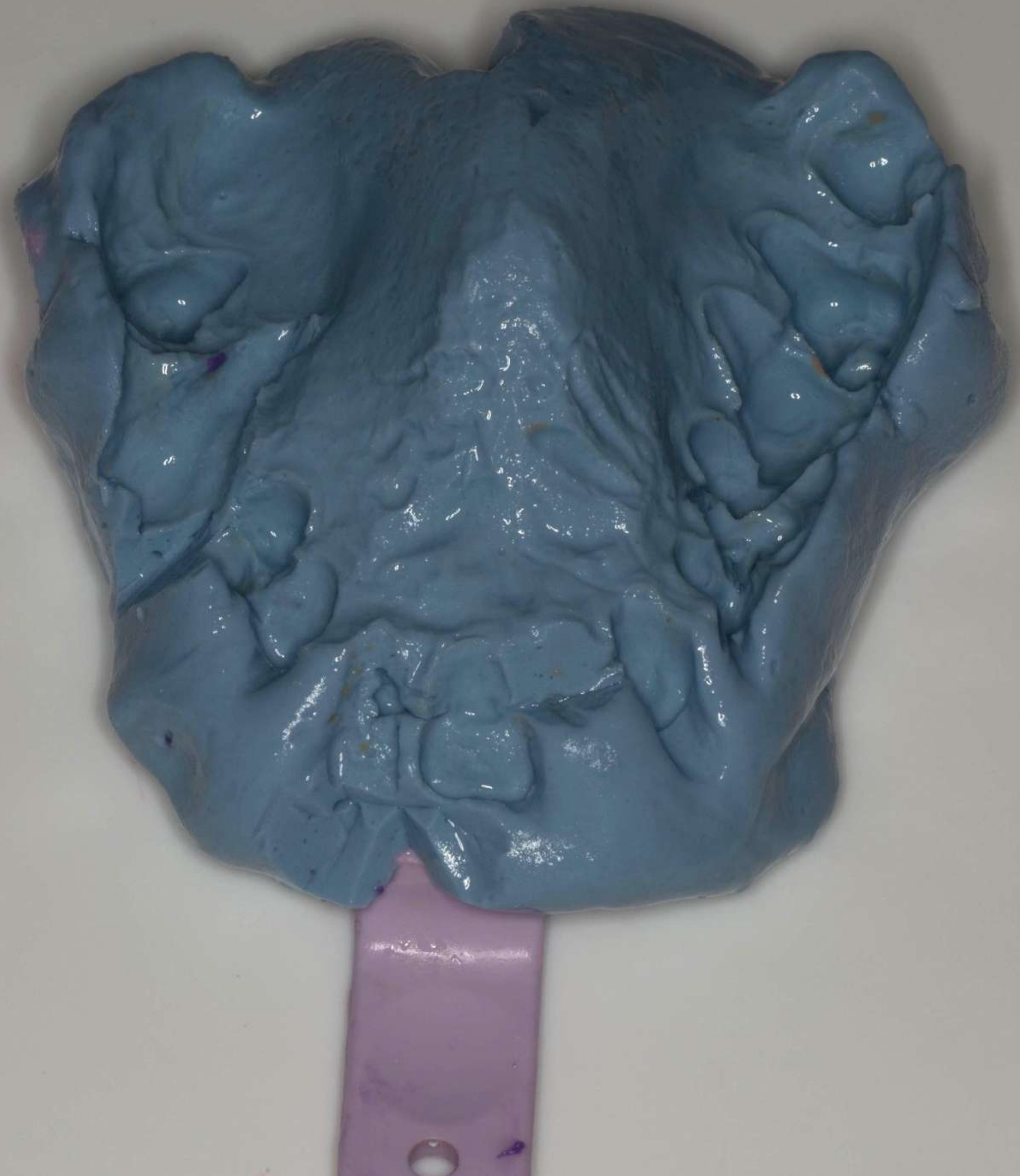Davis Schottlander & Davis Ltd.  
Letchworth, Herts. SG8 1LN  
Tel: +44 (0) 464 751111  
www.davisdentalsupply.com

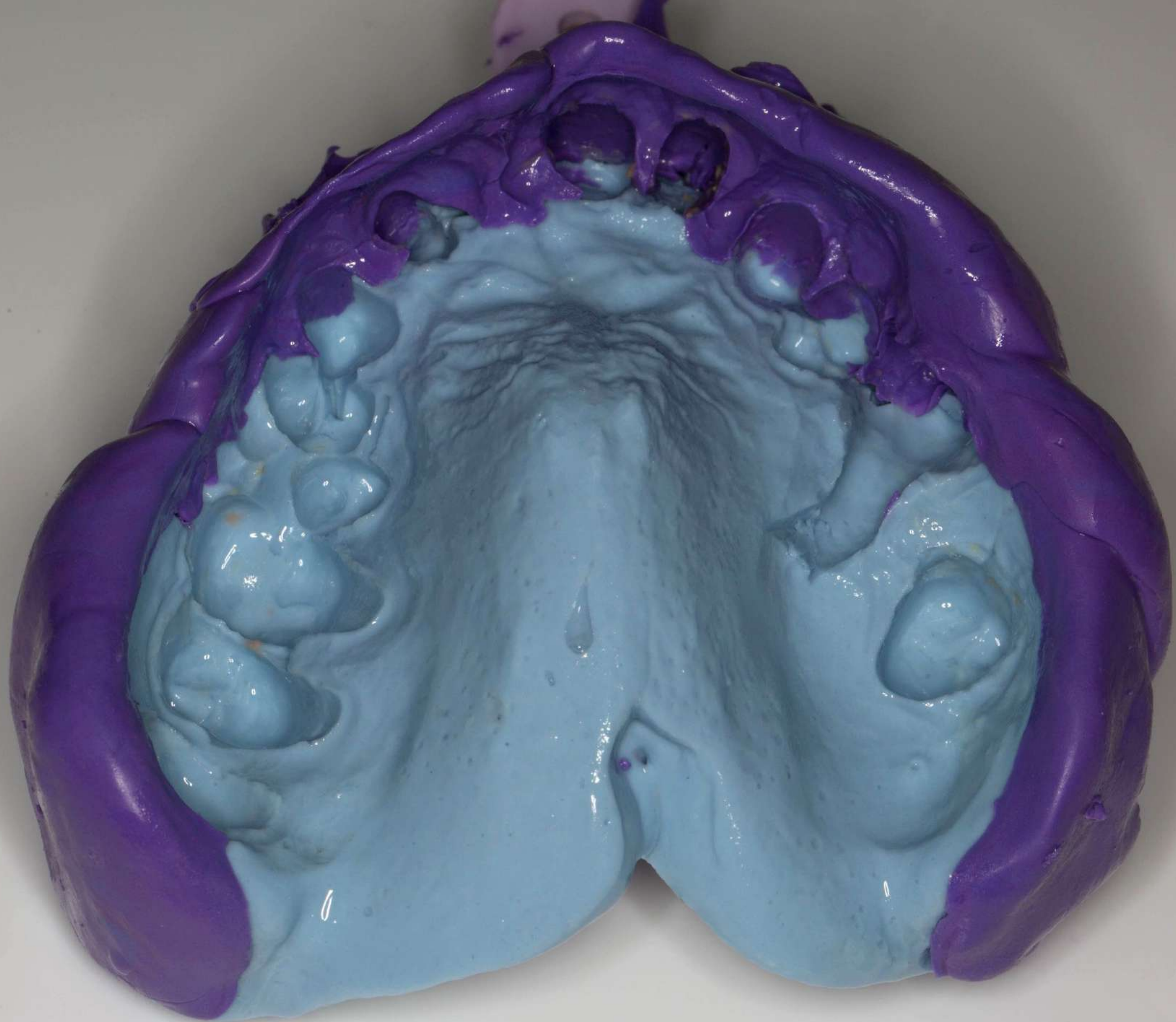


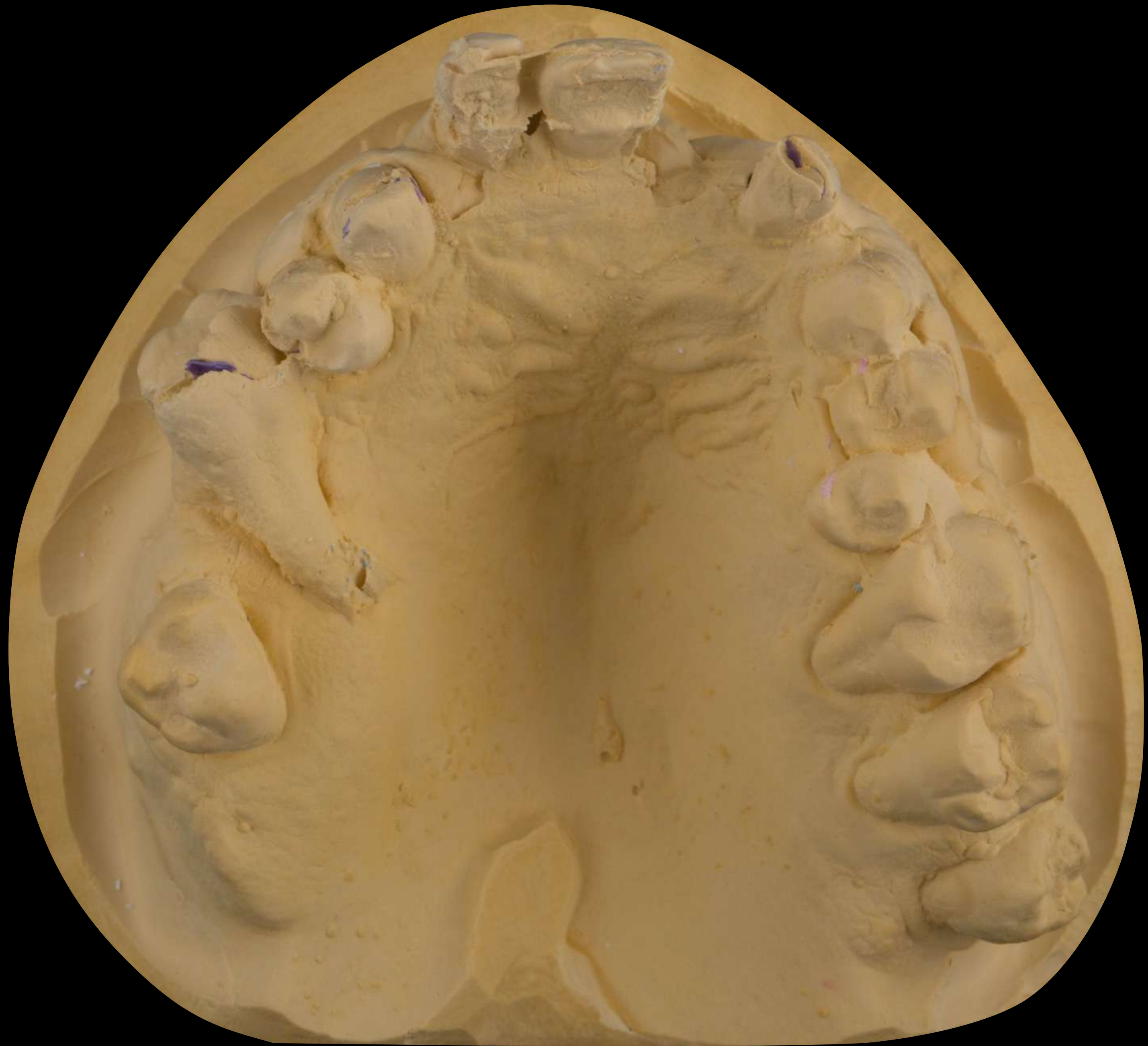


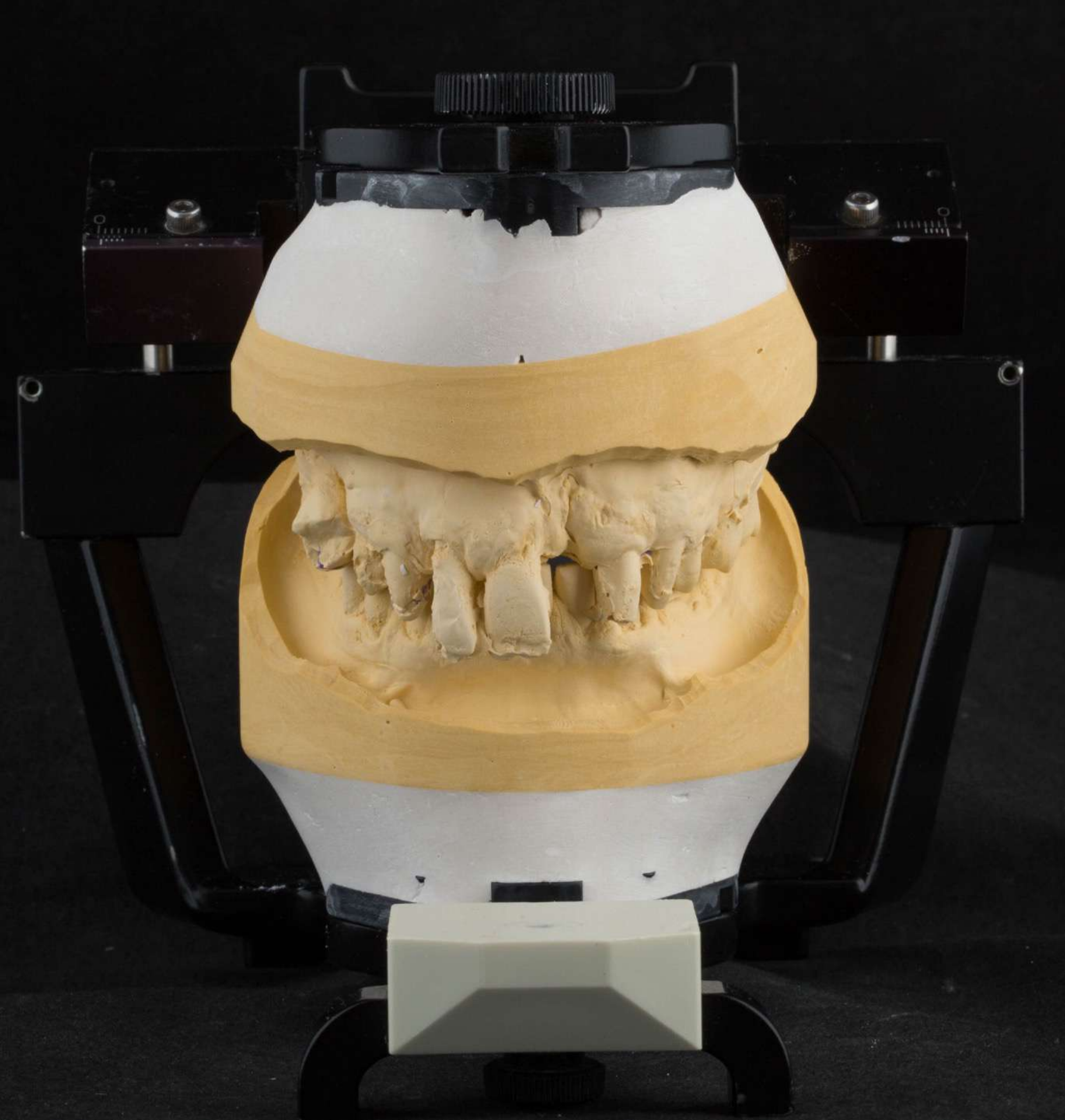

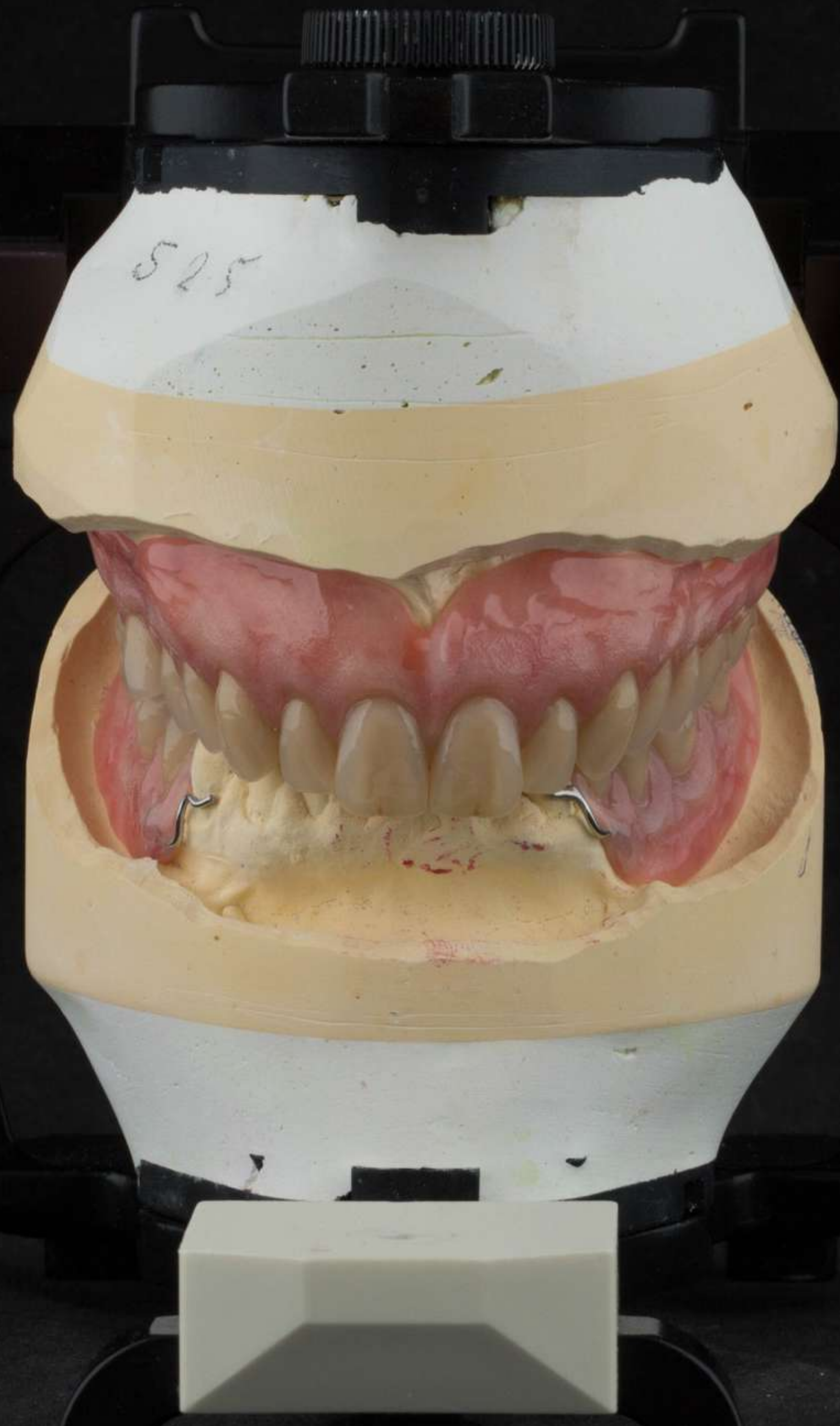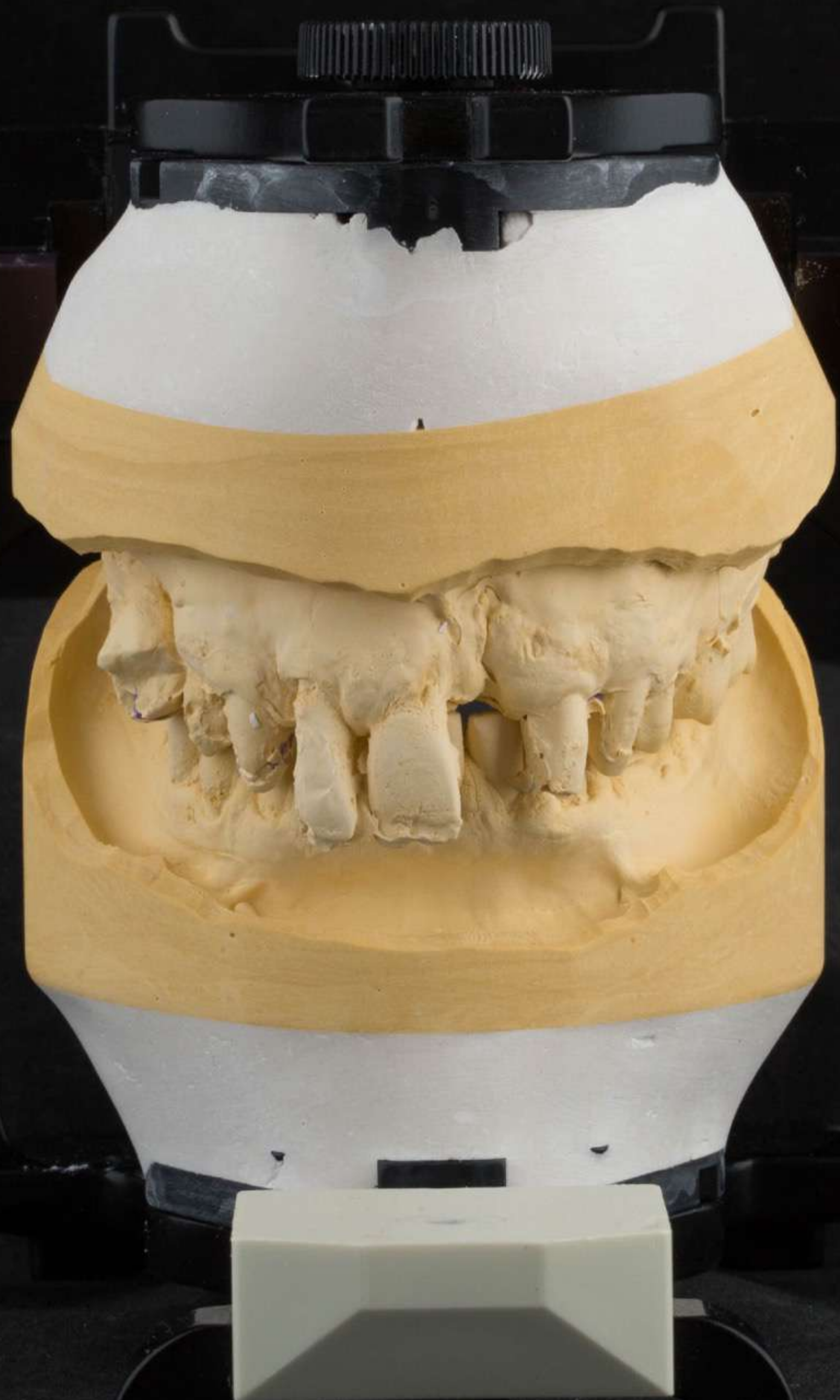




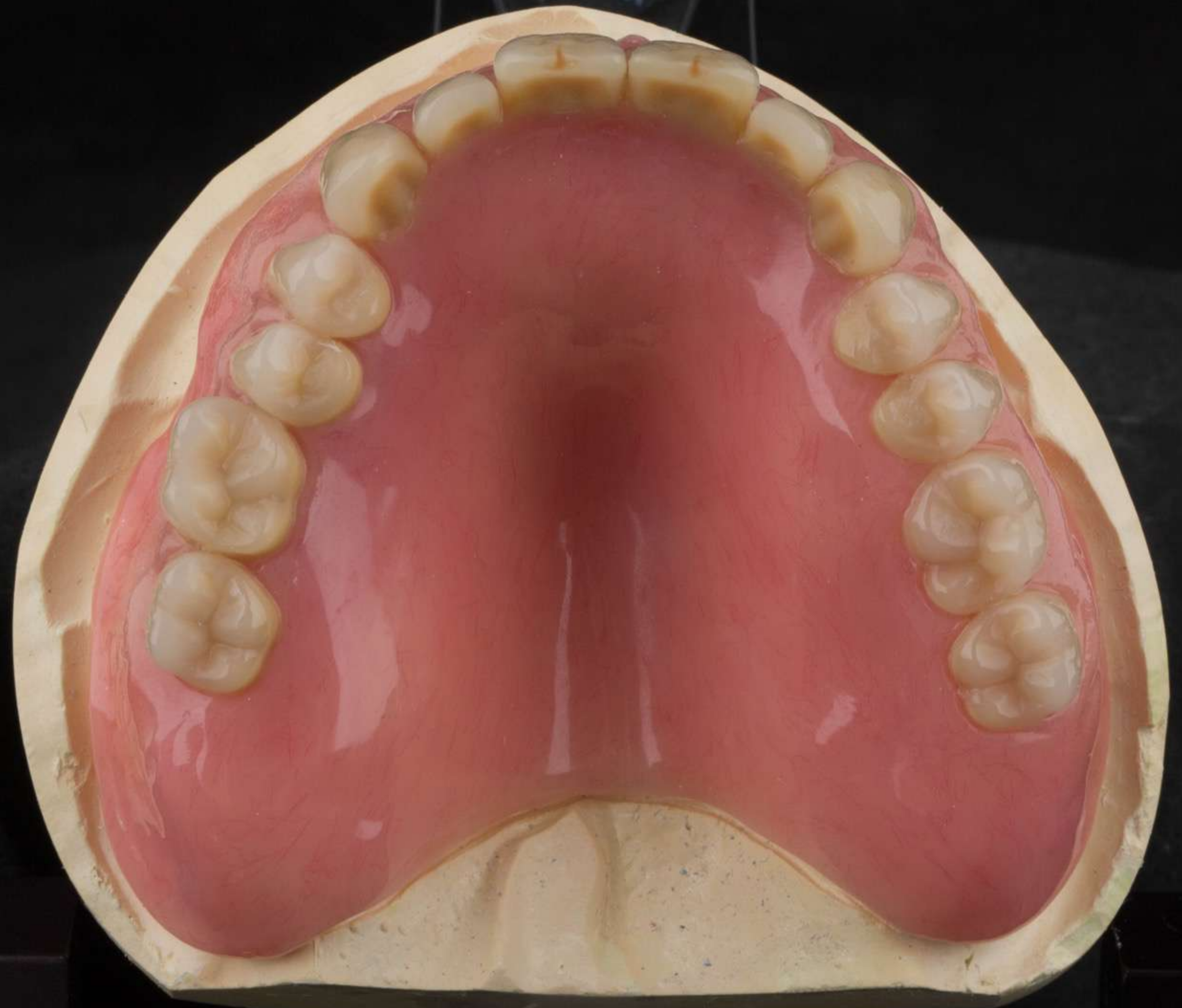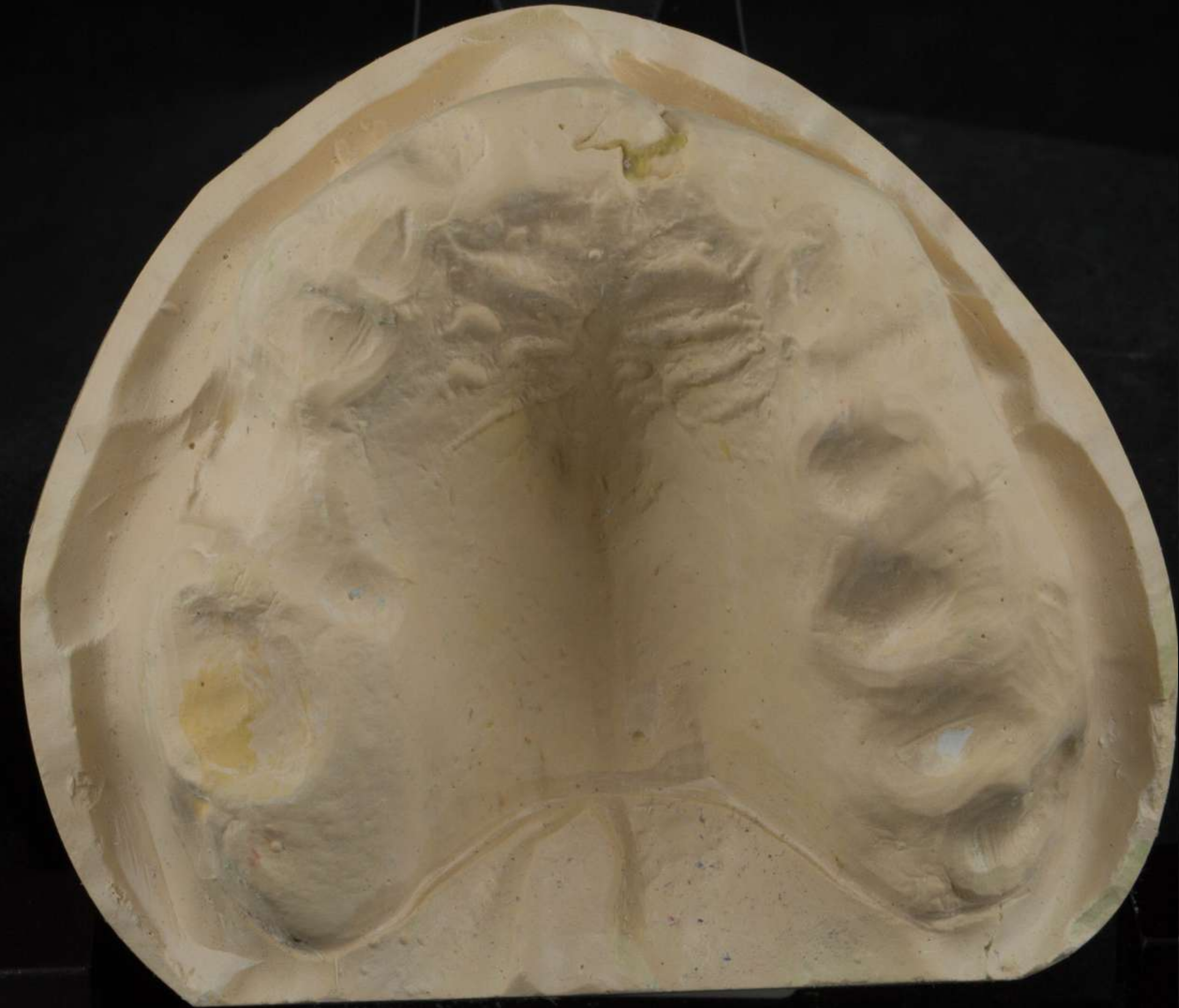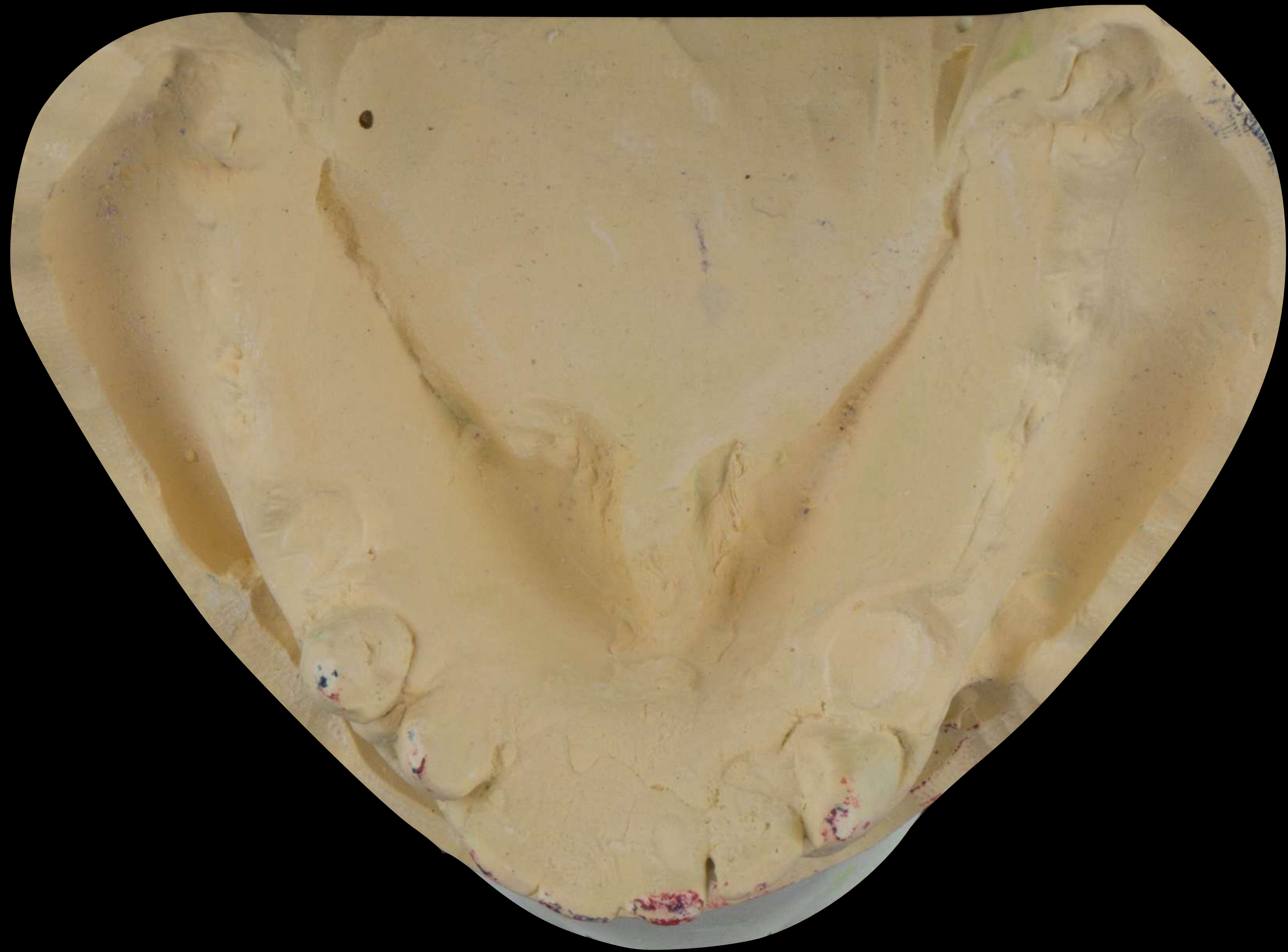






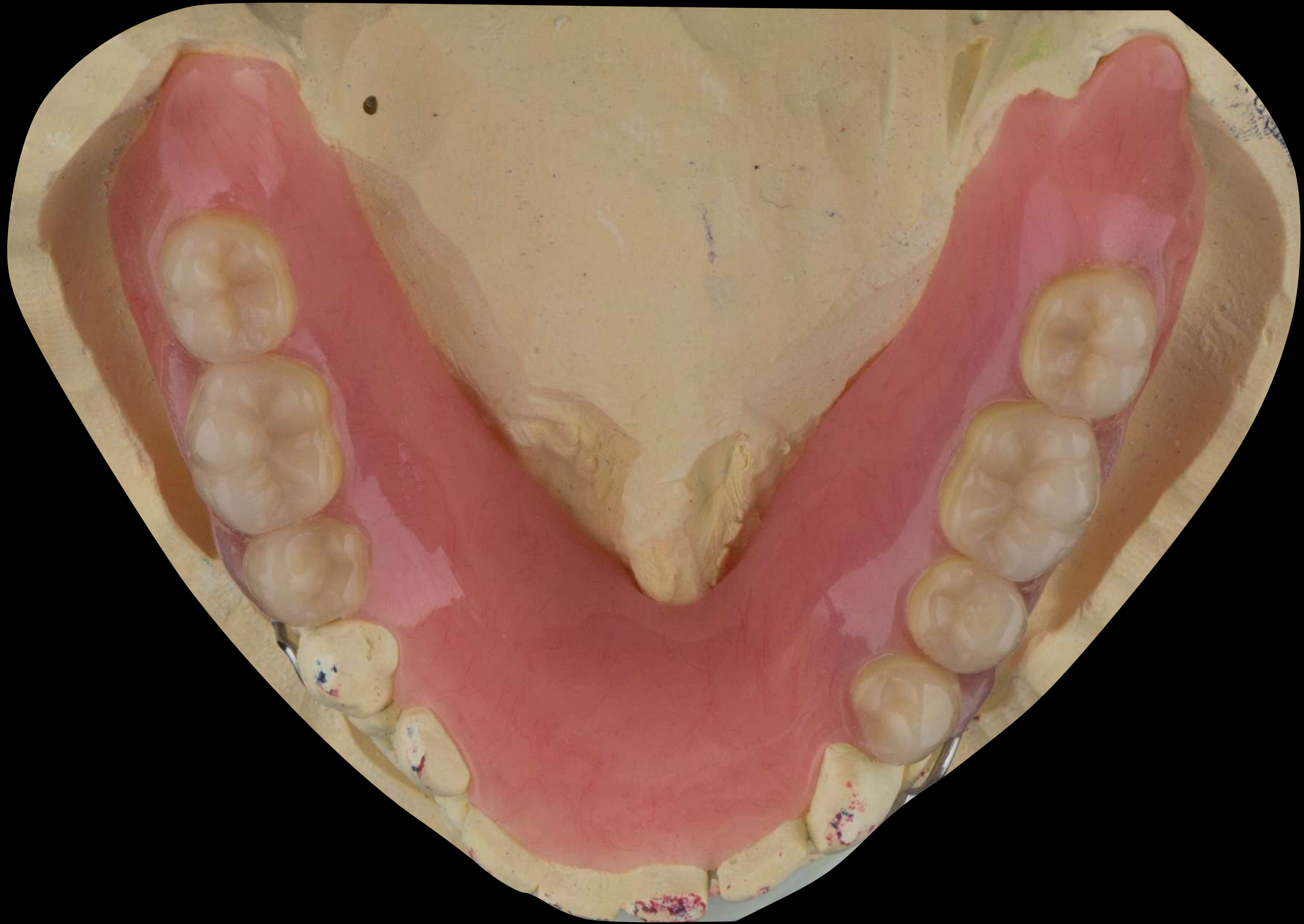




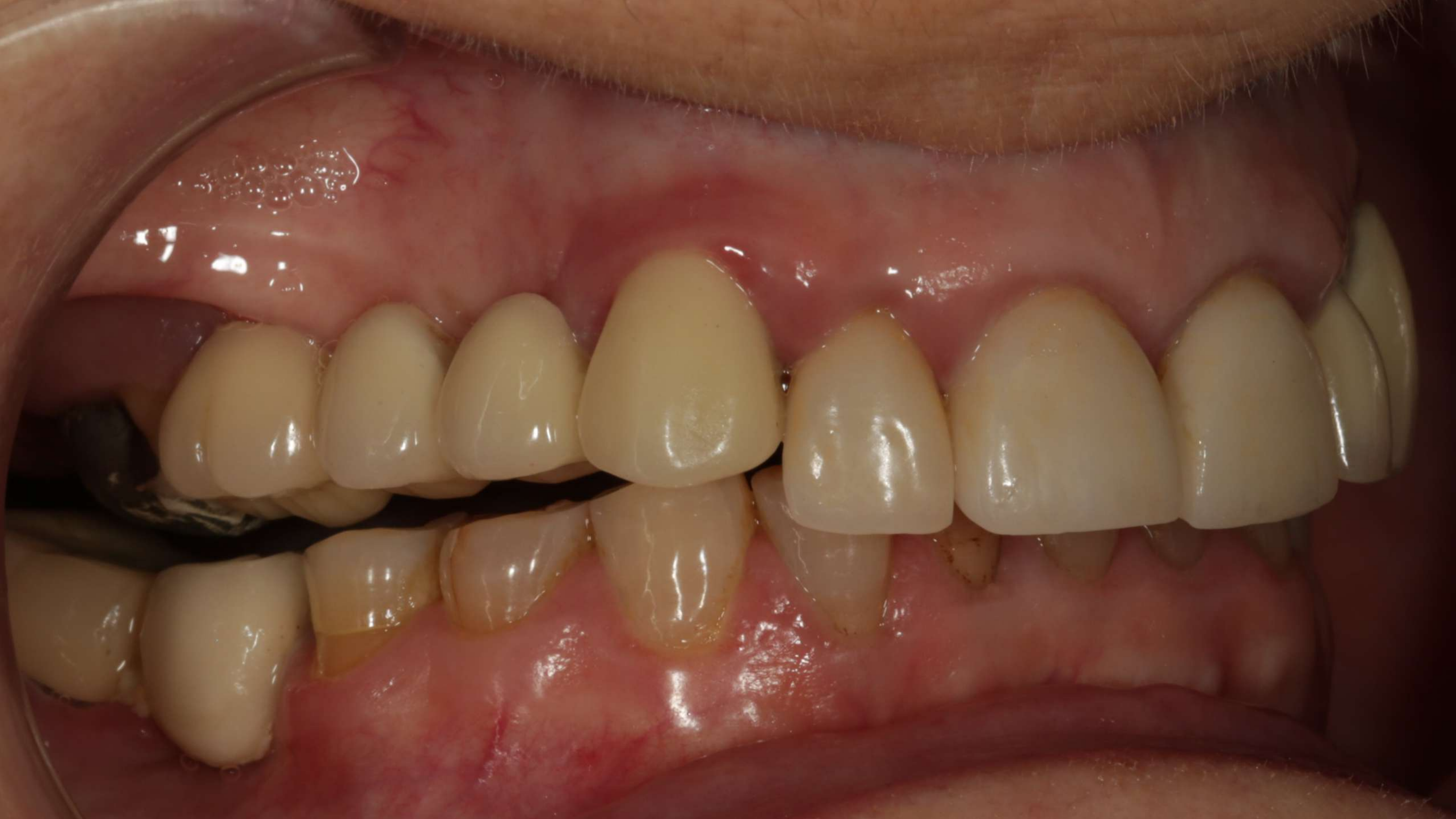


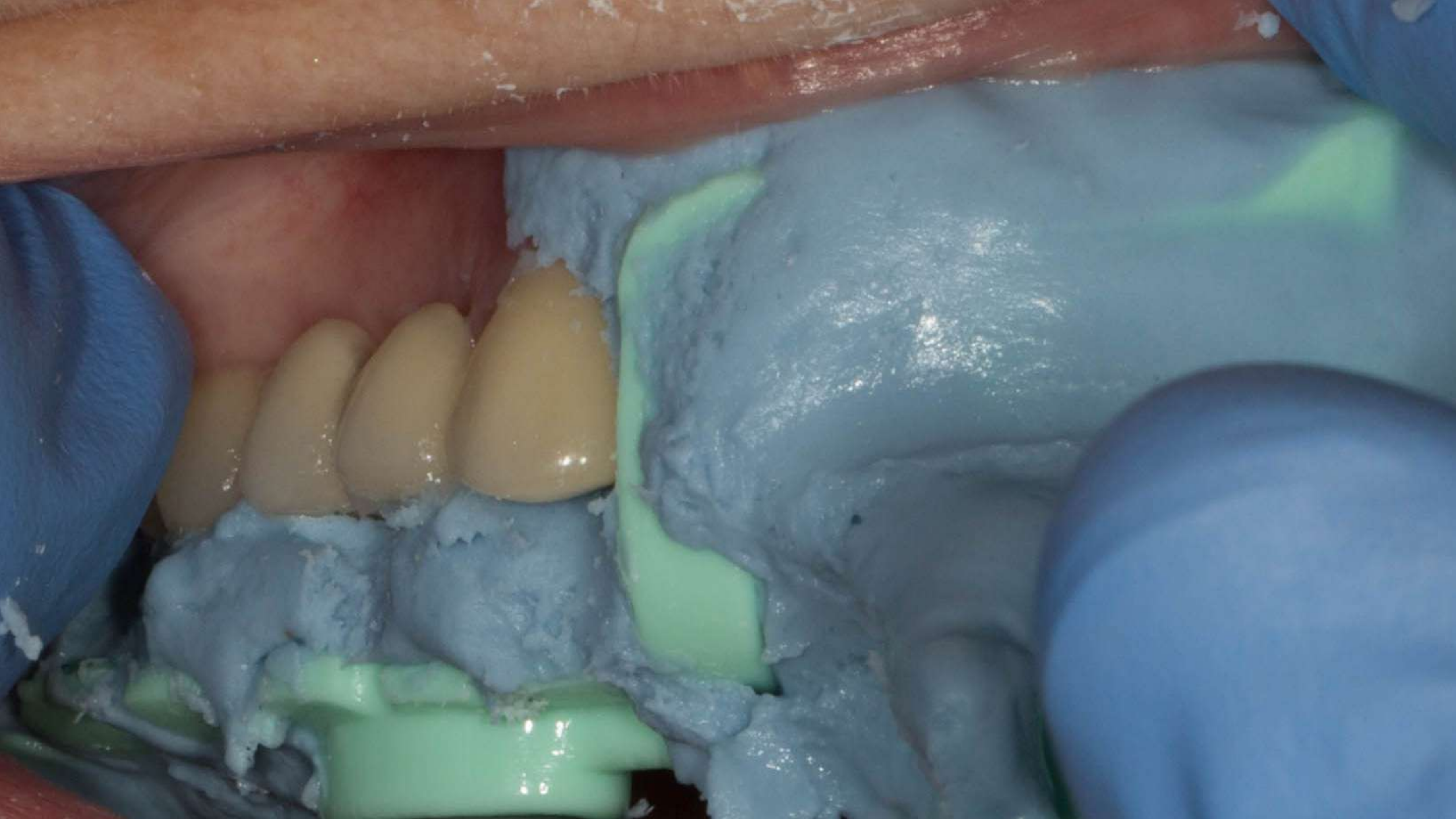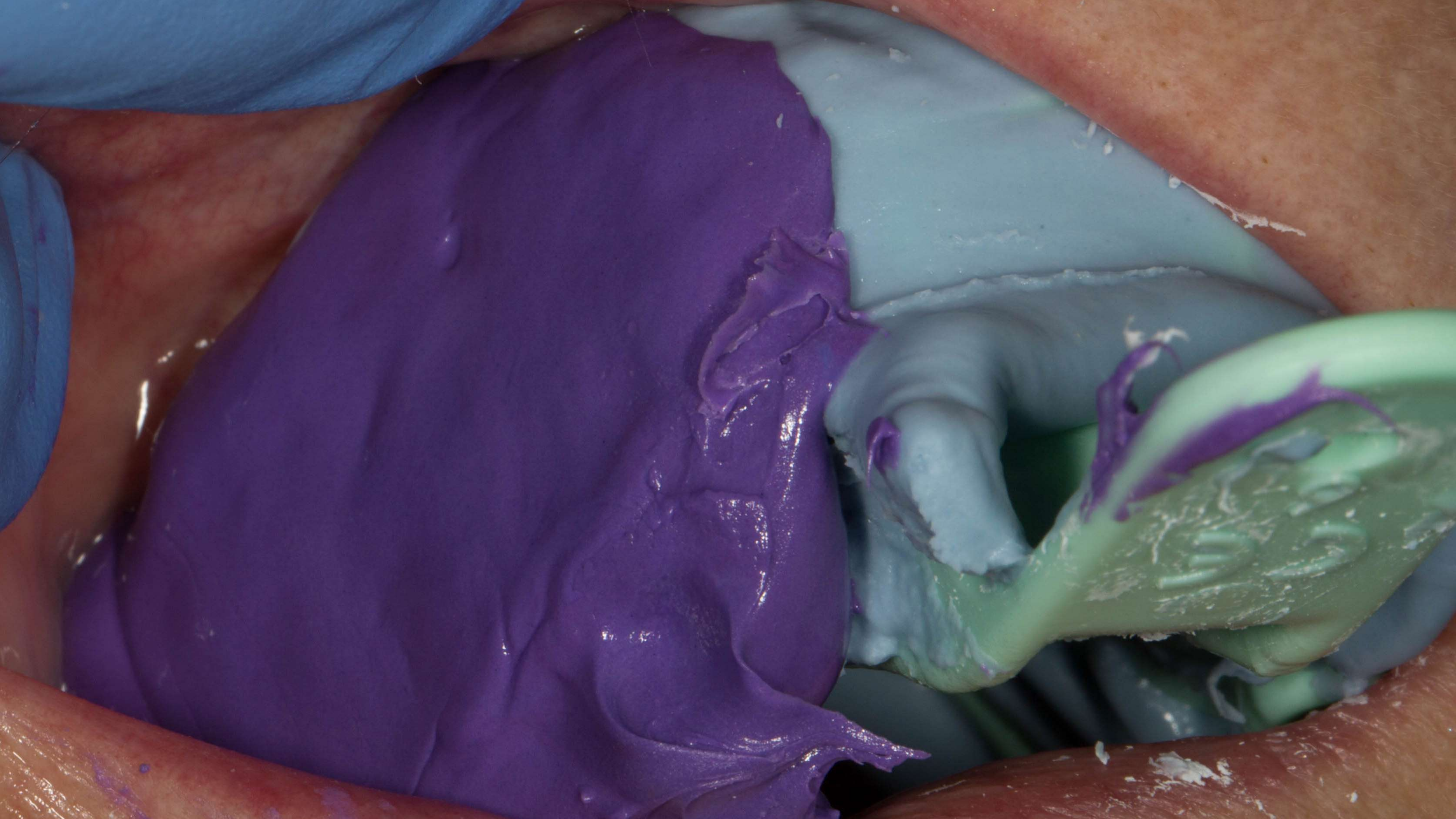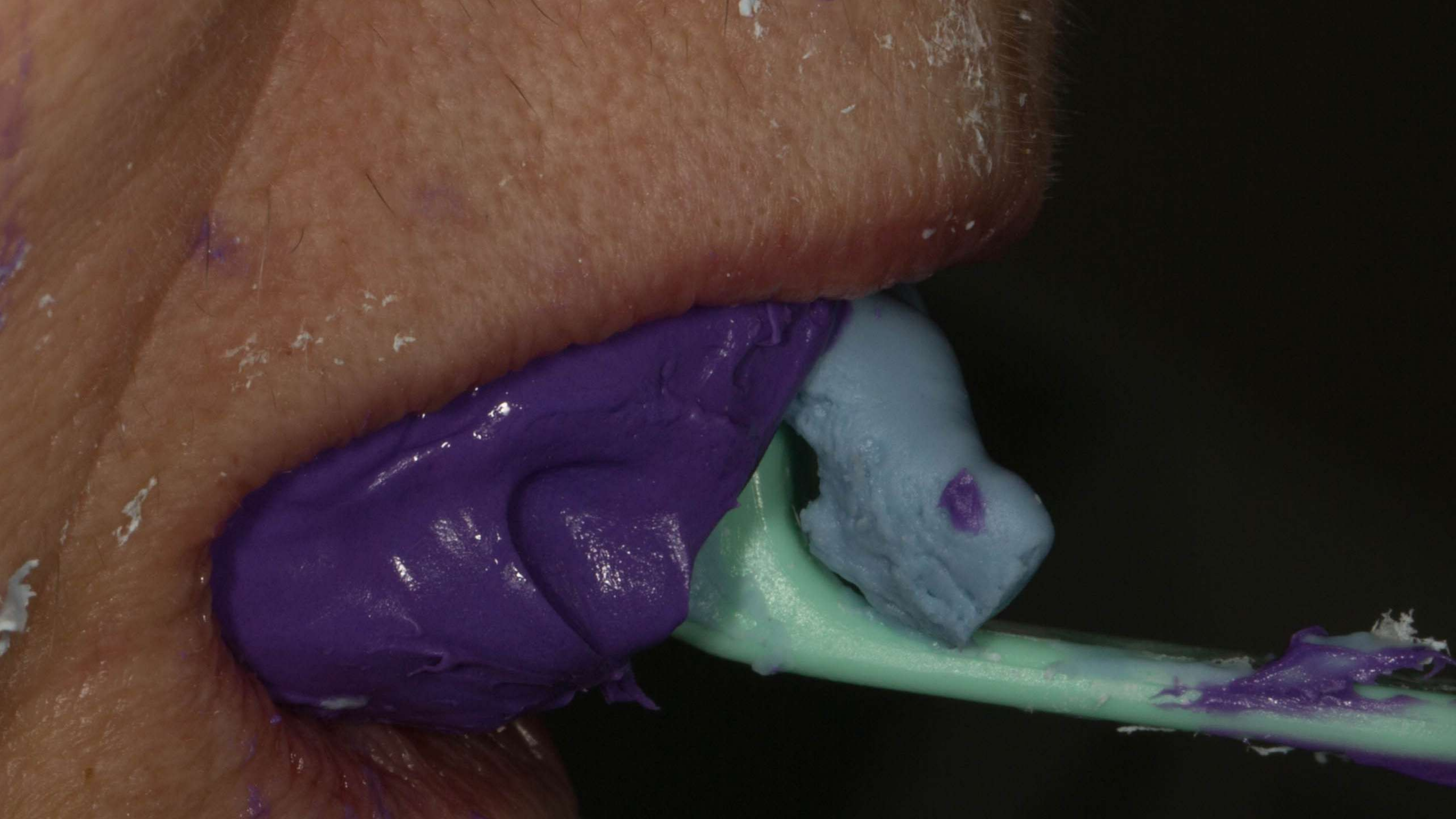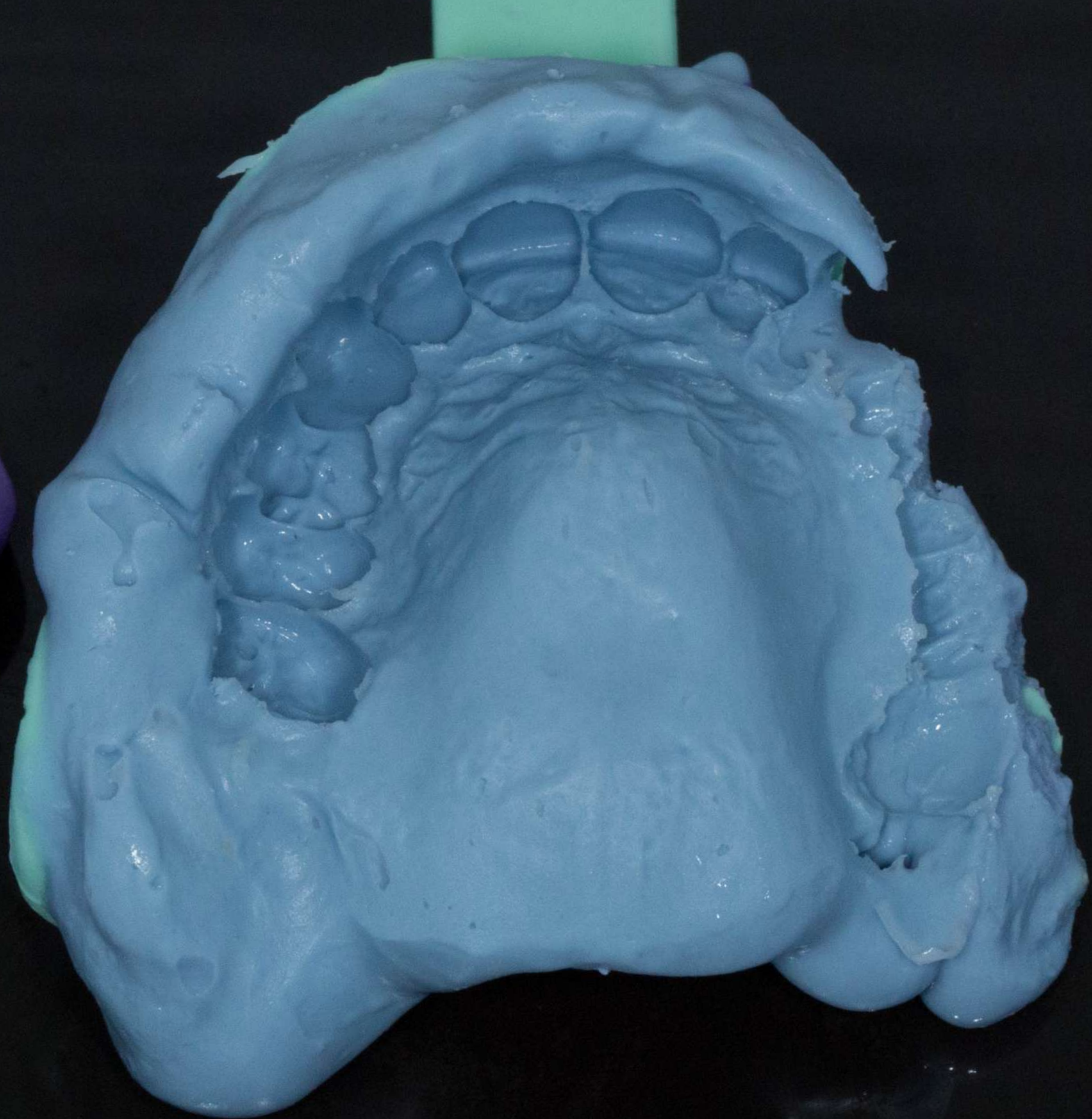


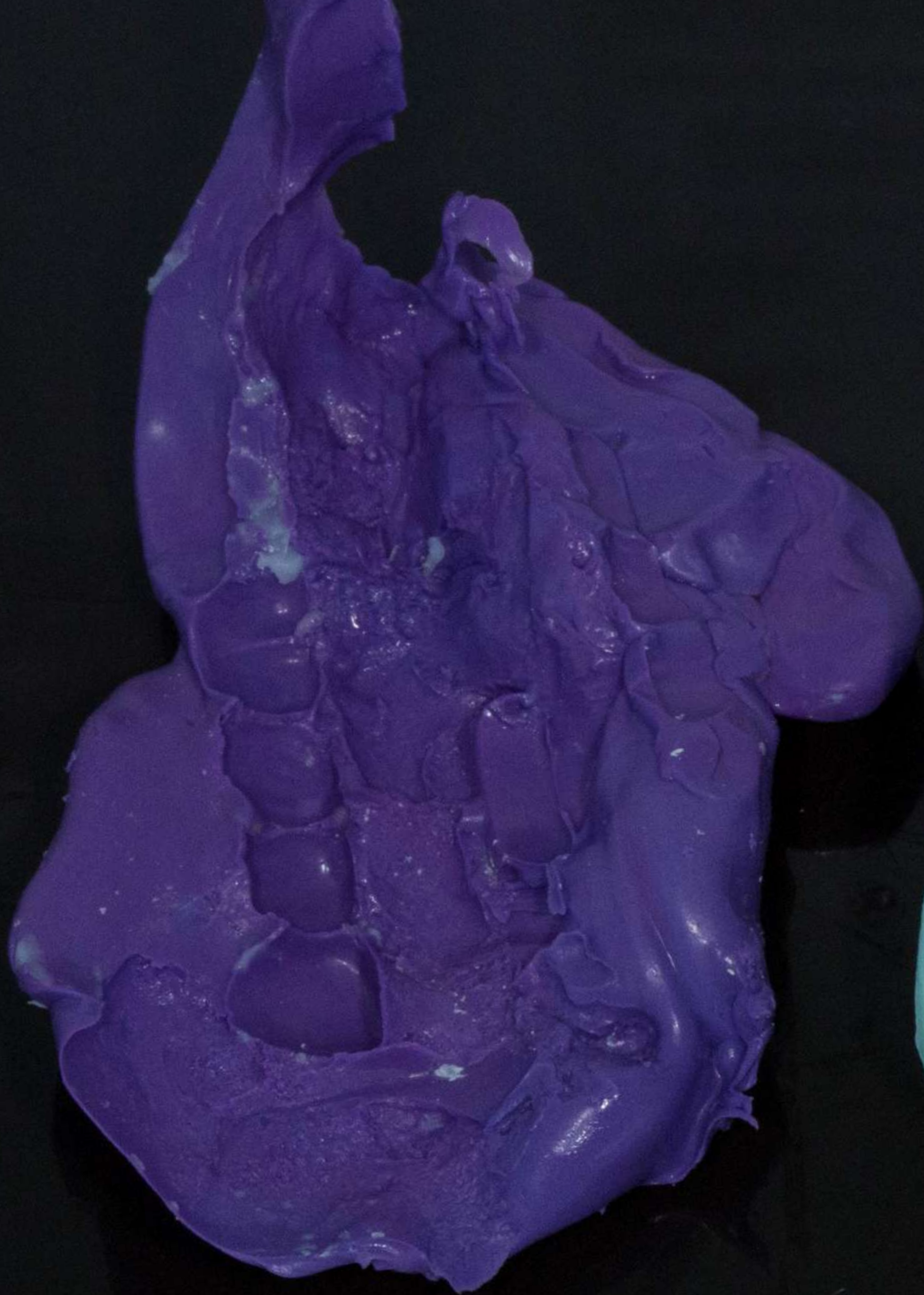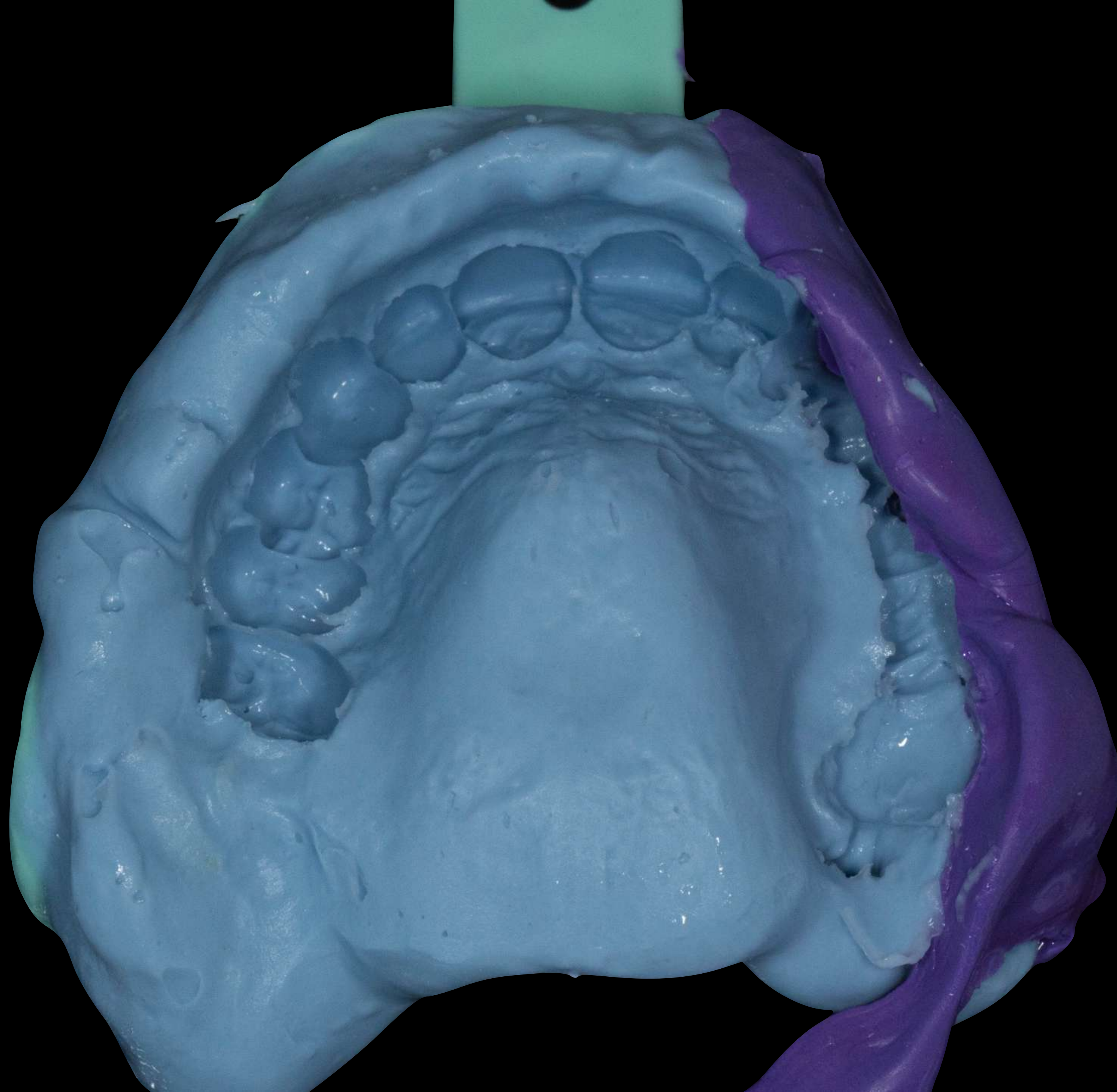














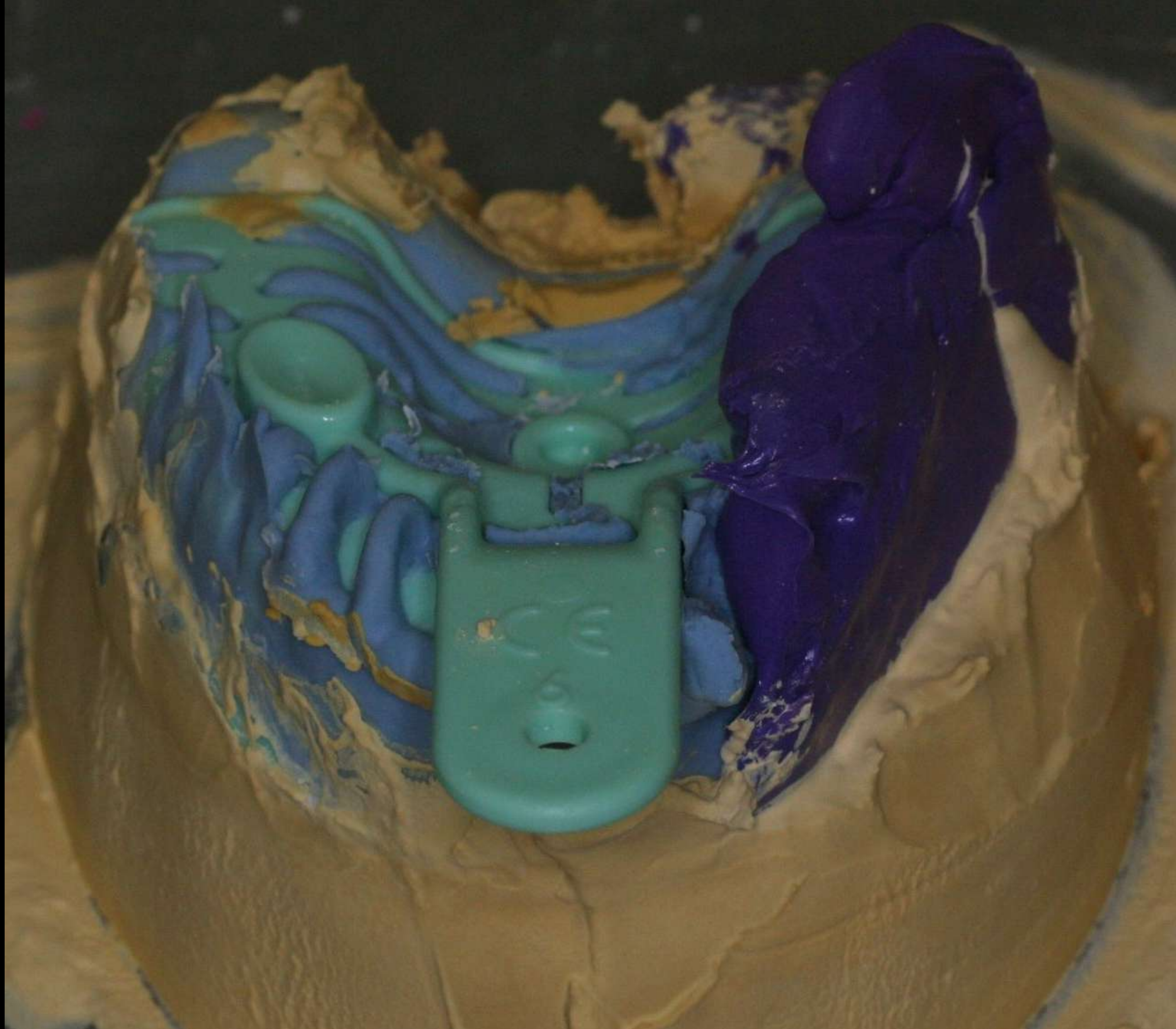




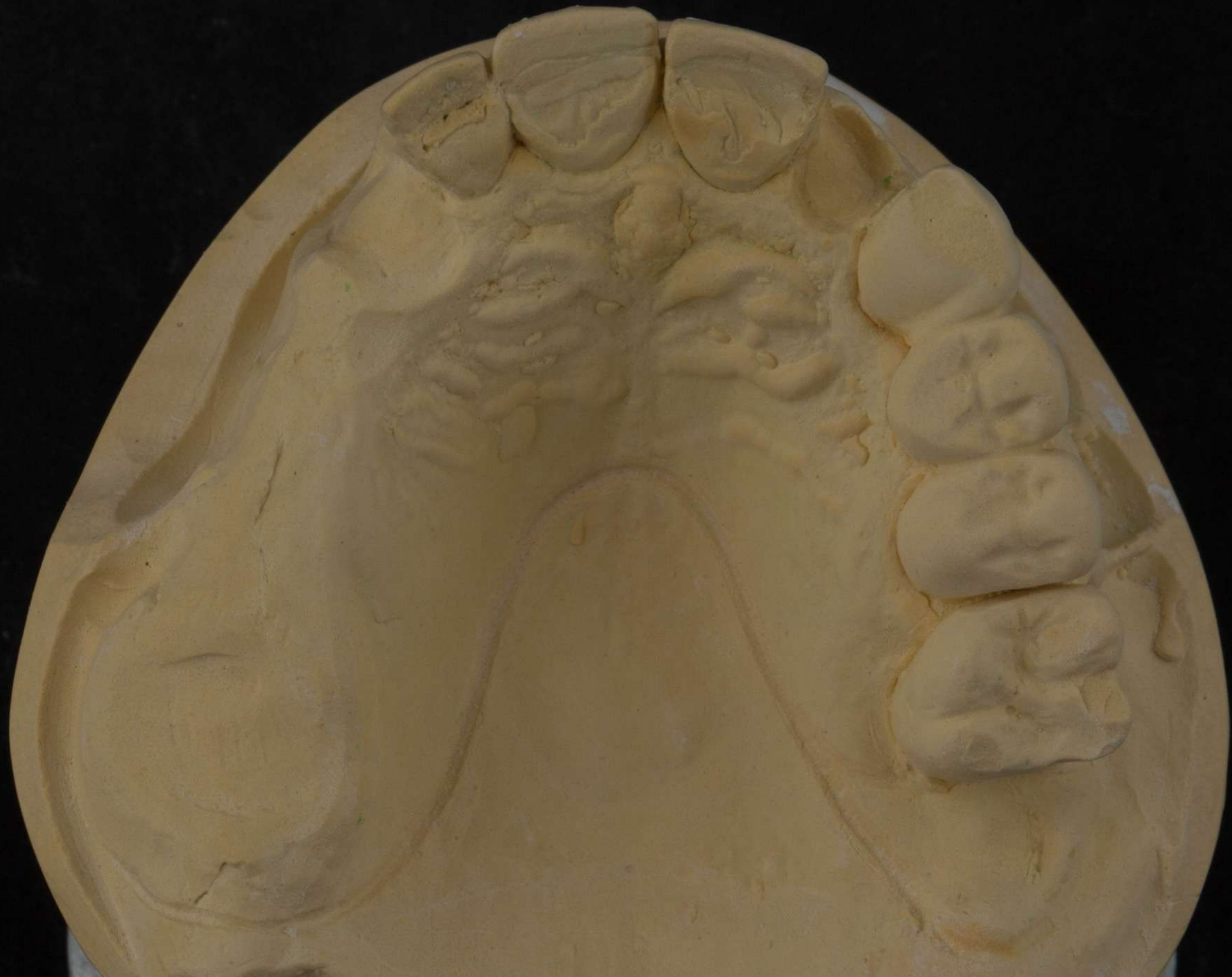


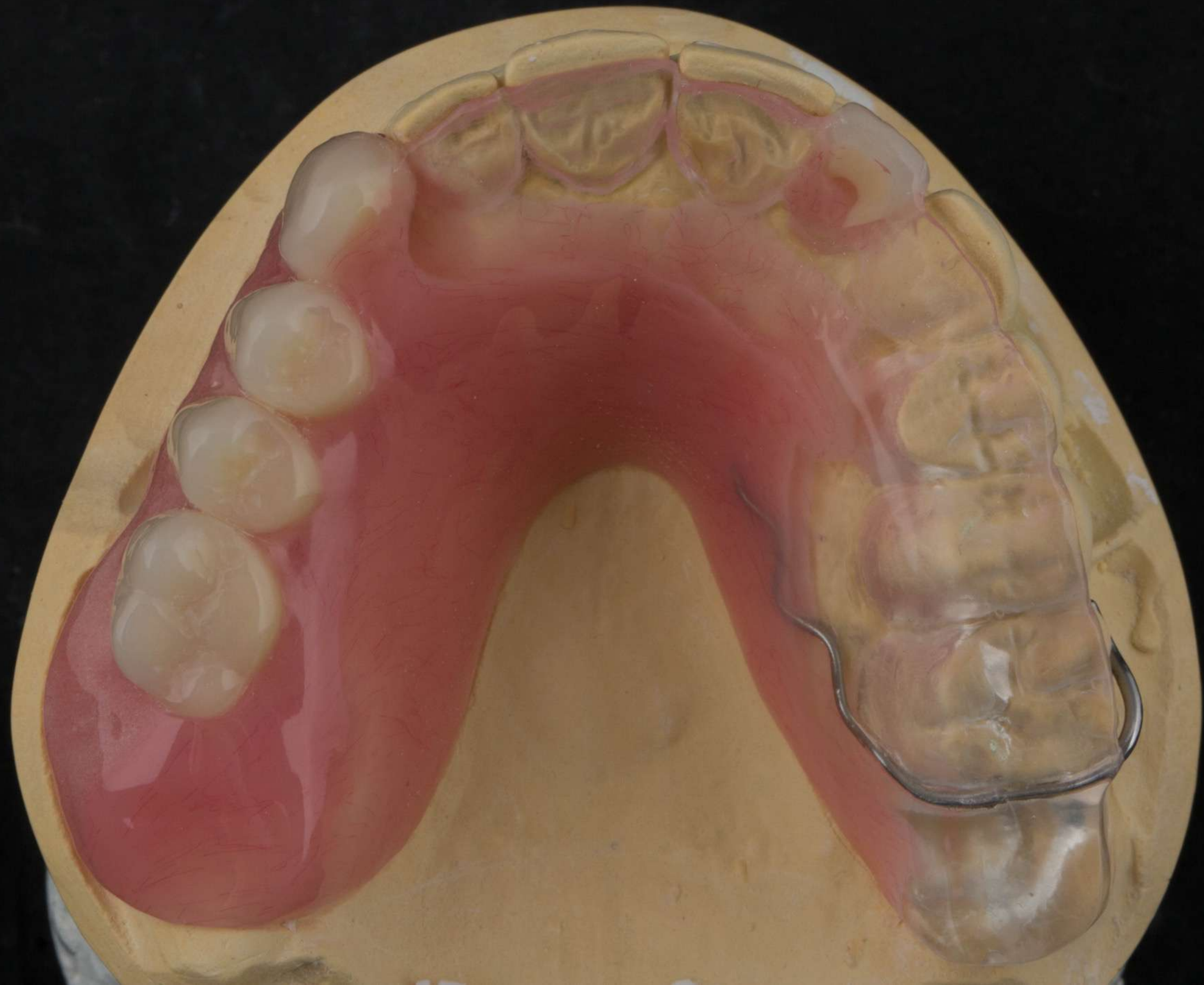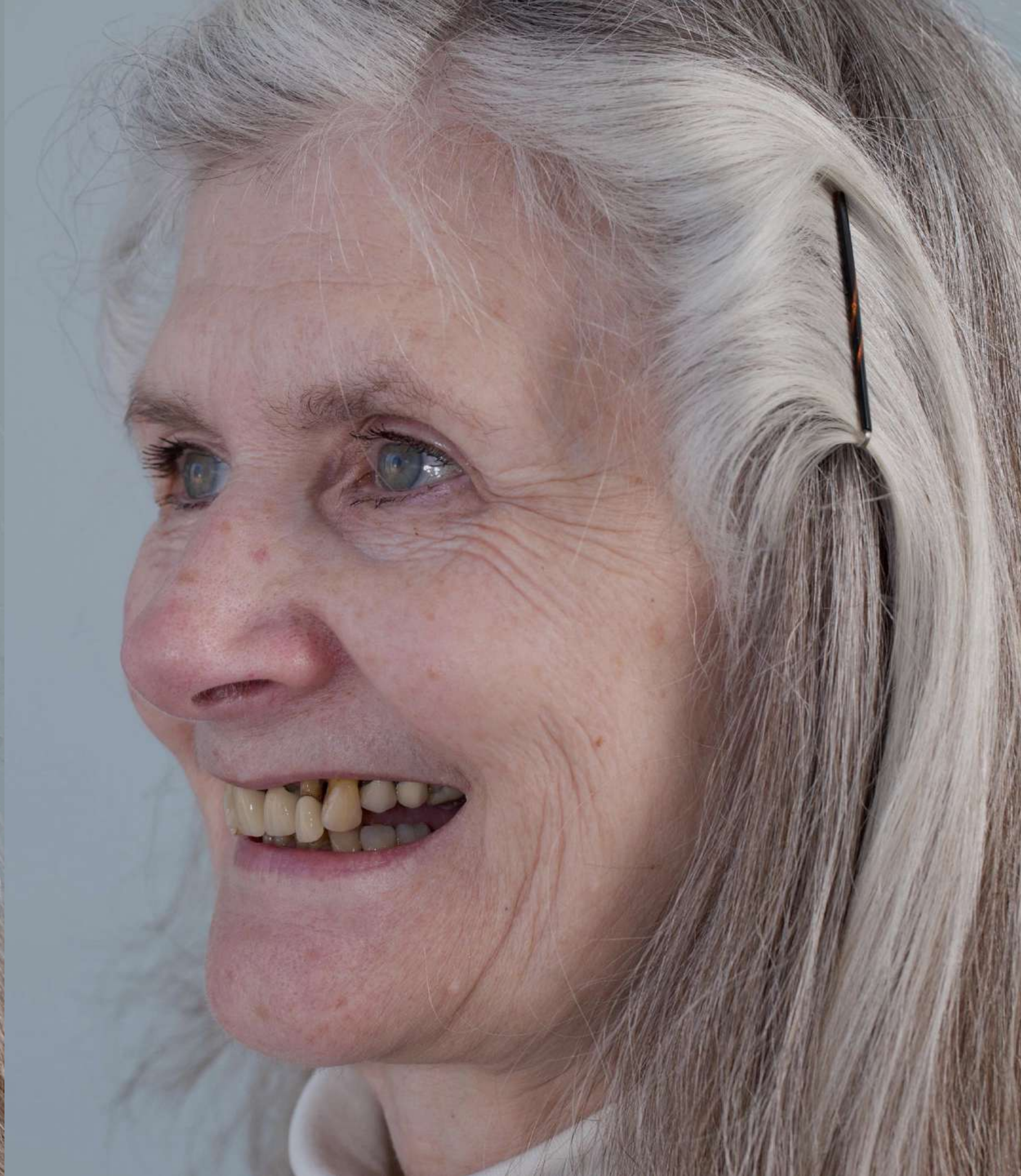*Make immediate denture*

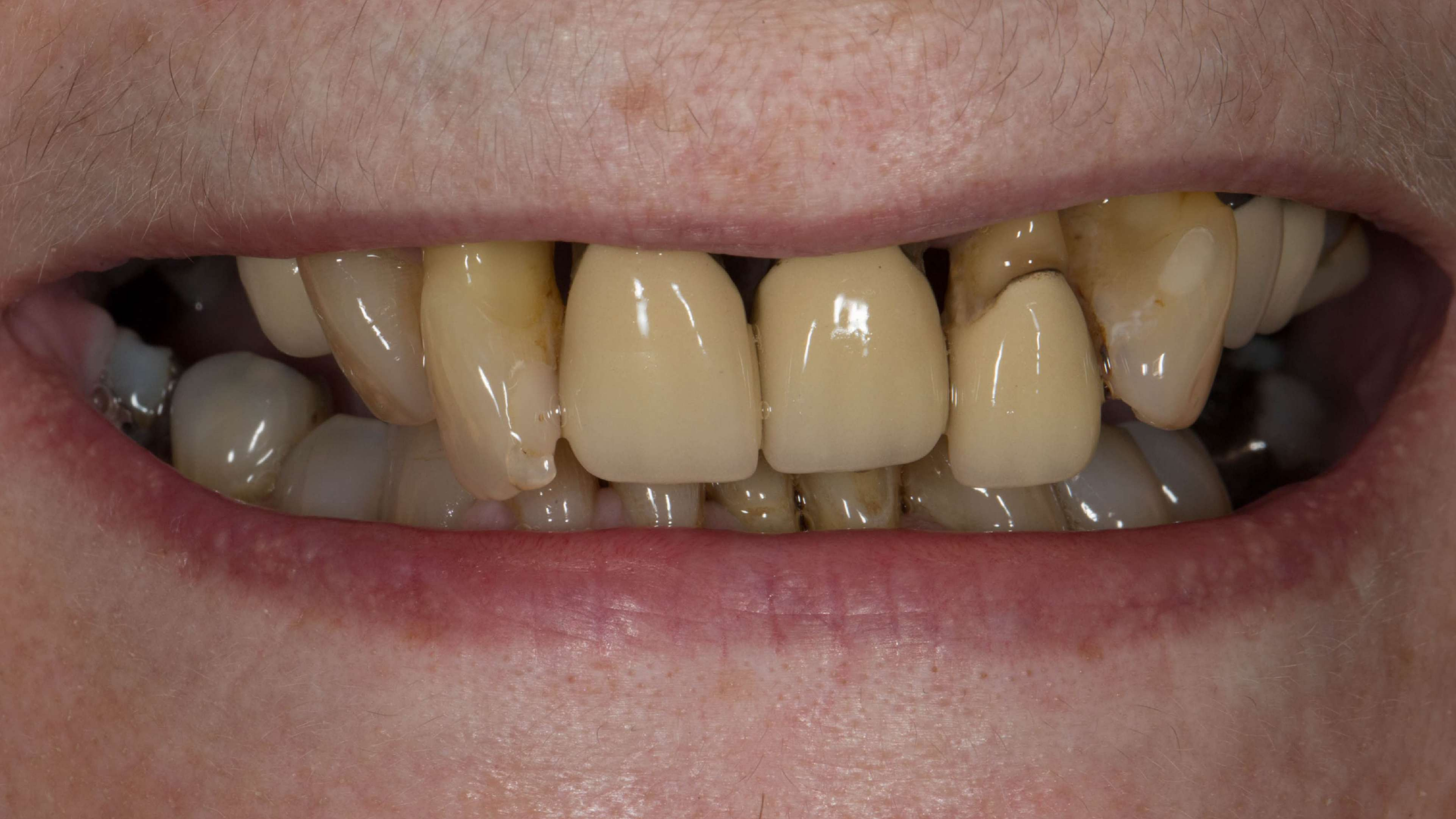*Remove teeth fit immediate - Viscogel*

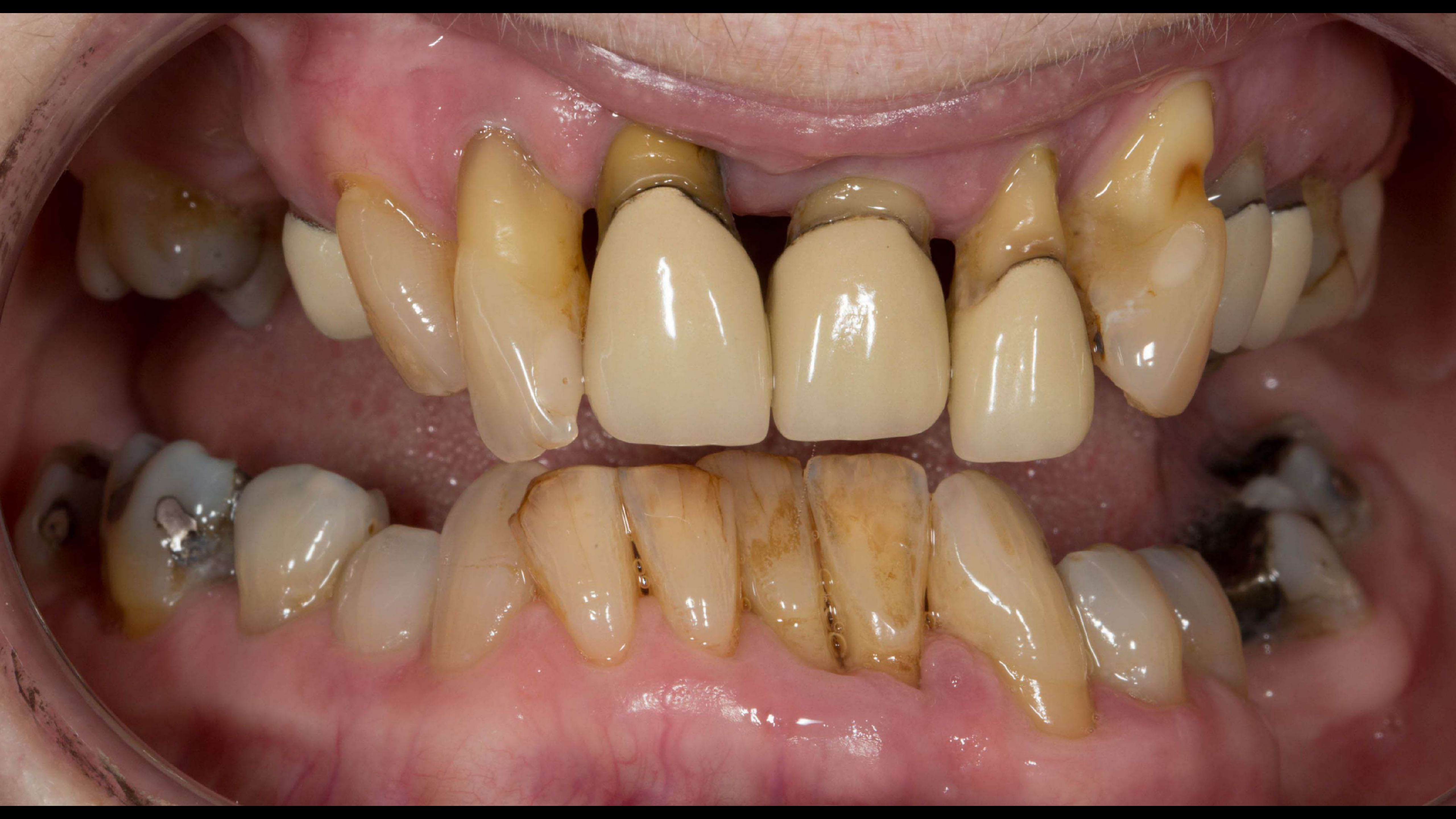*2 Months - chair side reline - Ufigel hard*

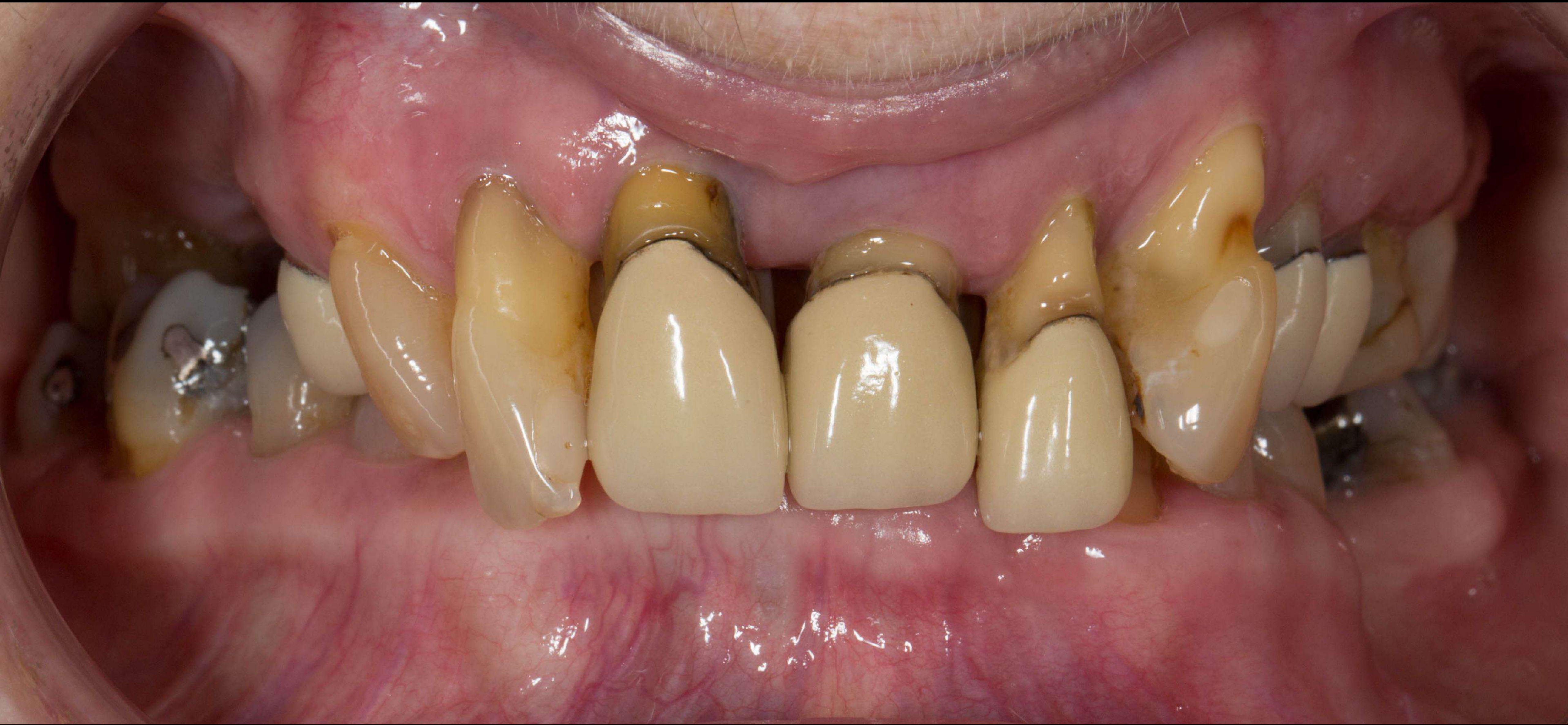*4 Months - Lab reline*

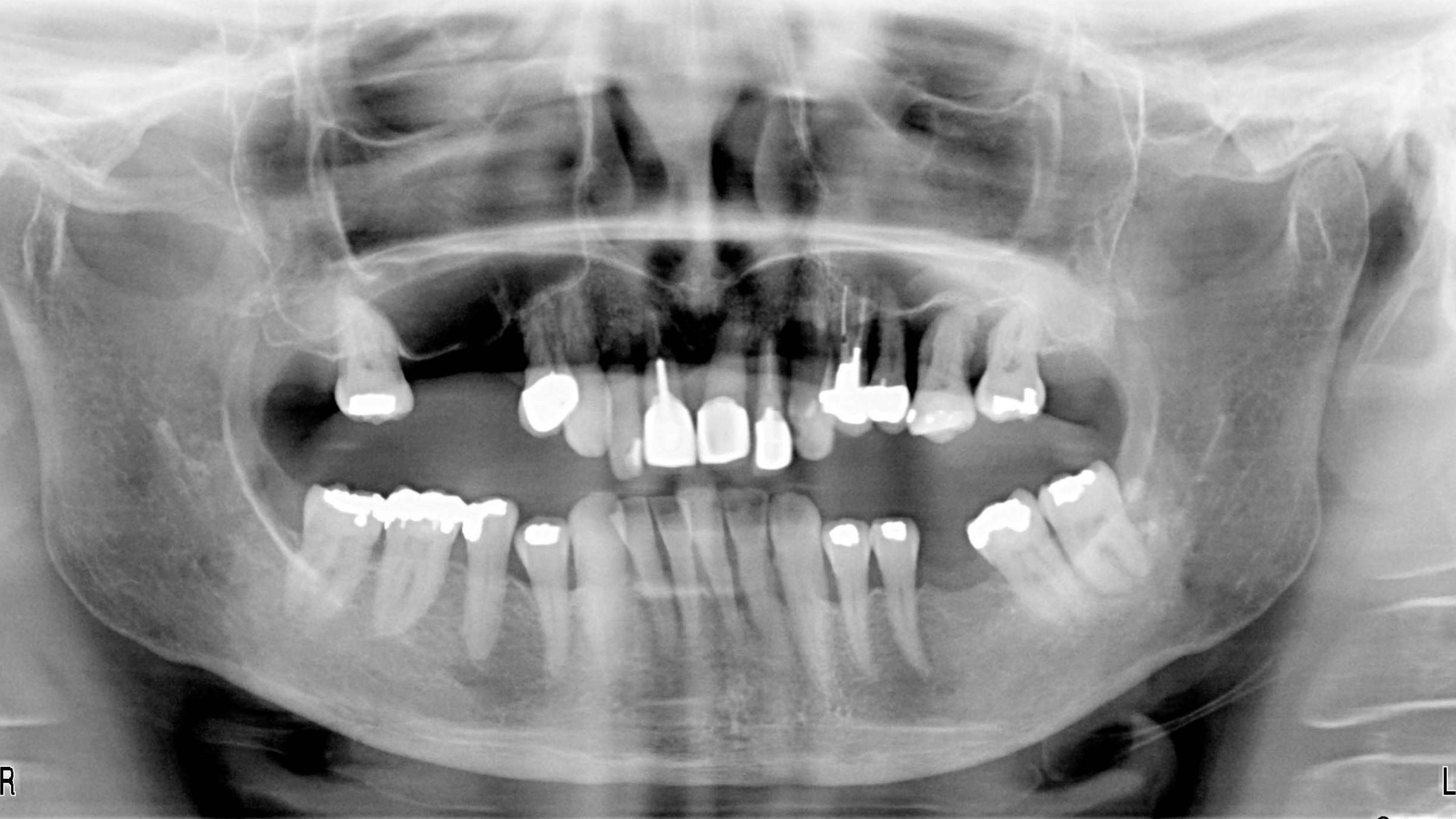*9 - 12 Months after extractions definitive denture*







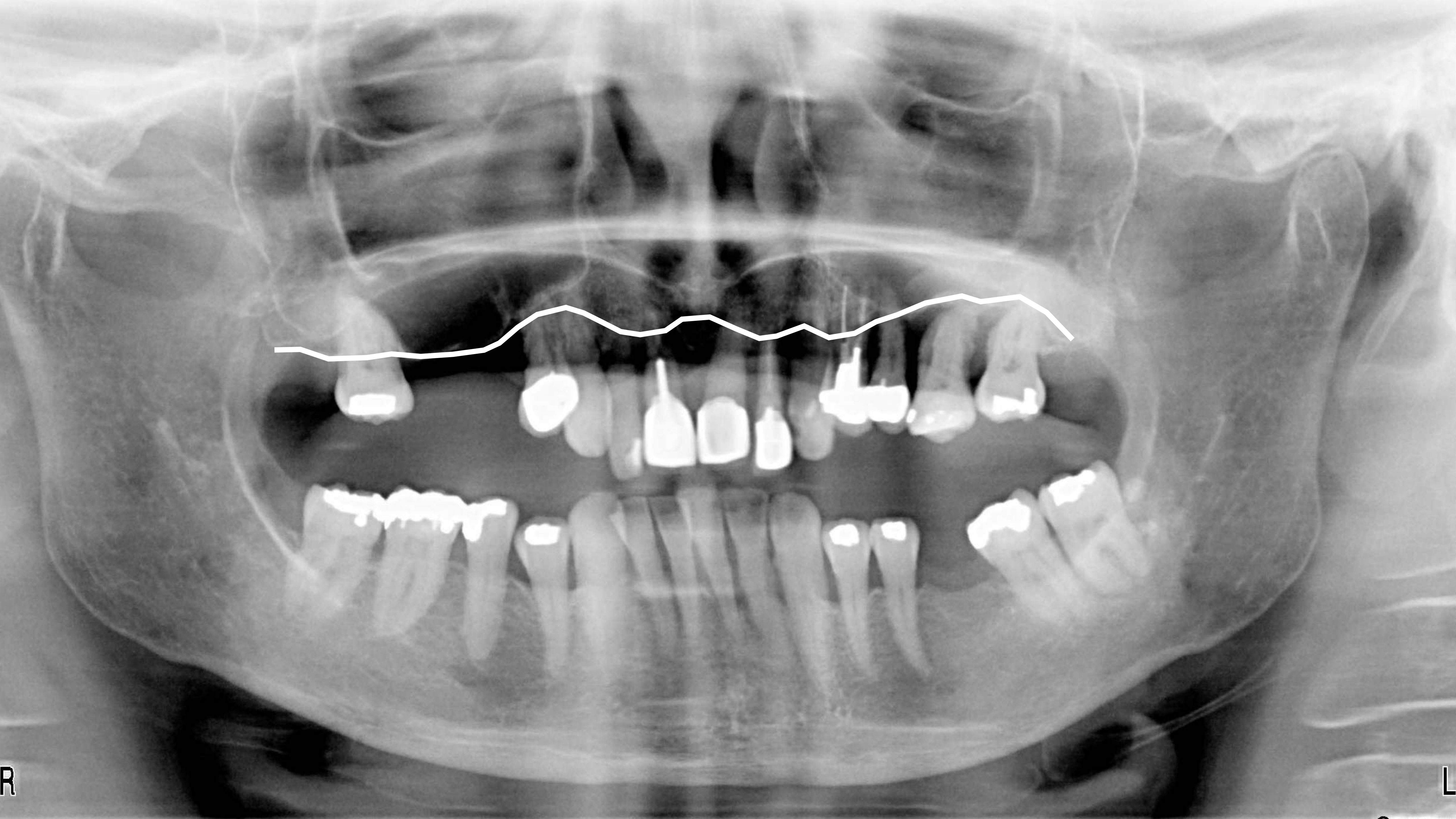




R

L





R

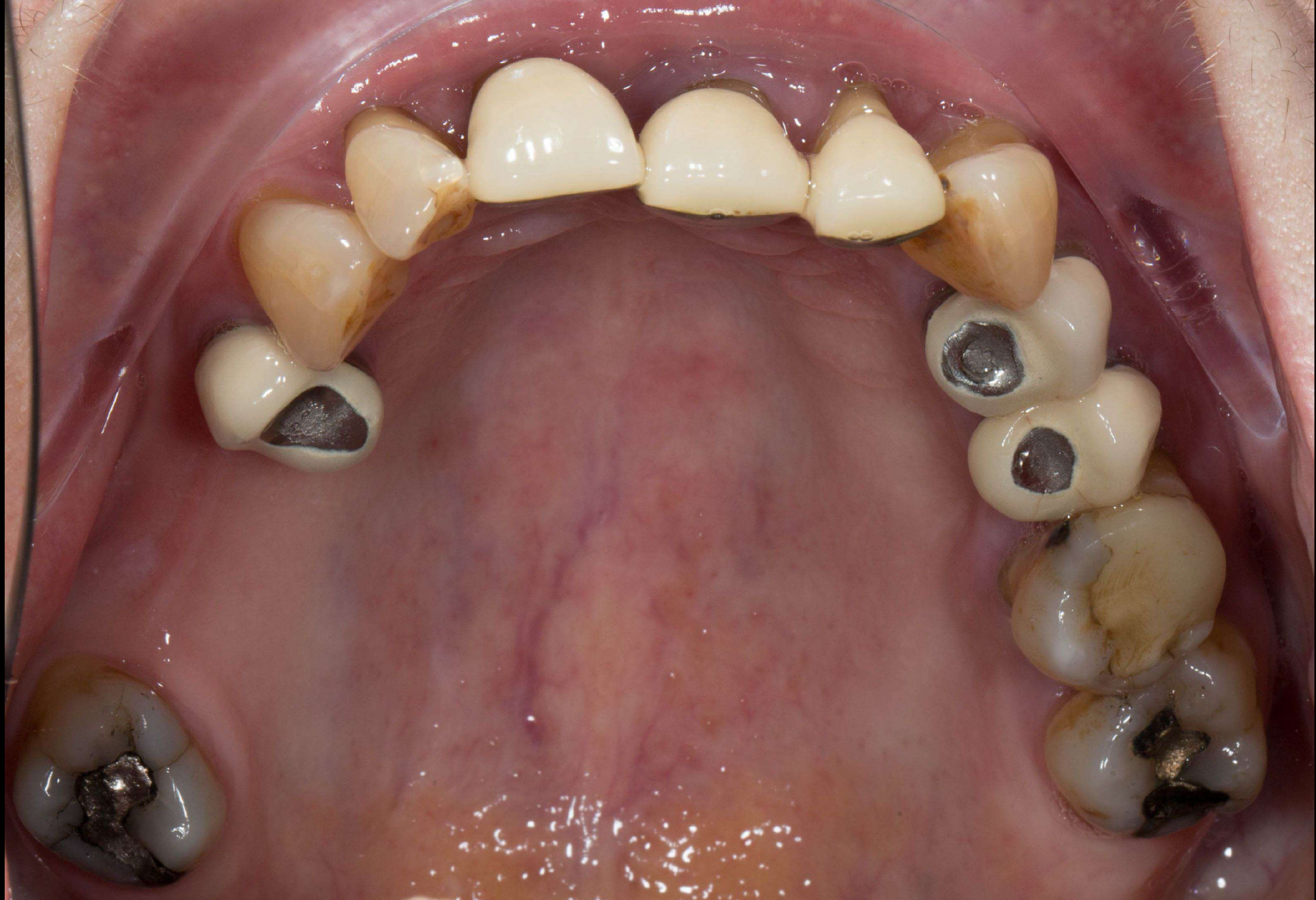L

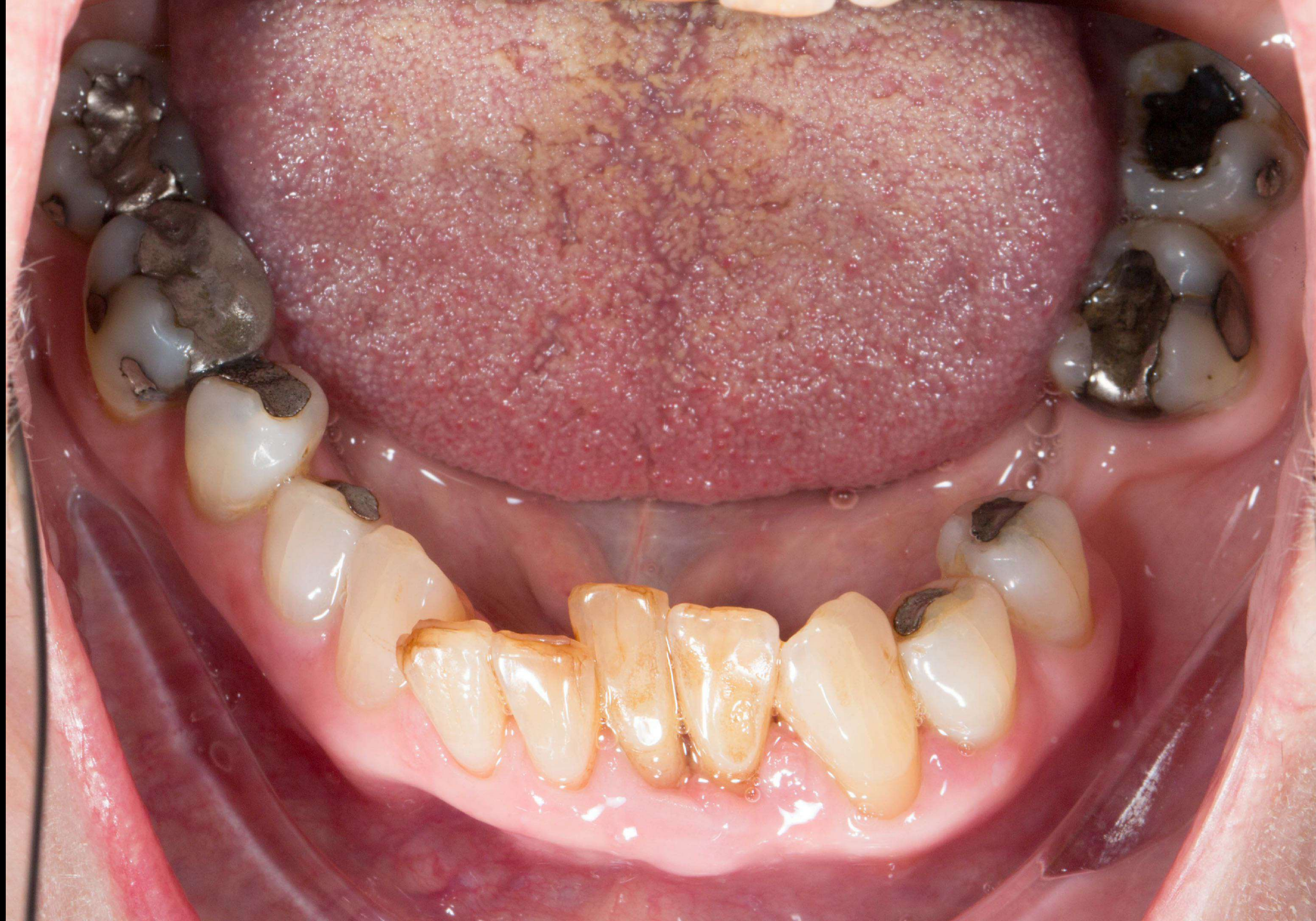

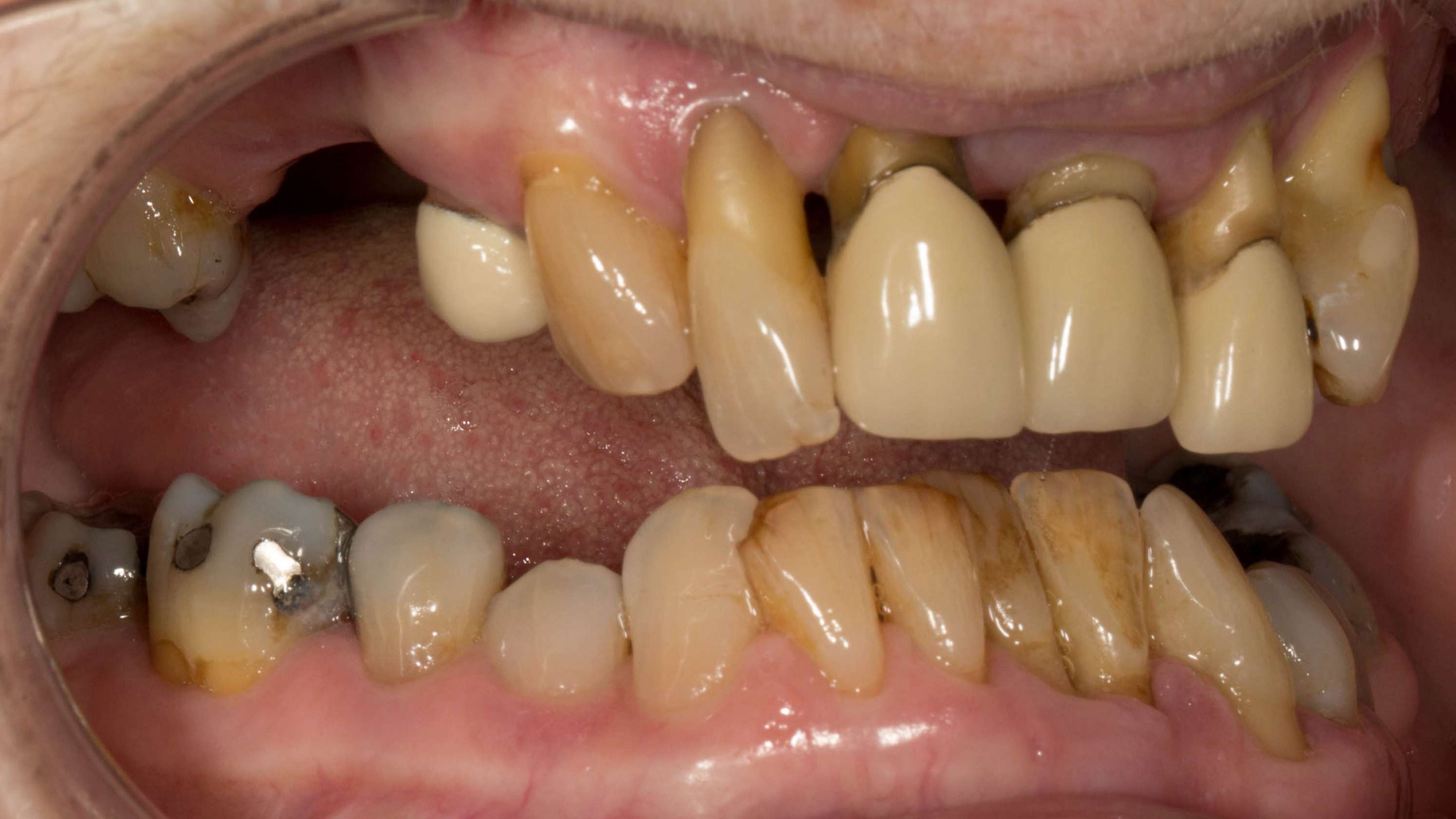C/- Acrylic based immediate window

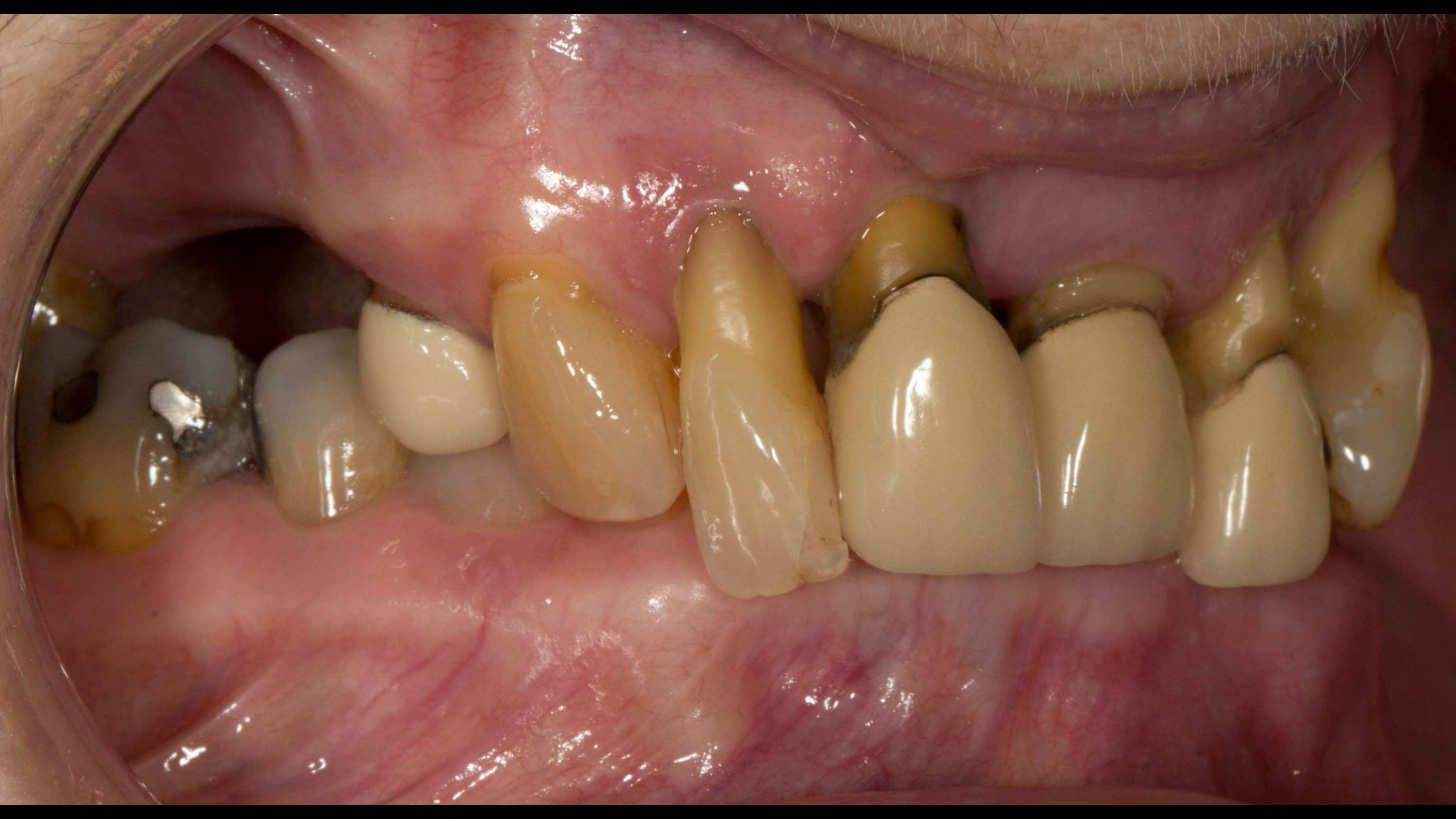NS periodontal therapy

C/- Metal base window

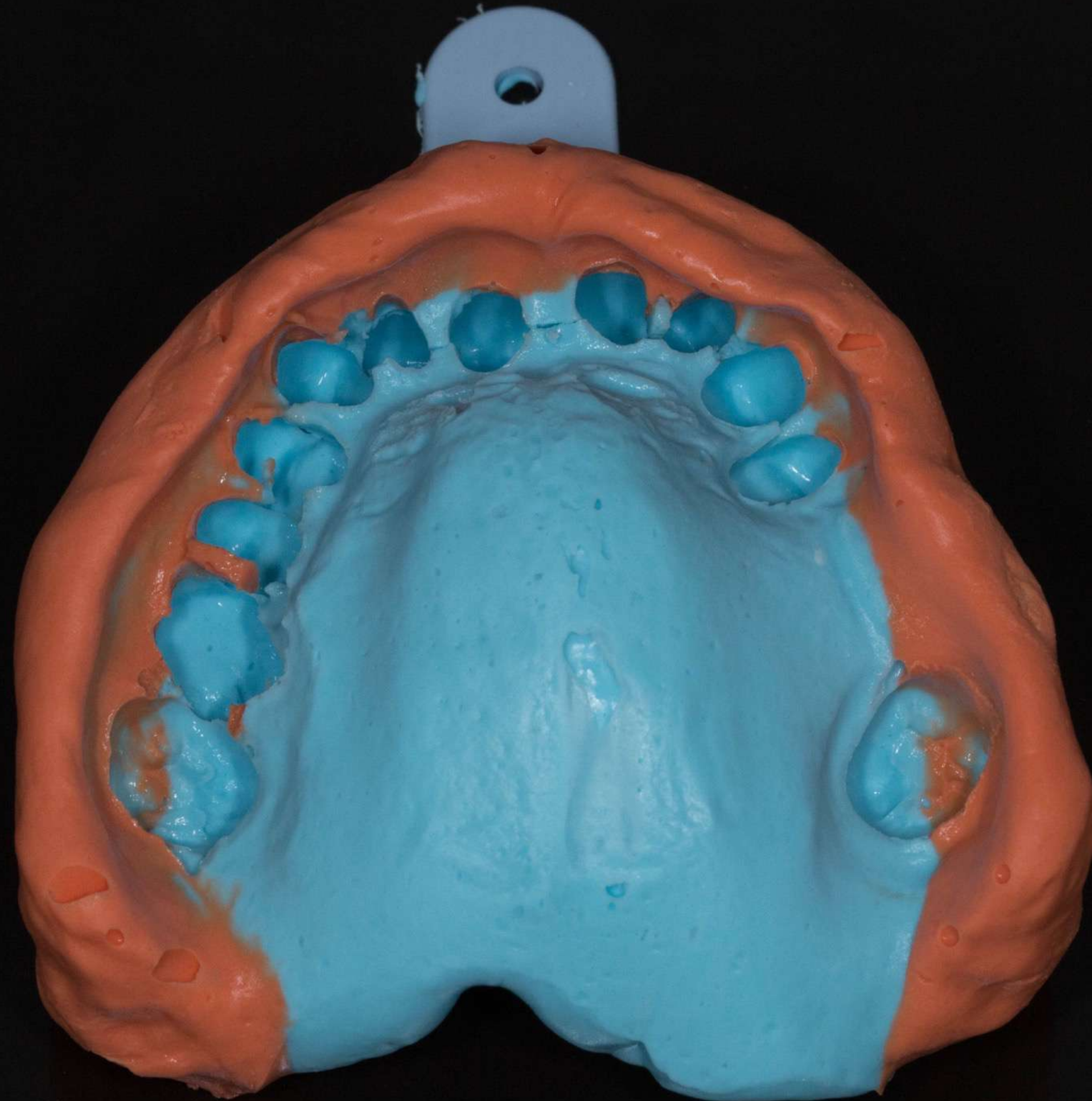




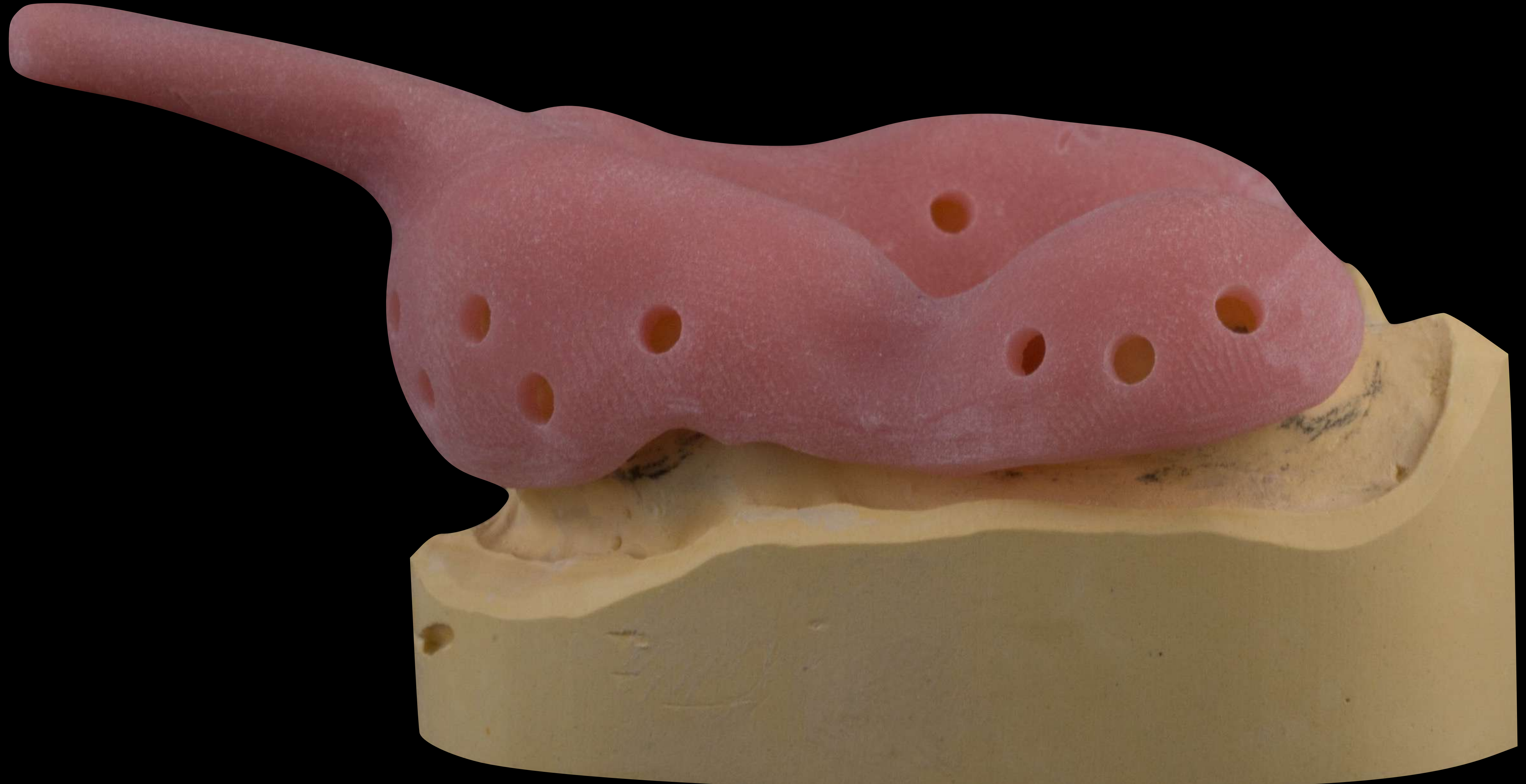



Visit 1

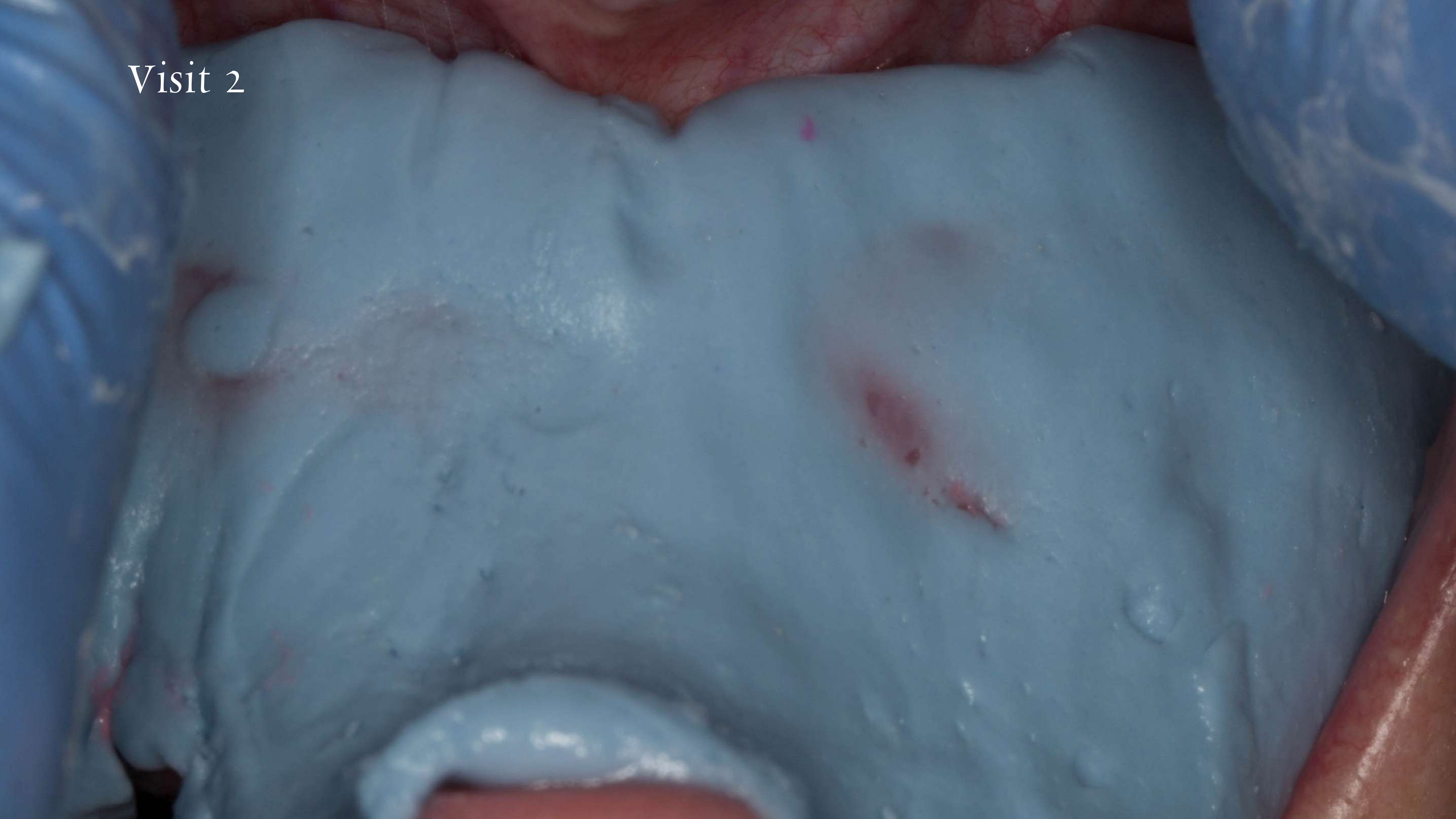

Visit 2

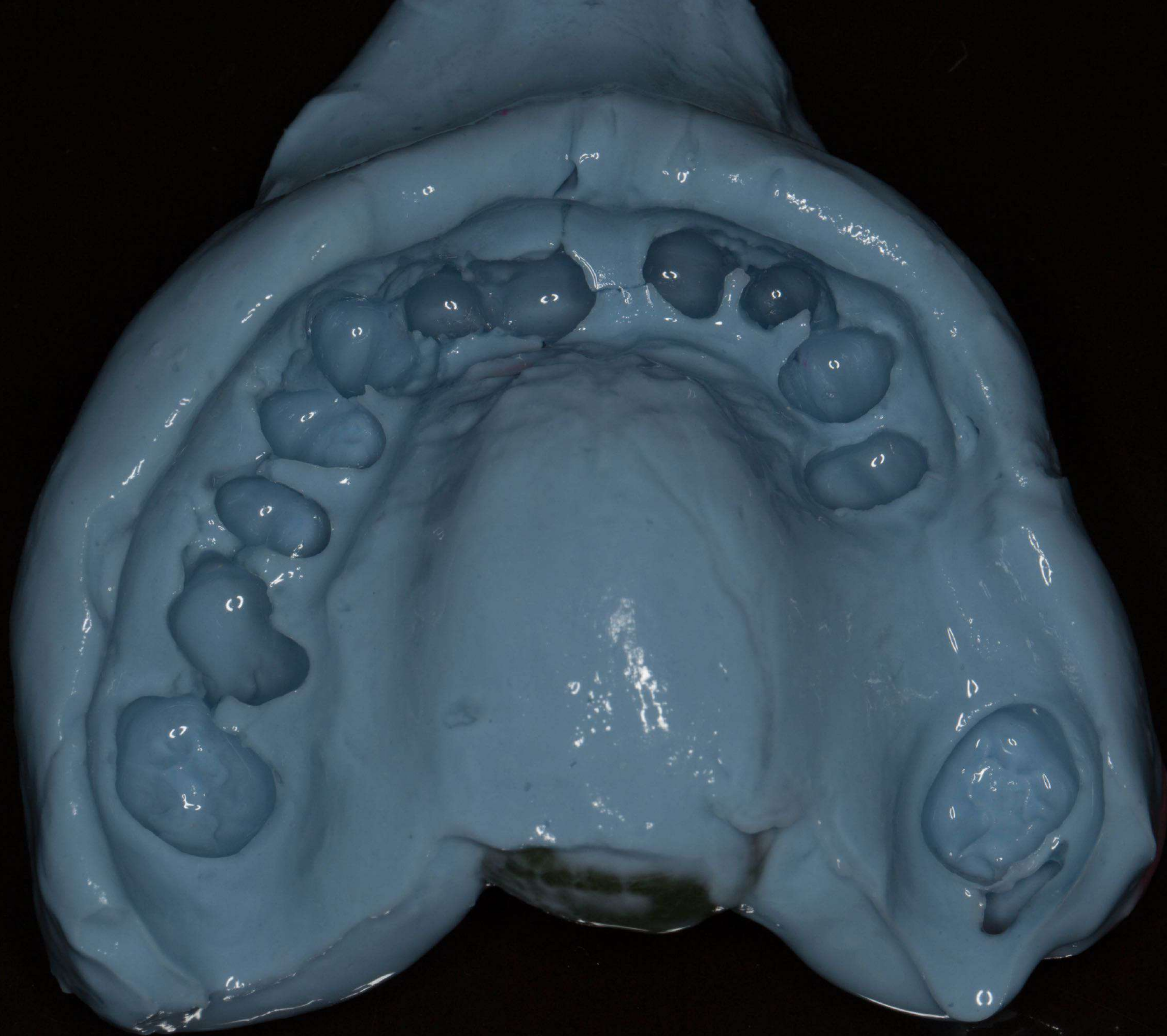




Visit 2

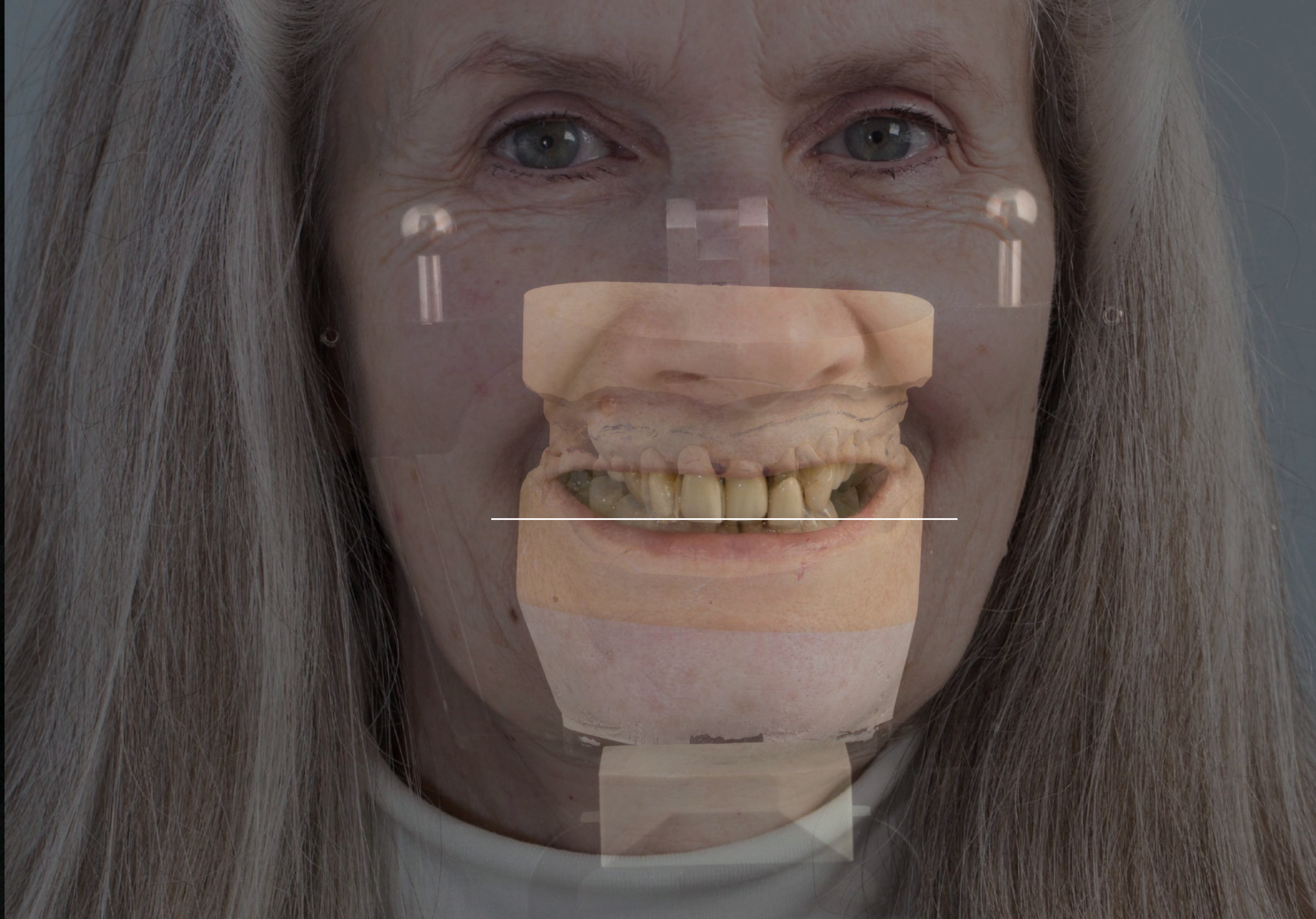


Visit 2

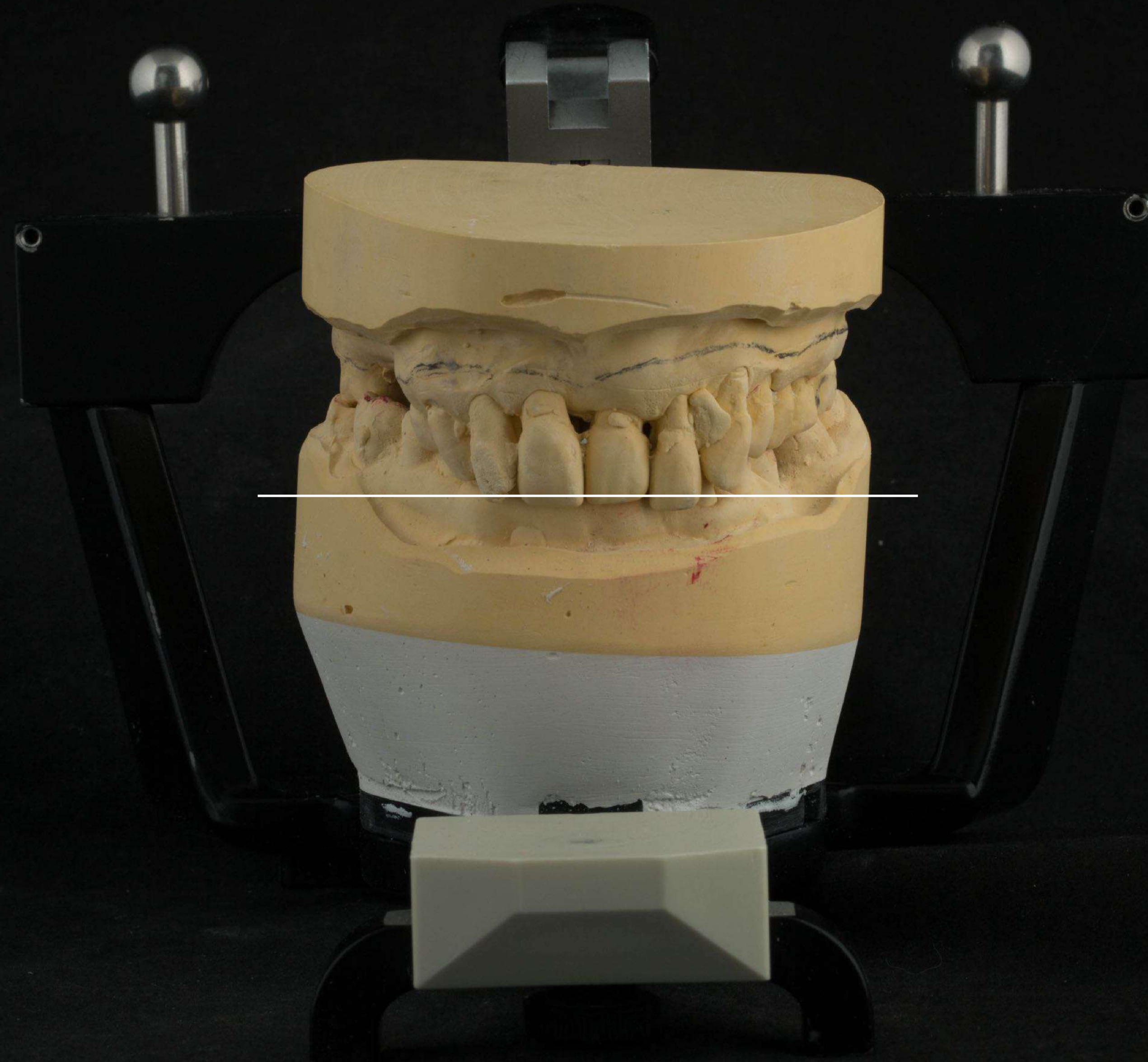



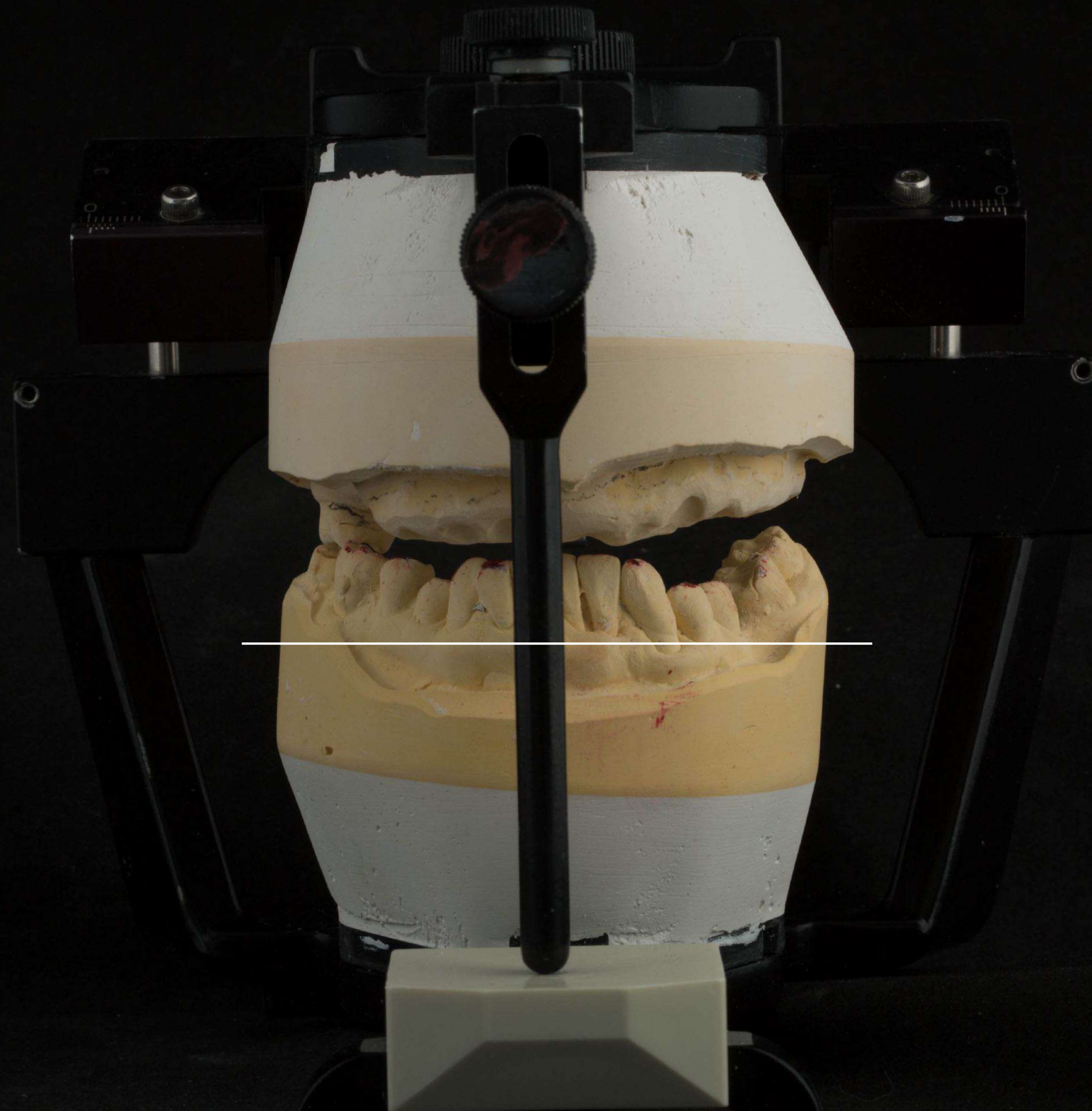




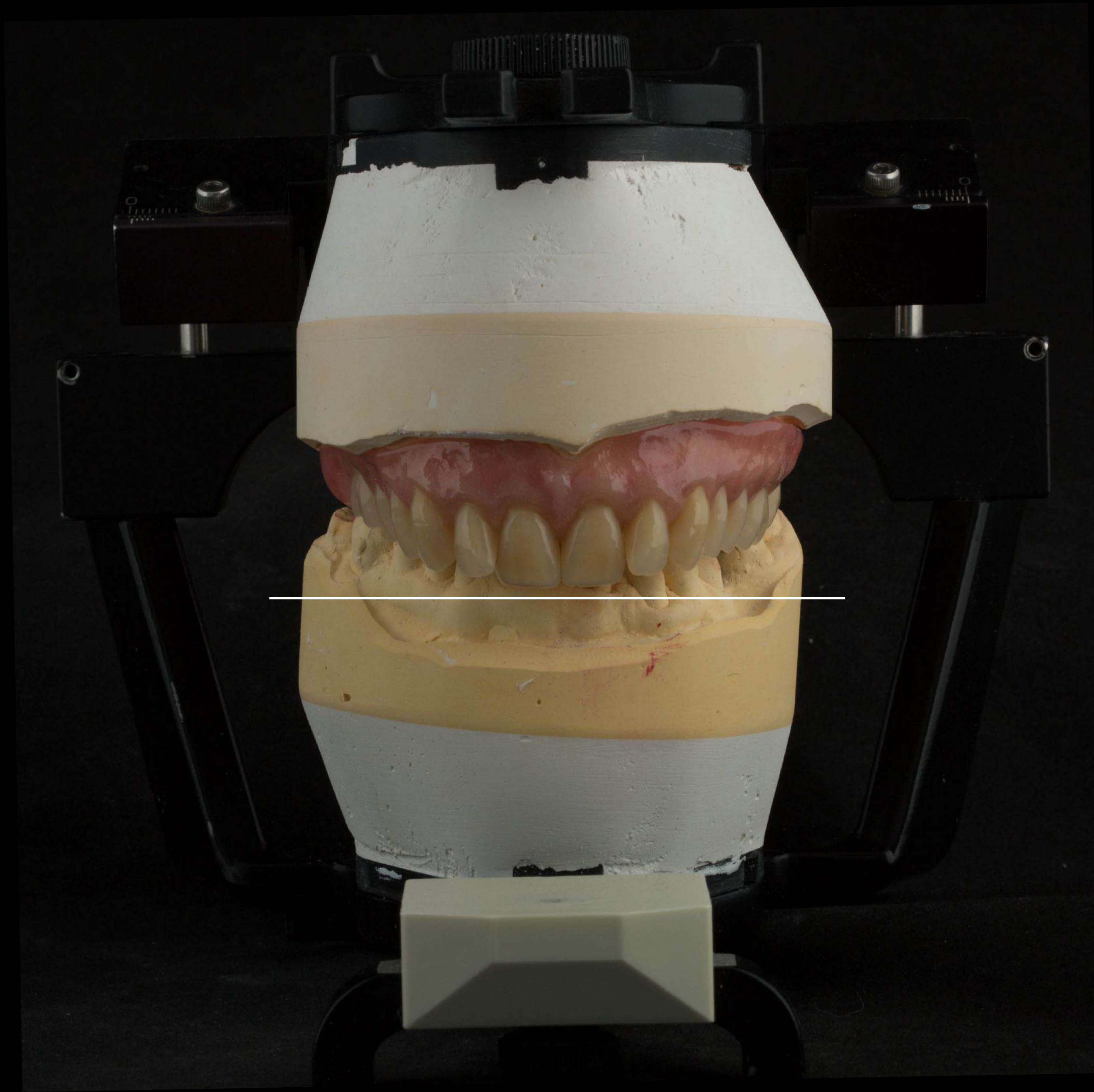Visit 3



Visit 3

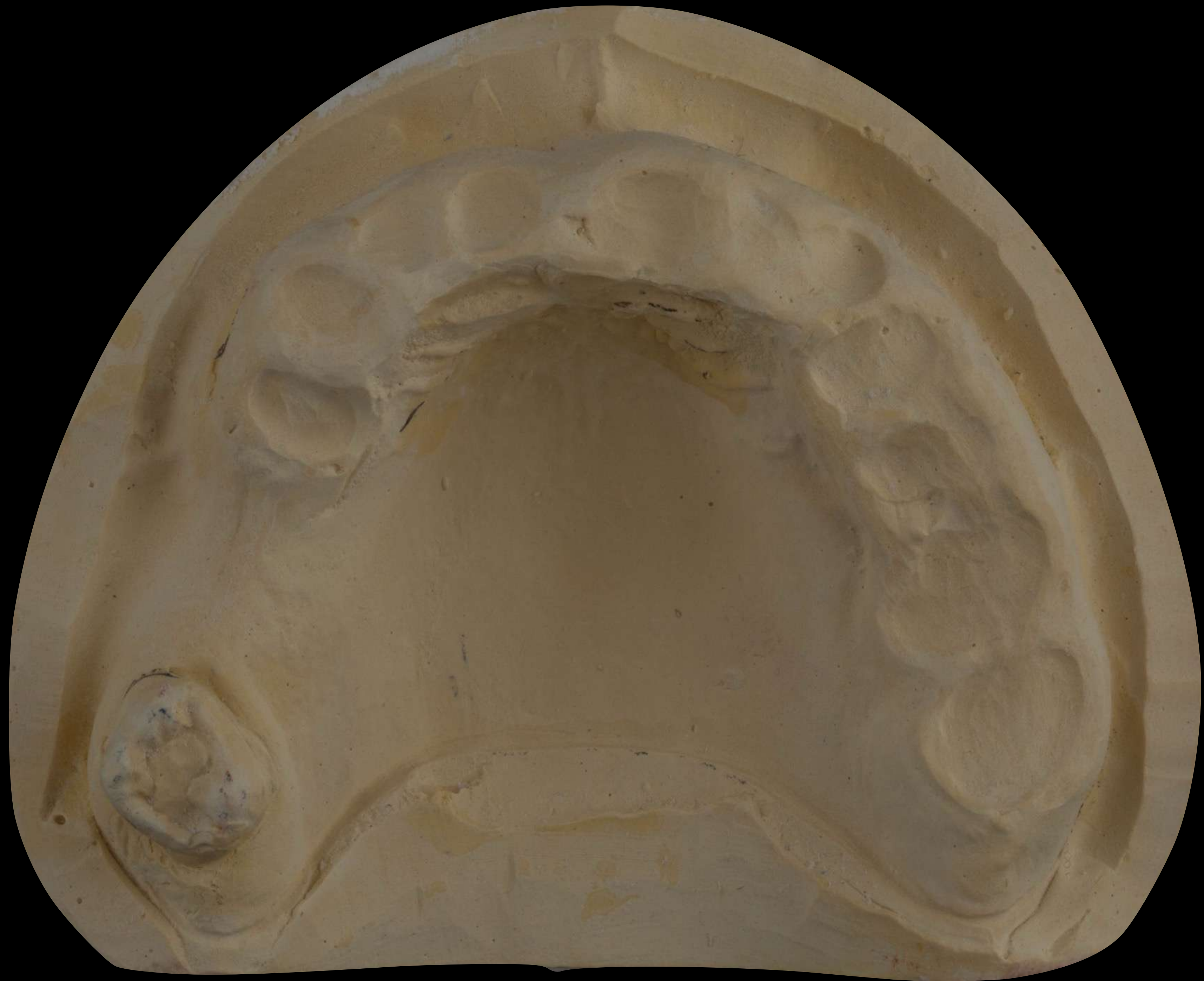

Visit 3

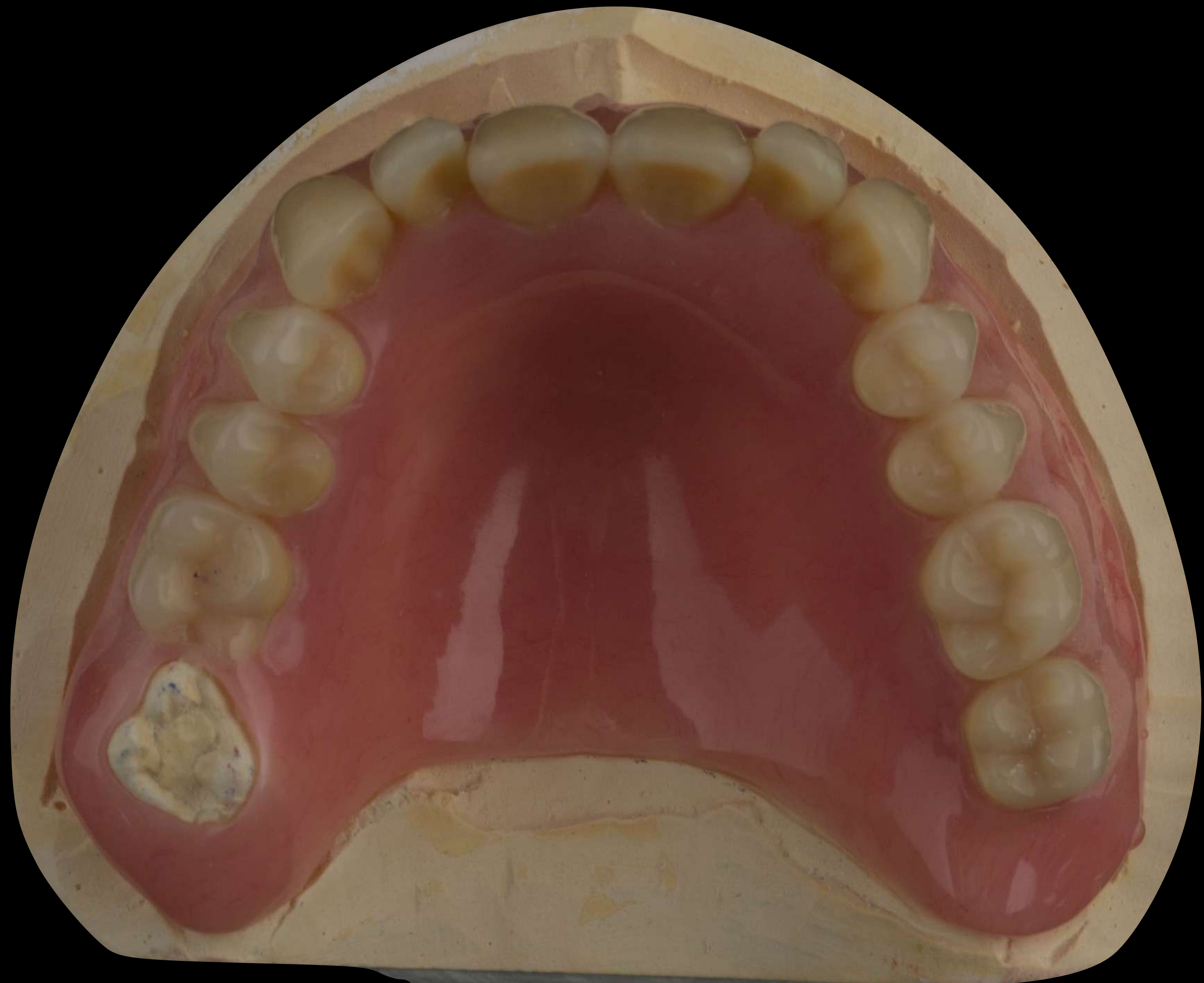




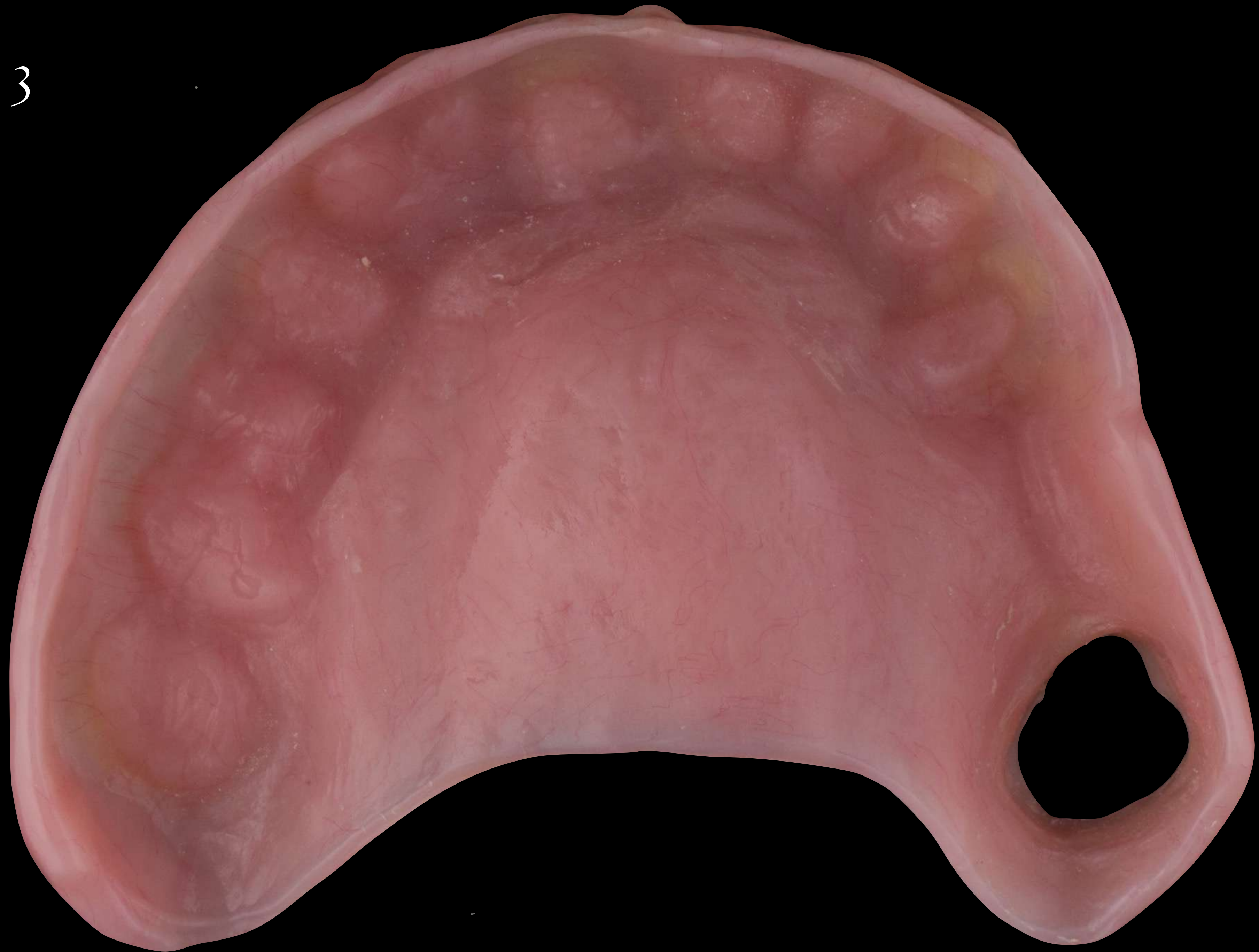Visit 3

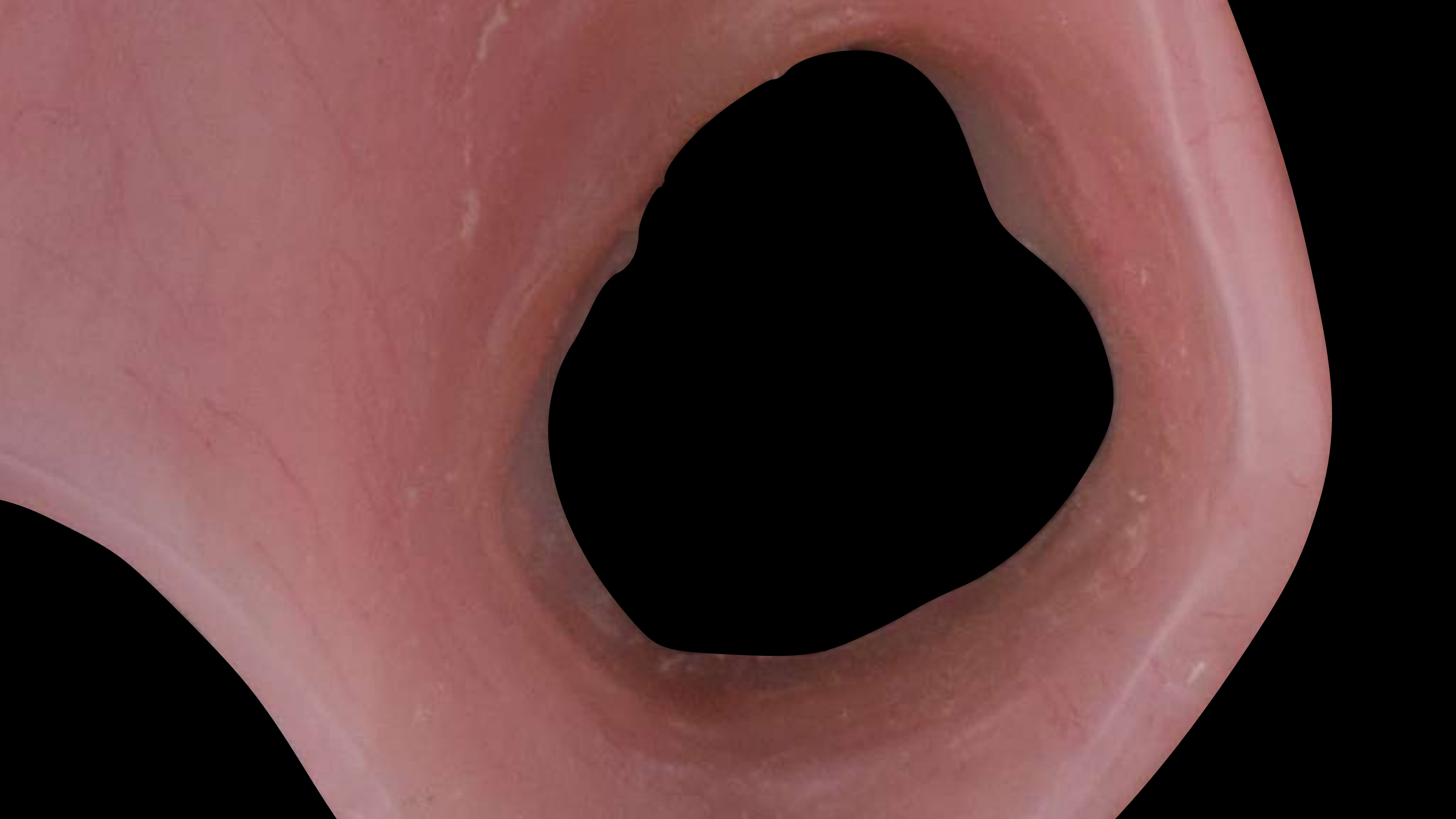

Visit 3

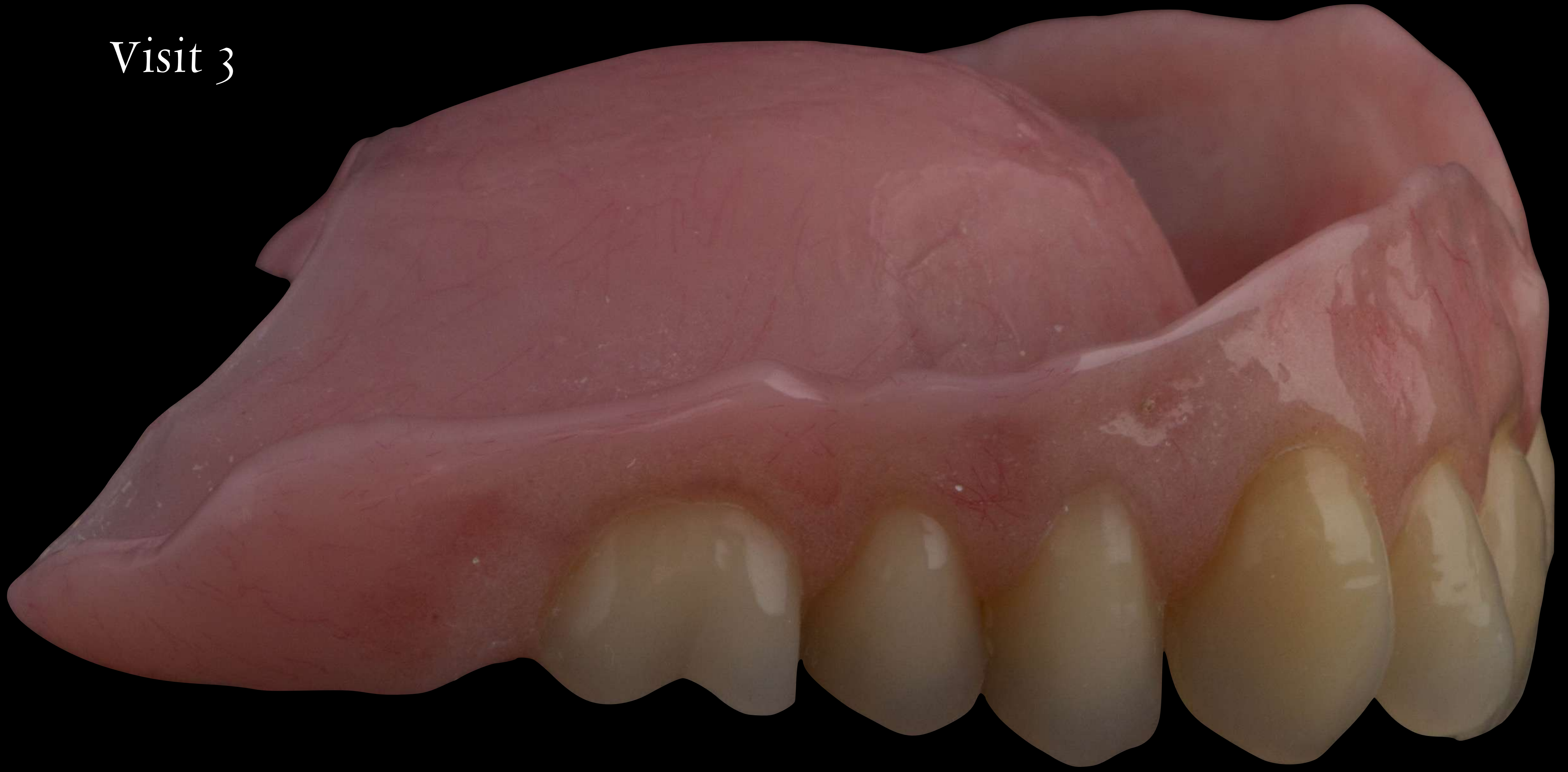

Visit 3





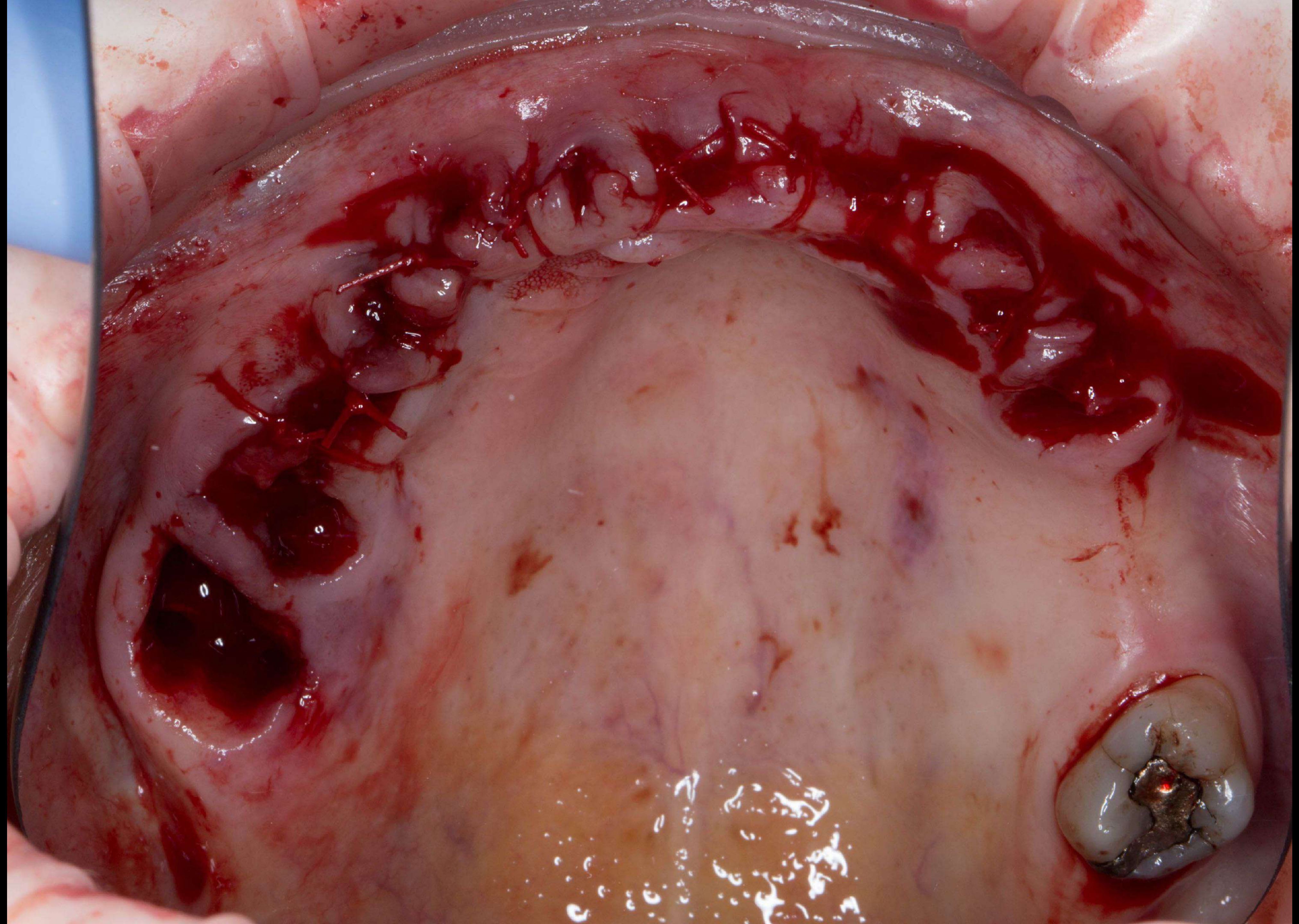
Visit 3

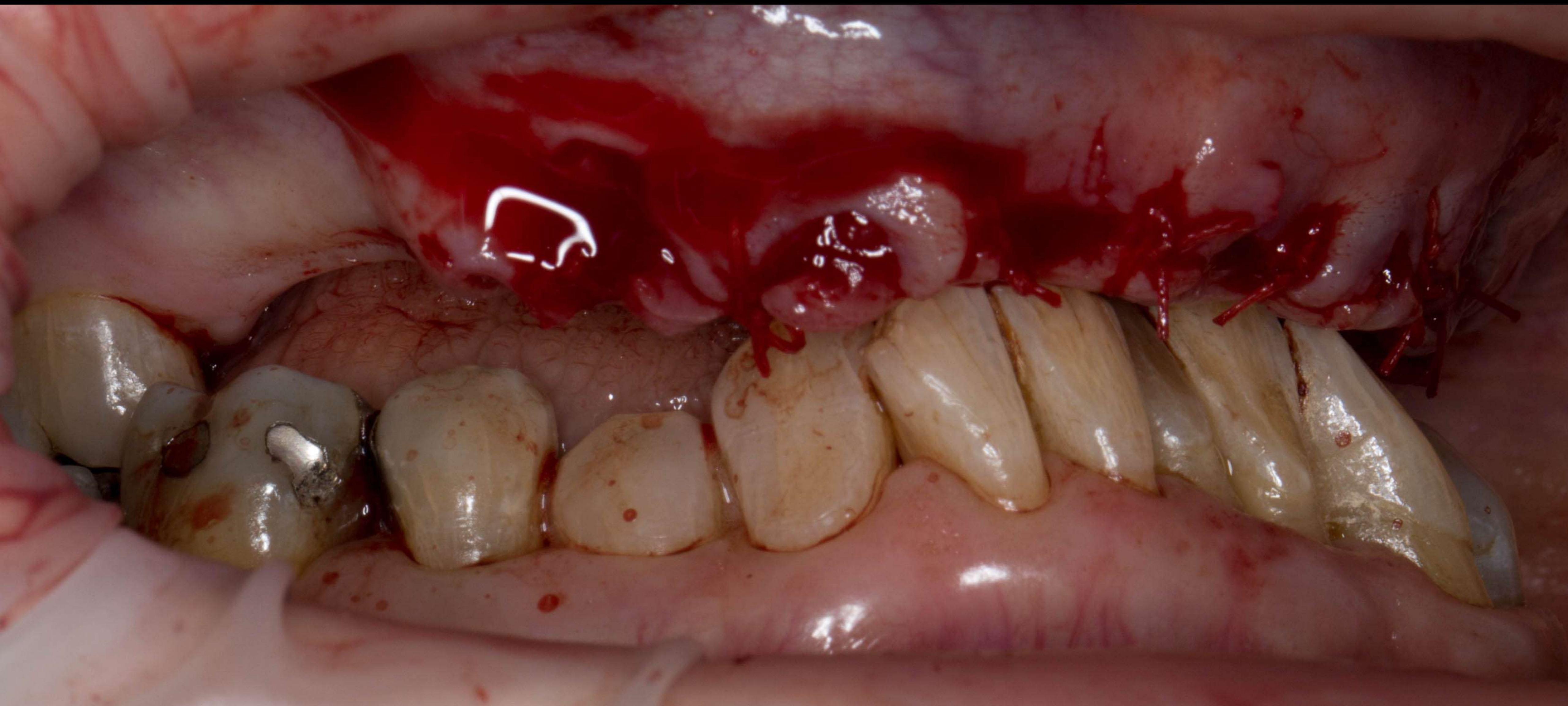


Visit 3



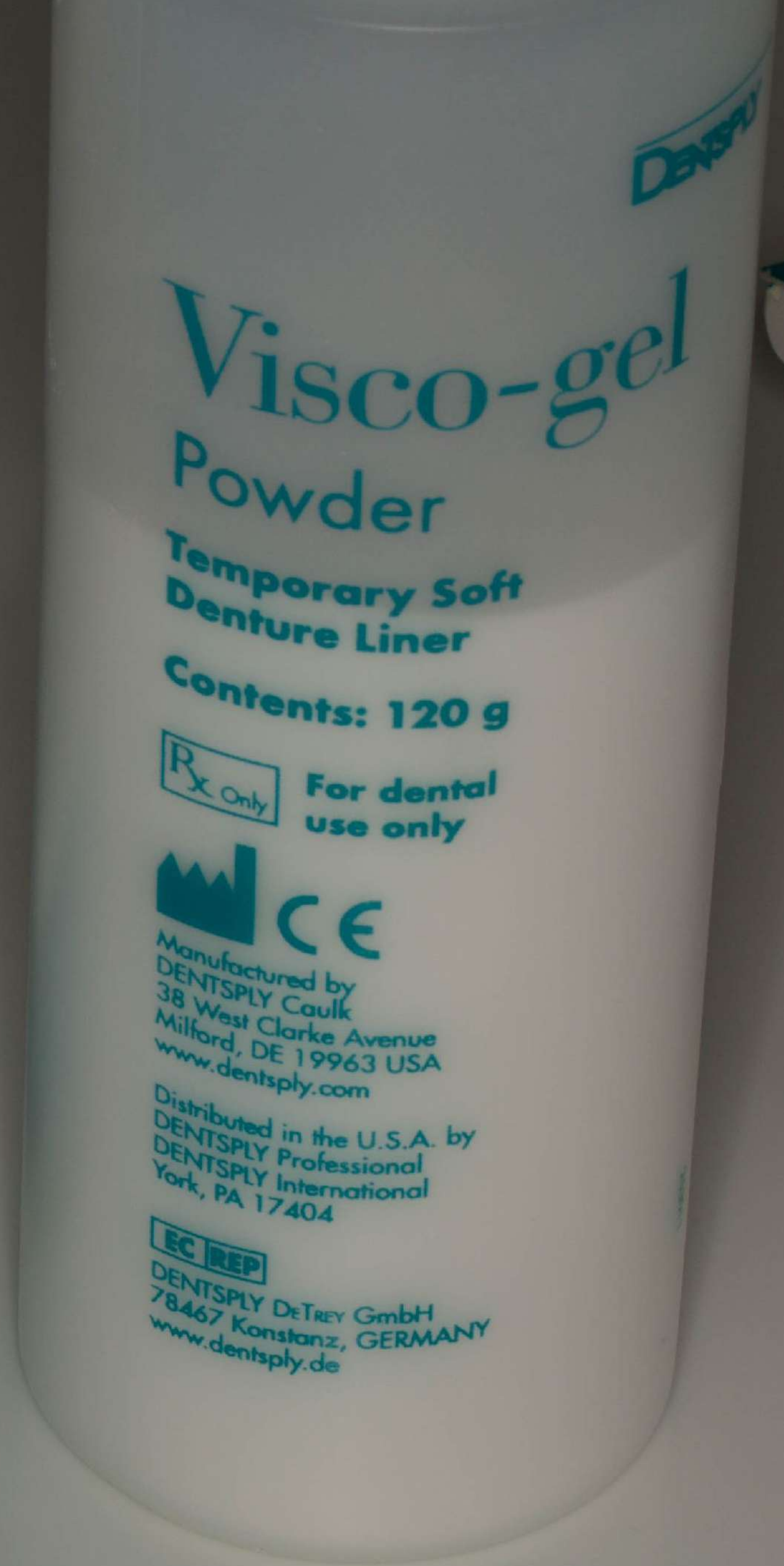
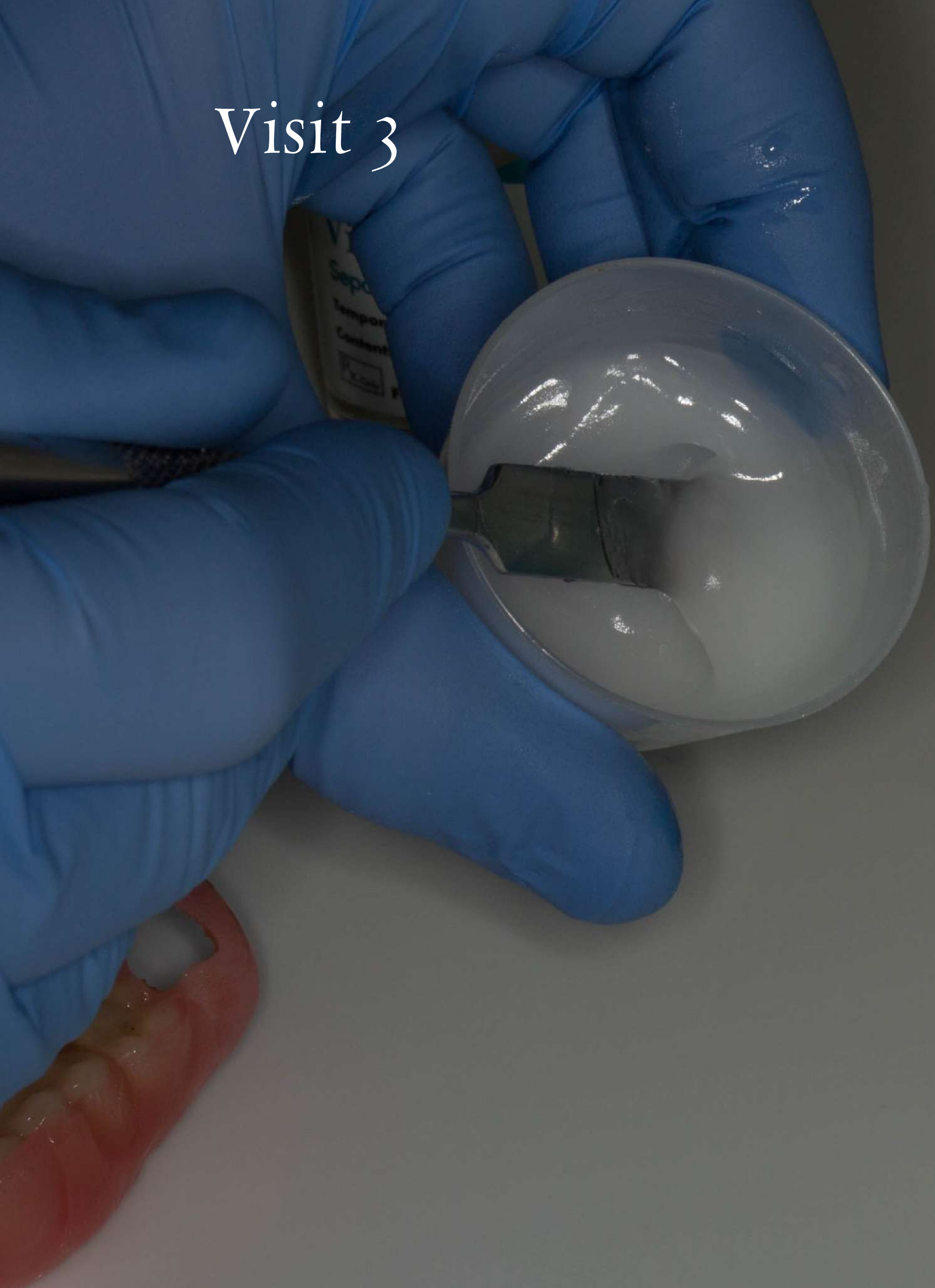Visit 3



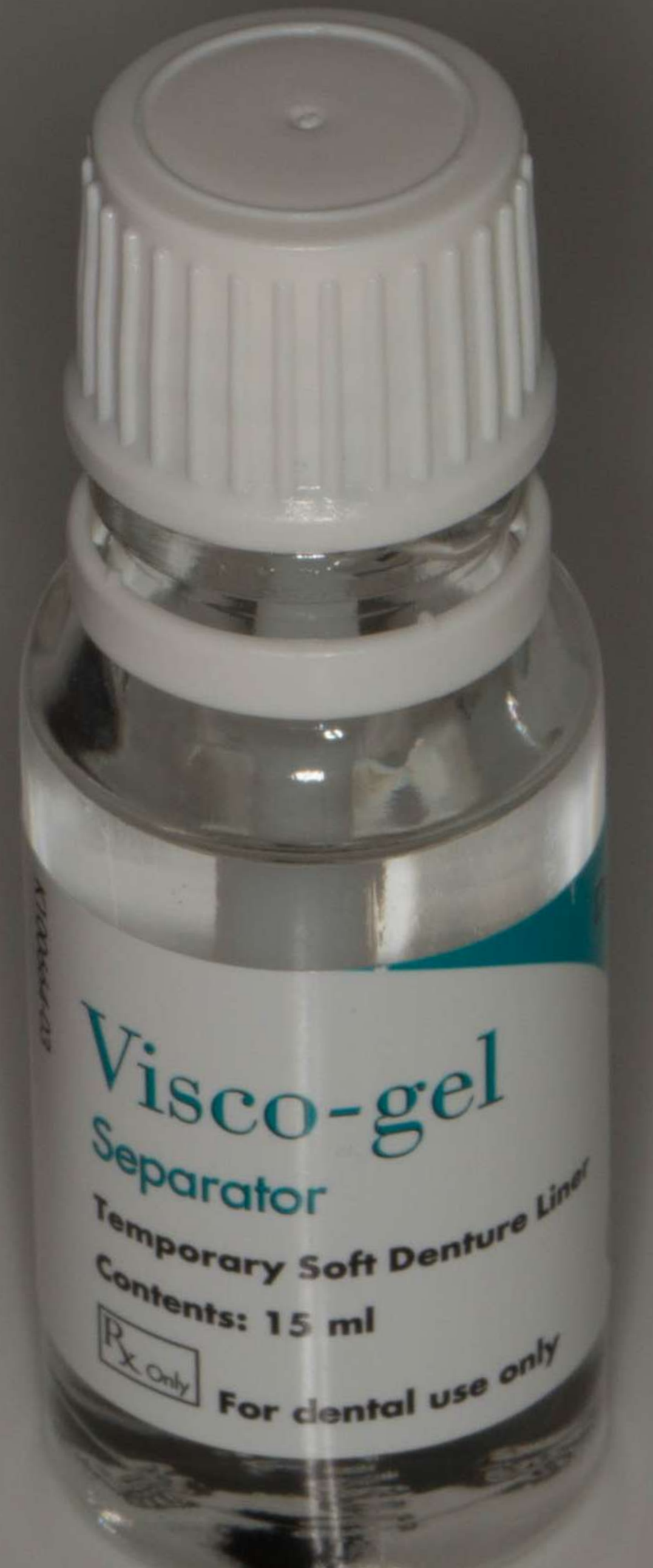
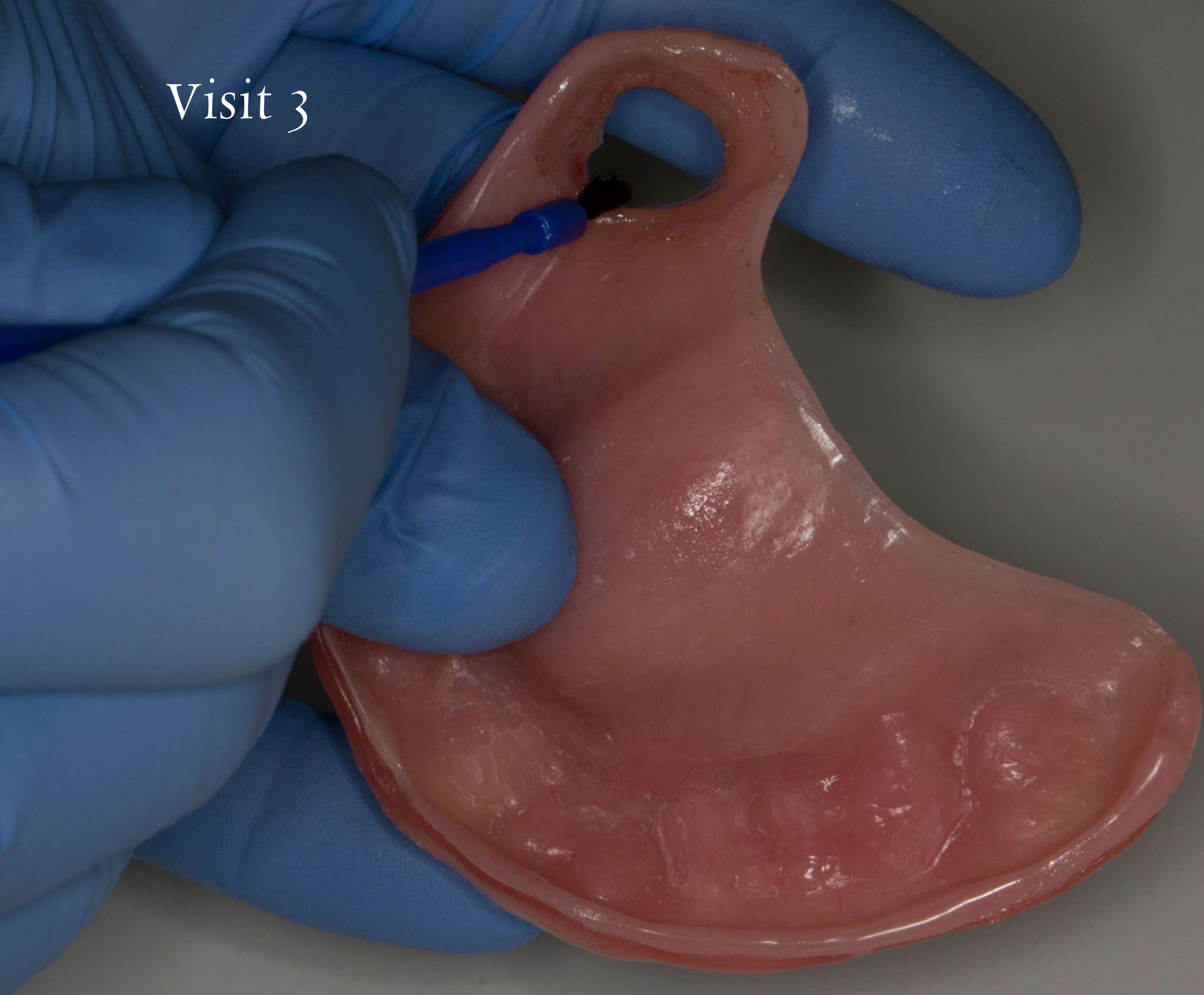


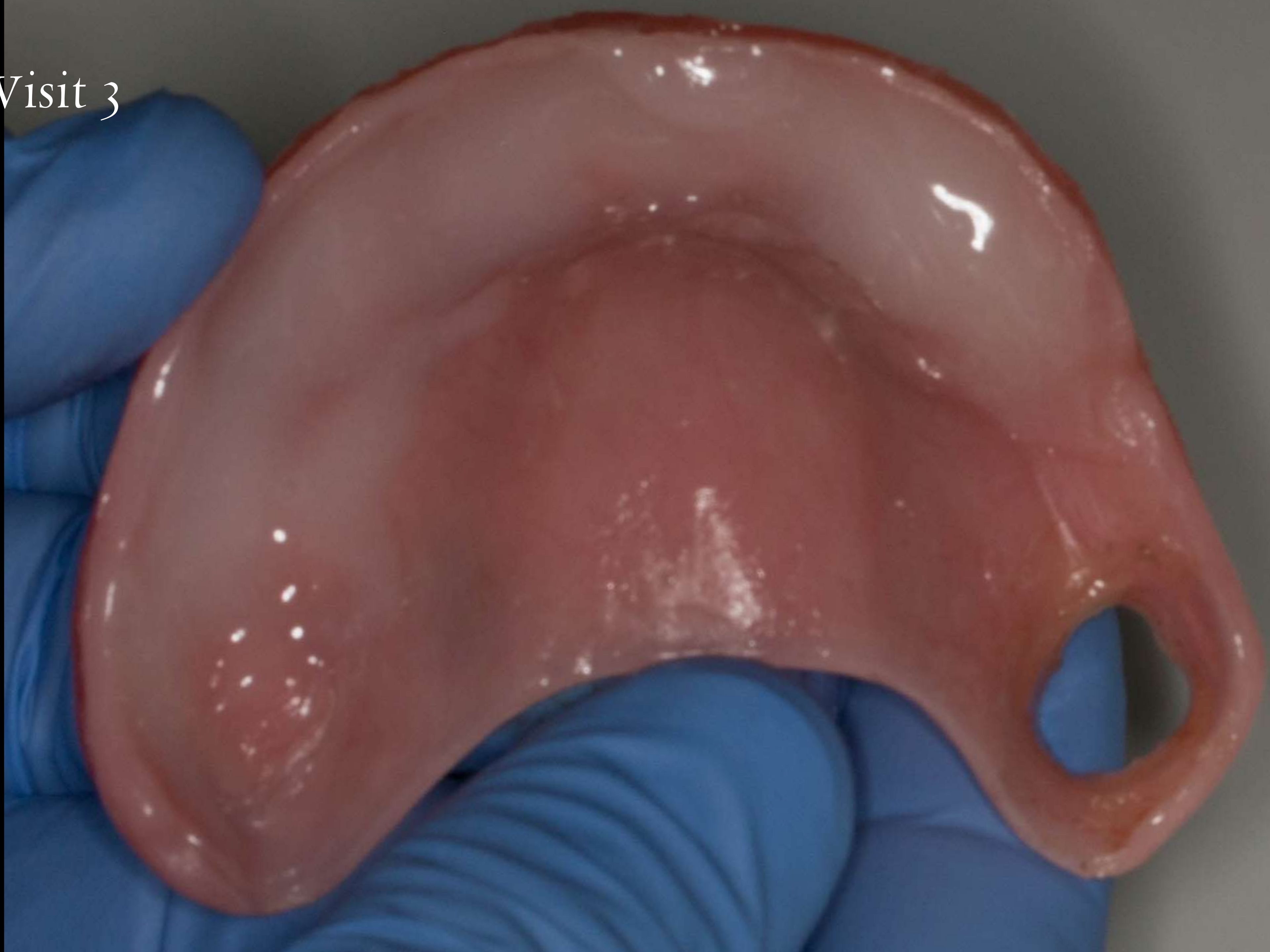
Visit 3



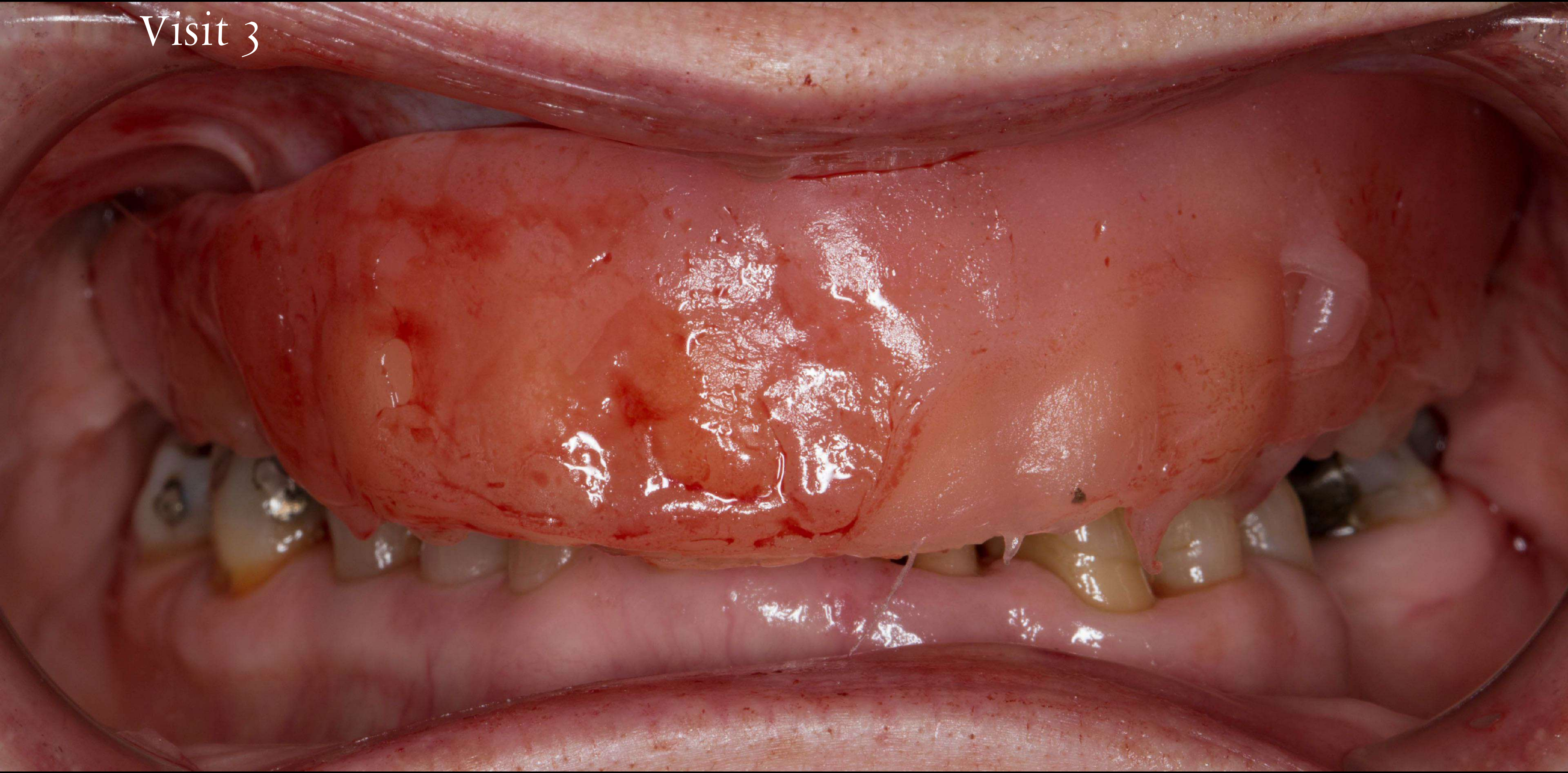Visit 3



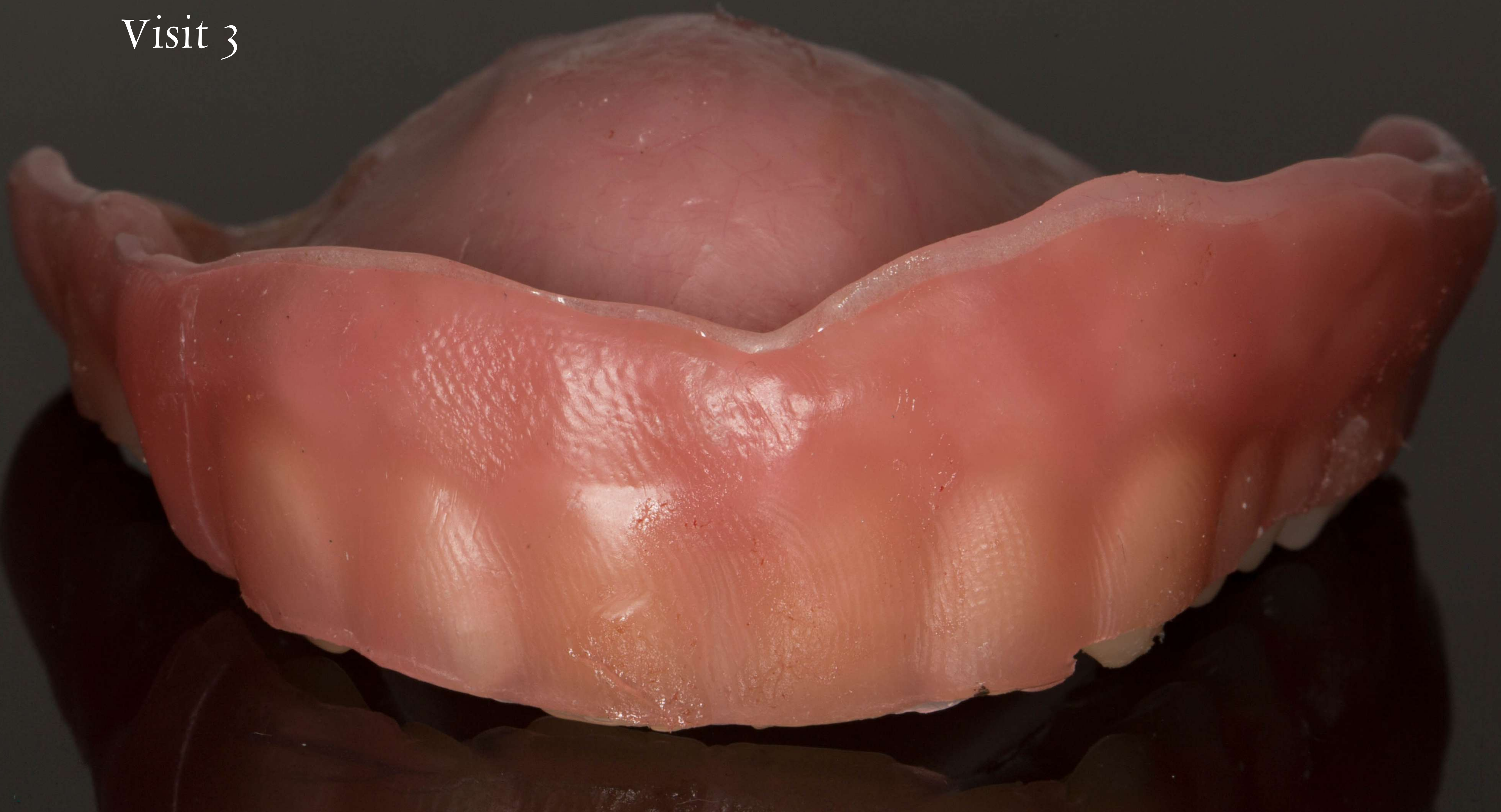Visit 3



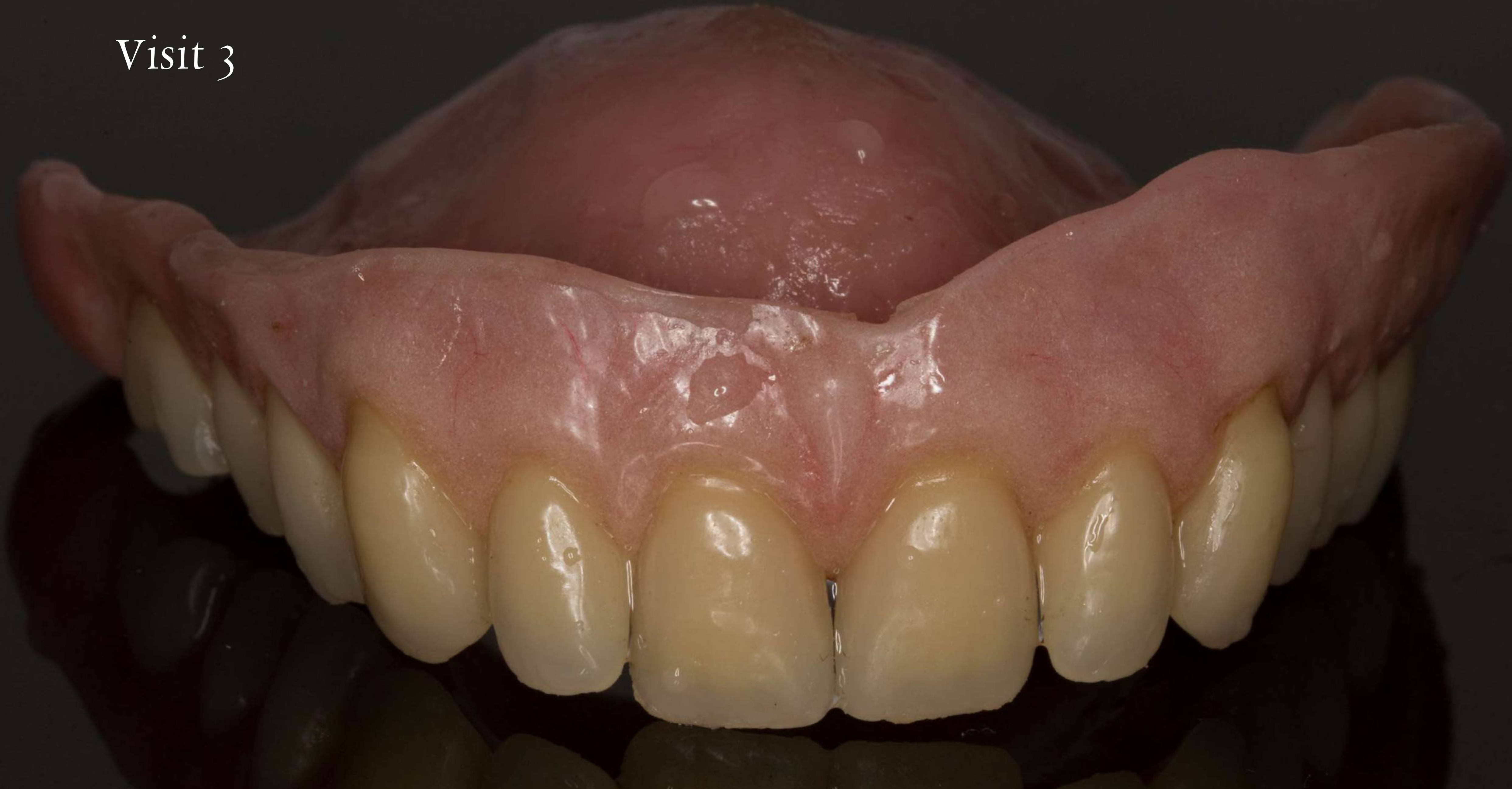Visit 3



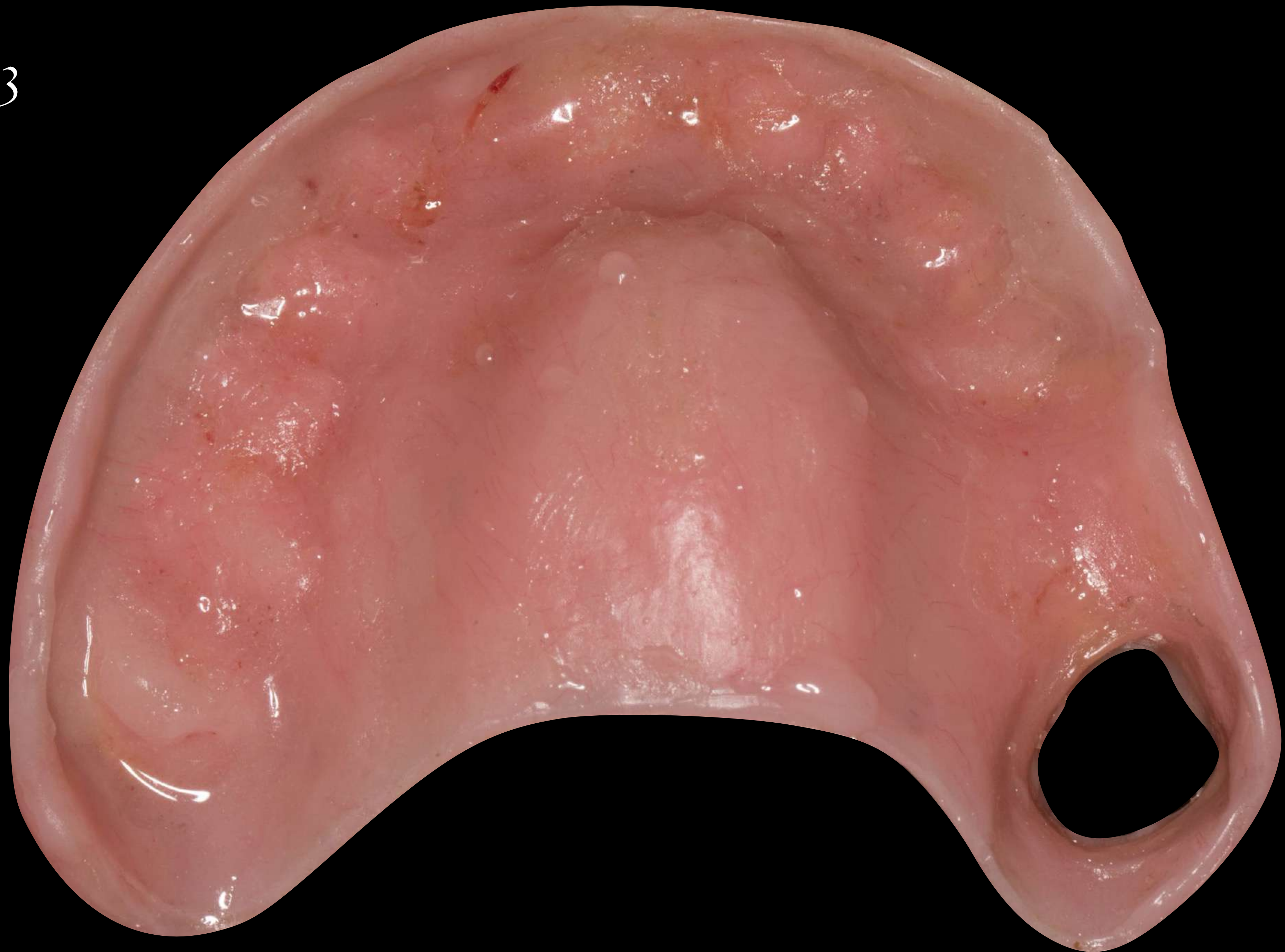Visit 3

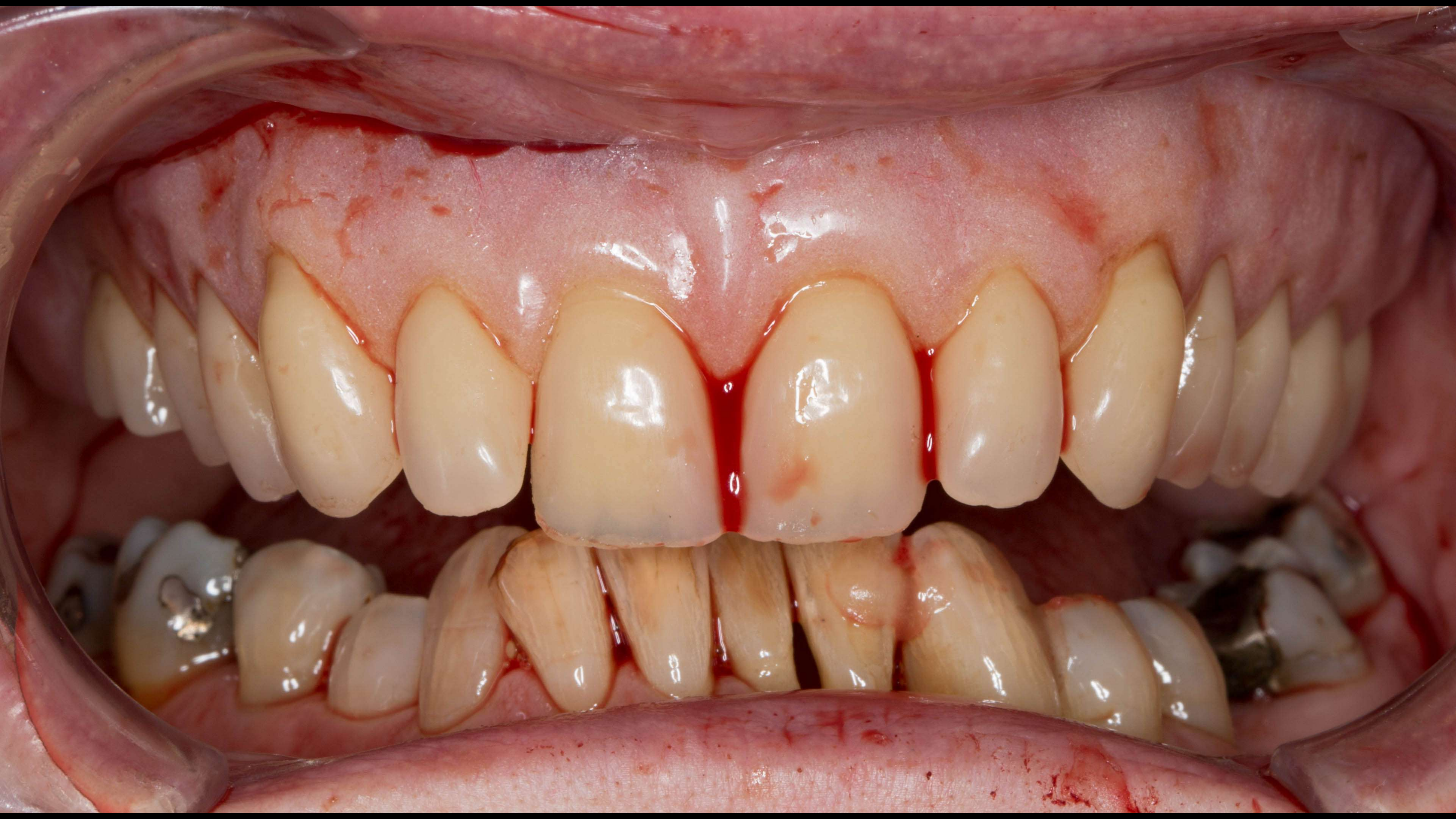

Visit 3

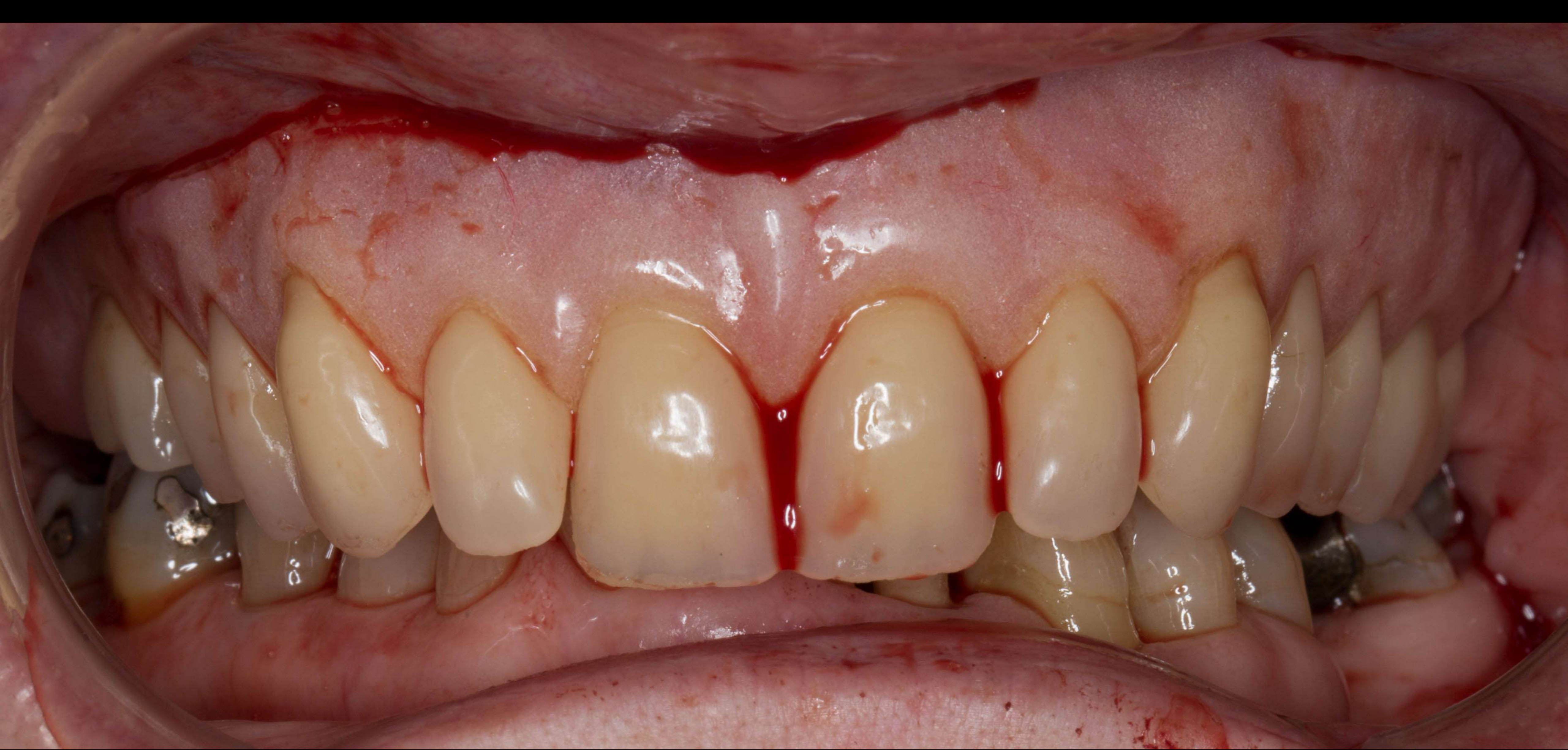

Visit 3

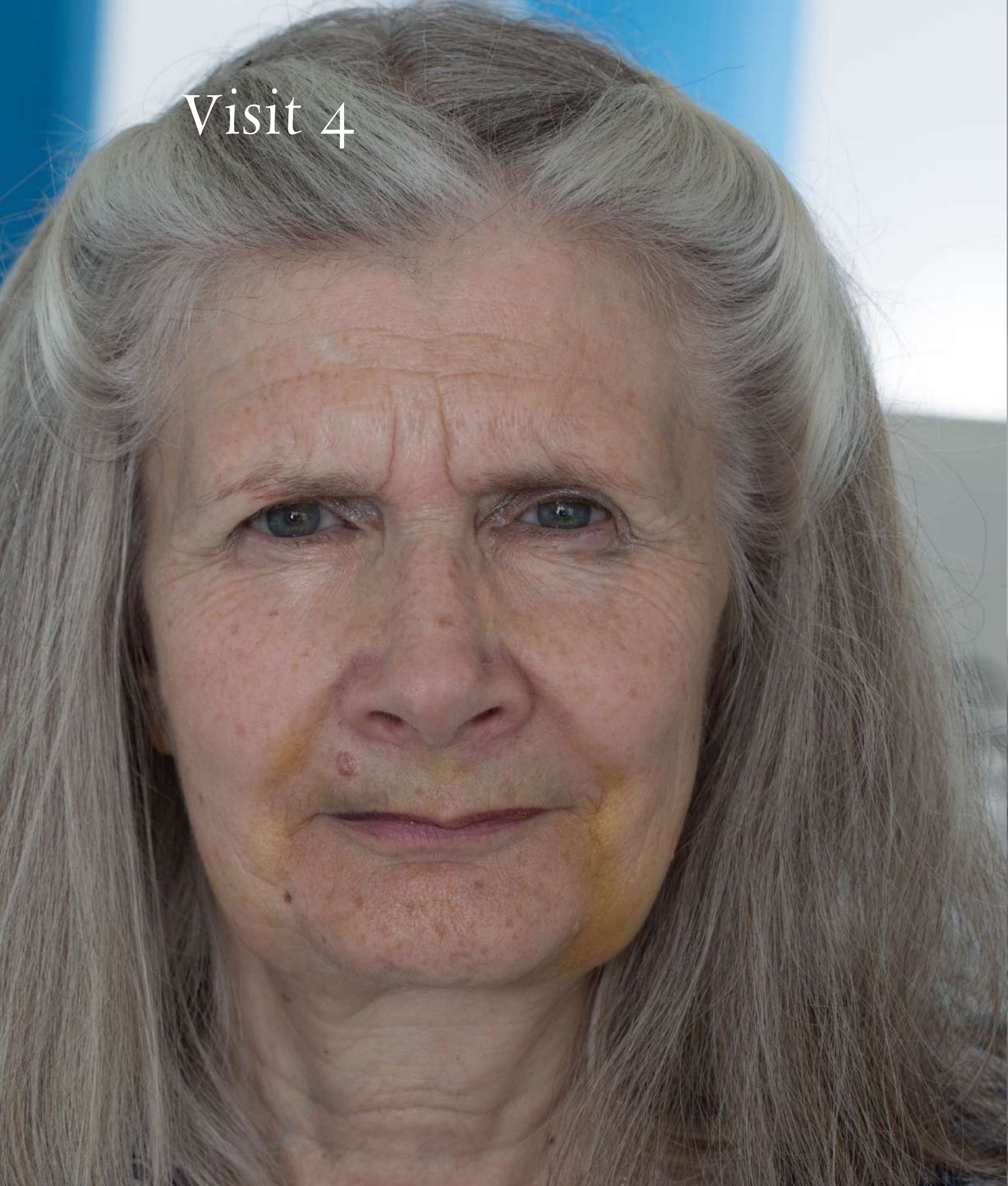




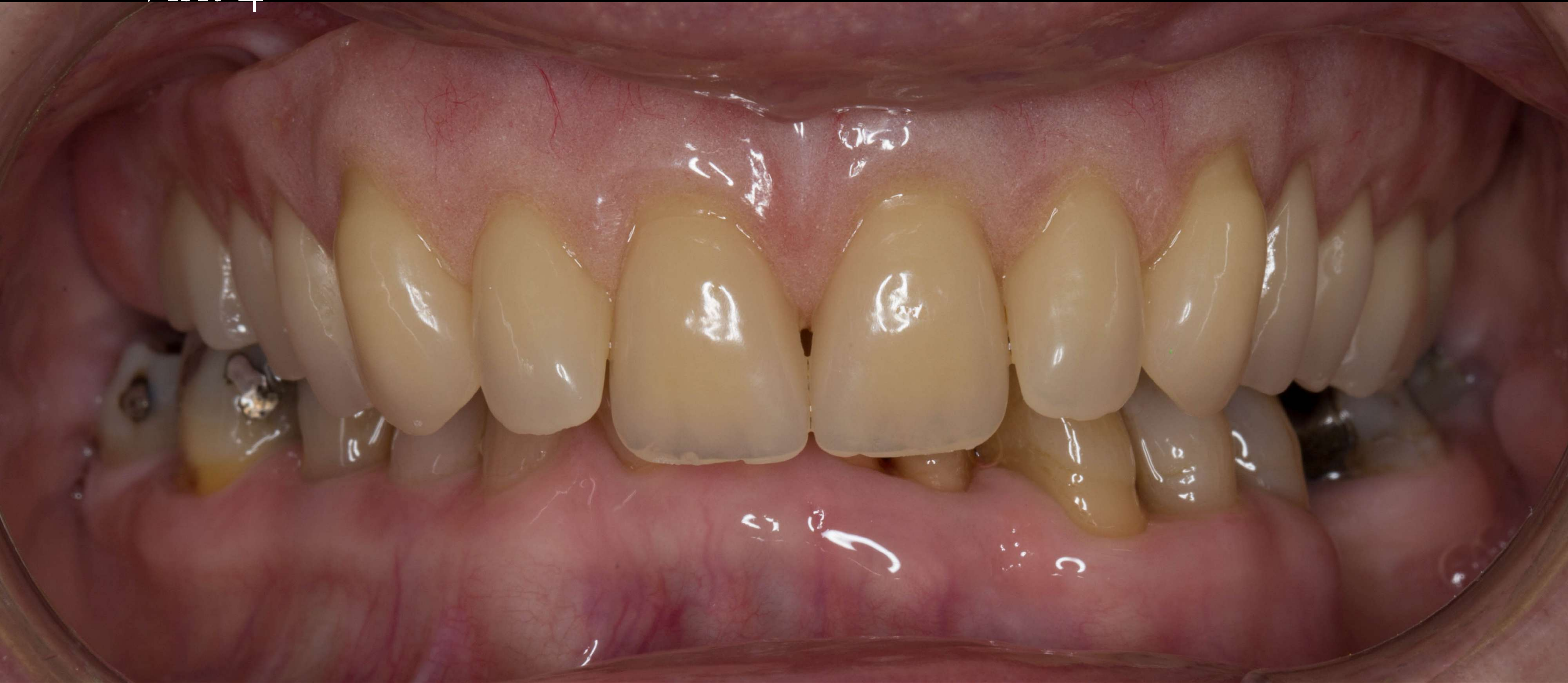


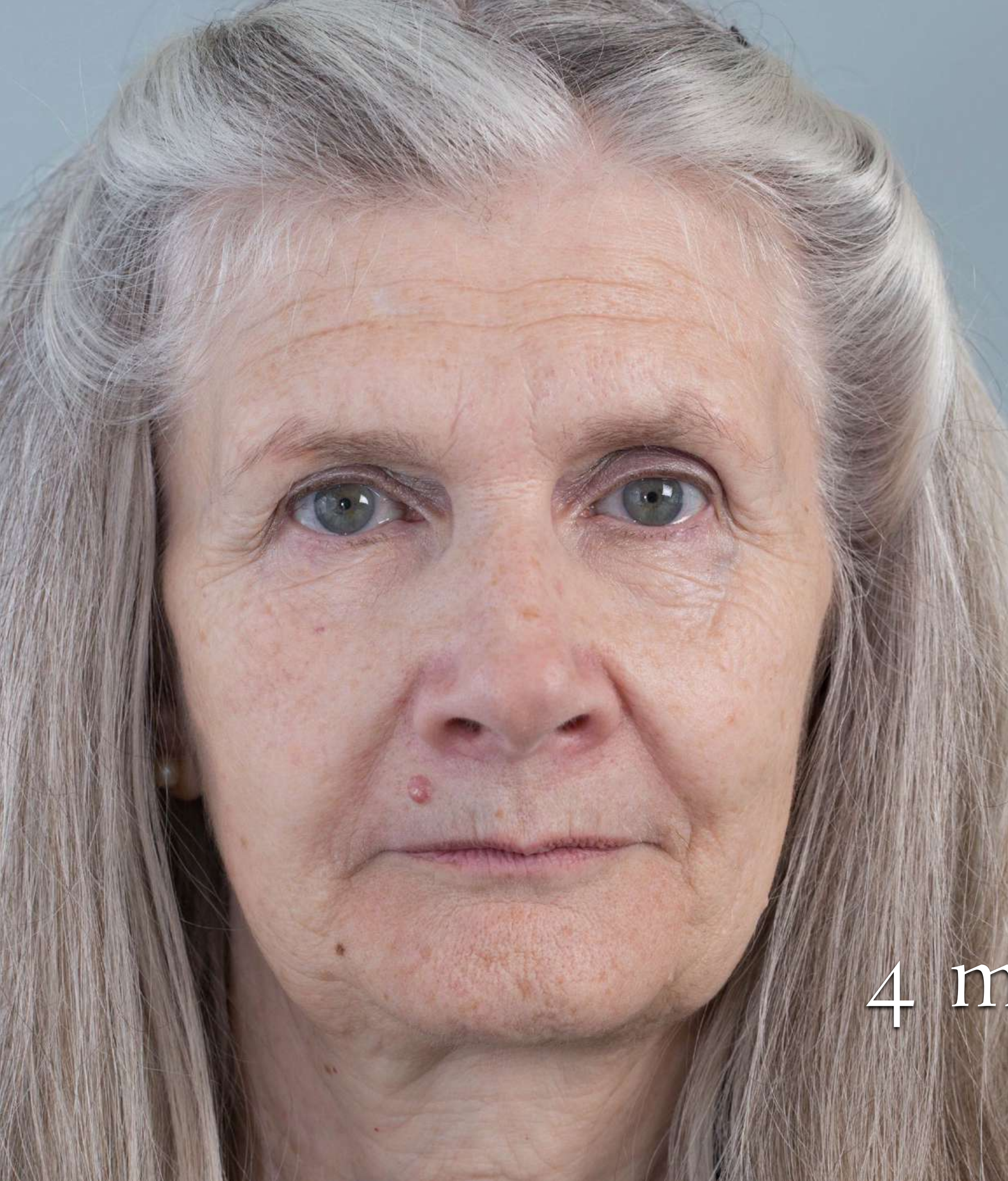Visit 4

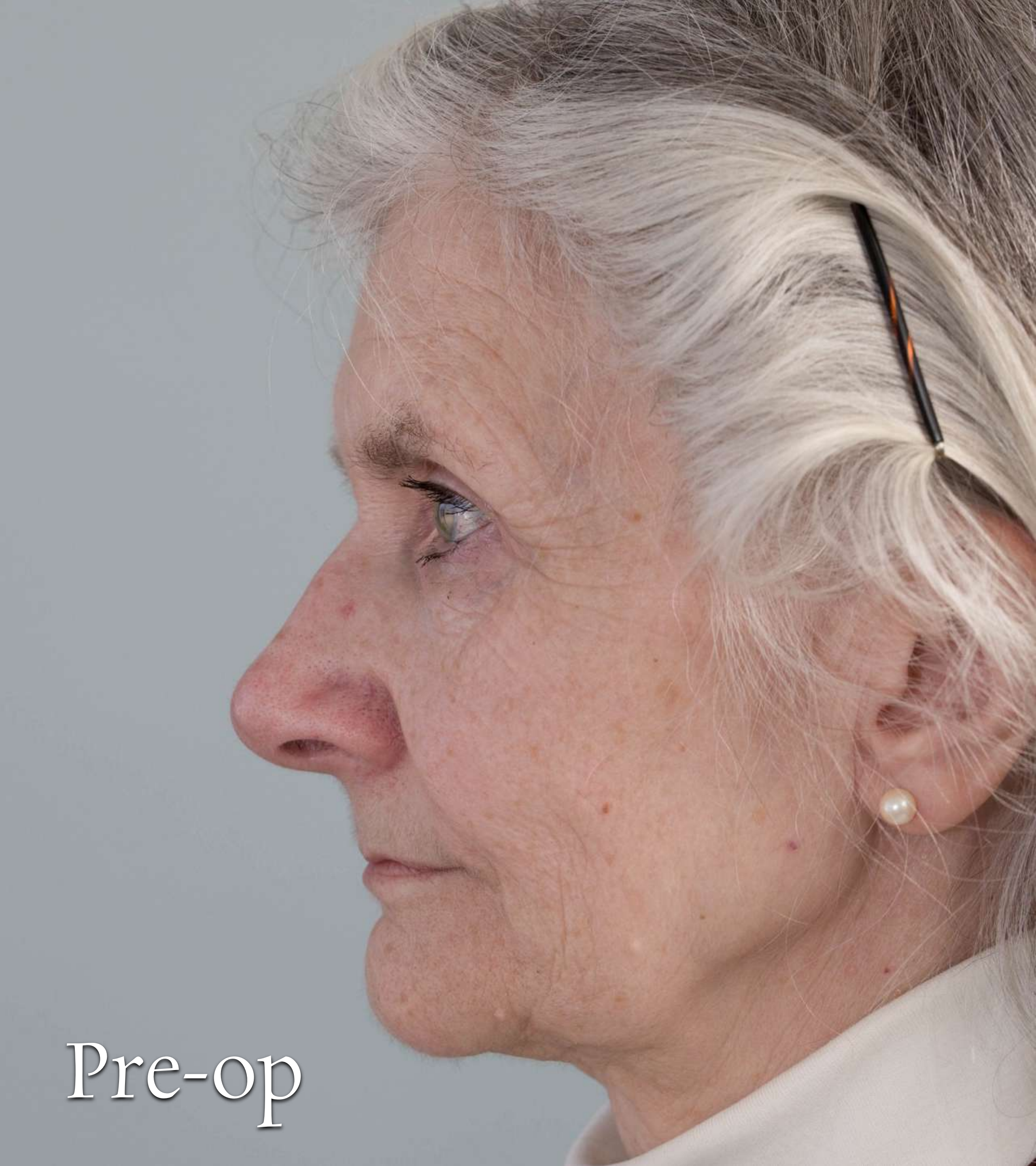

Visit 4





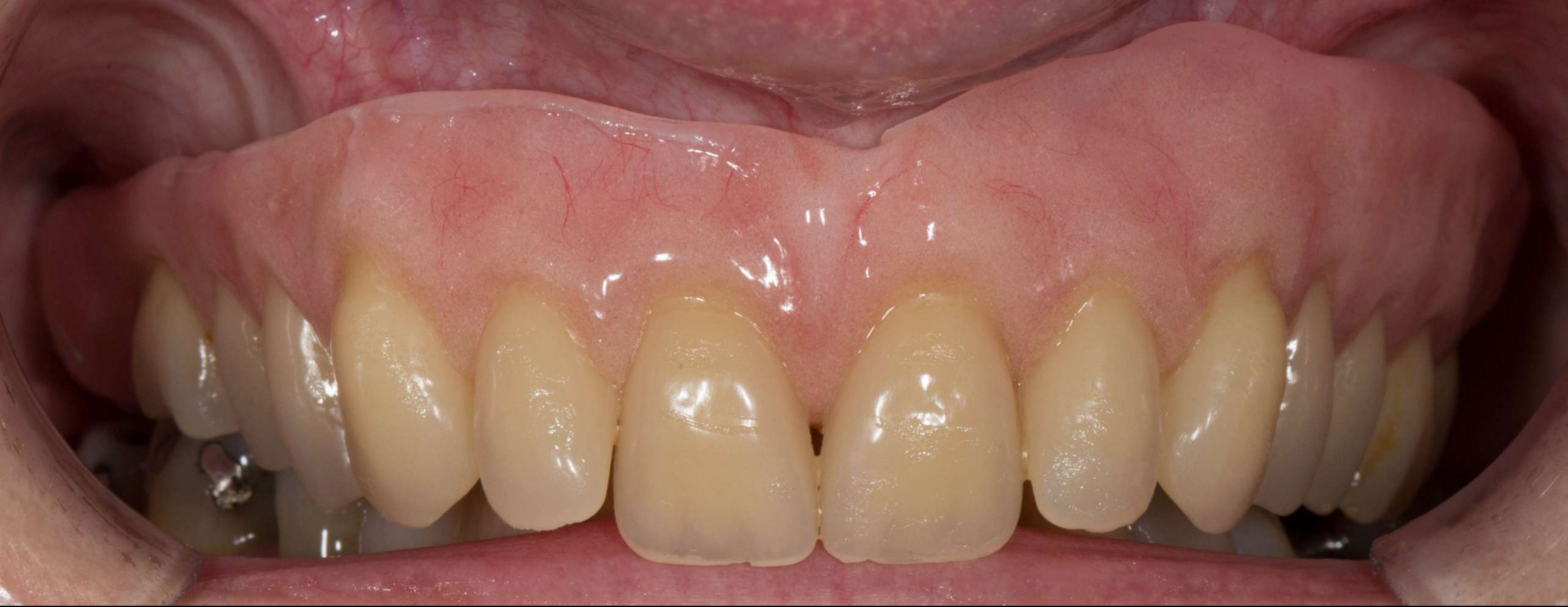
4 months



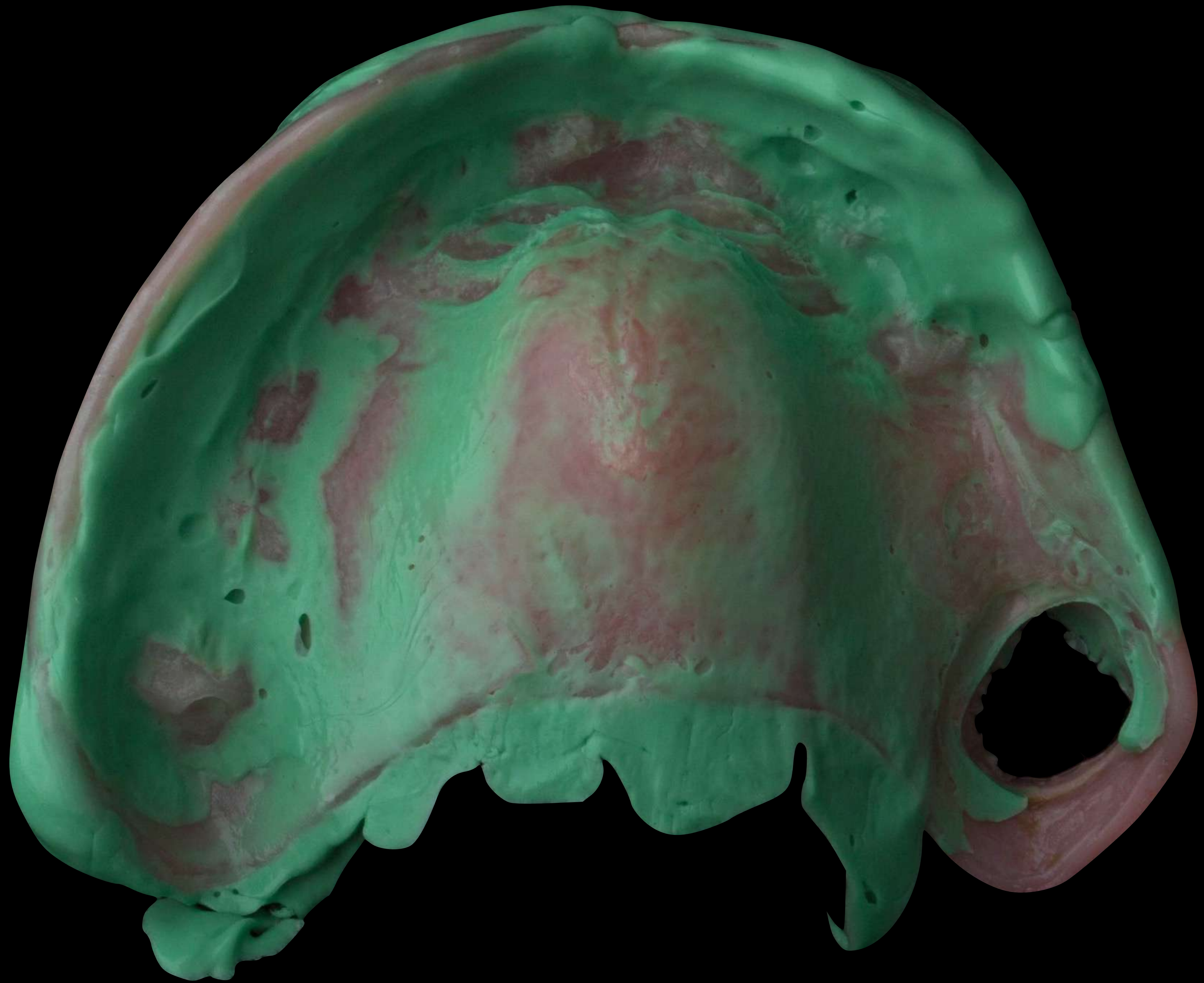
Pre-op

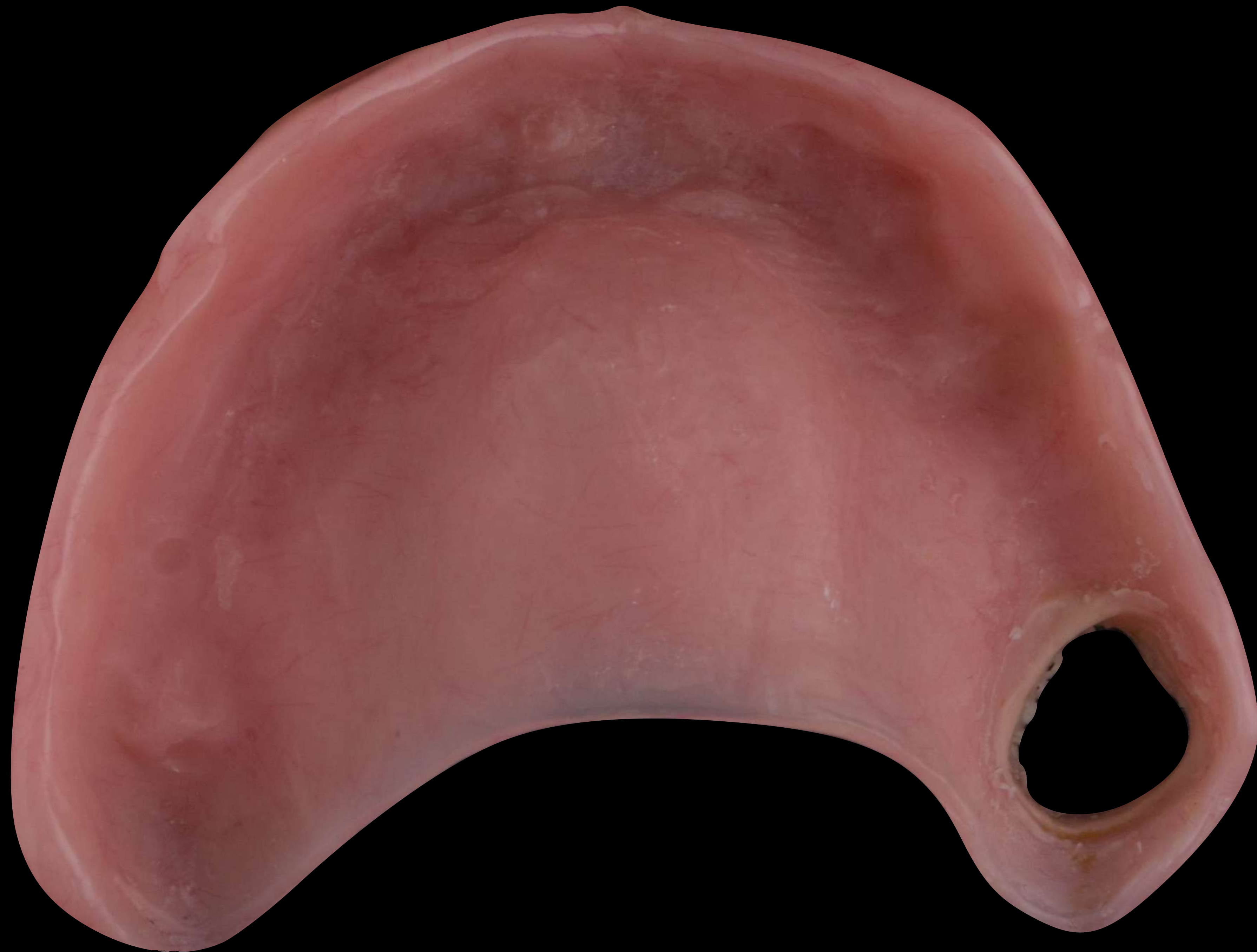

4 months

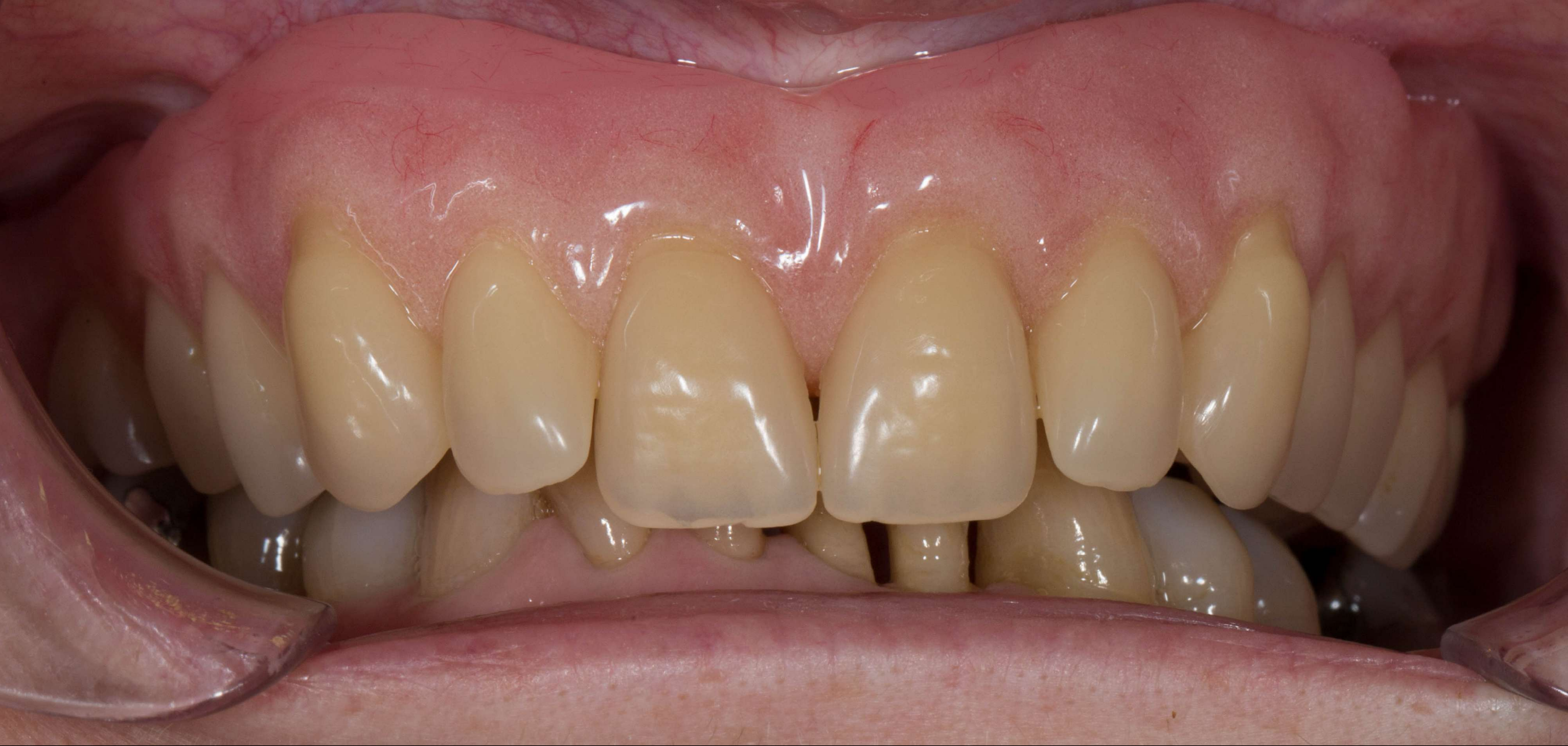

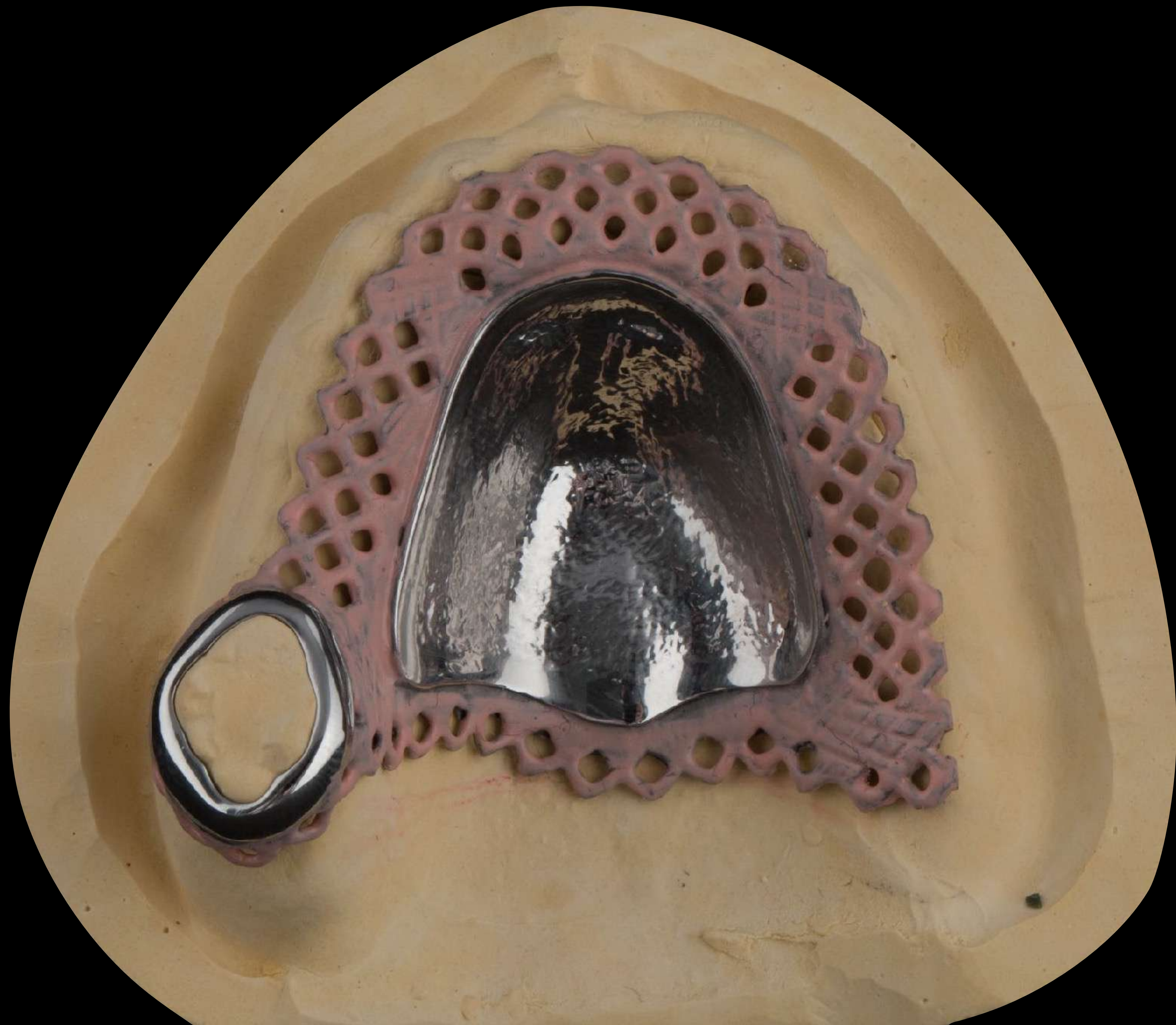4 months lab reline needed

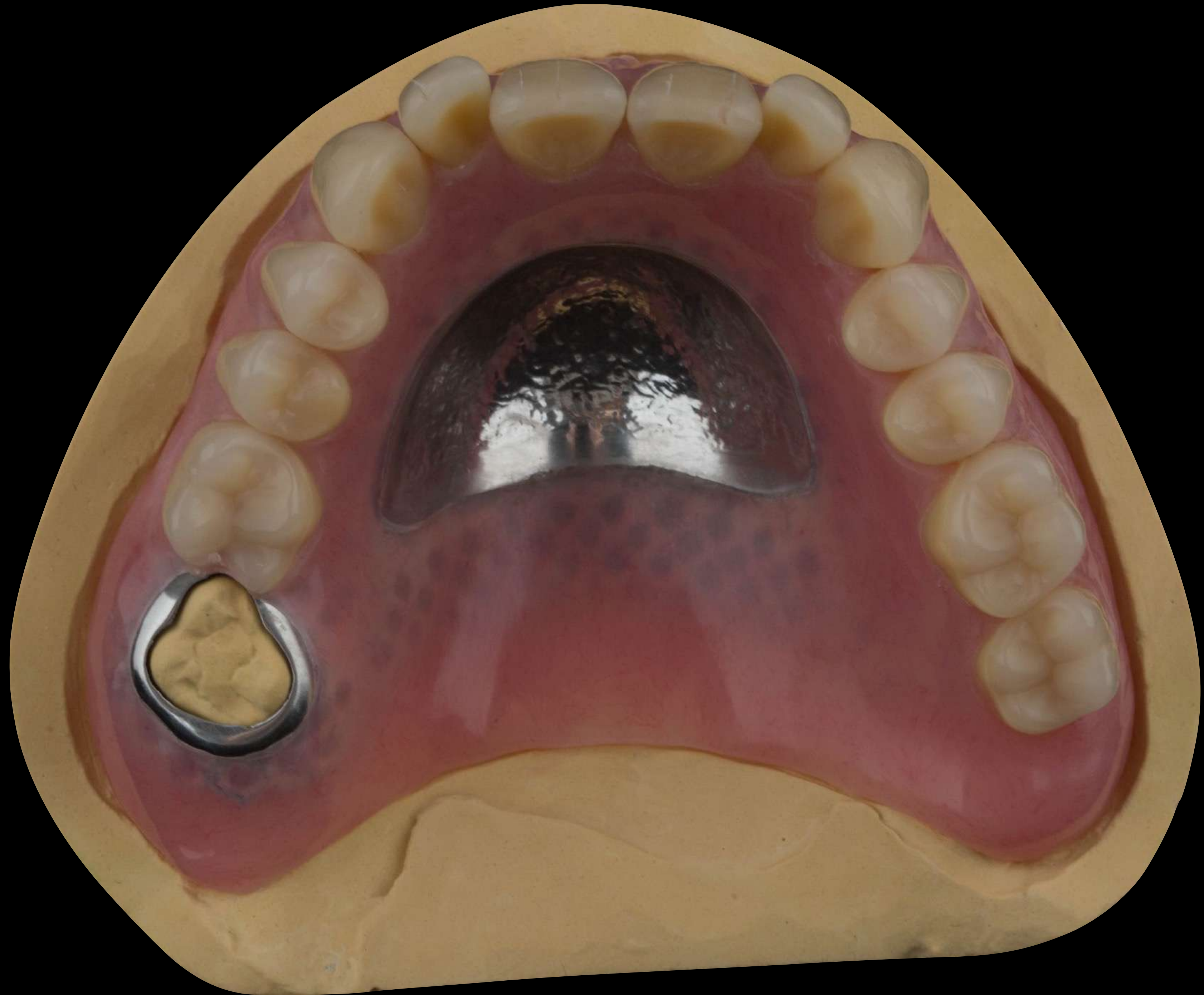


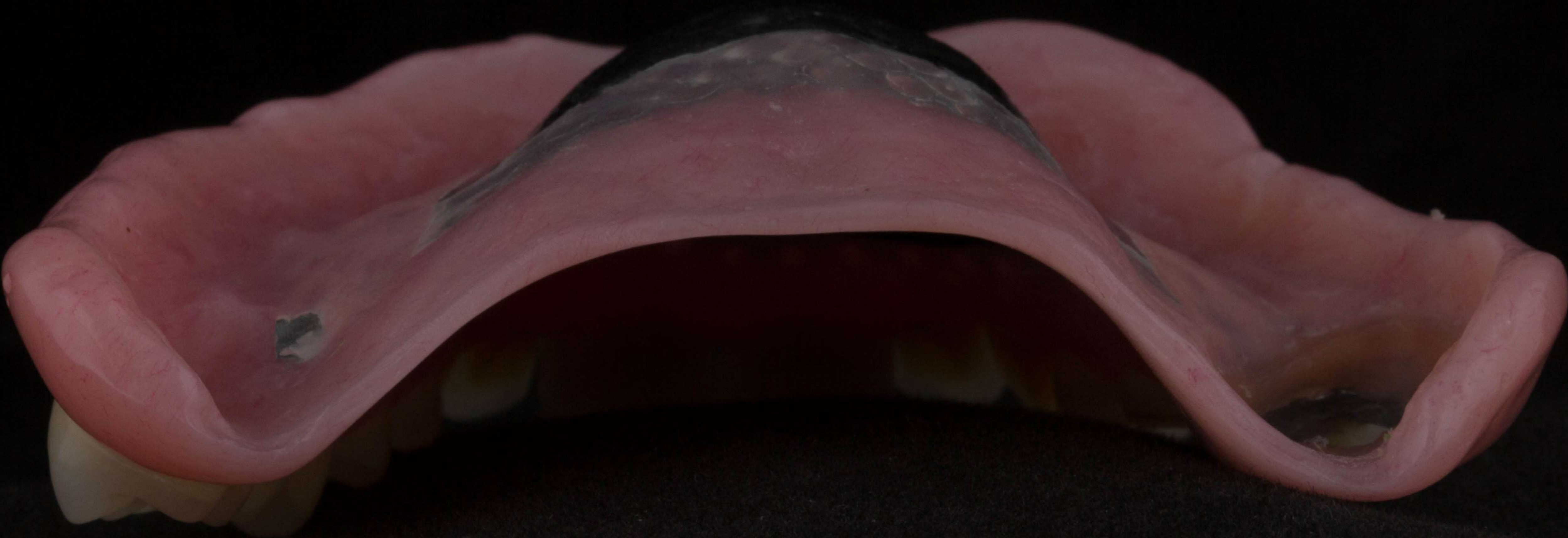


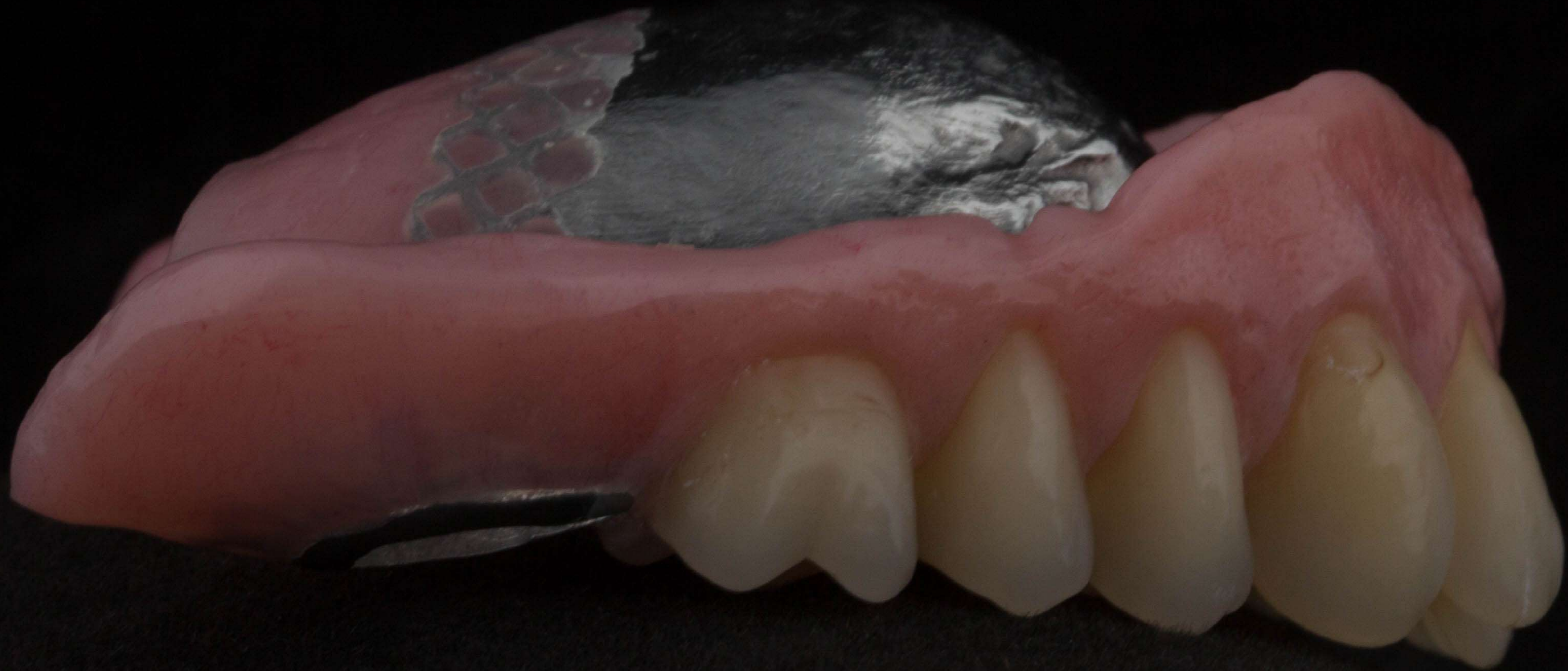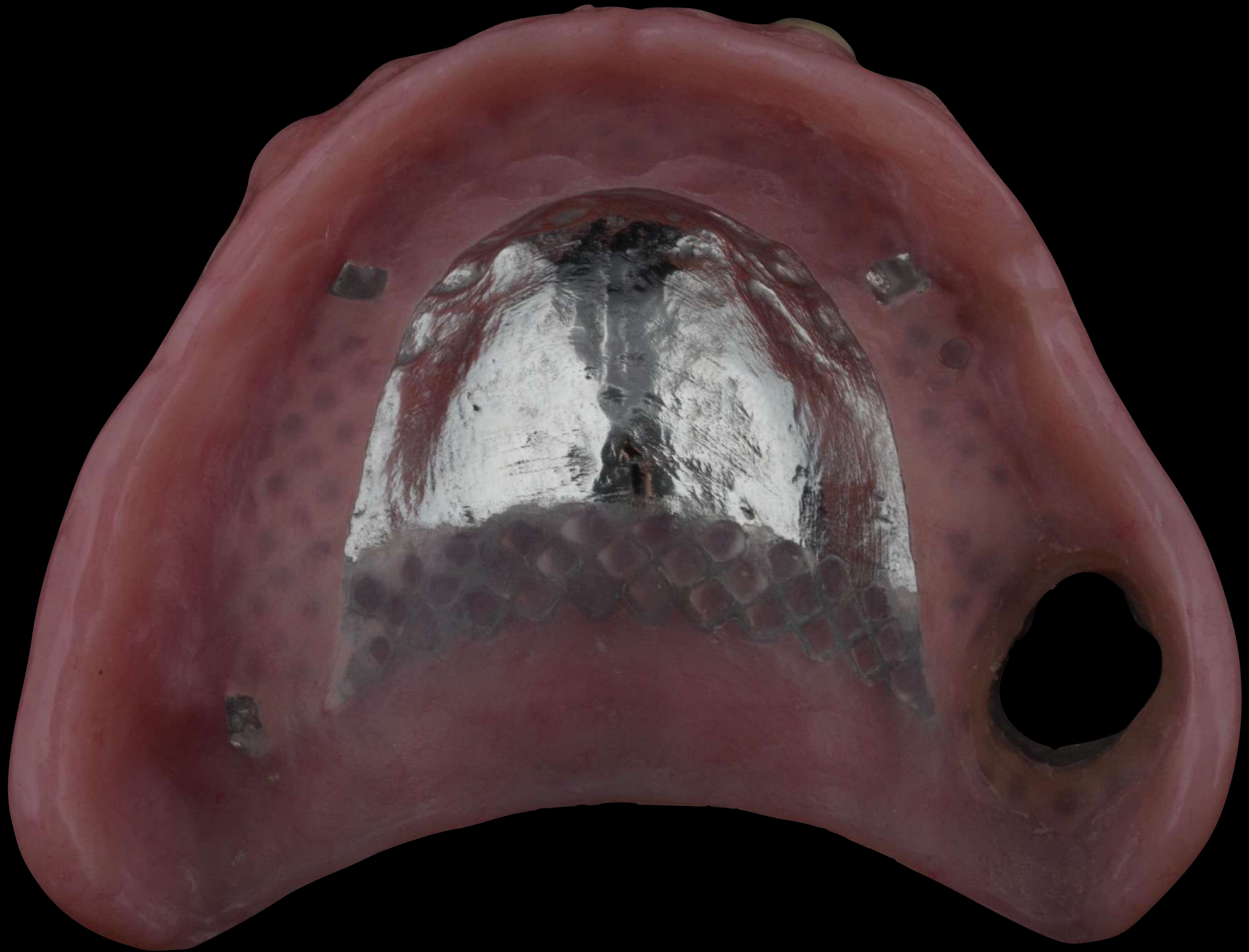


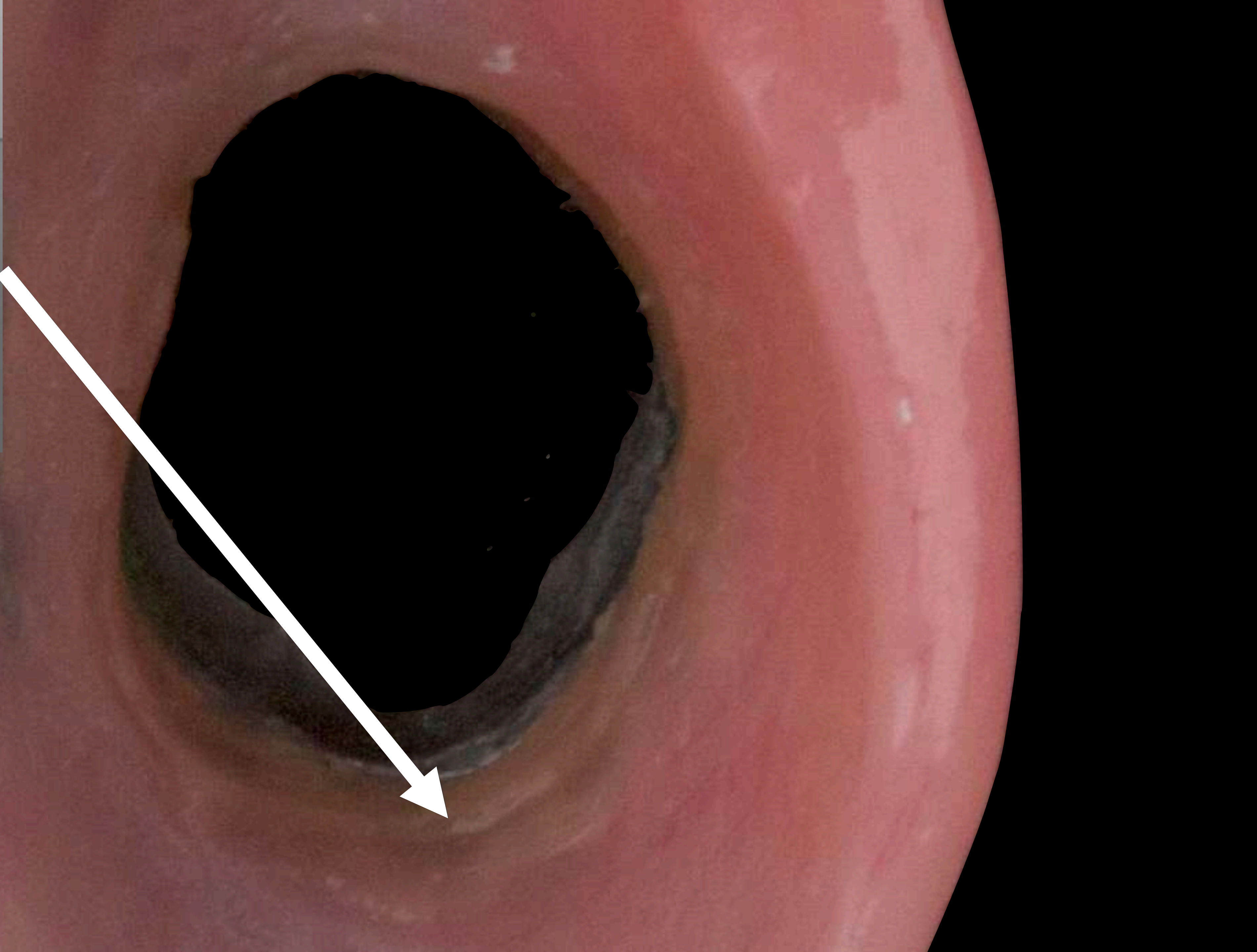


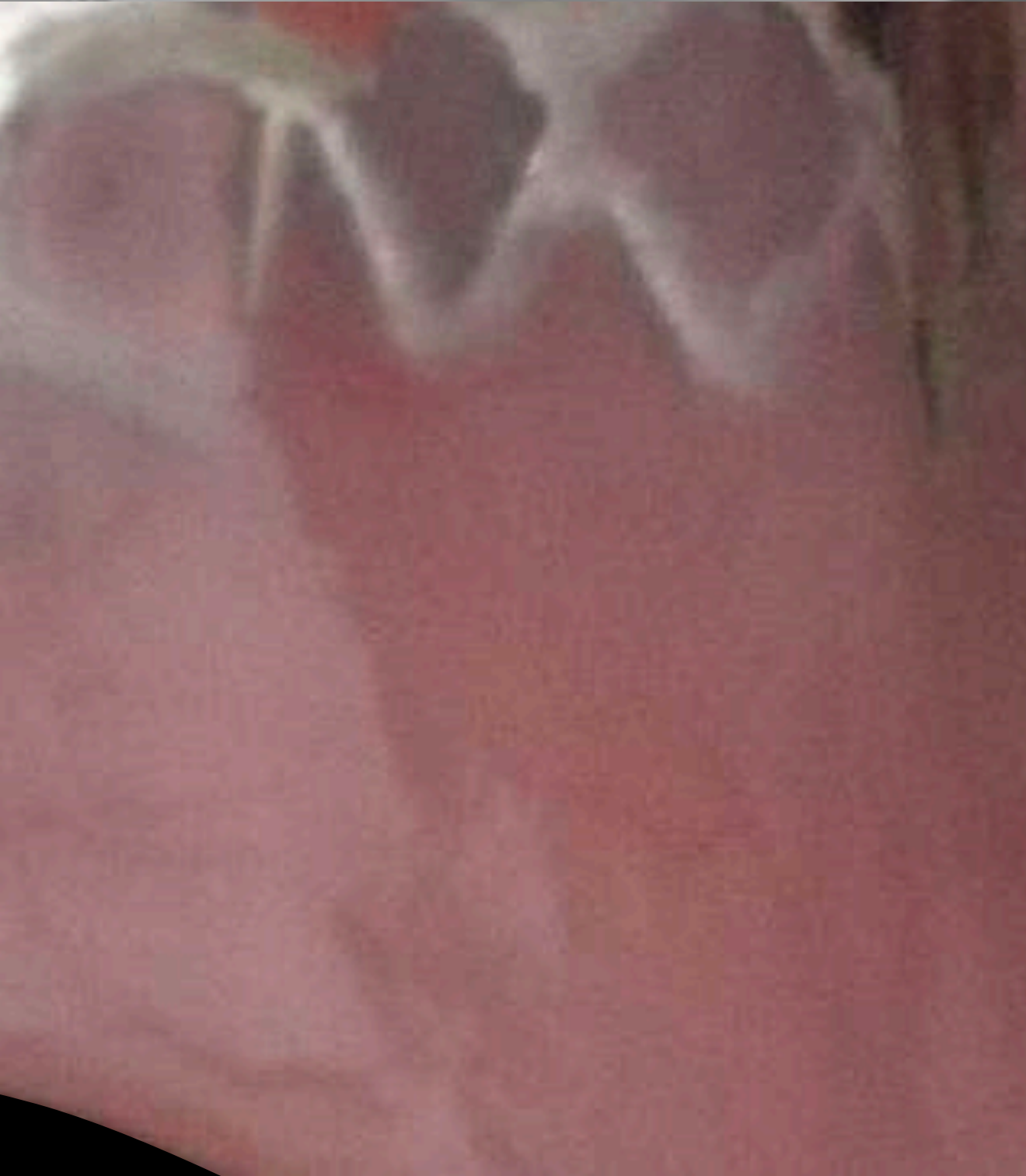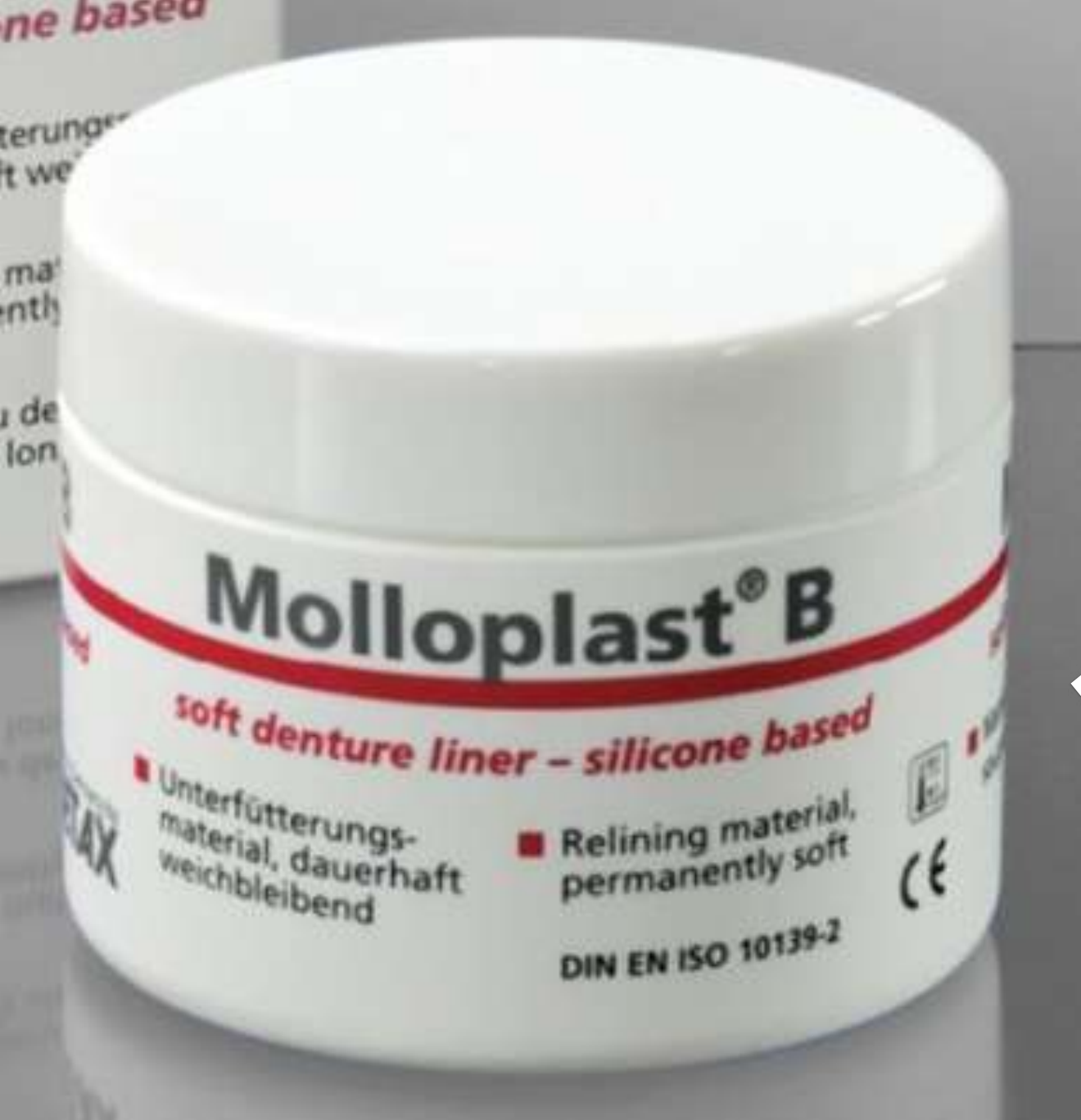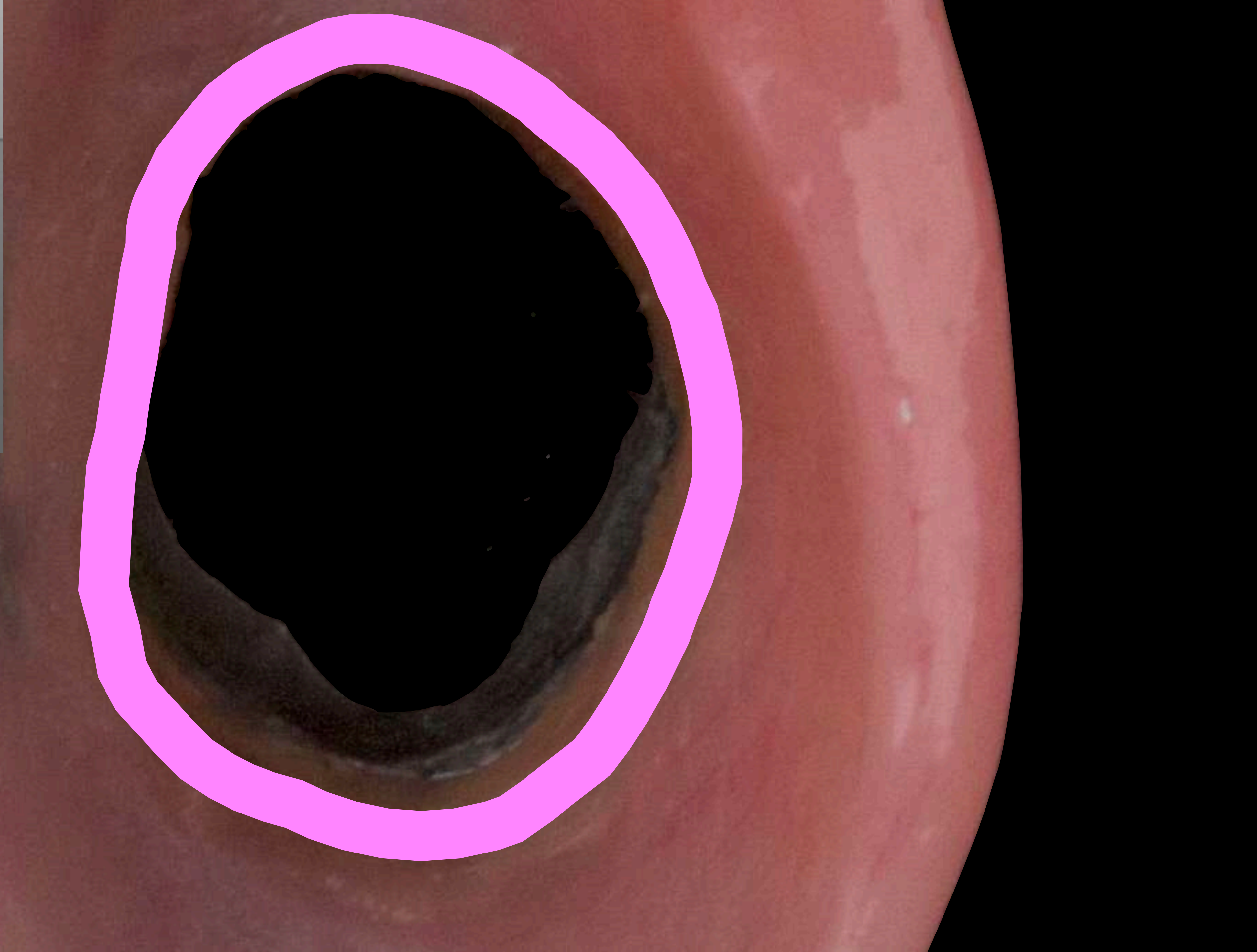





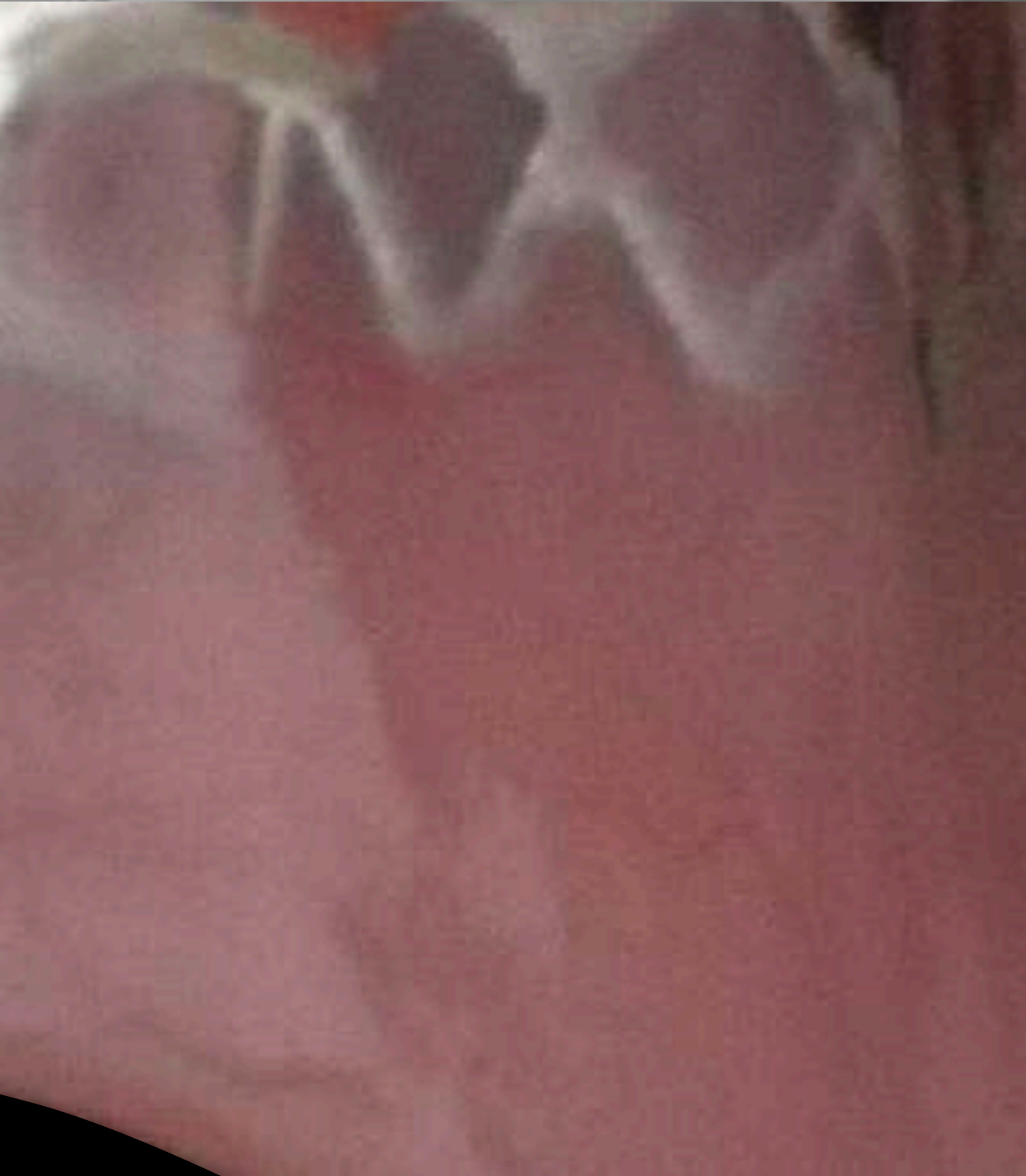
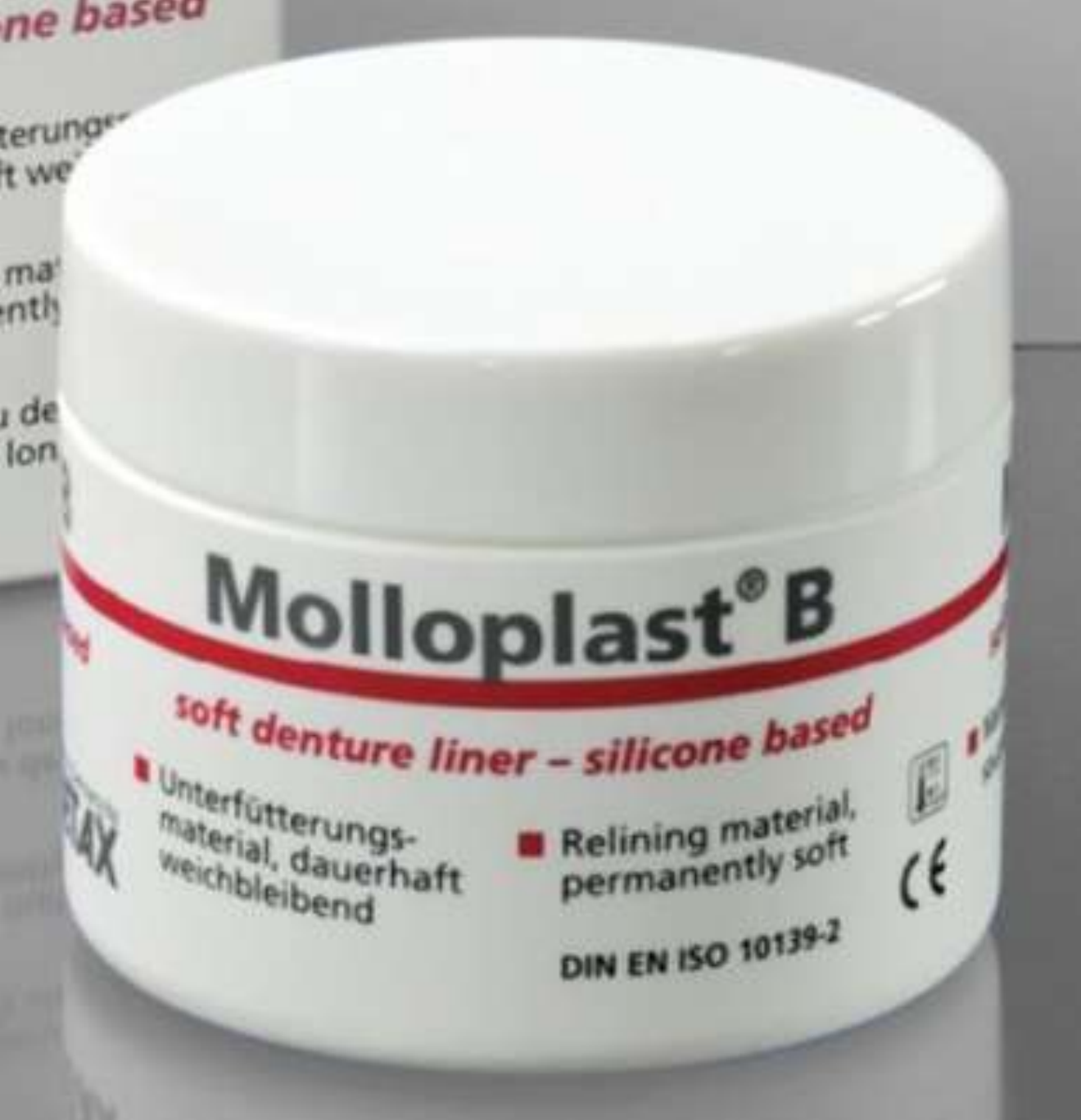




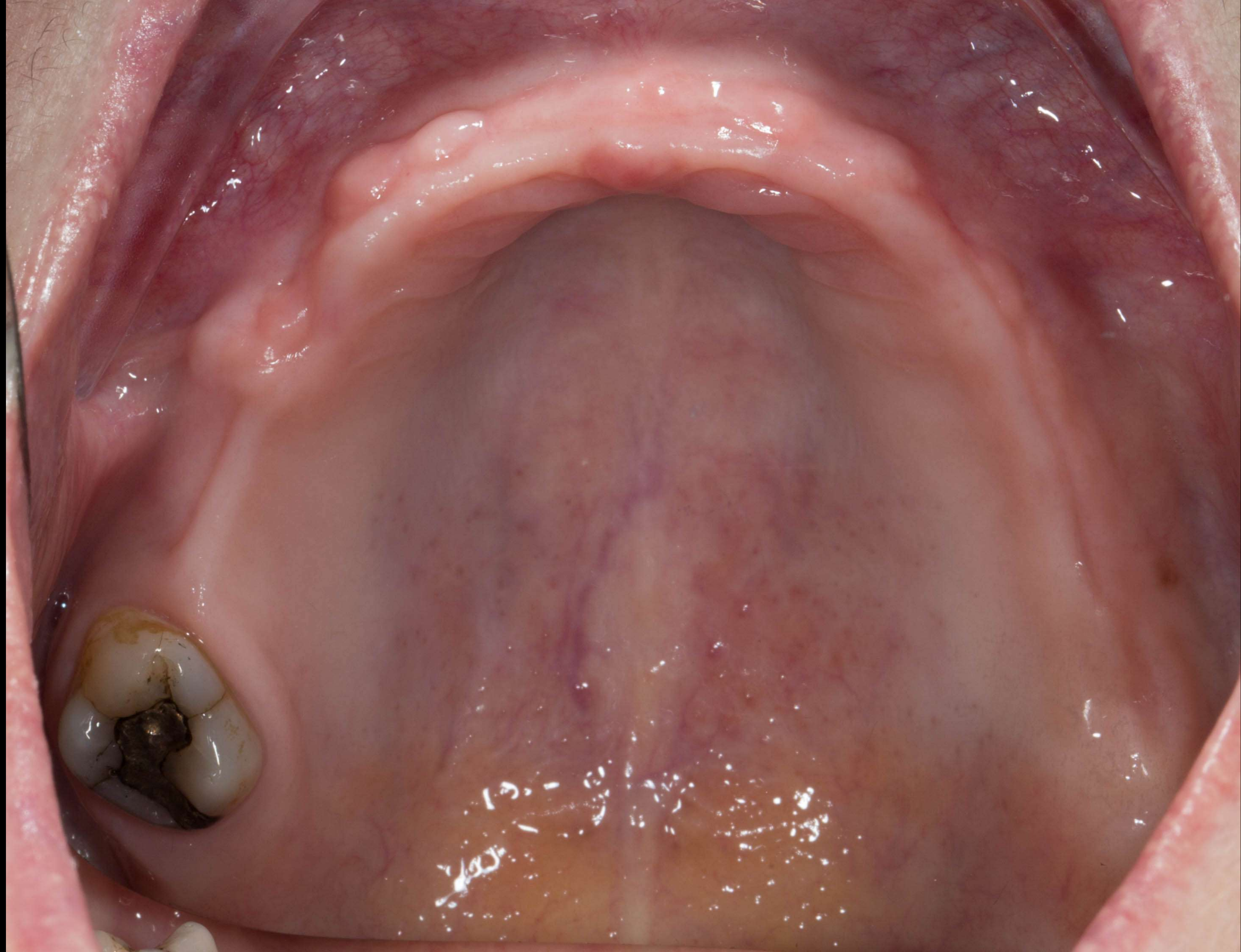


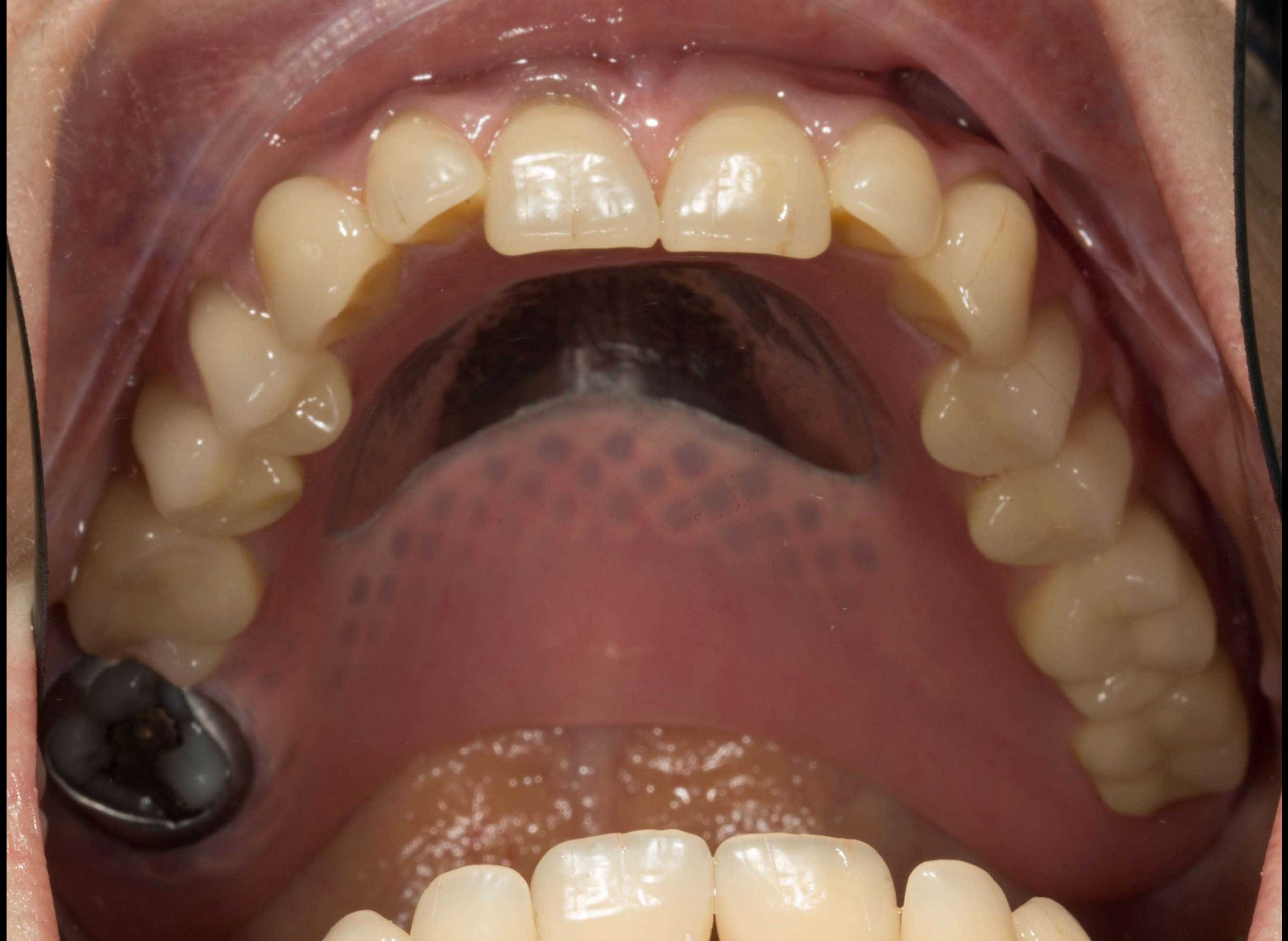


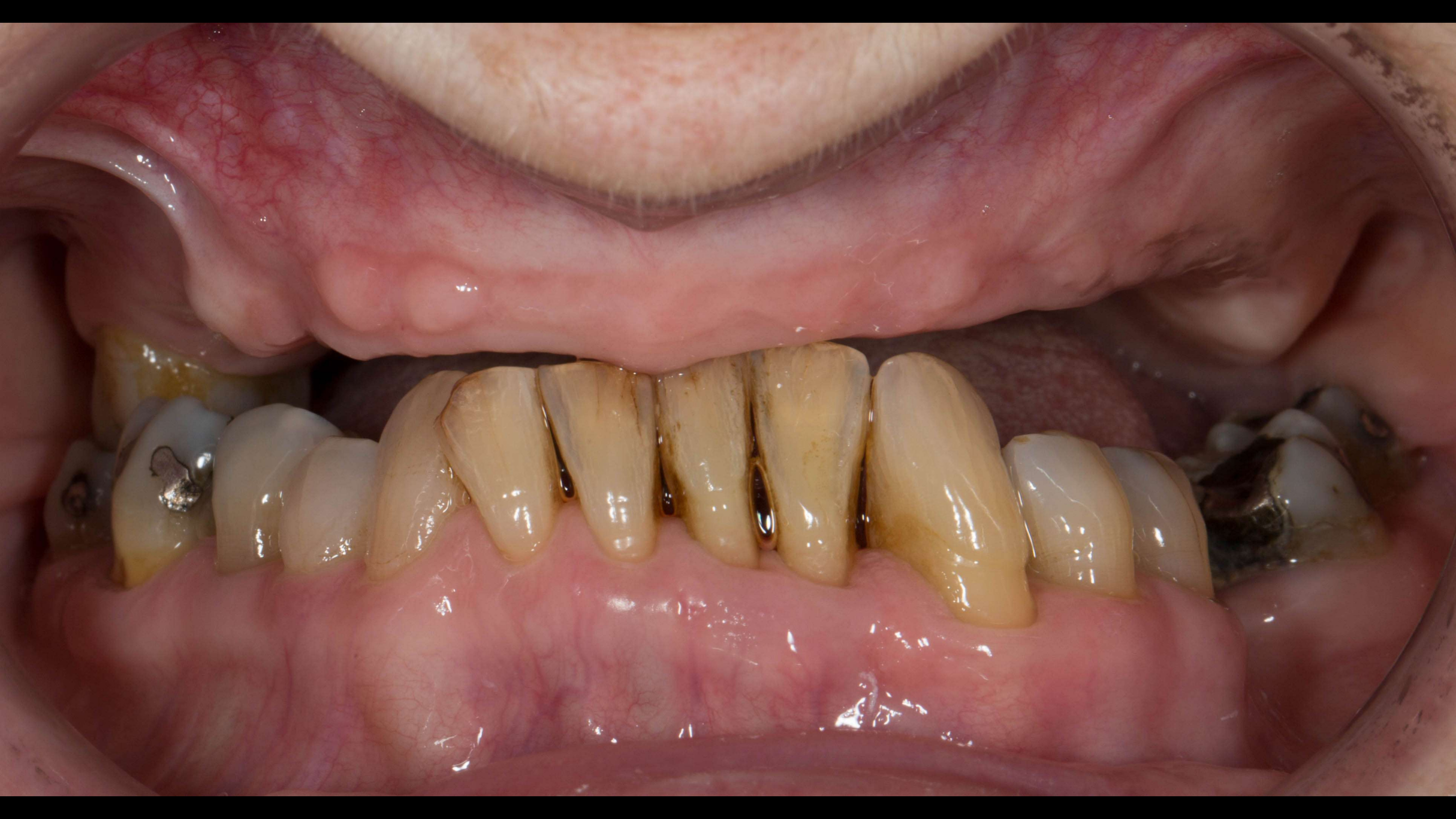


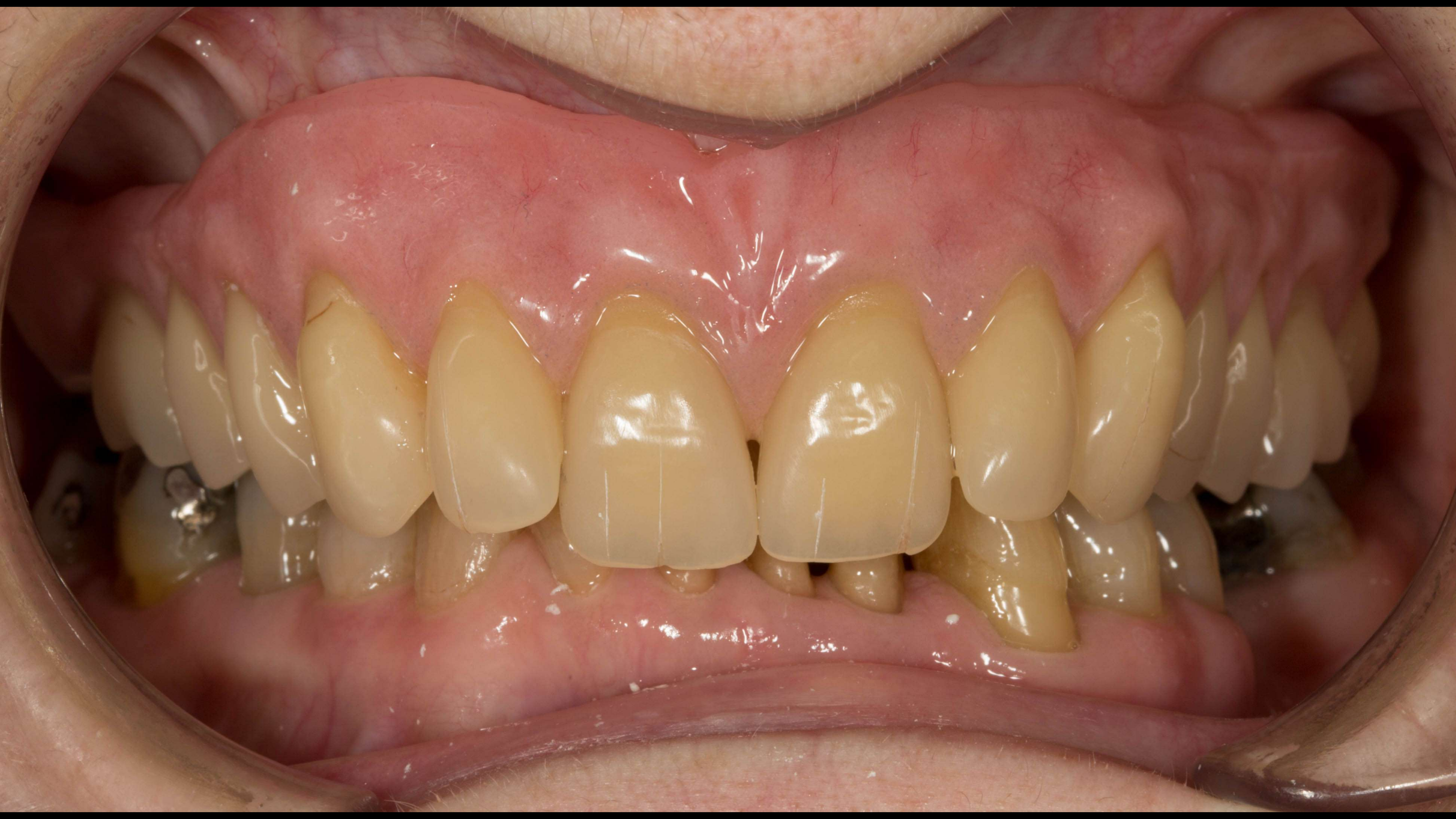


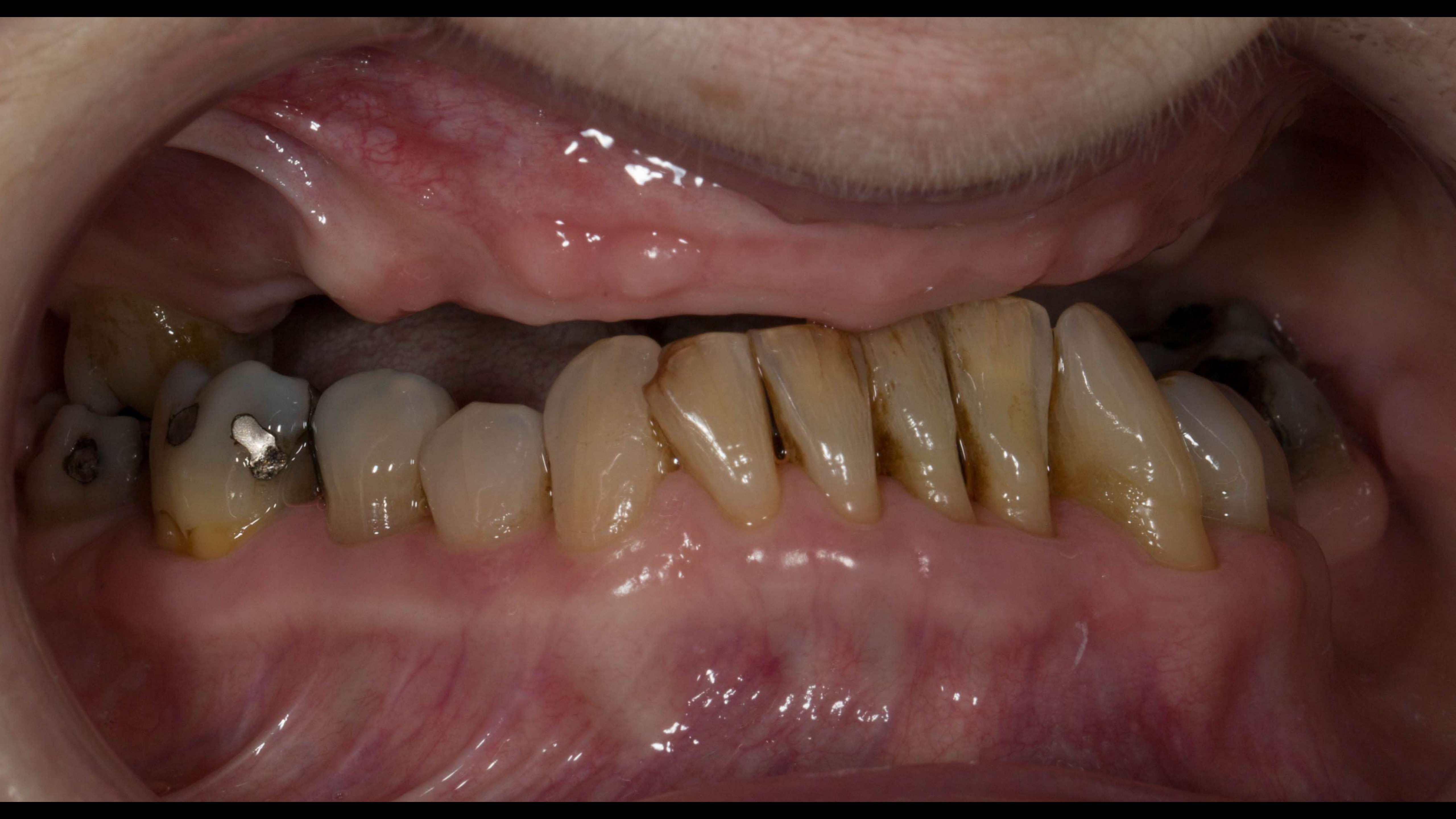


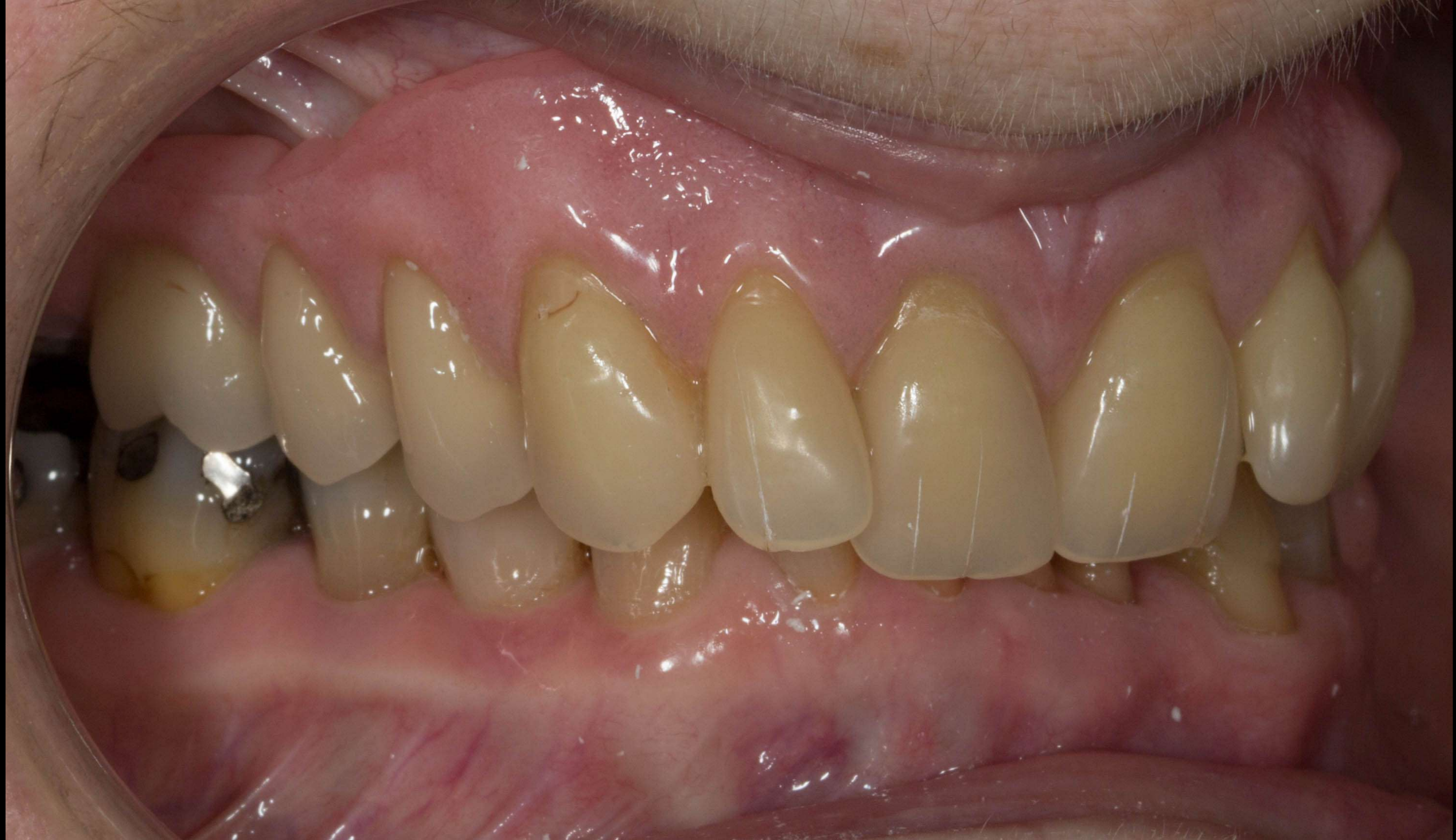


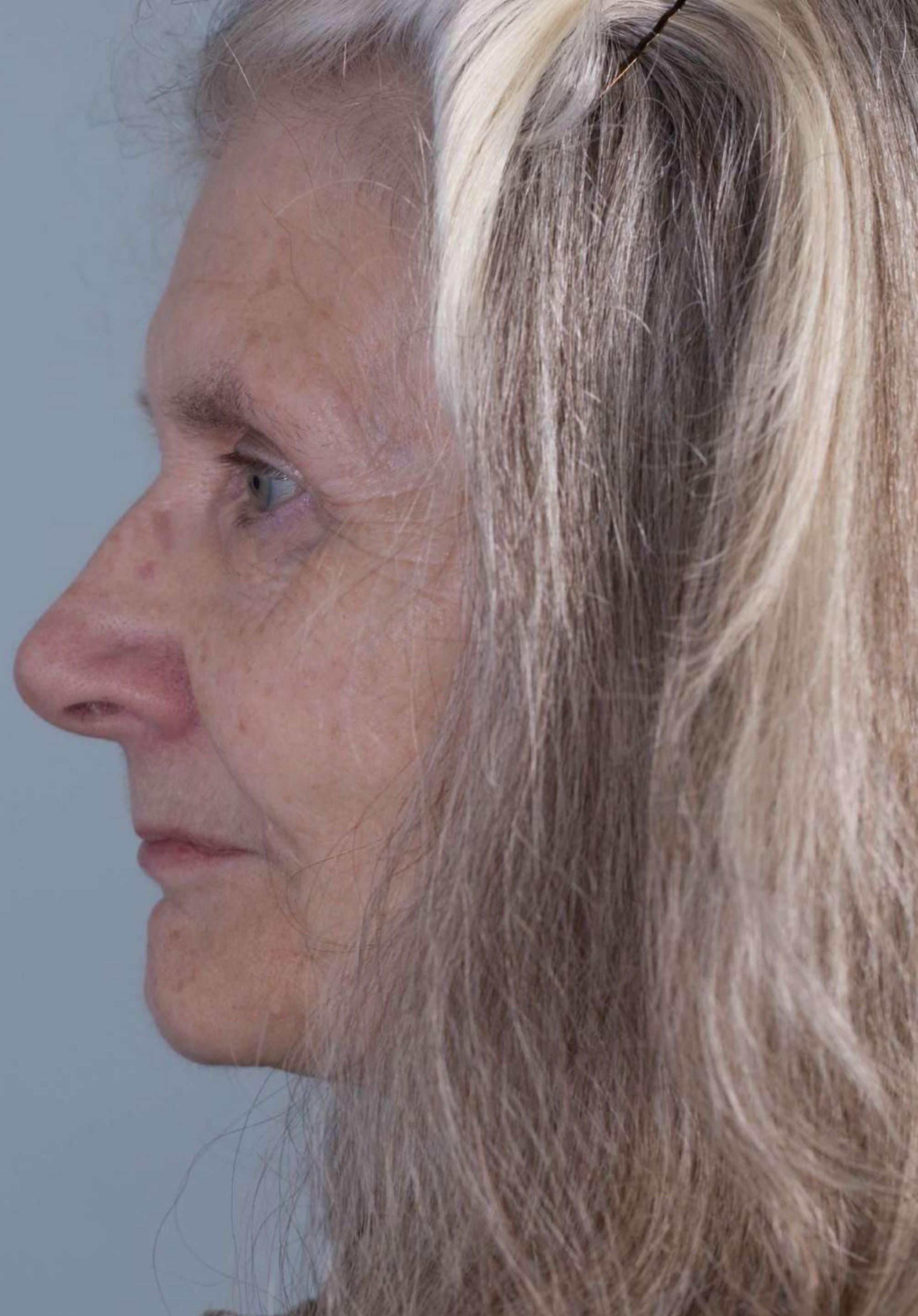
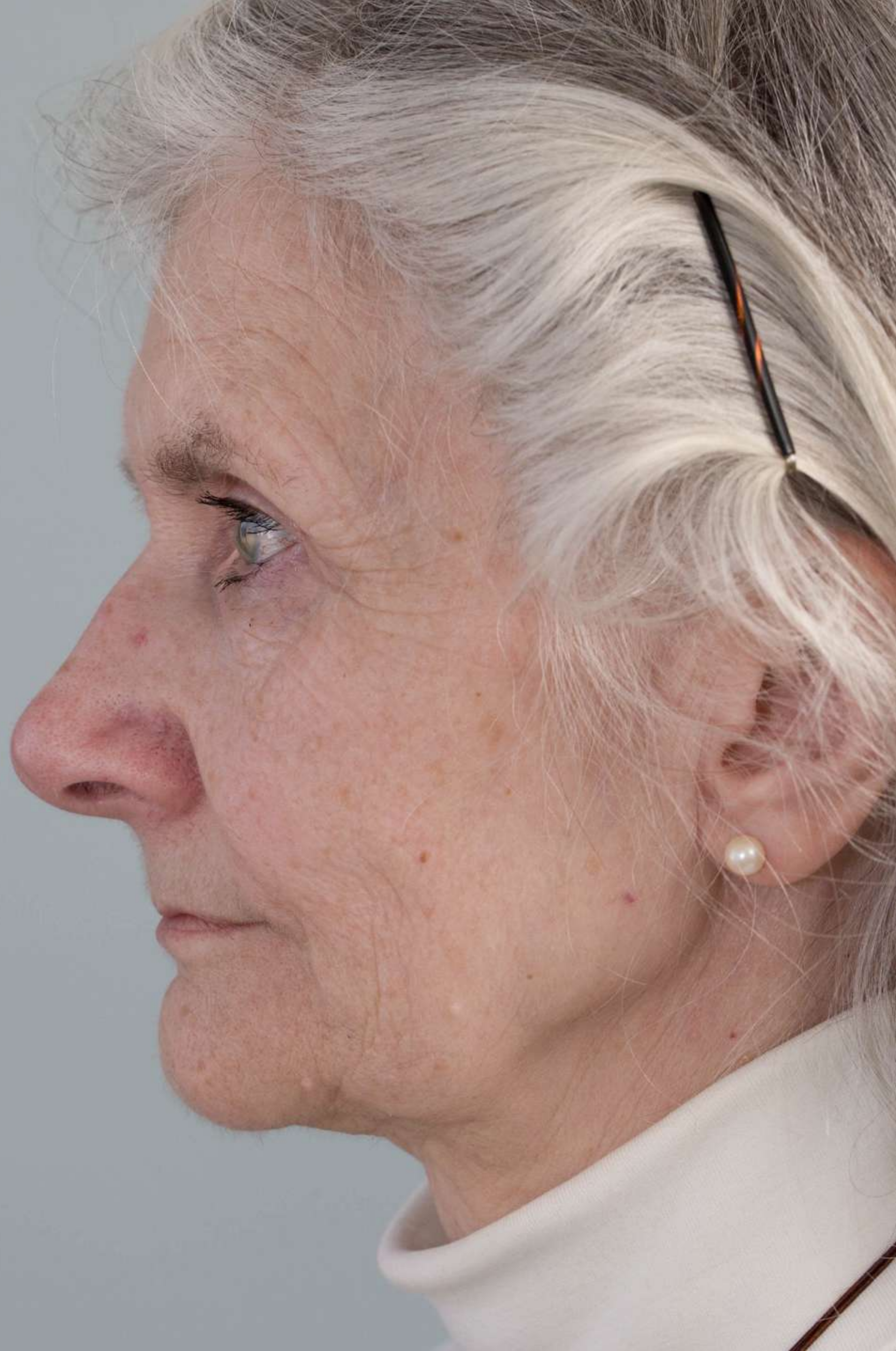


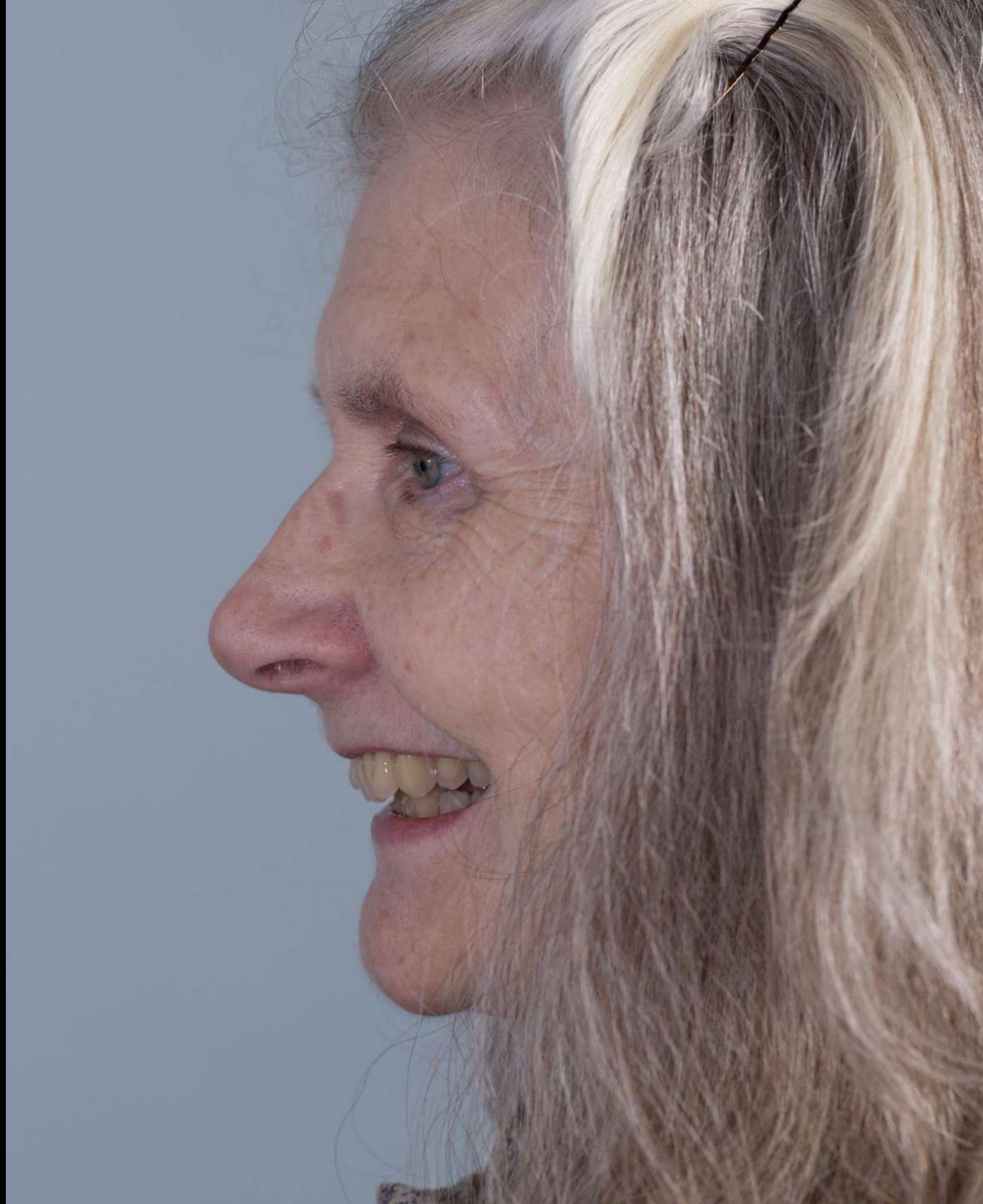
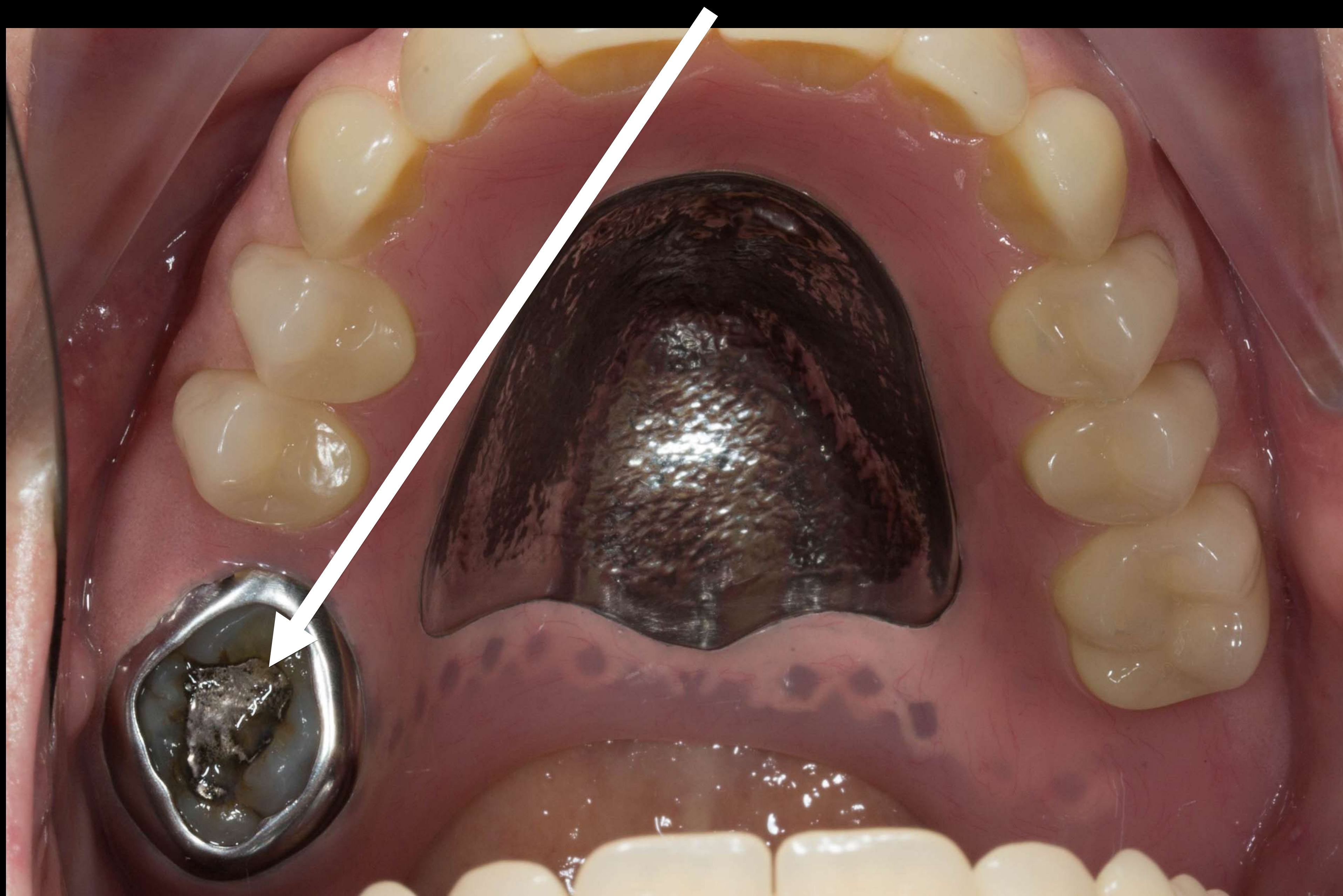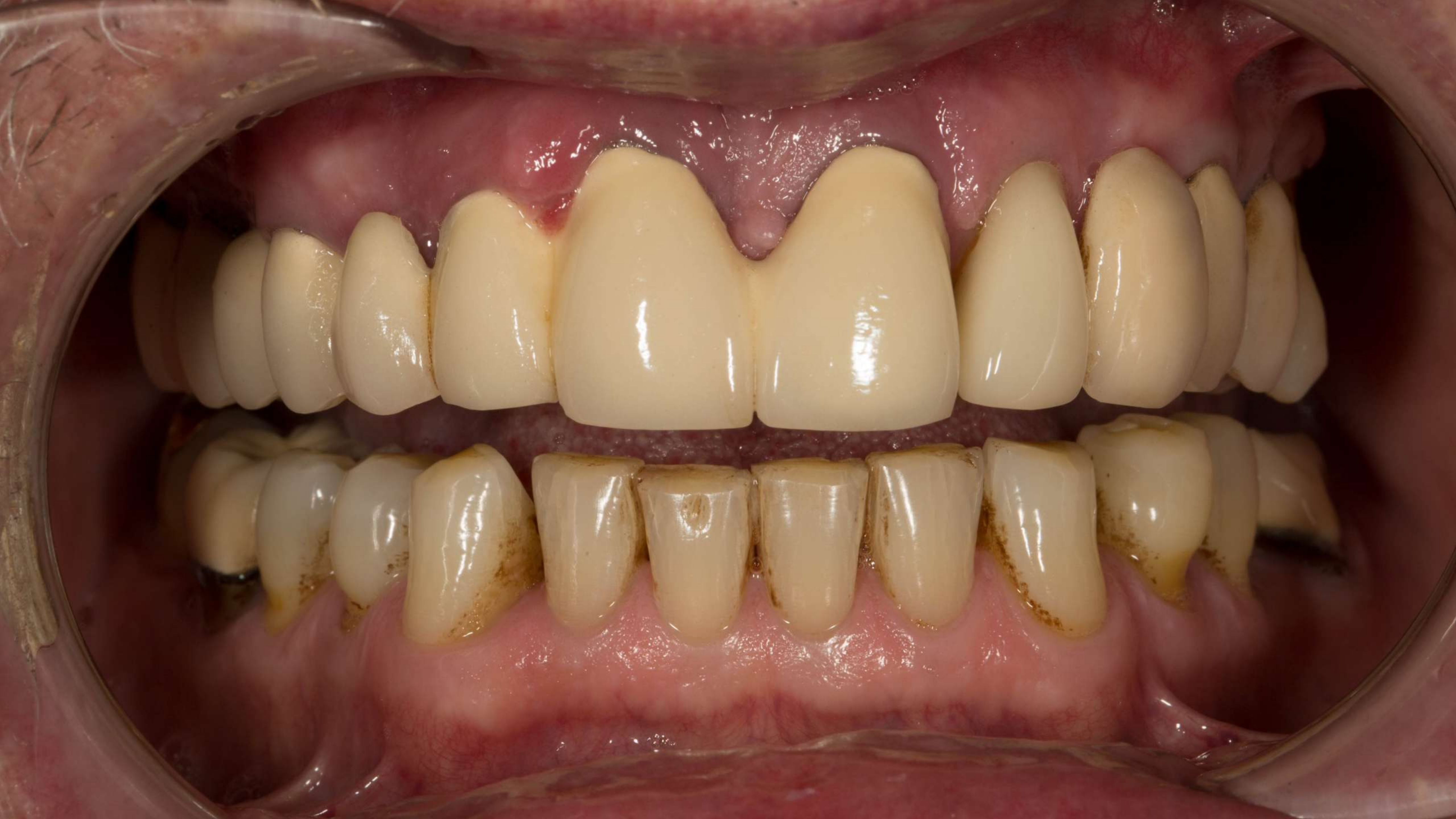The window may accelerate  
the demise of the tooth

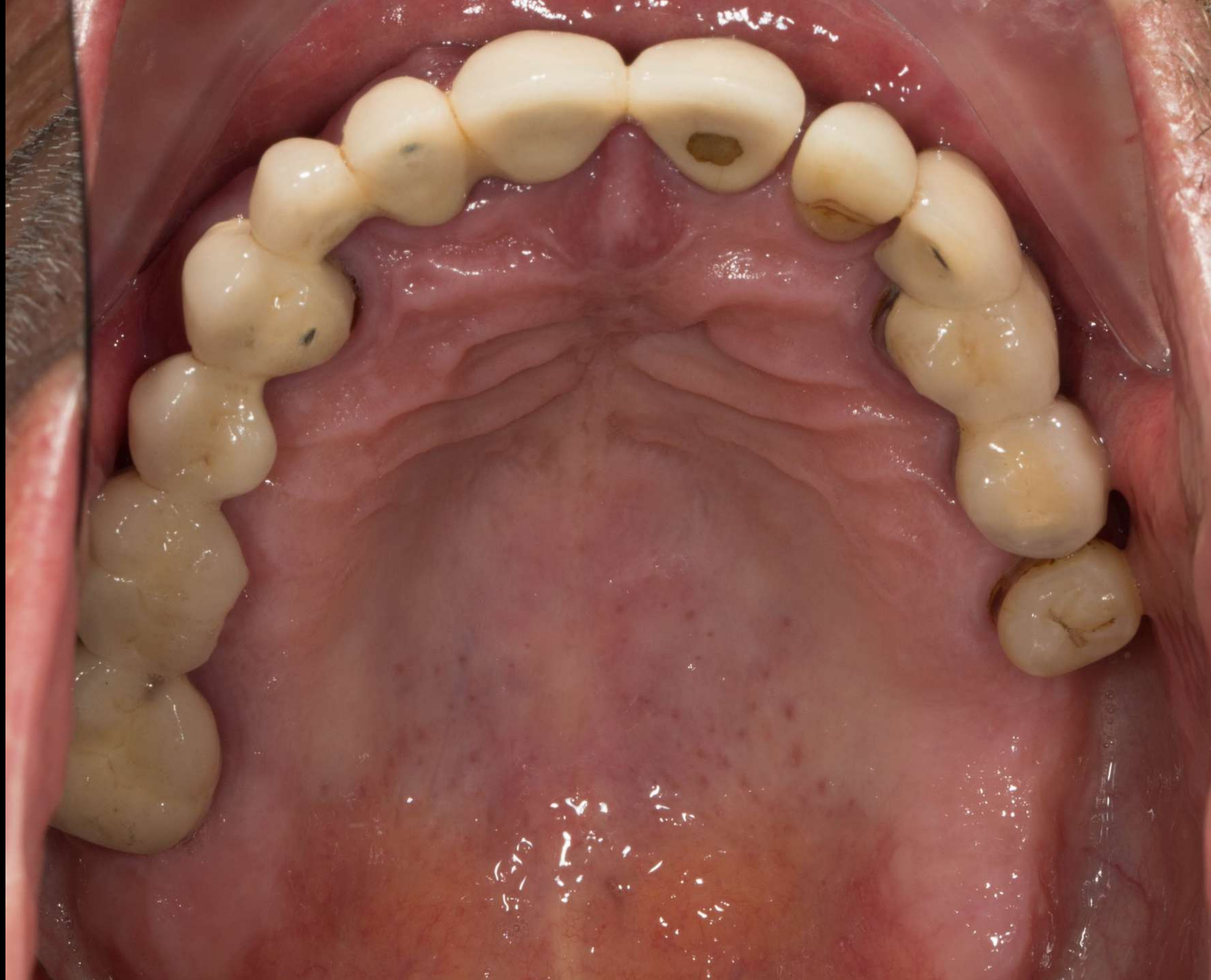If support tooth fails - addition to convert to complete denture

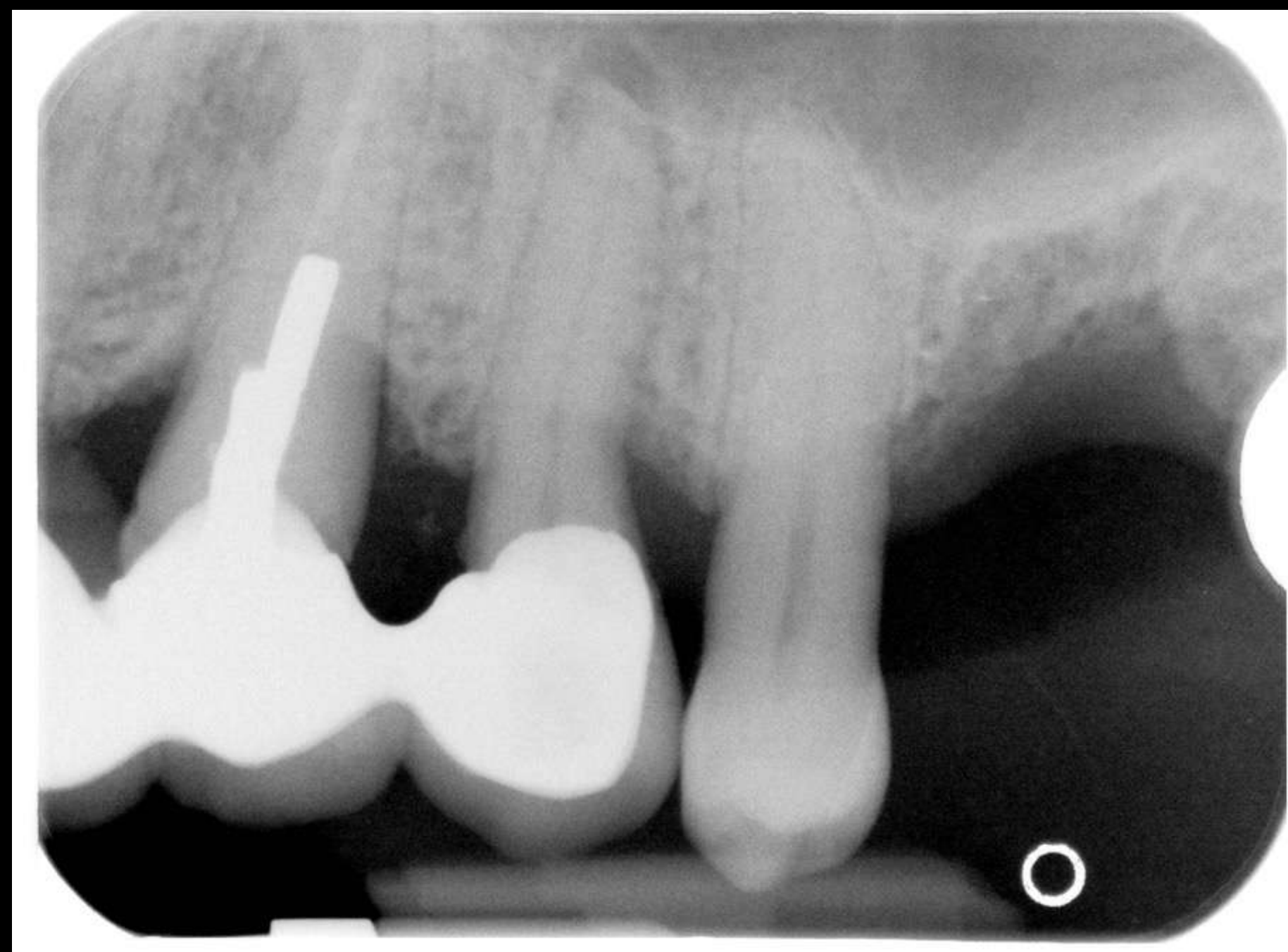
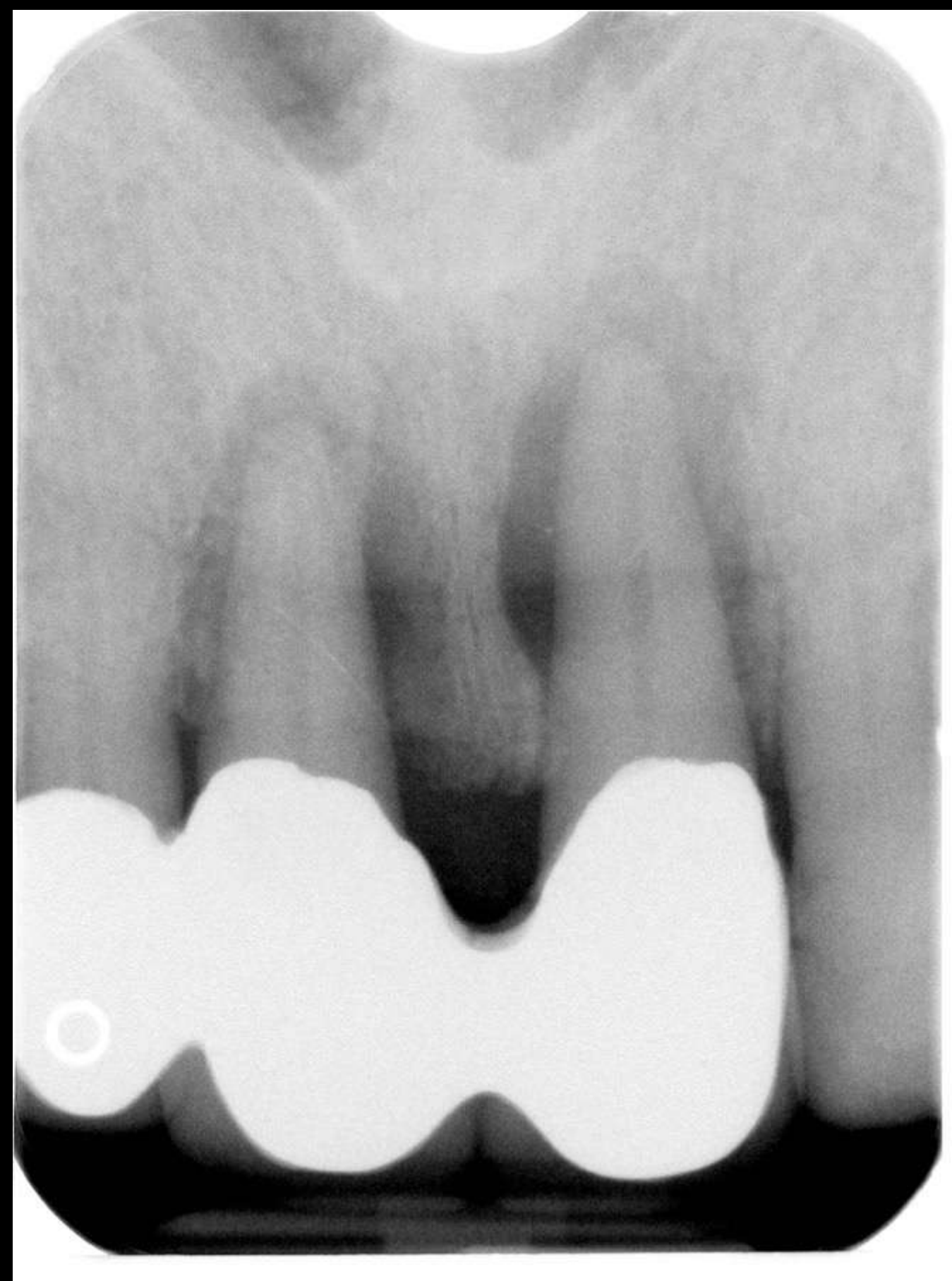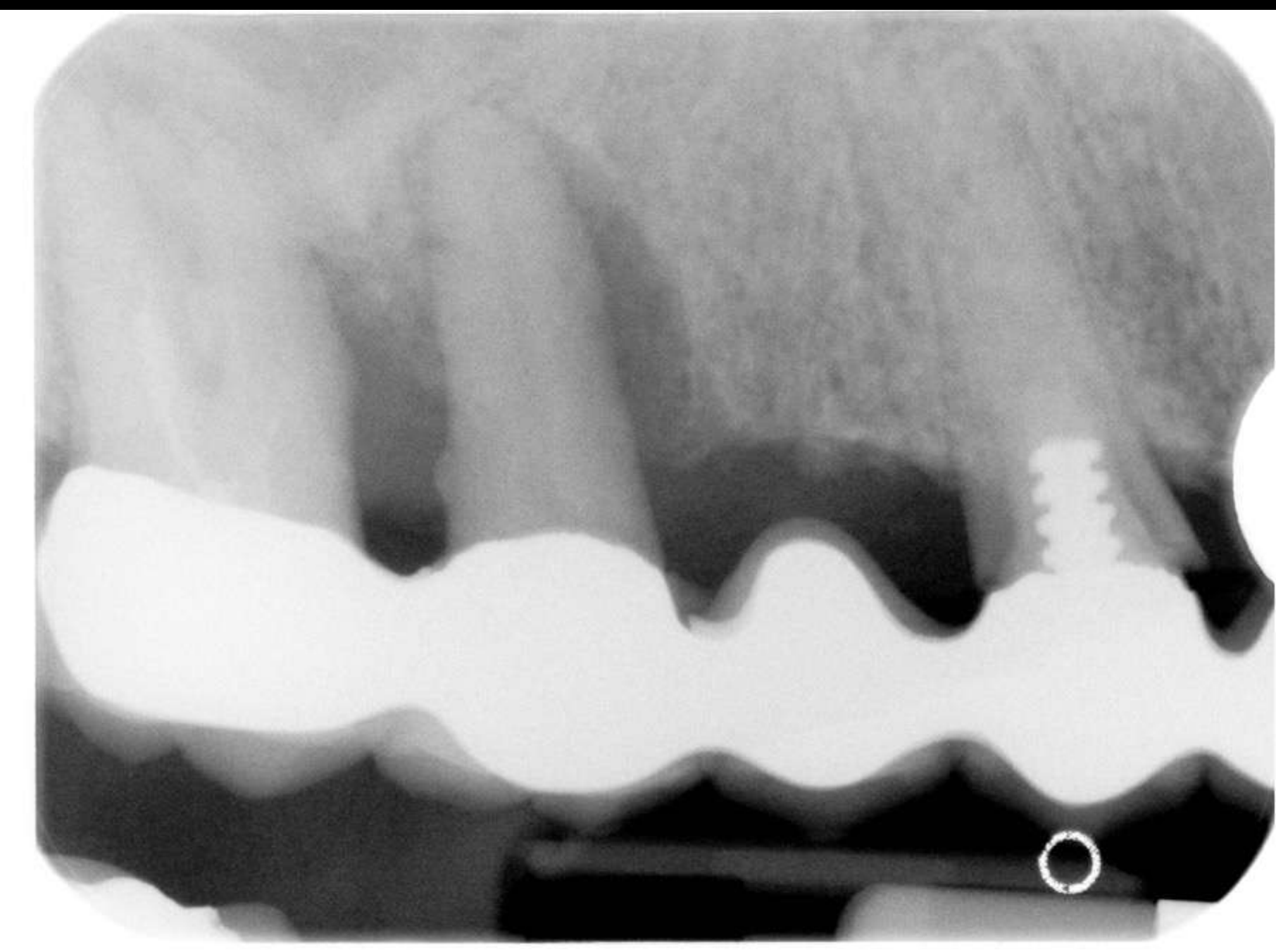


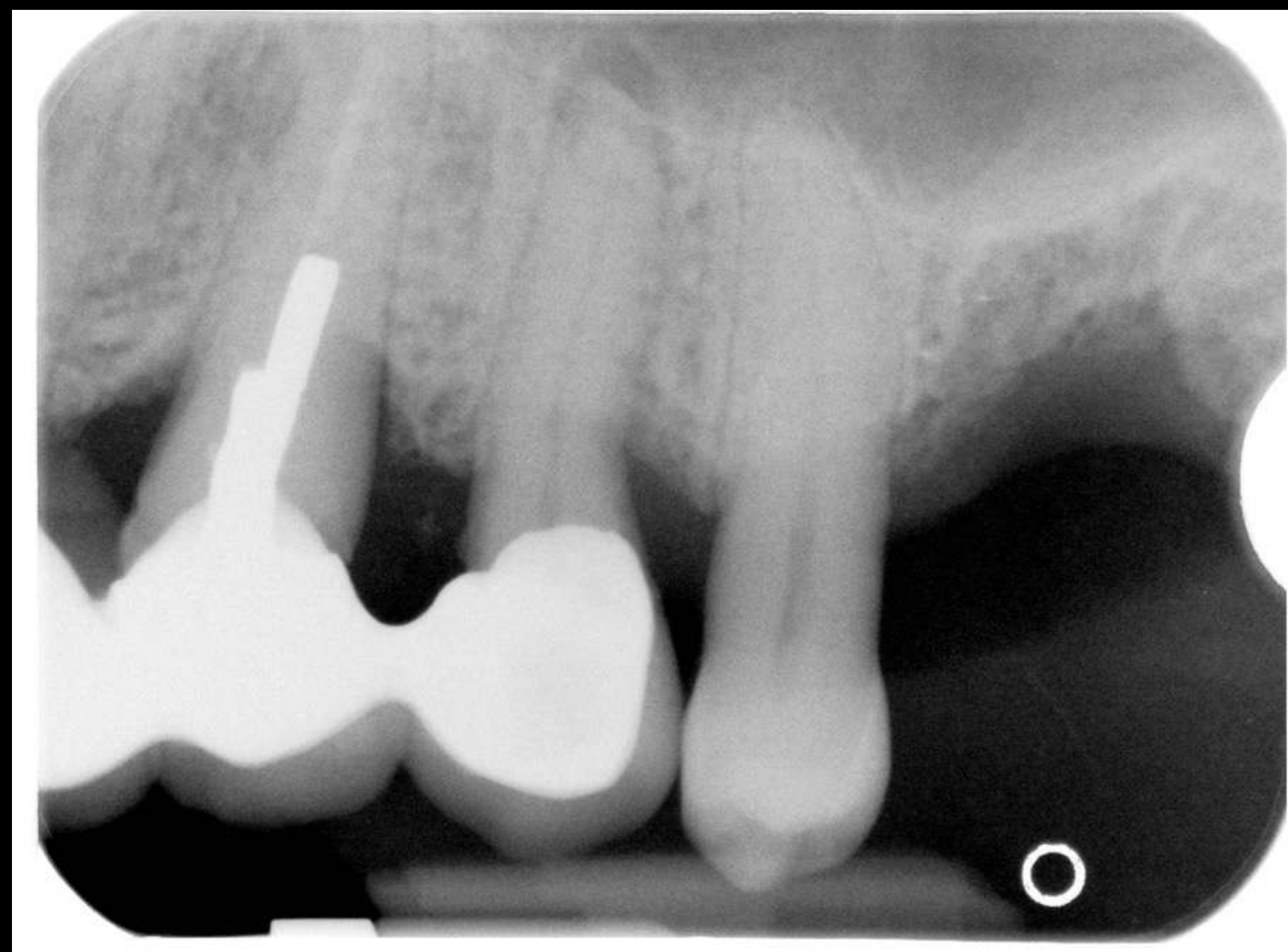
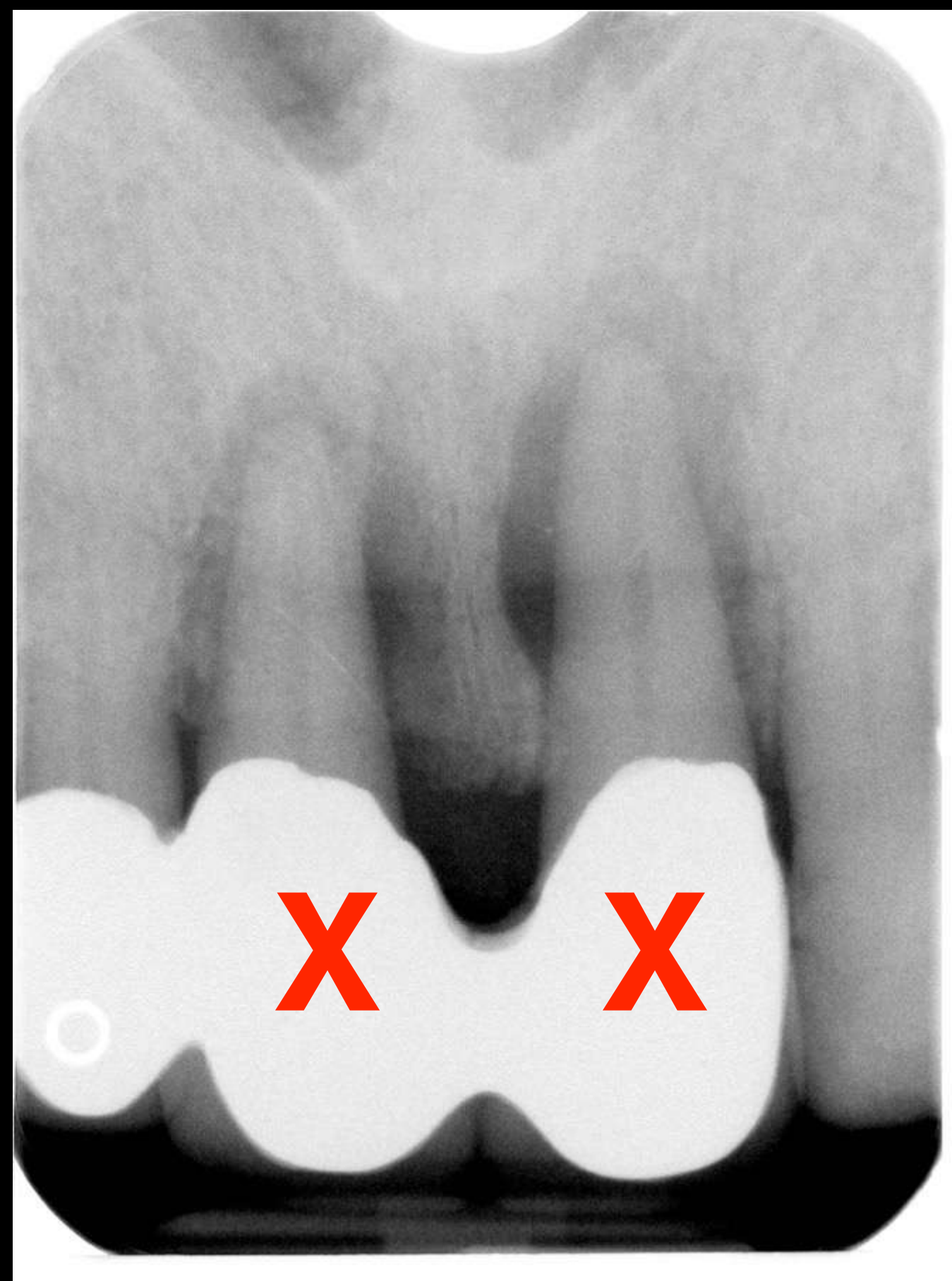
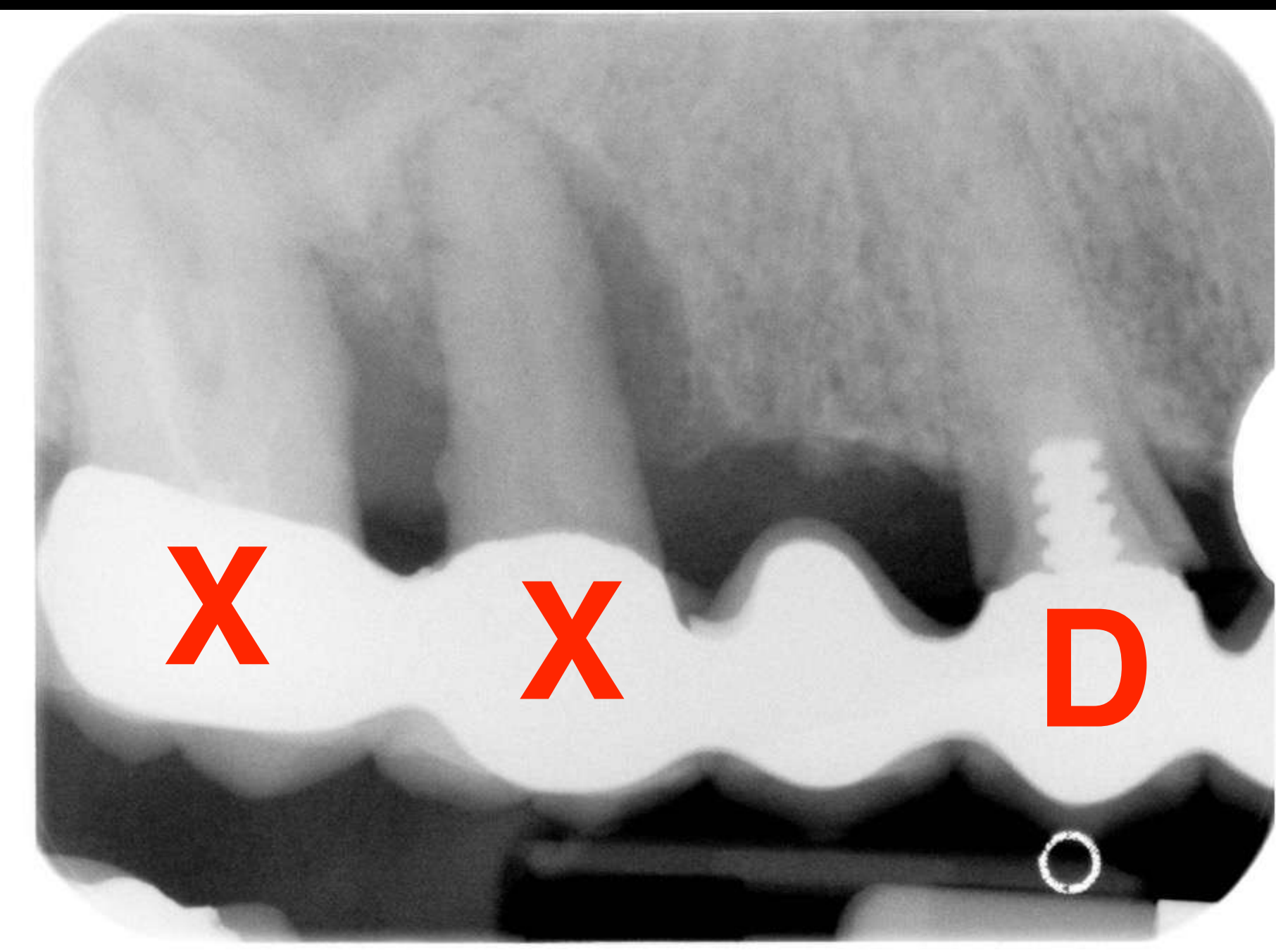


John

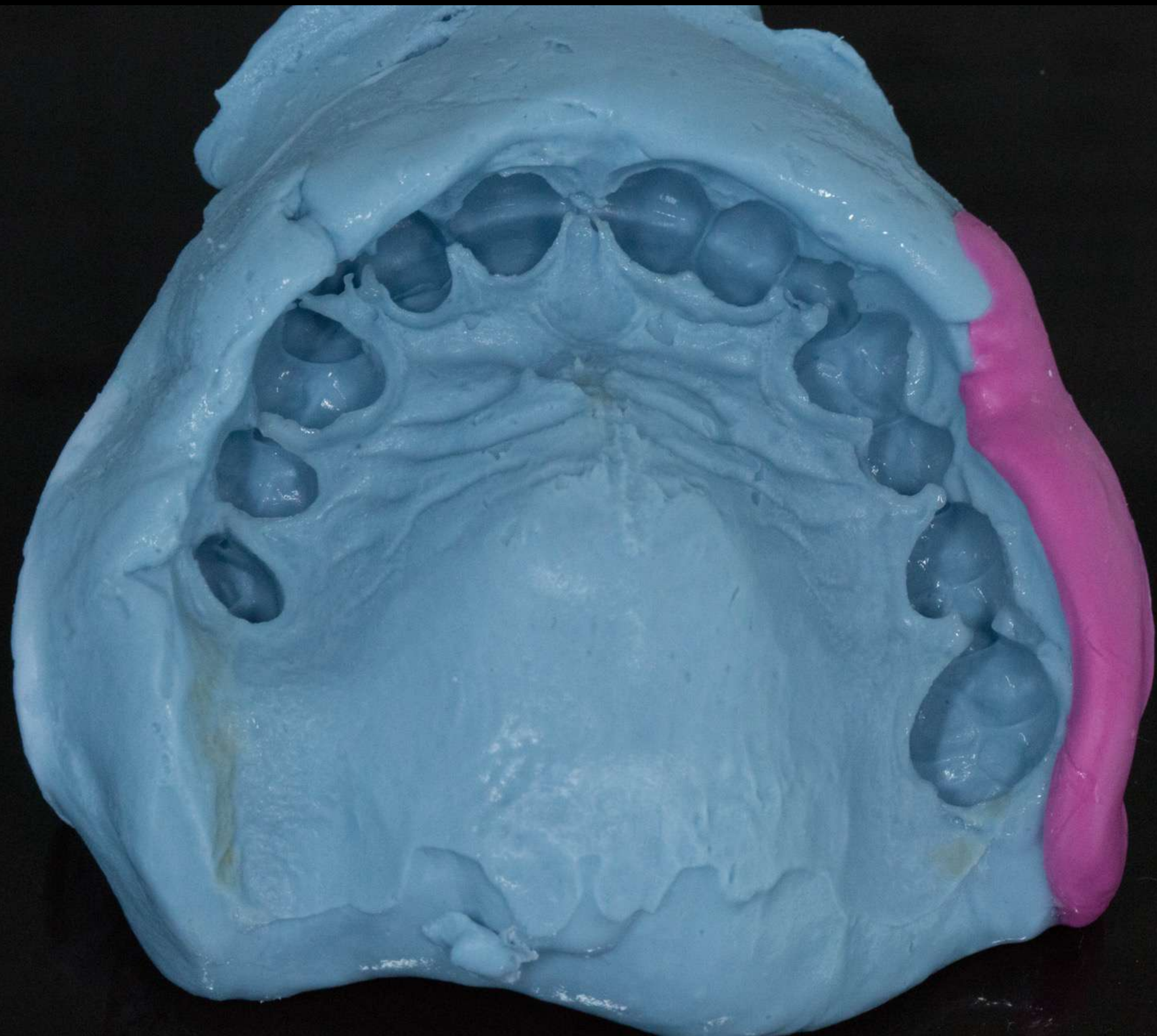


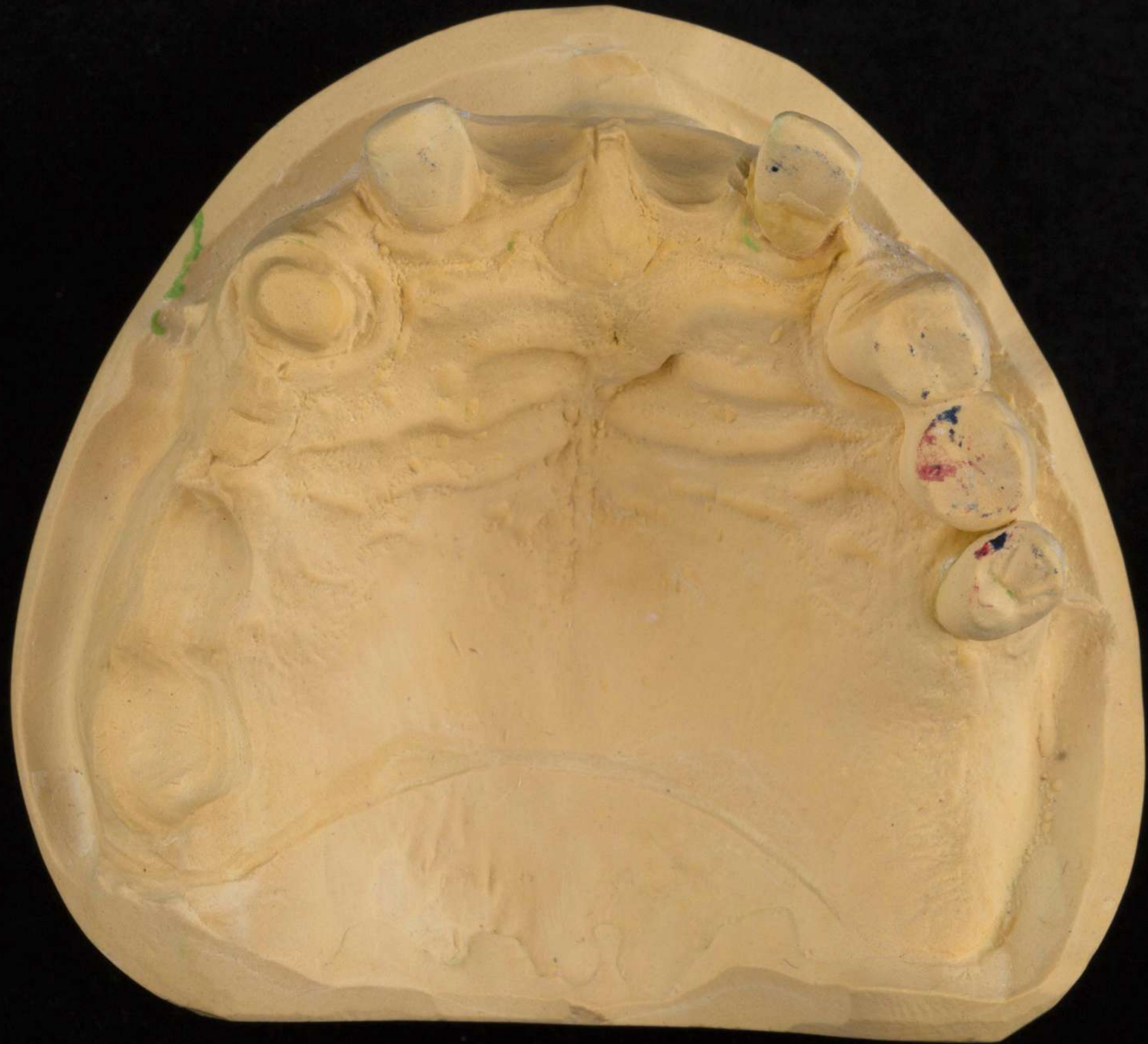


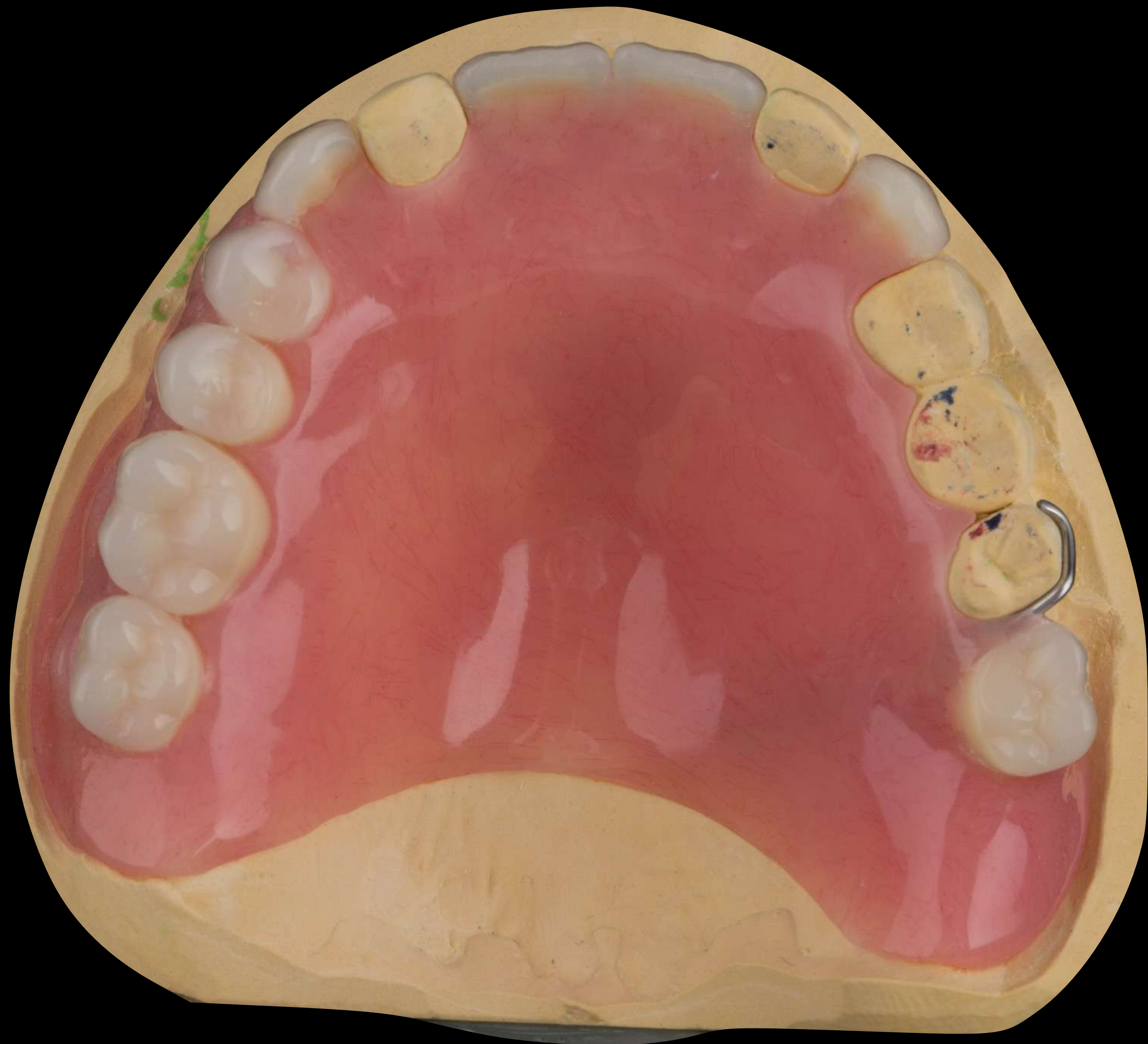


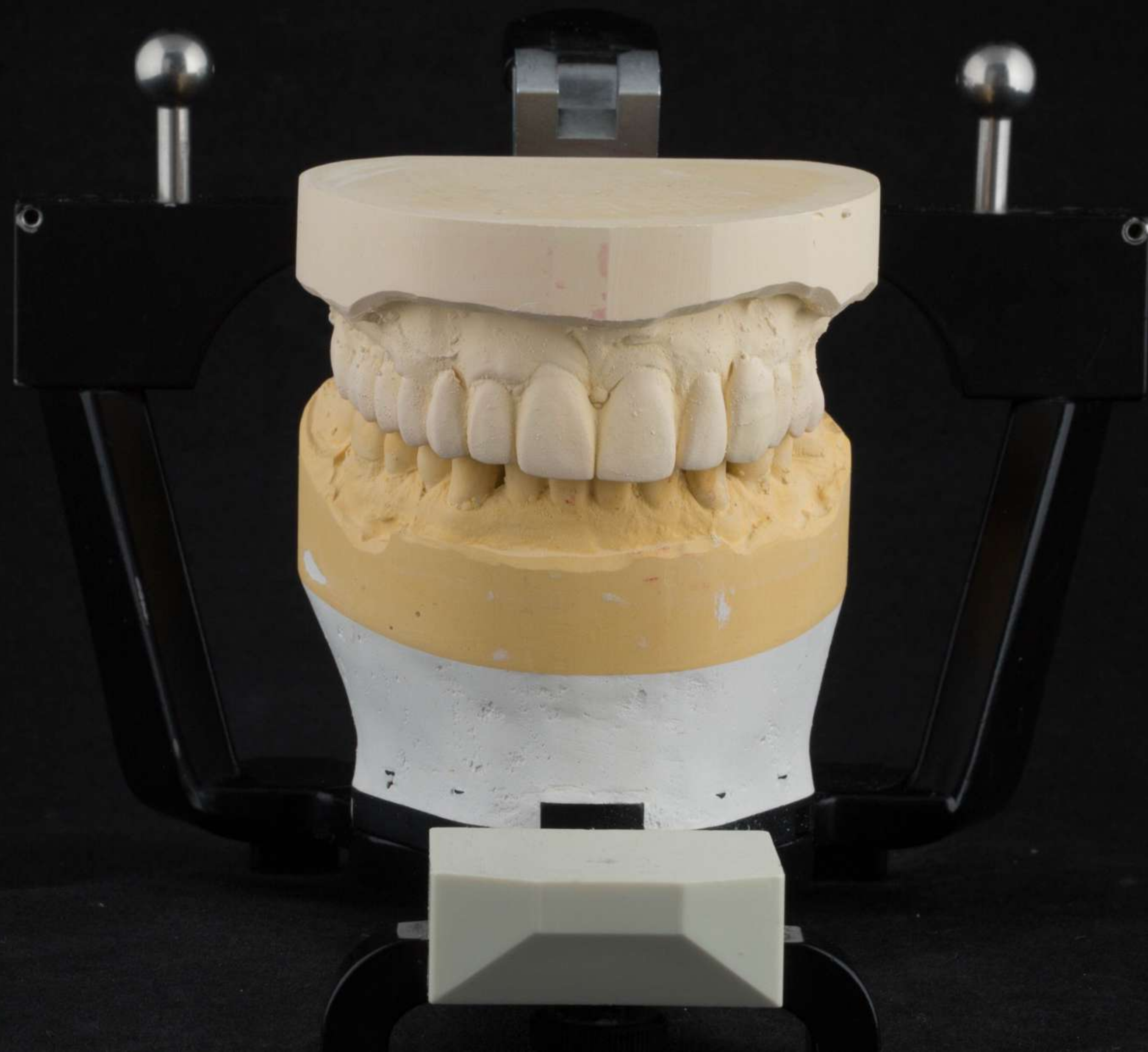


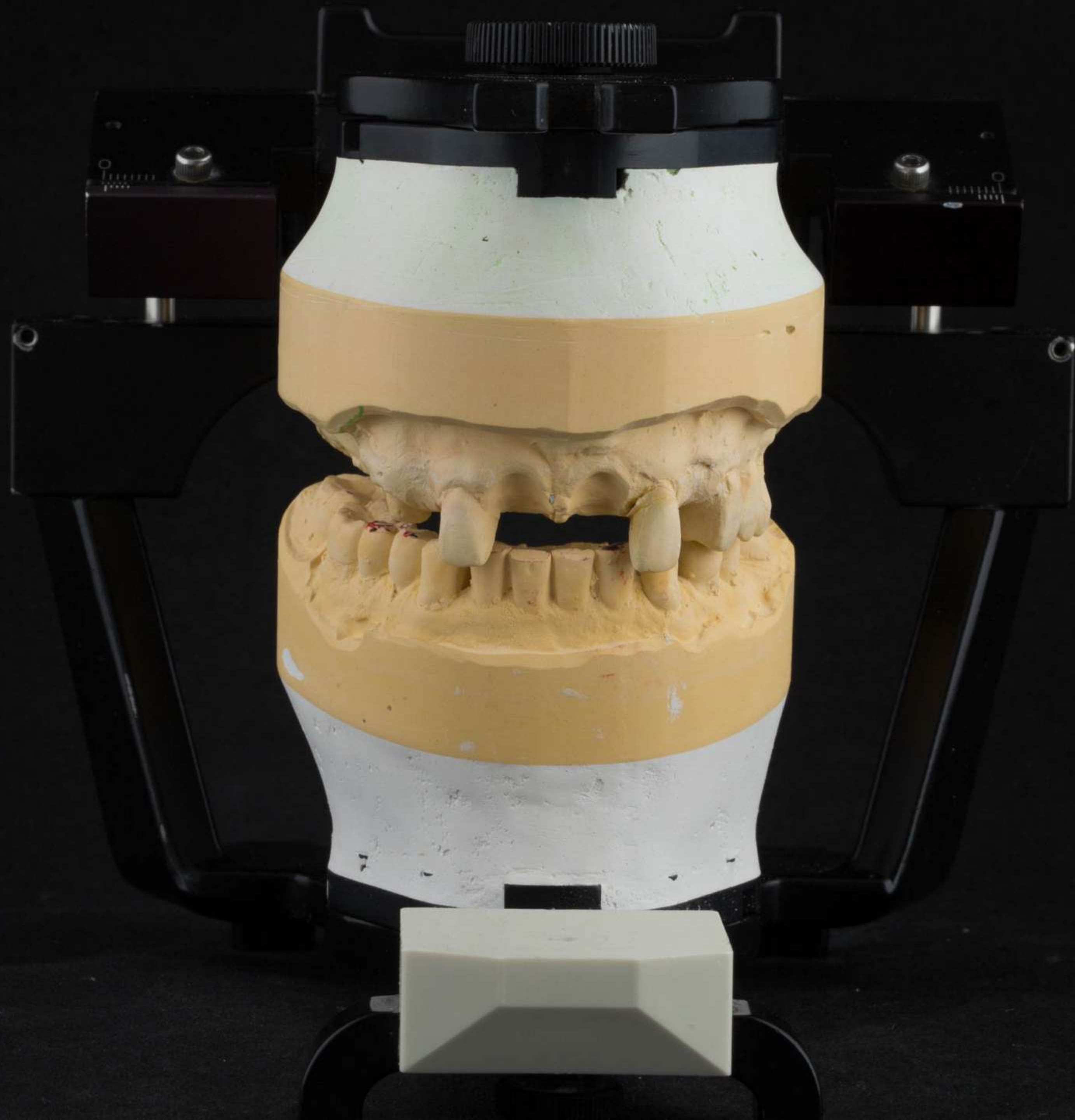

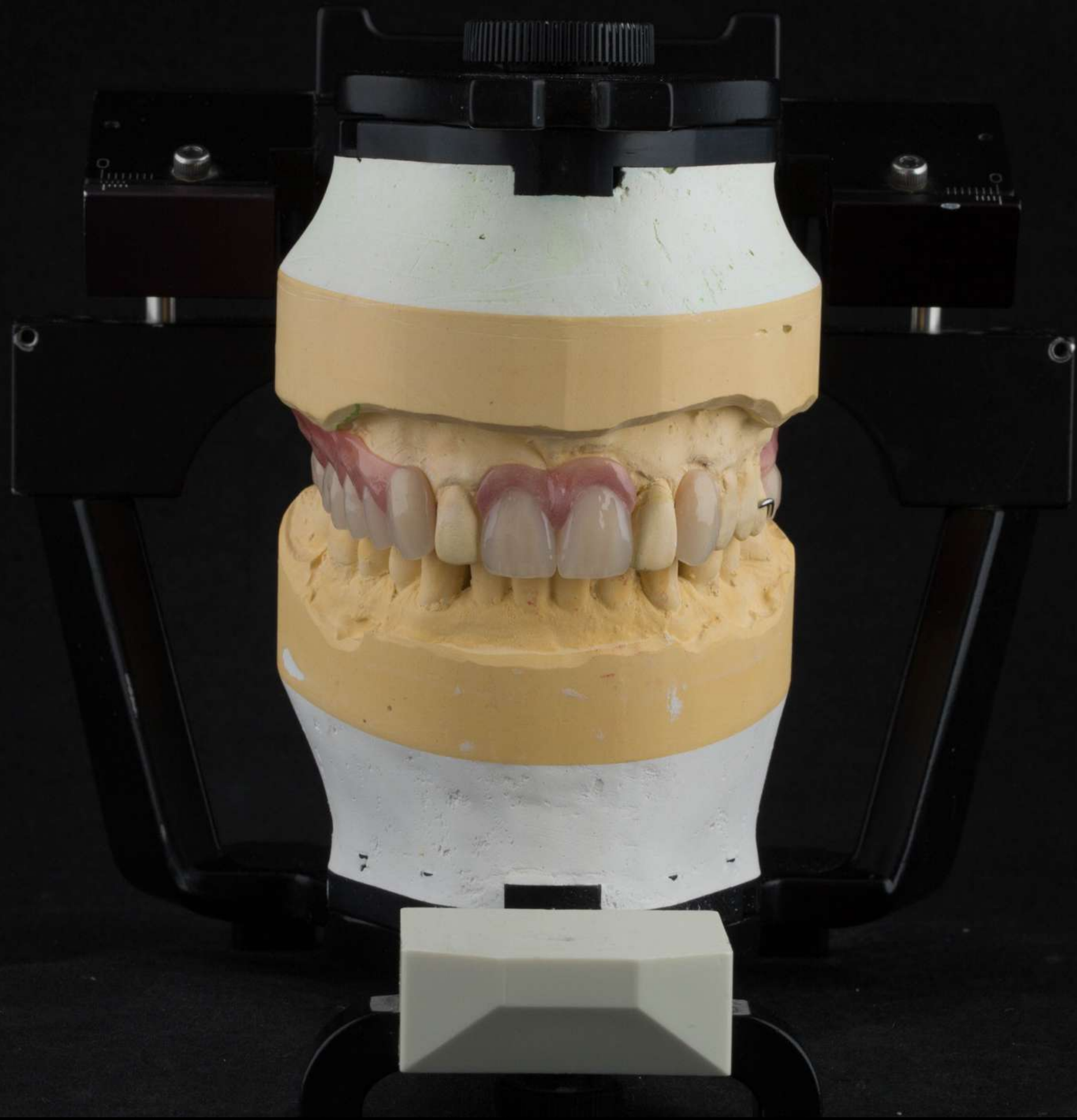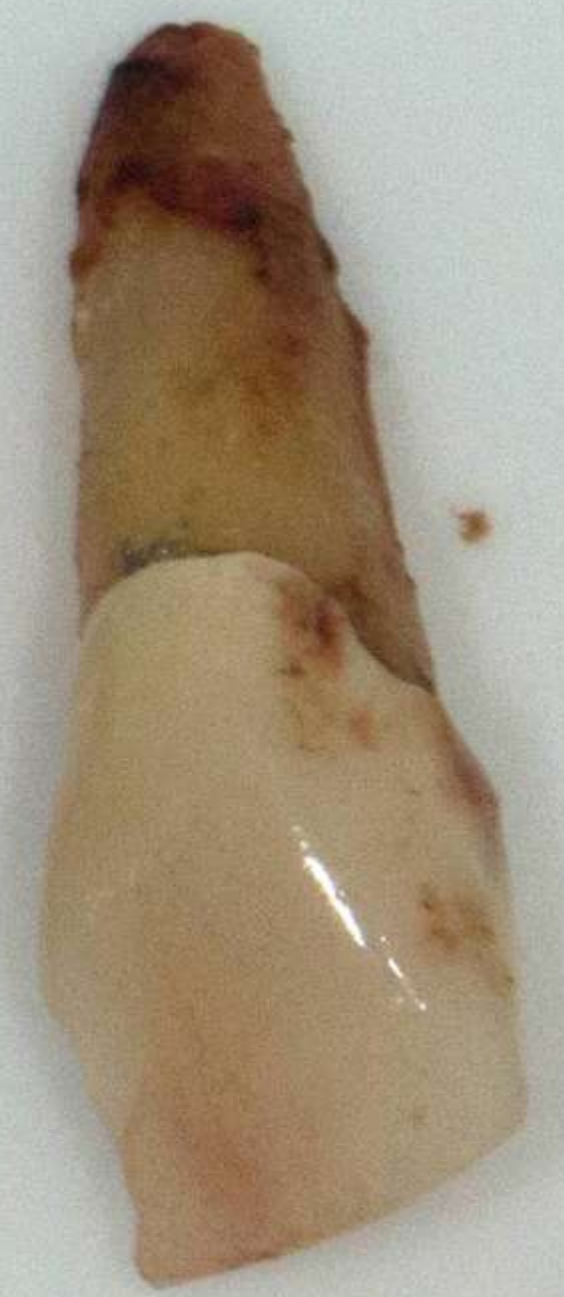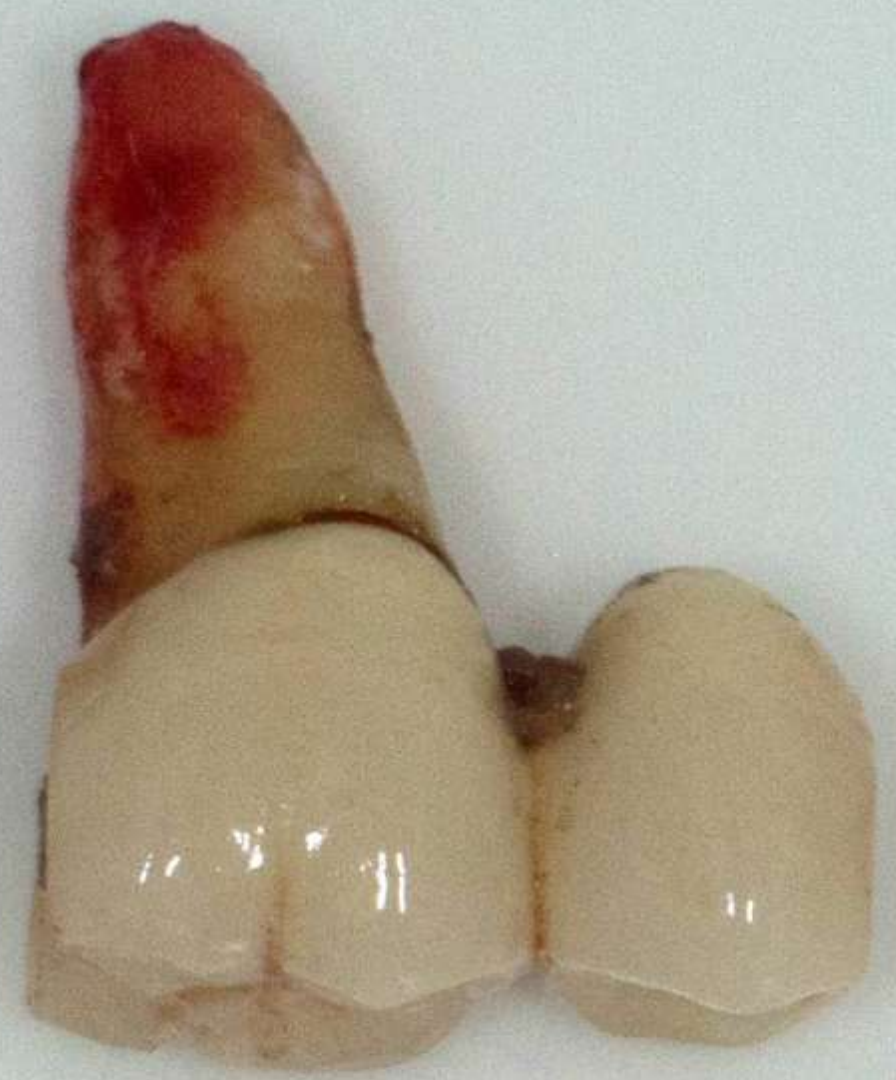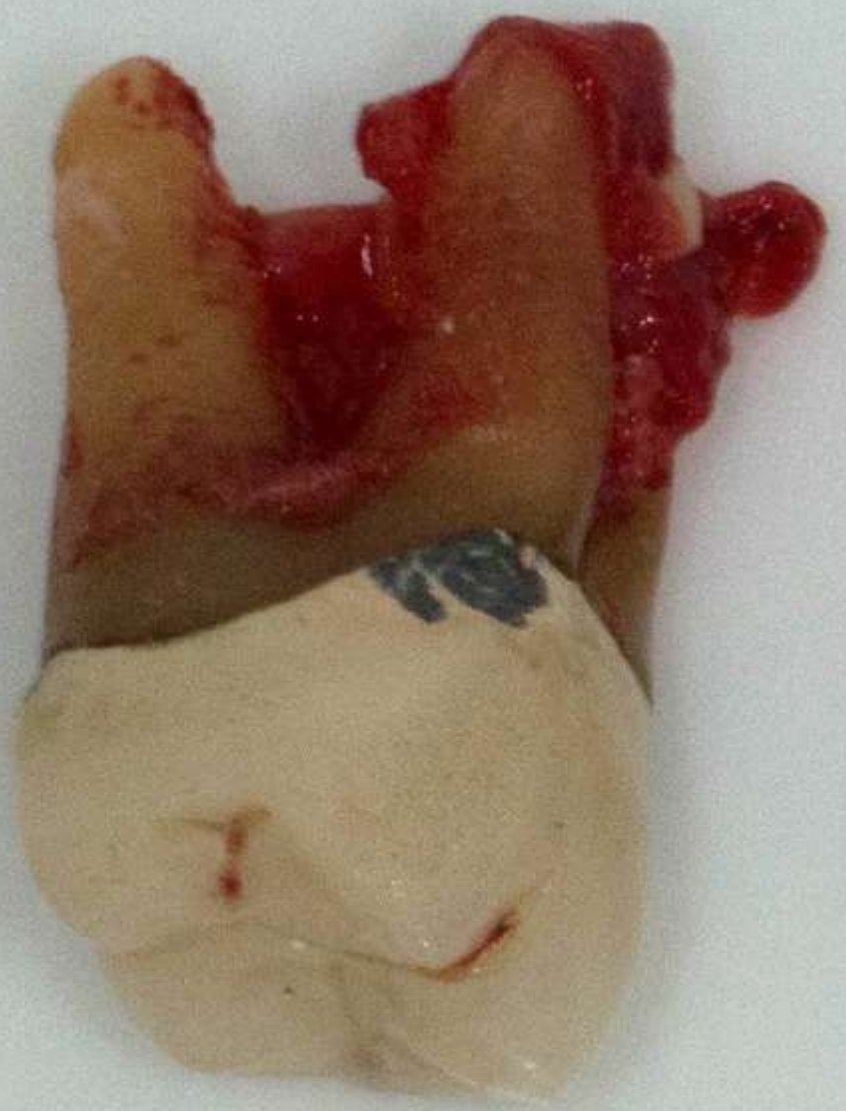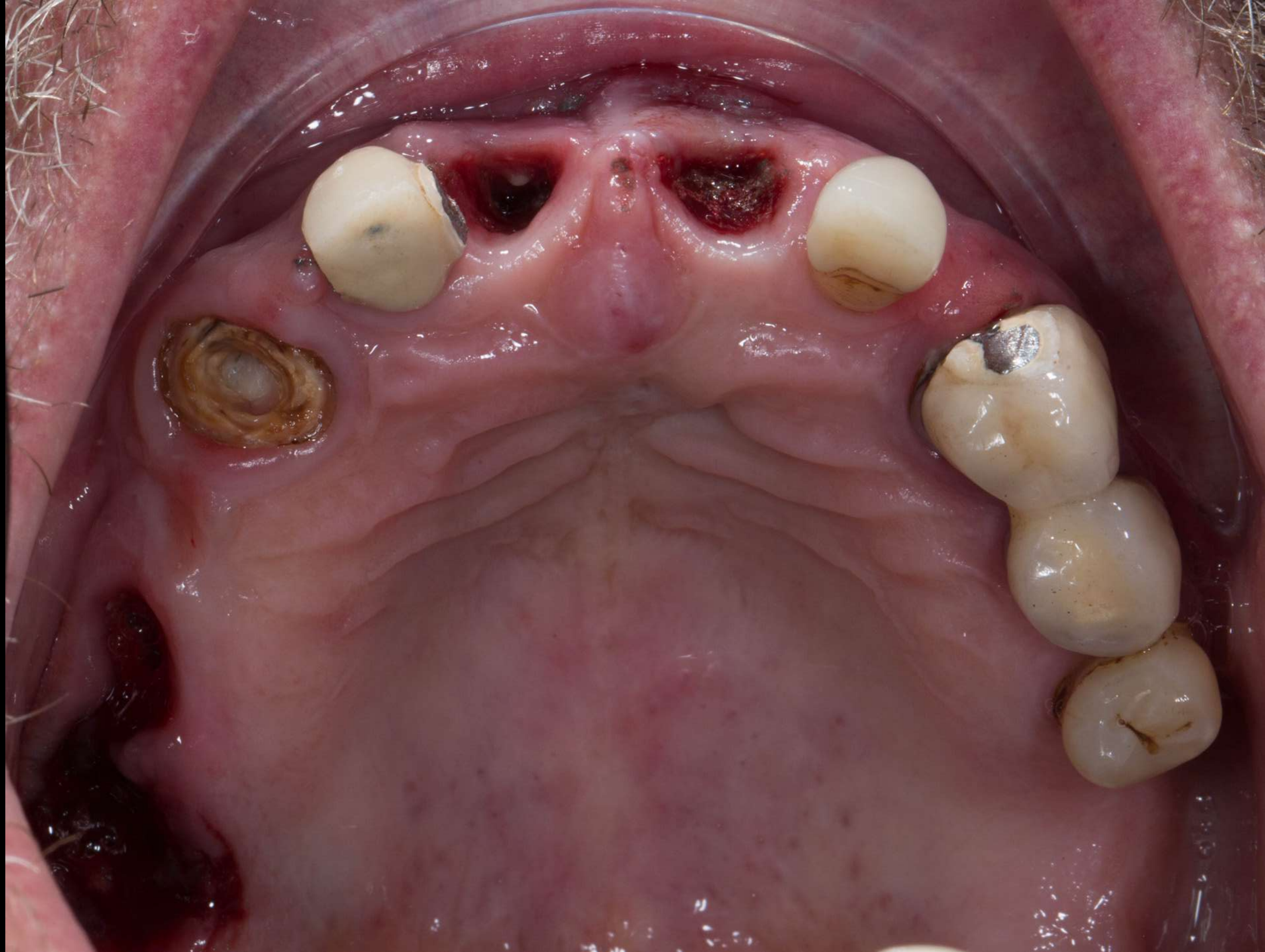




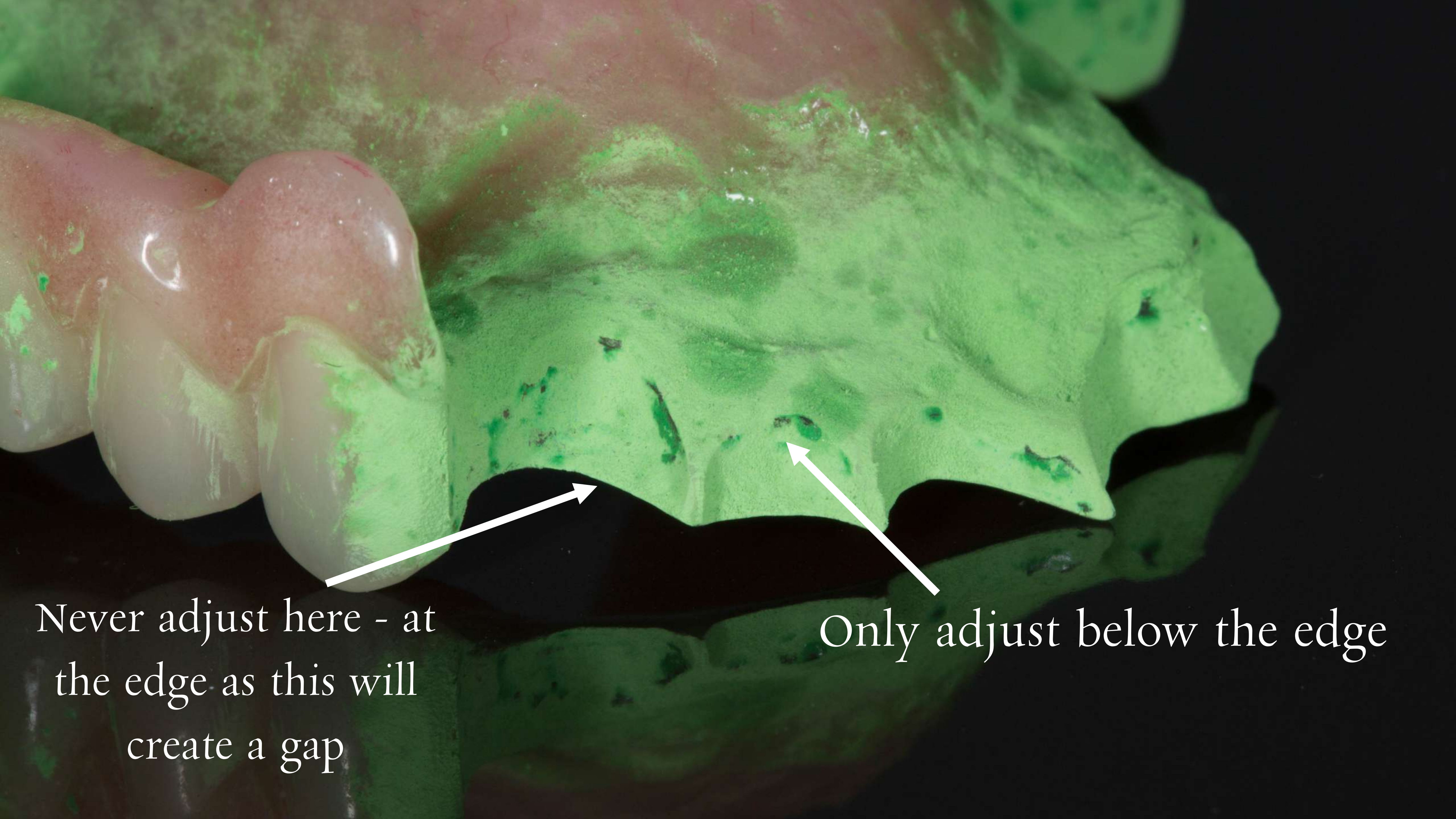










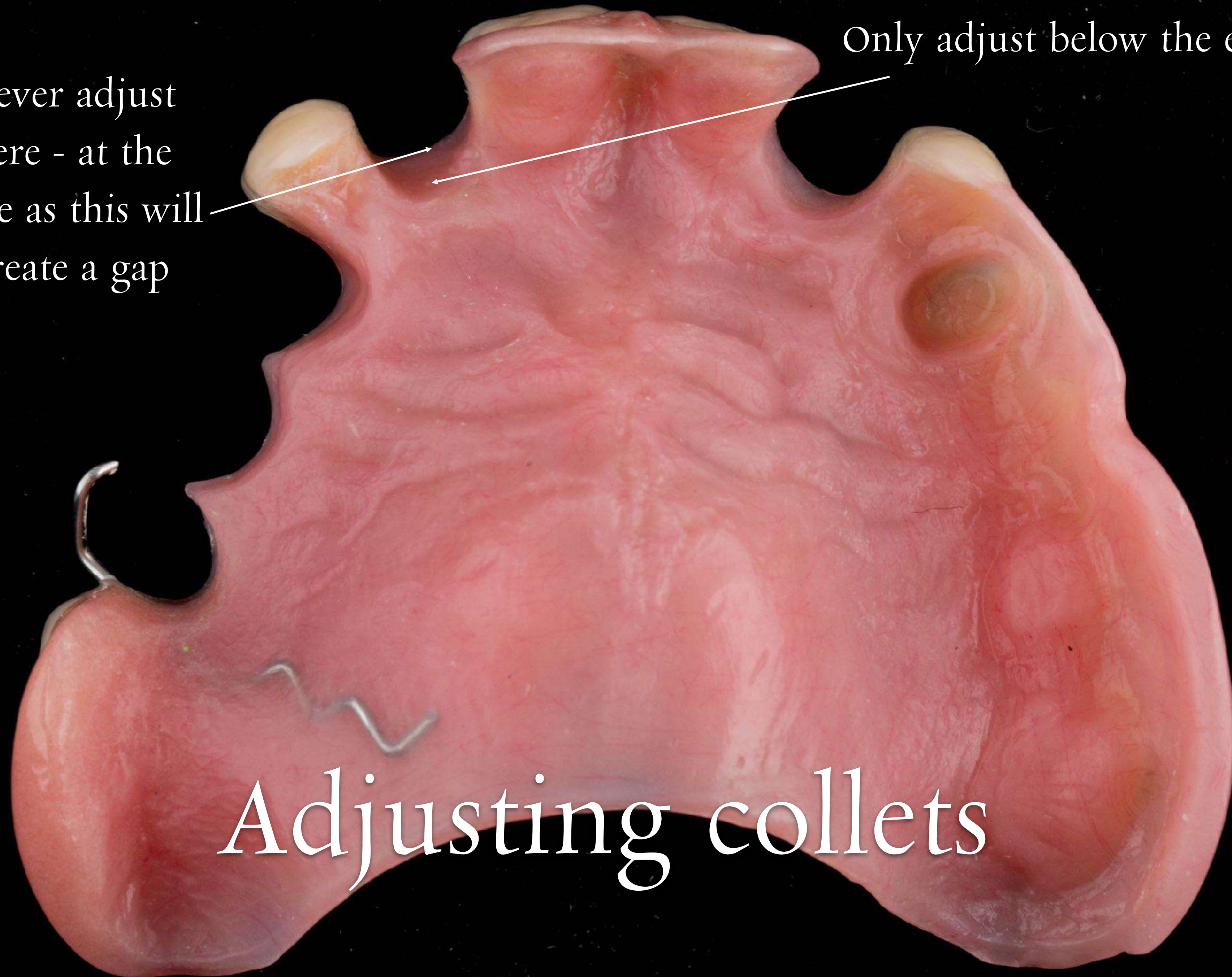


Never adjust here - at the edge as this will create a gap

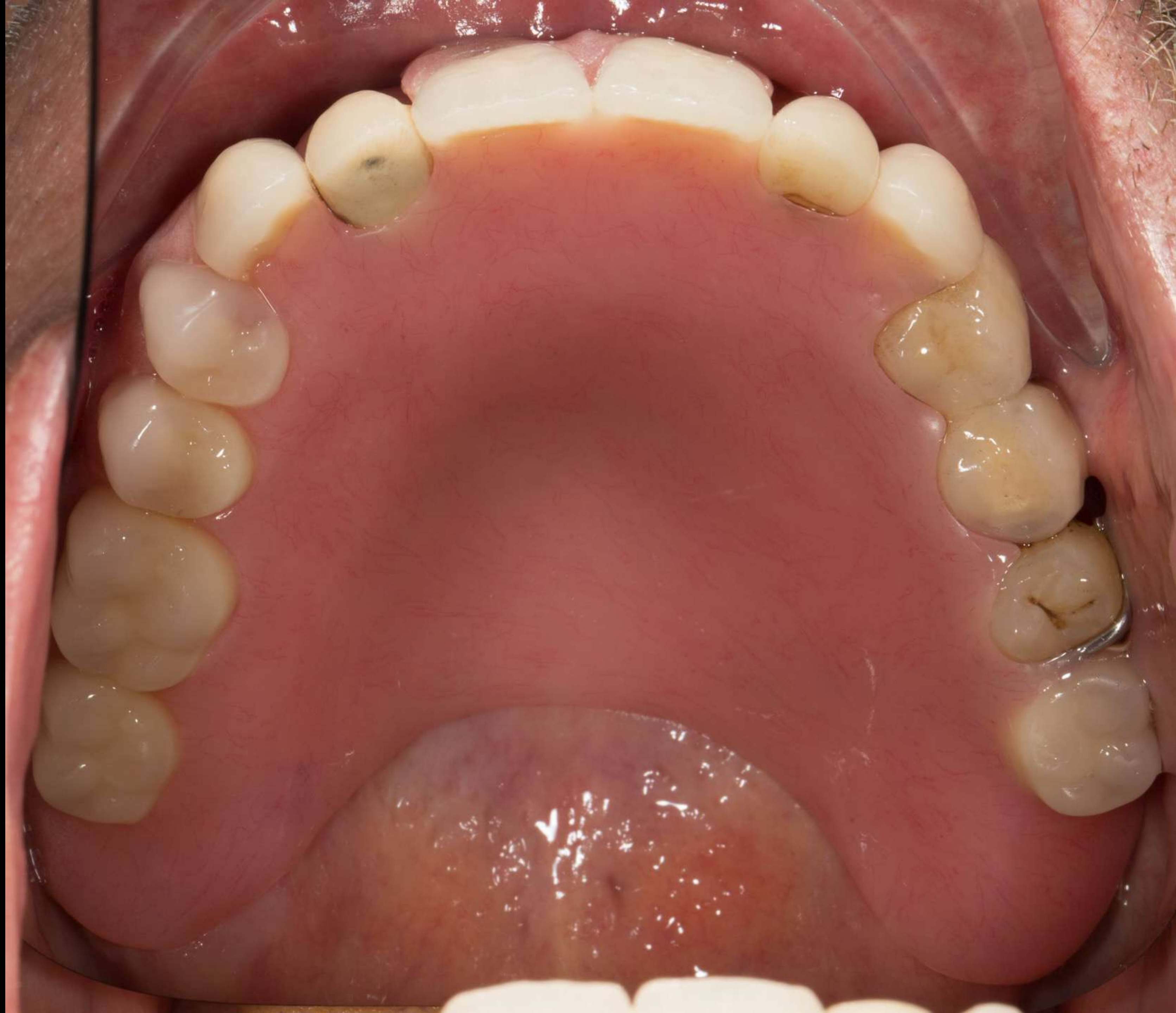Only adjust below the edge

Never adjust  
here - at the  
edge as this will  
create a gap

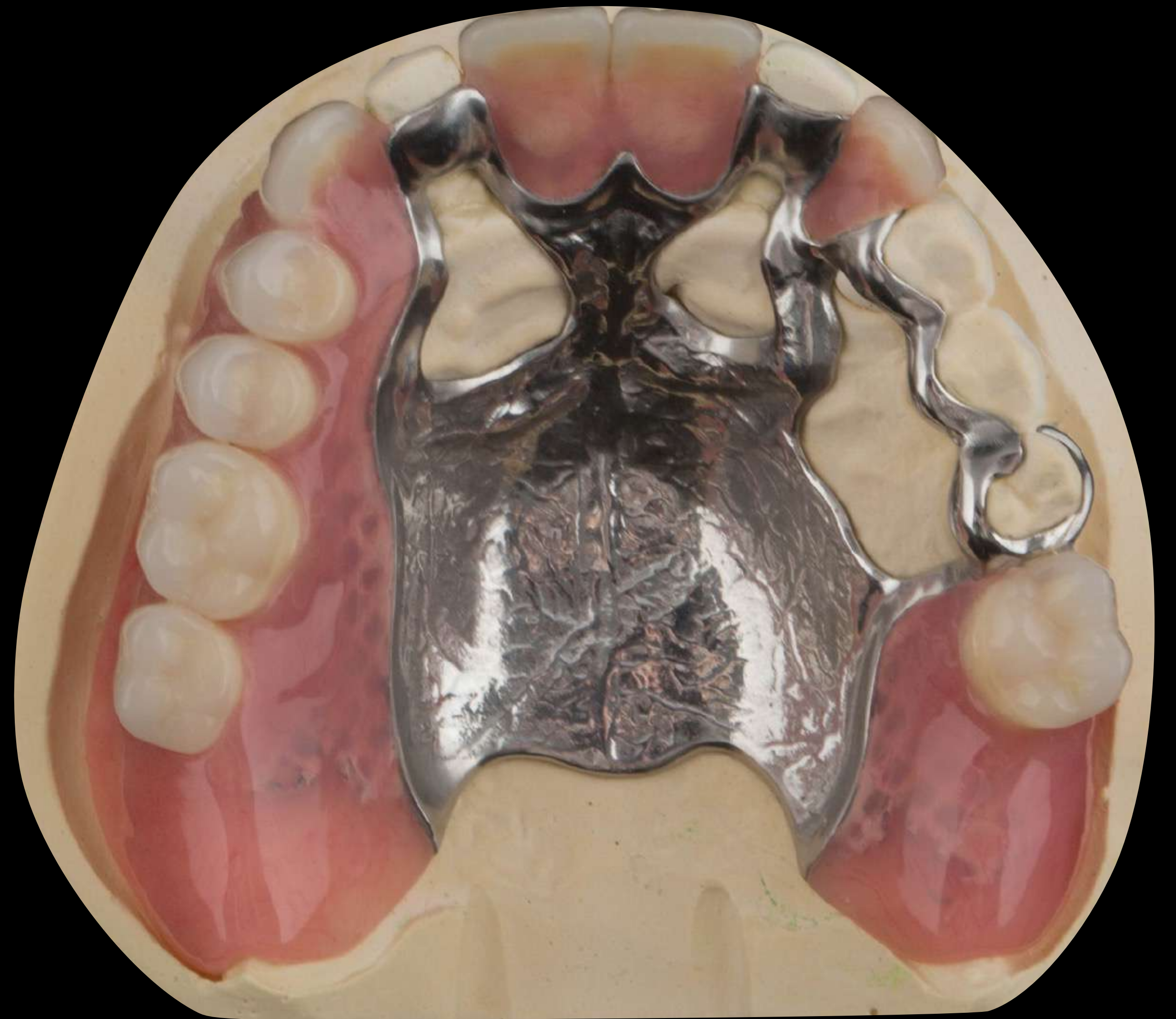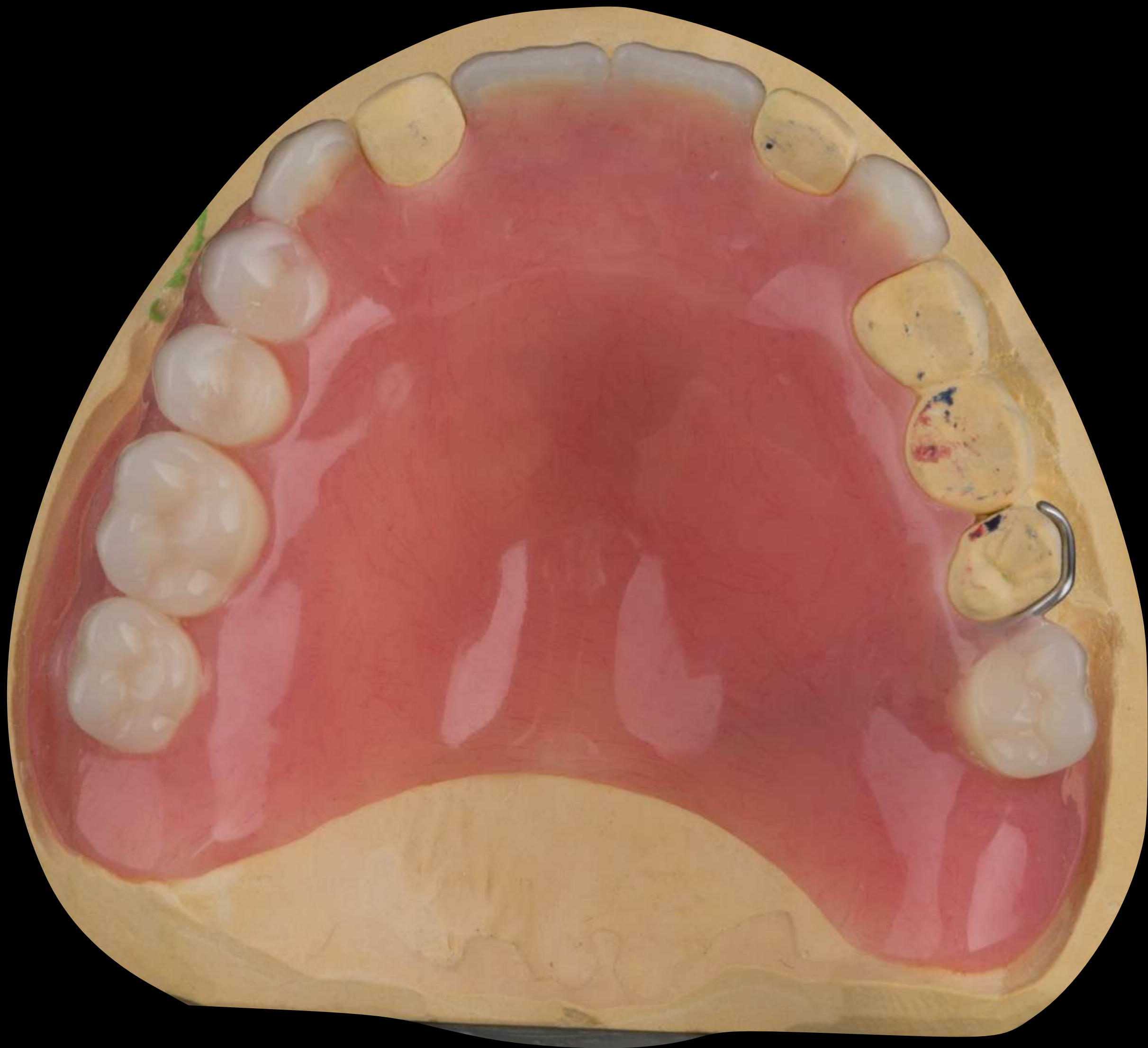Only adjust below the edge

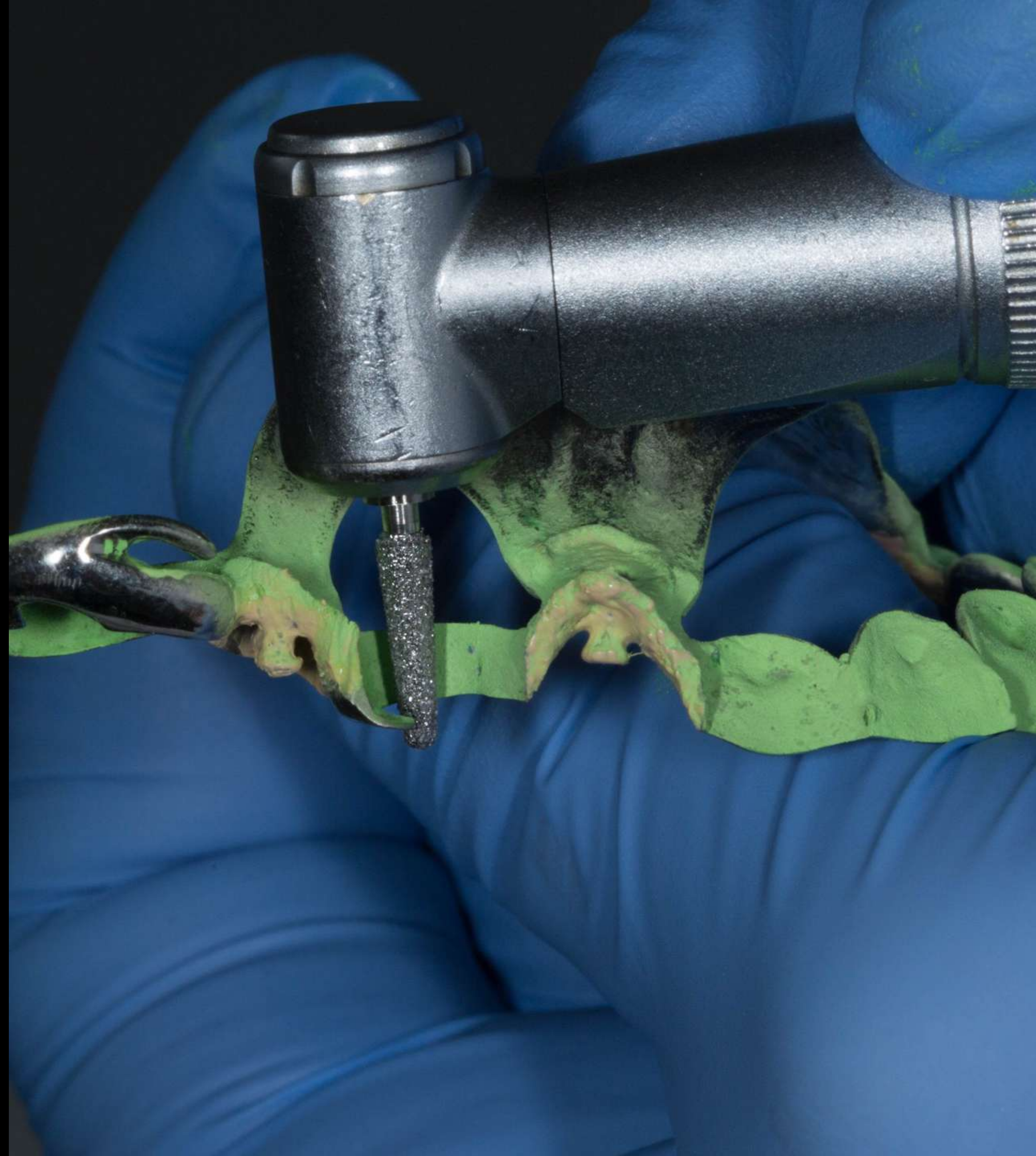
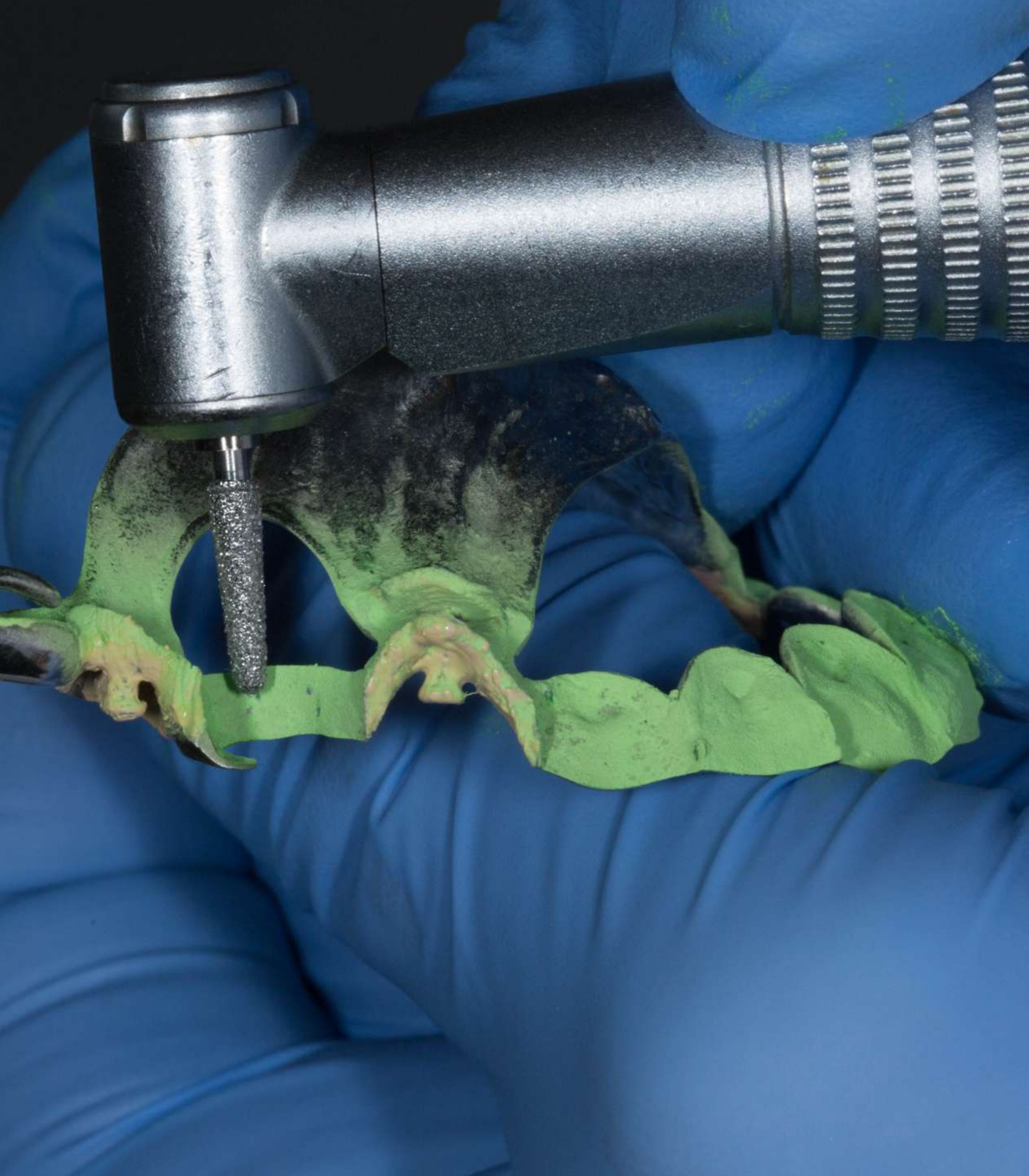
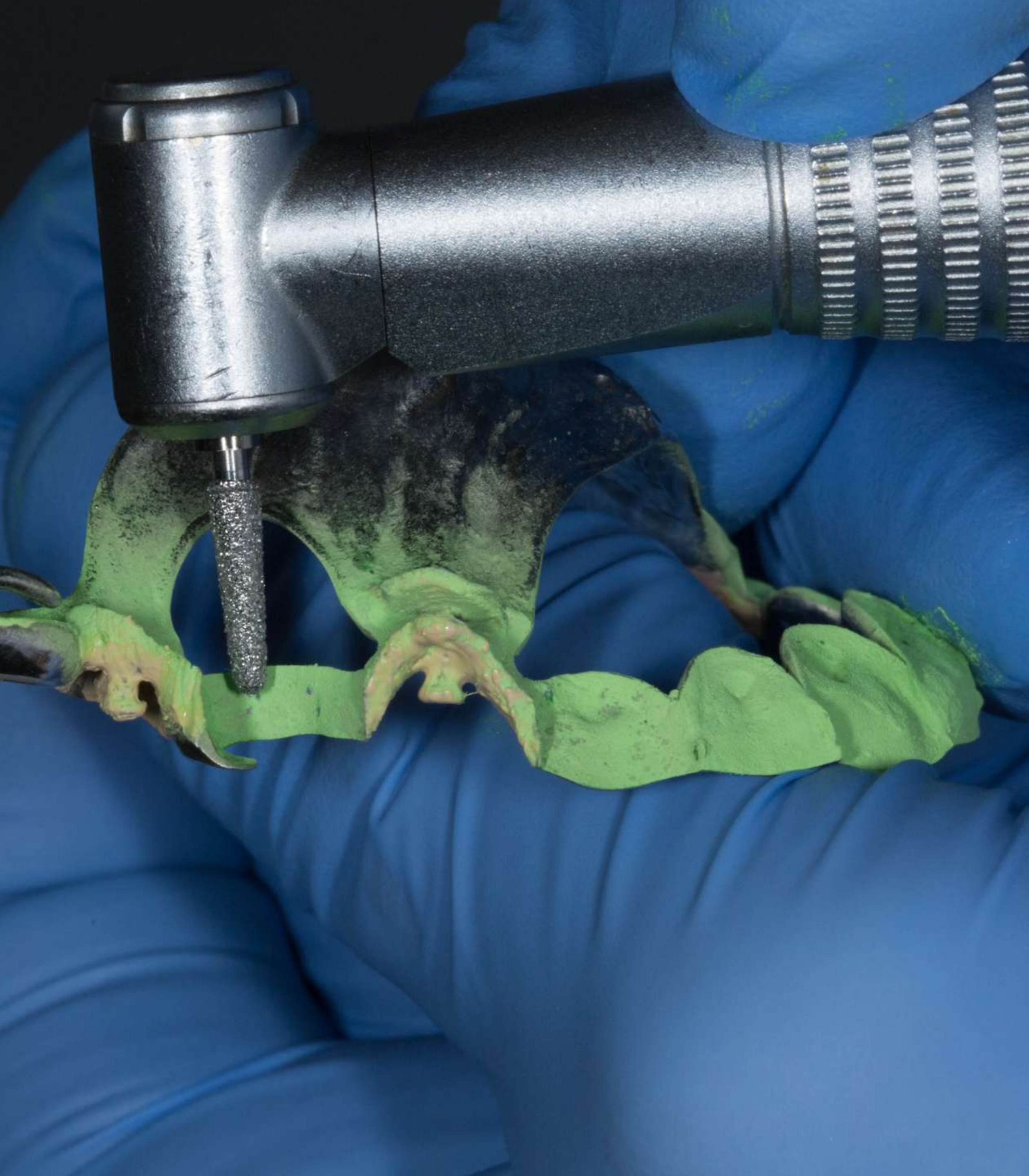
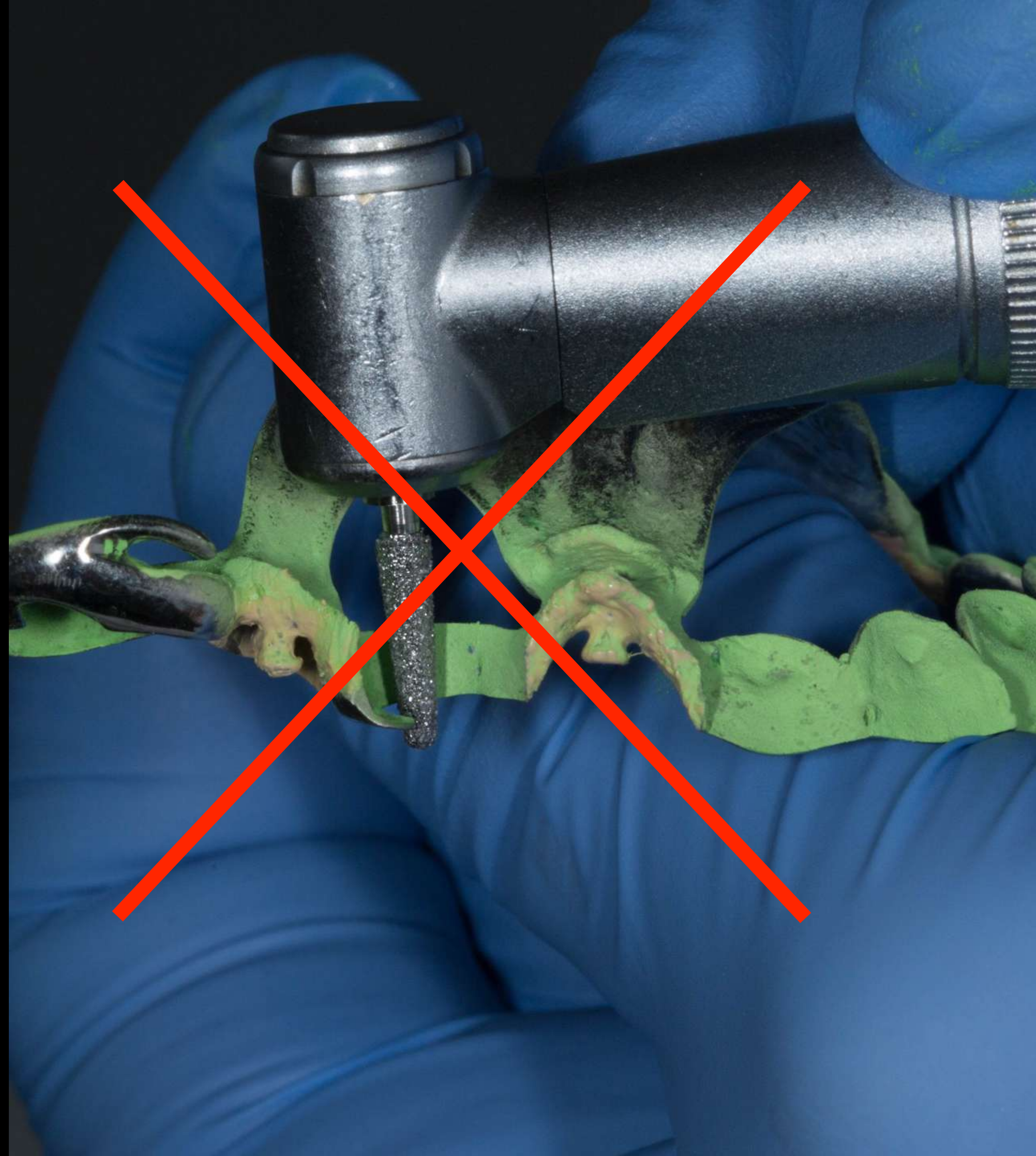Adjusting collets

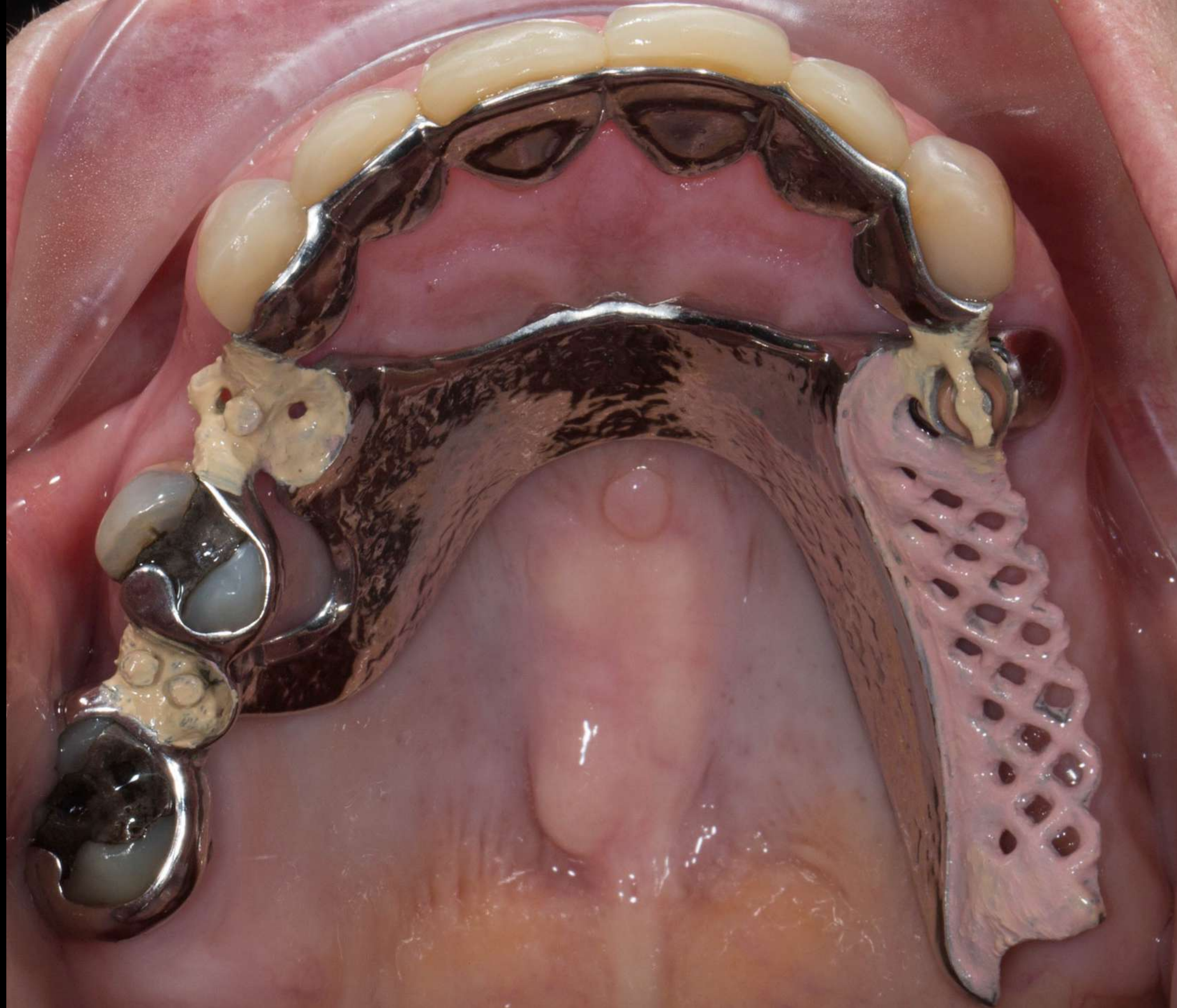




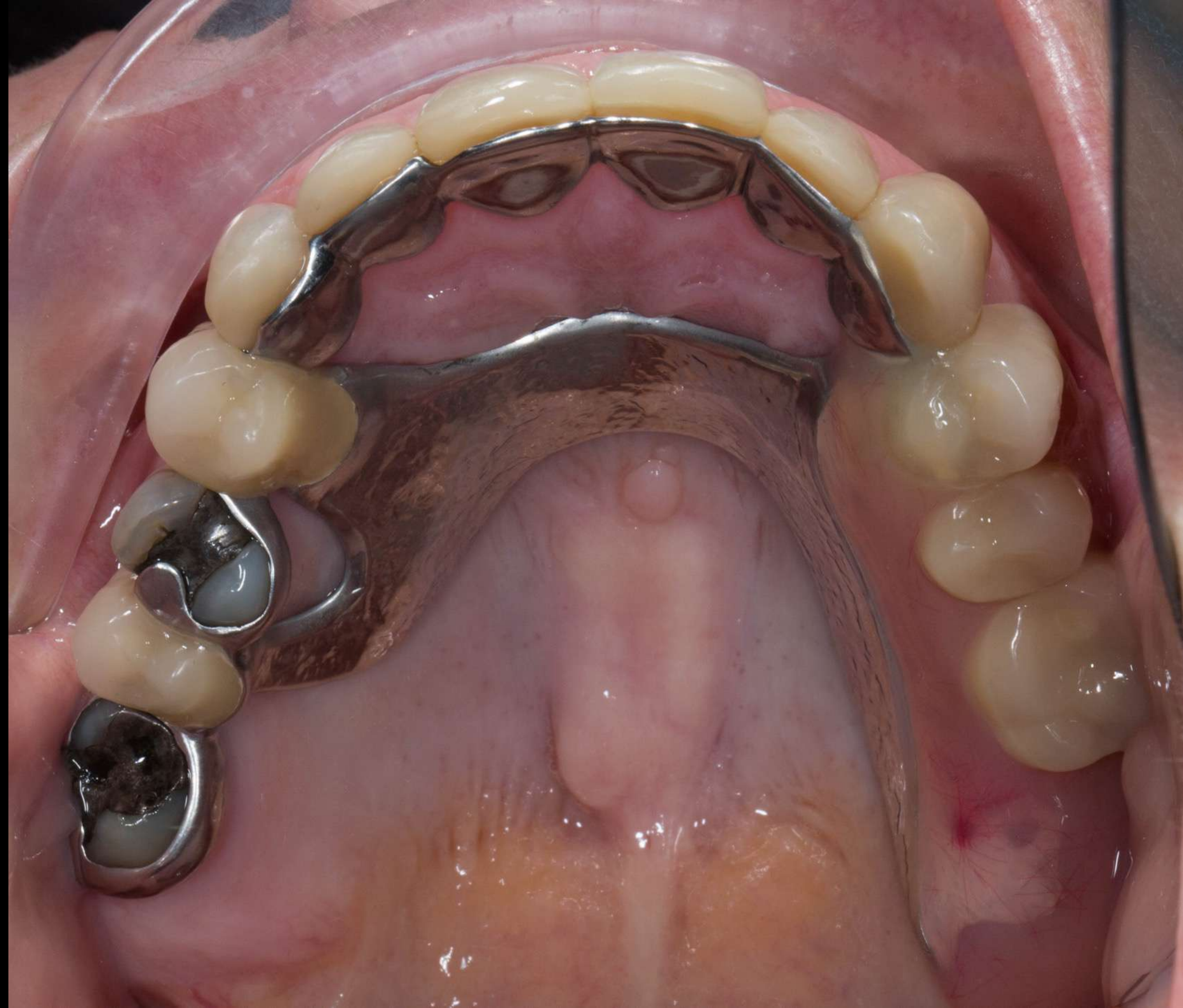


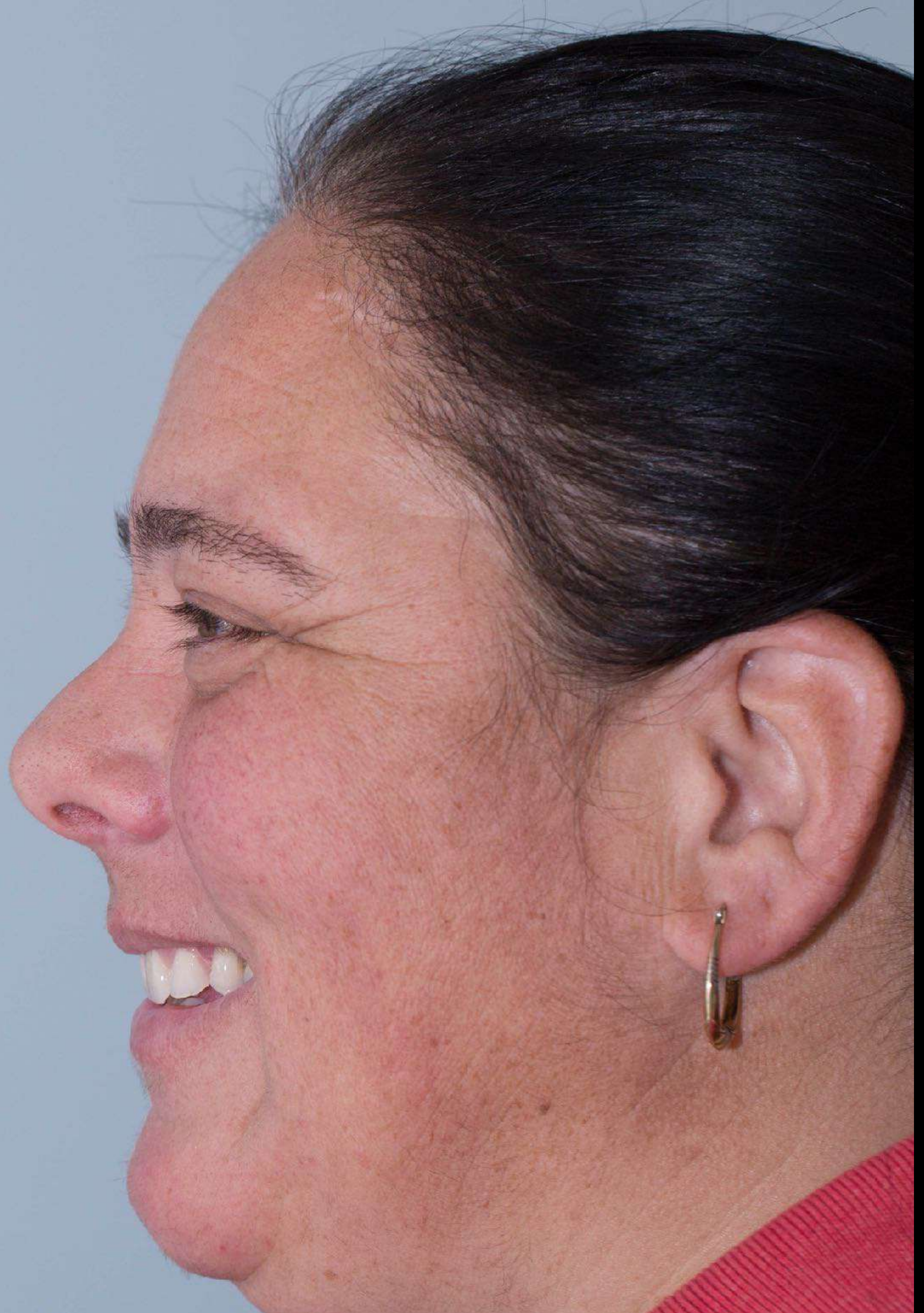
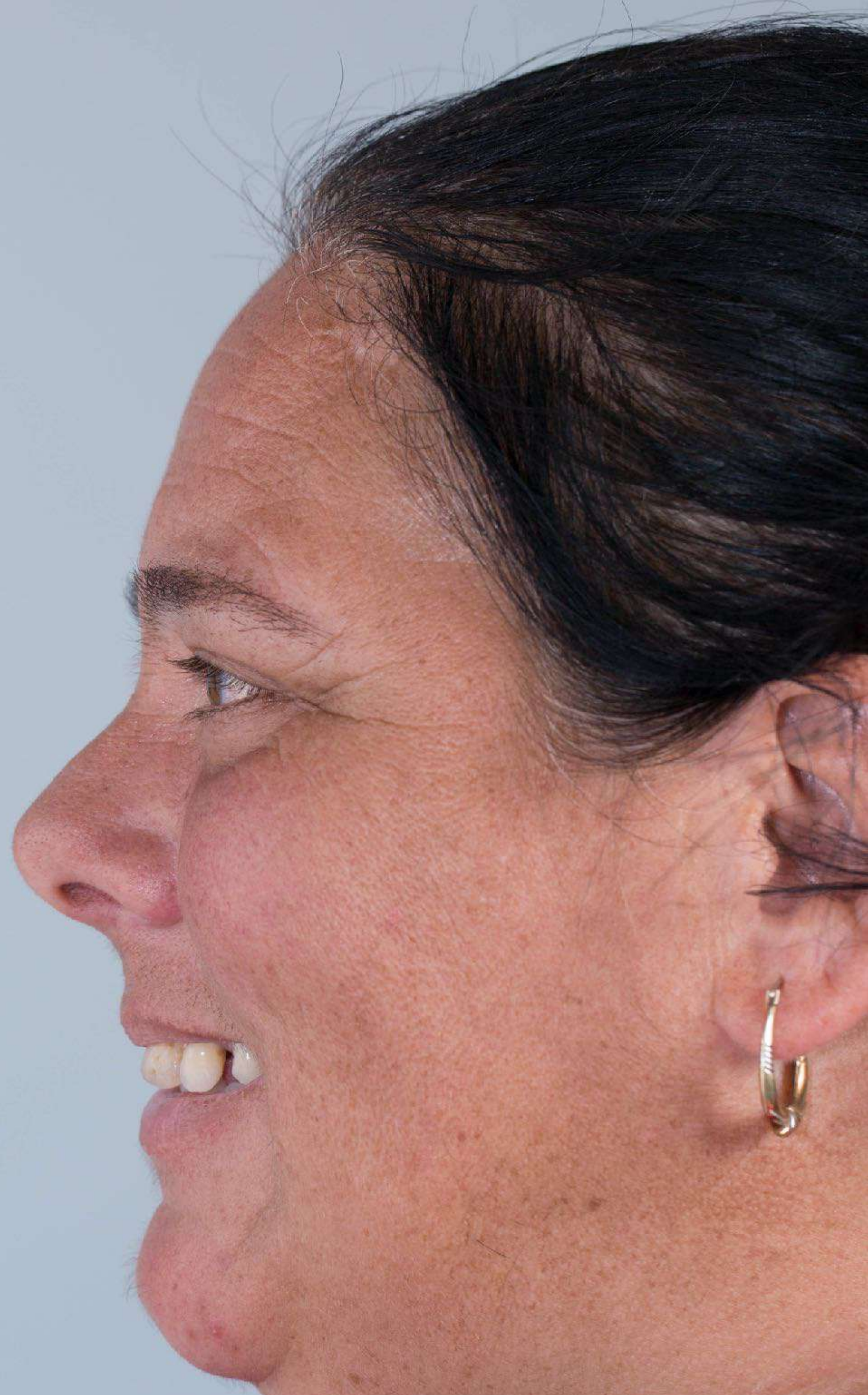




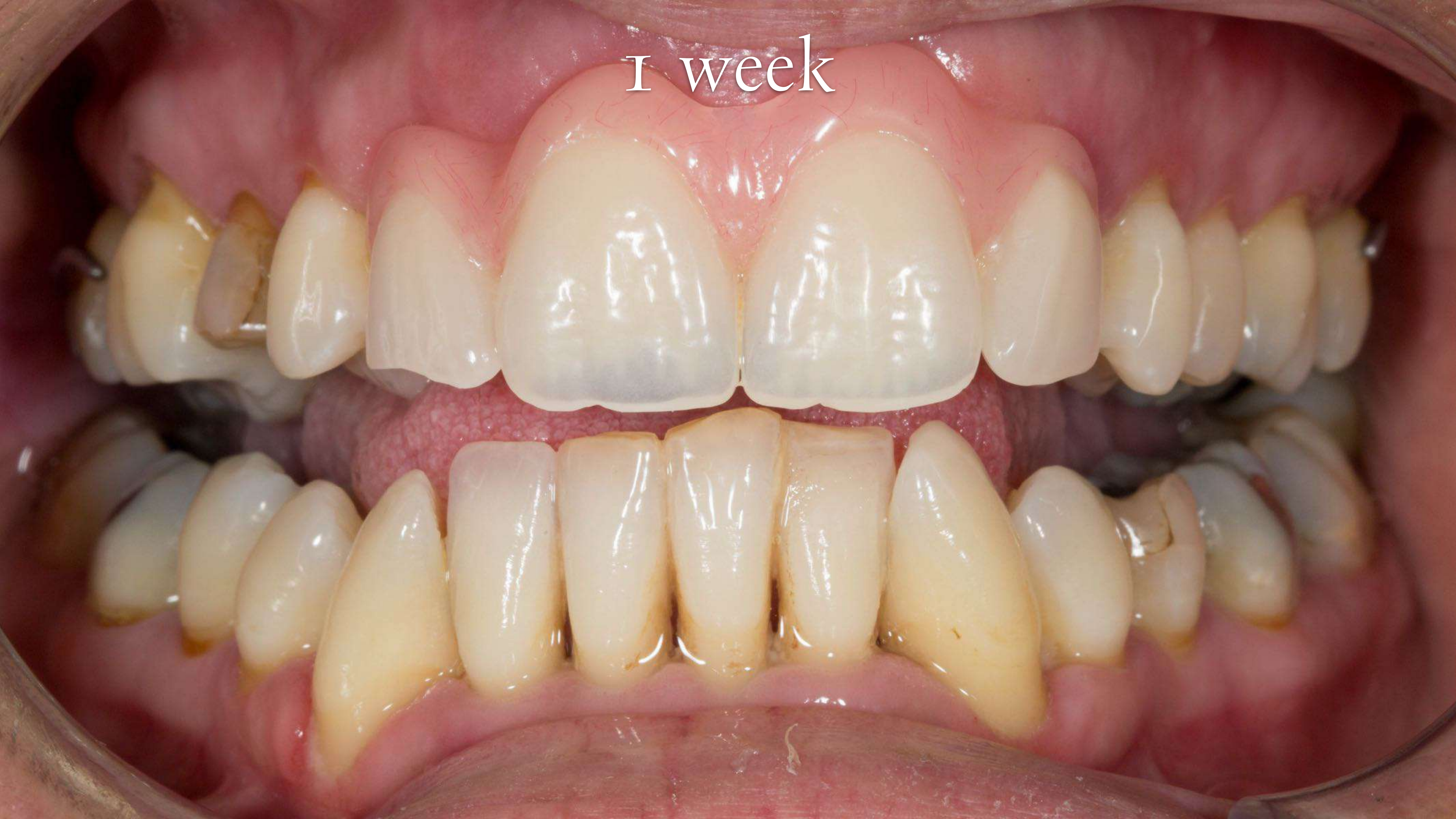



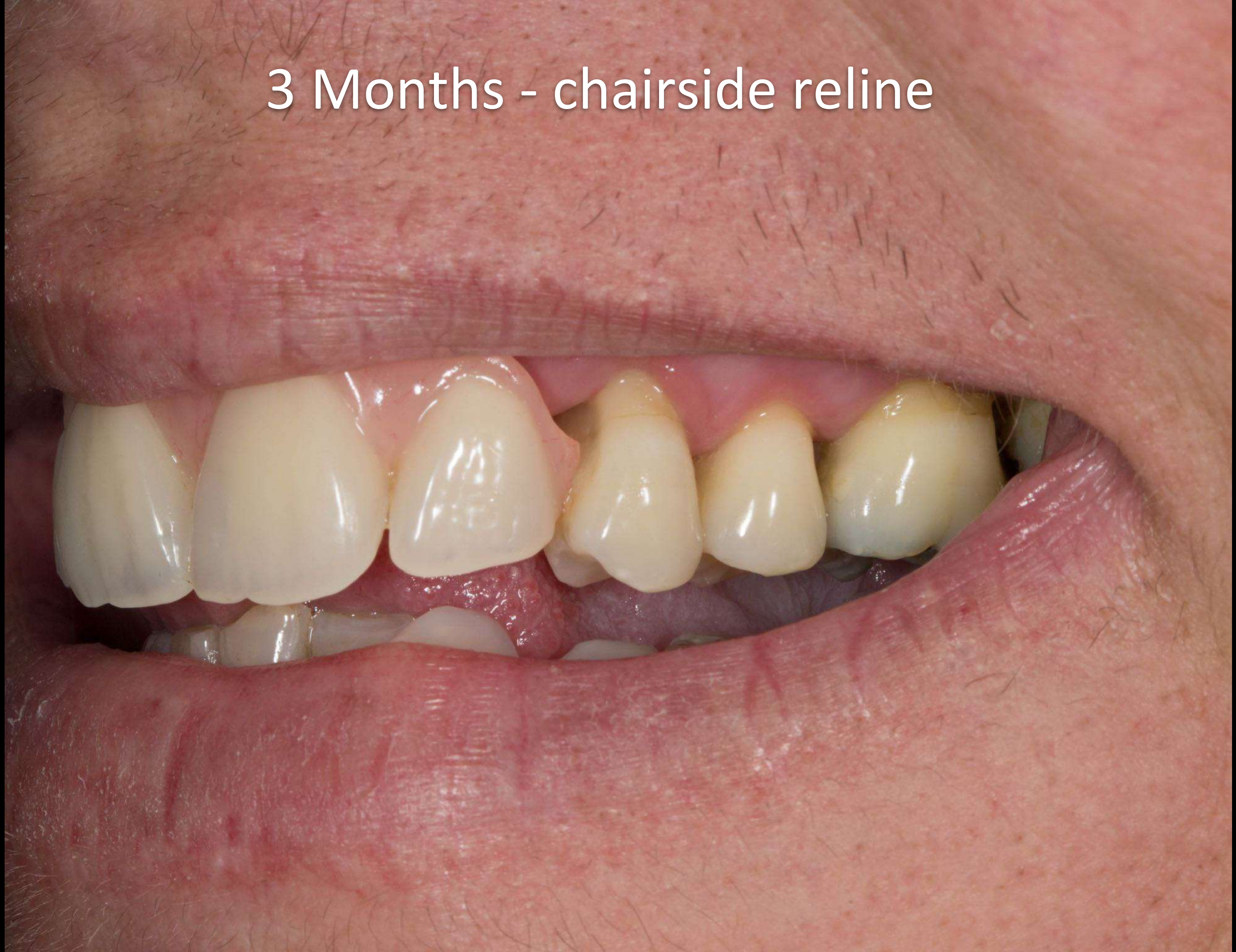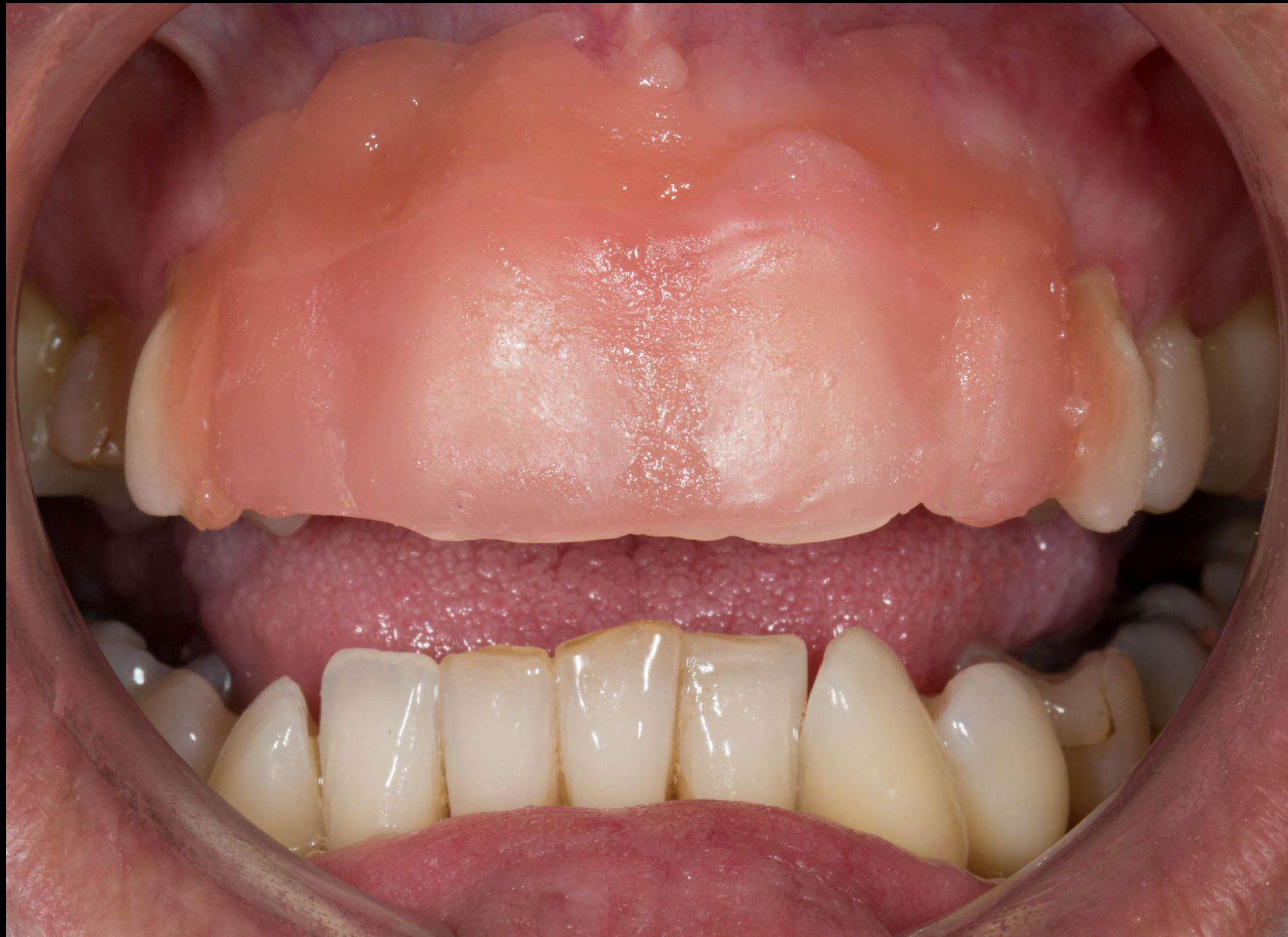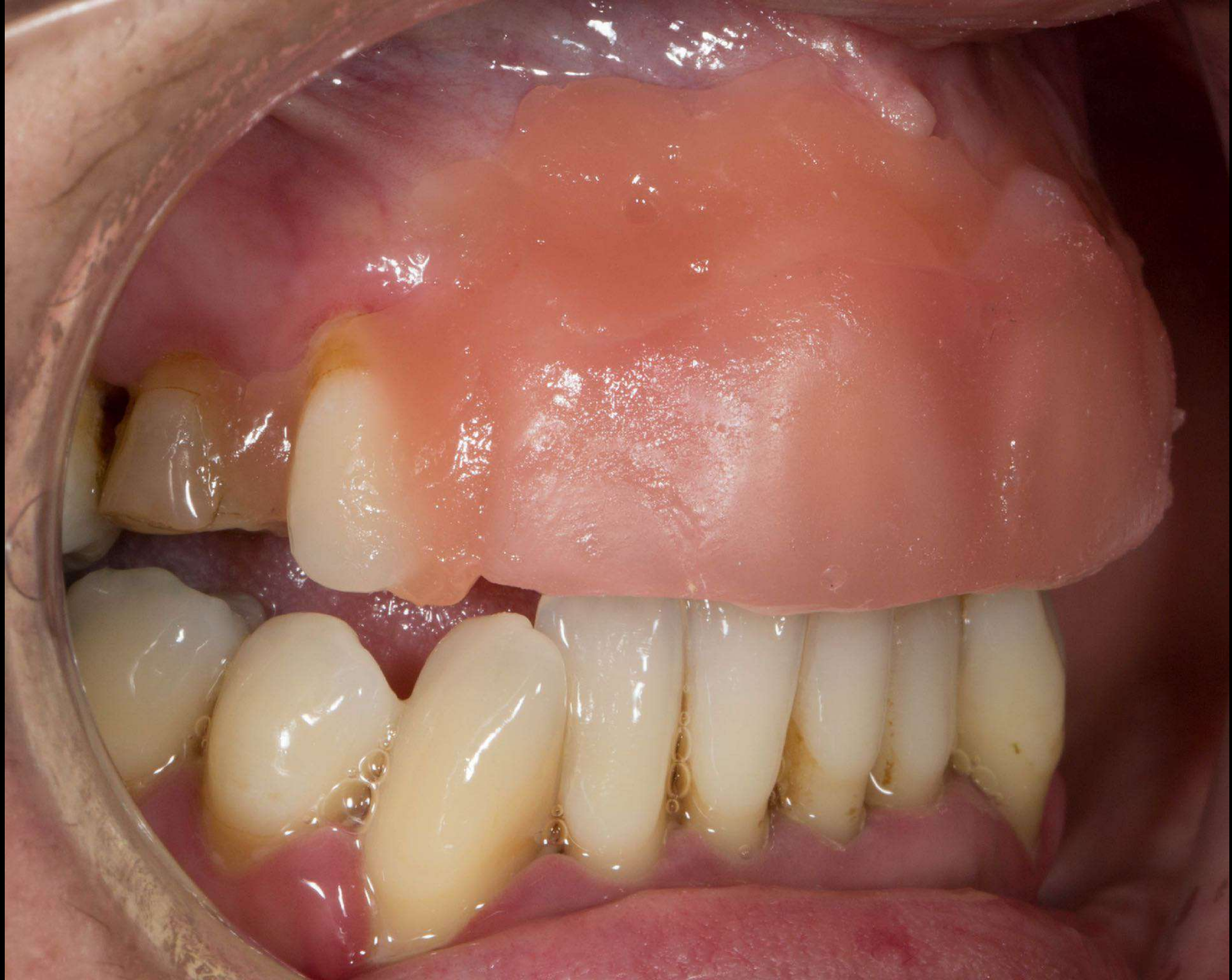1 week

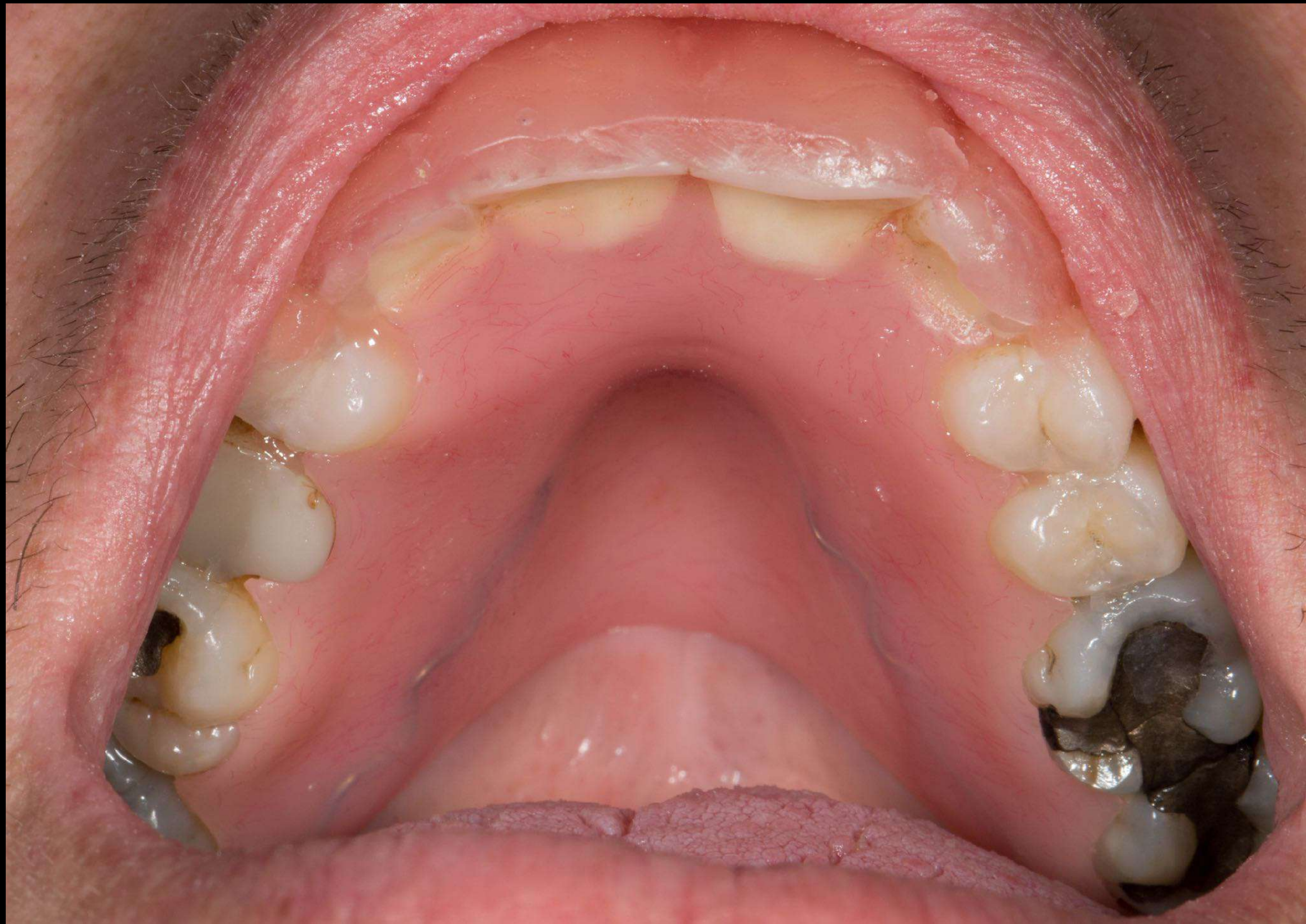

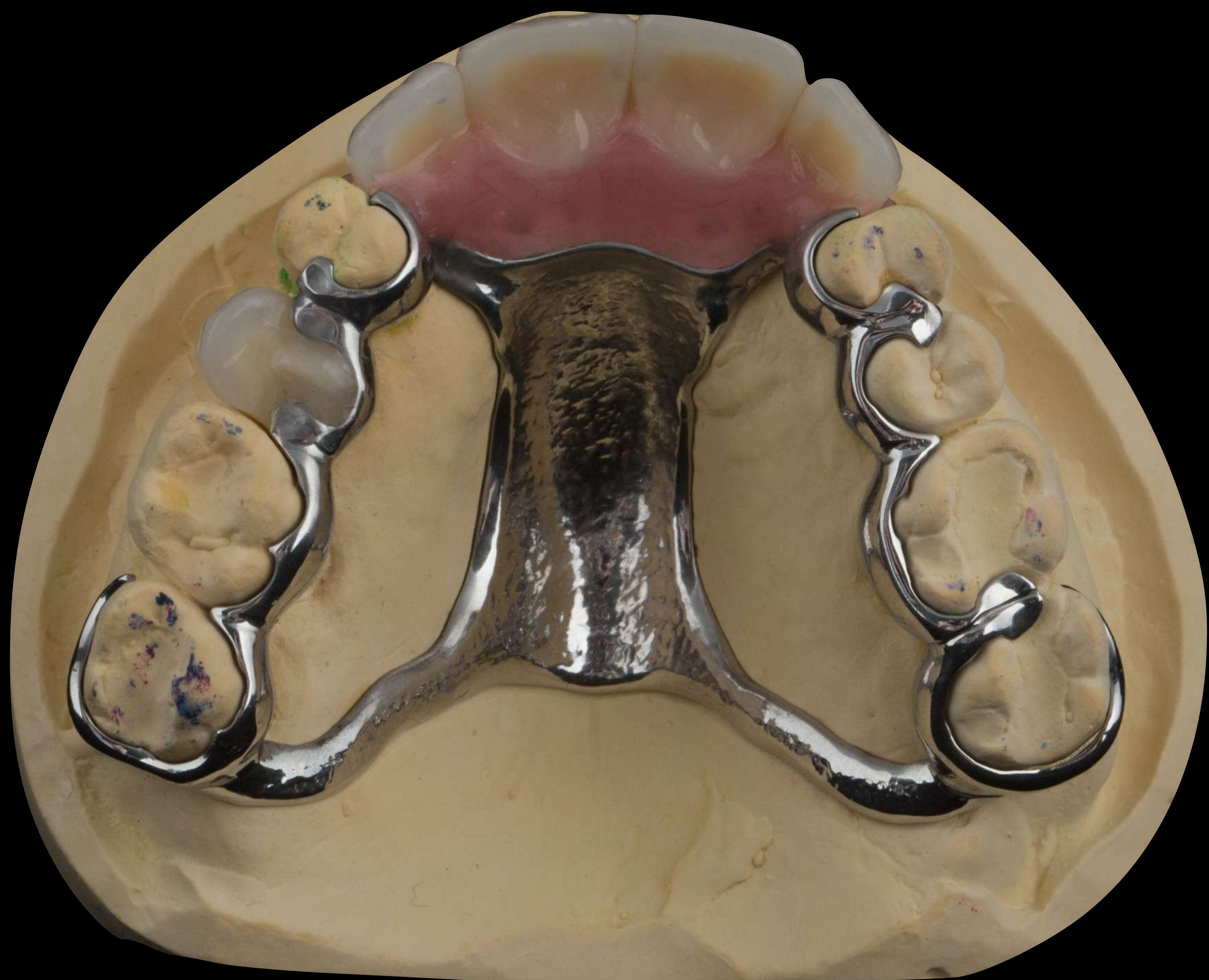
3 Months - chairside reline



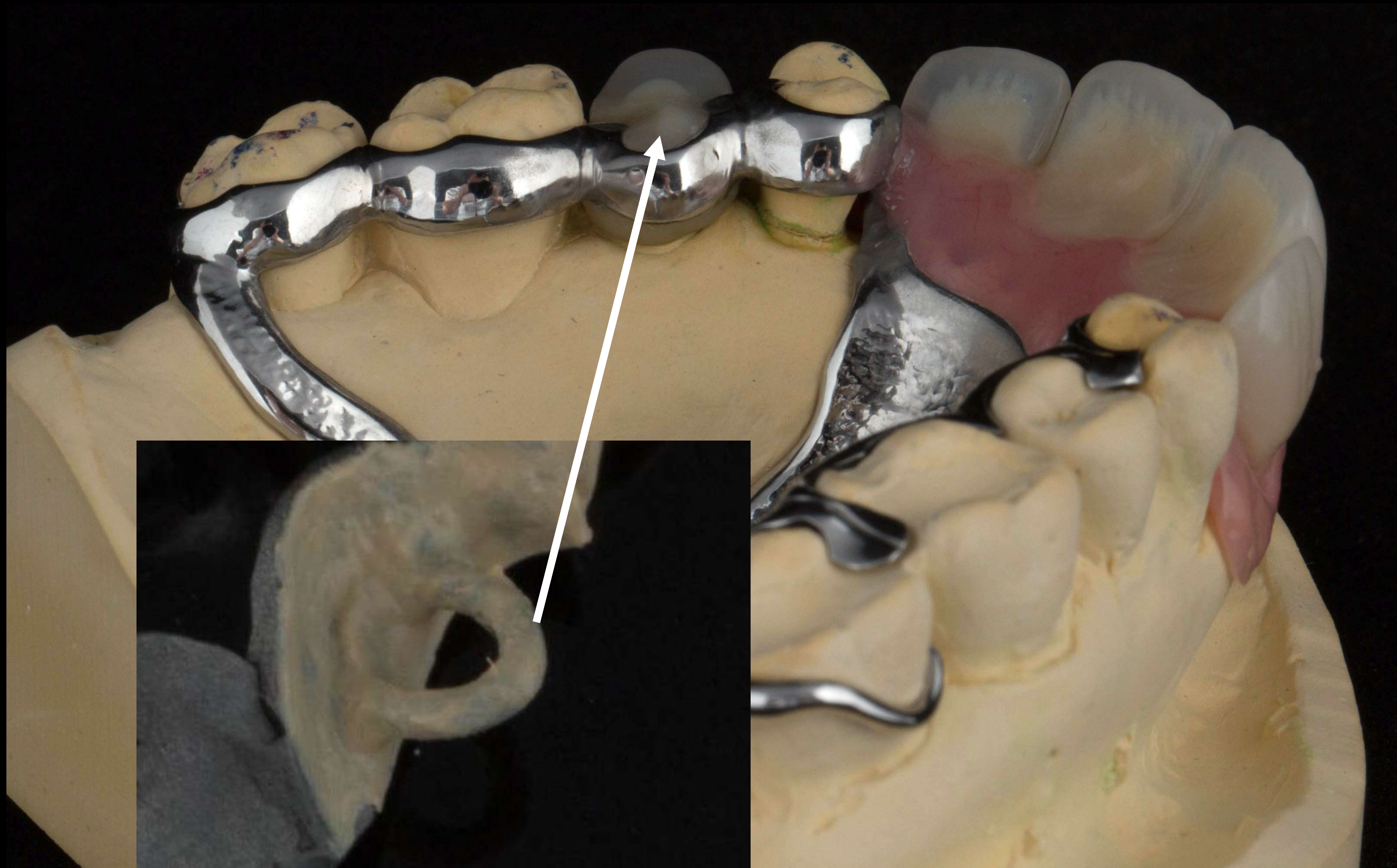


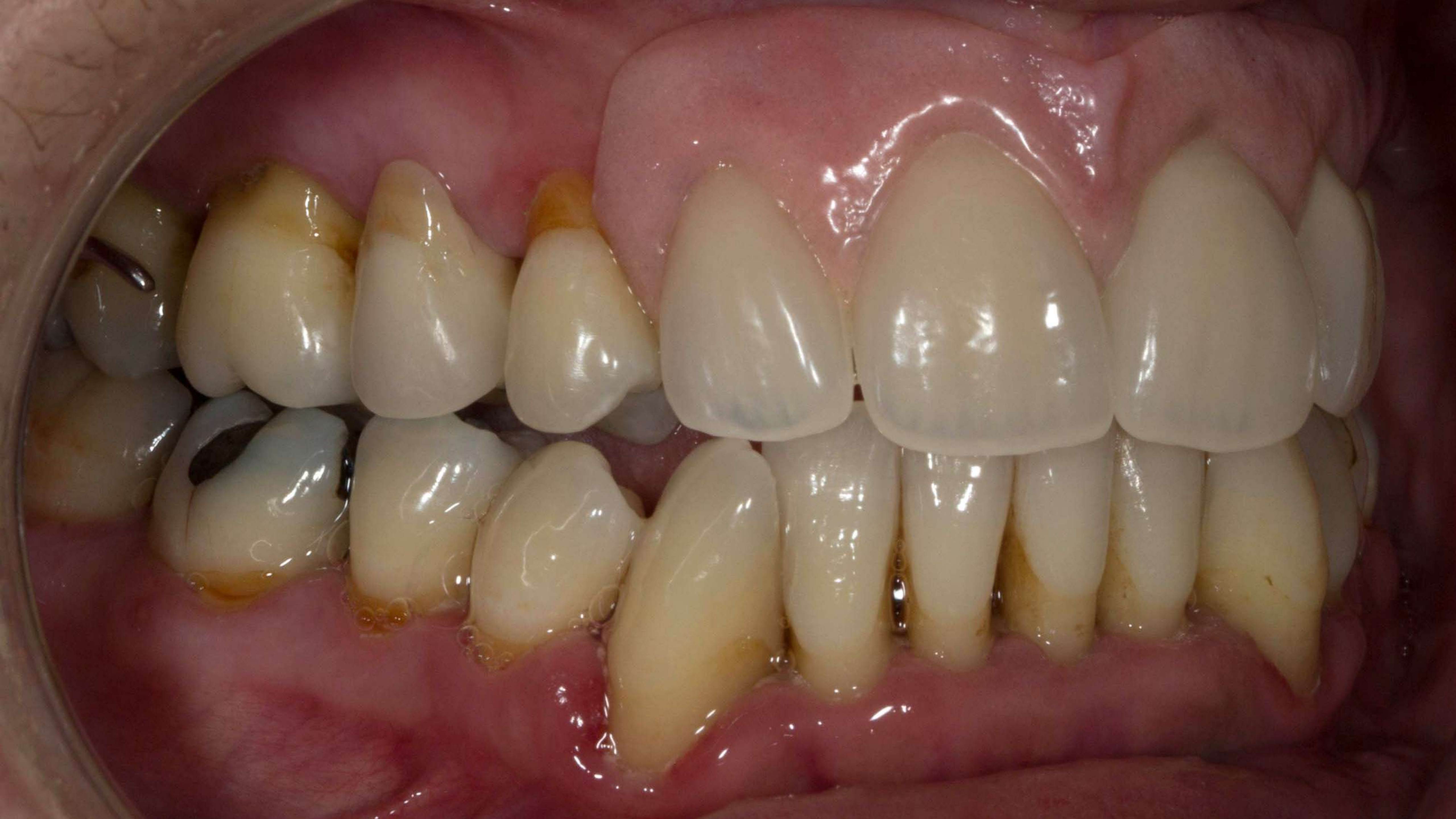


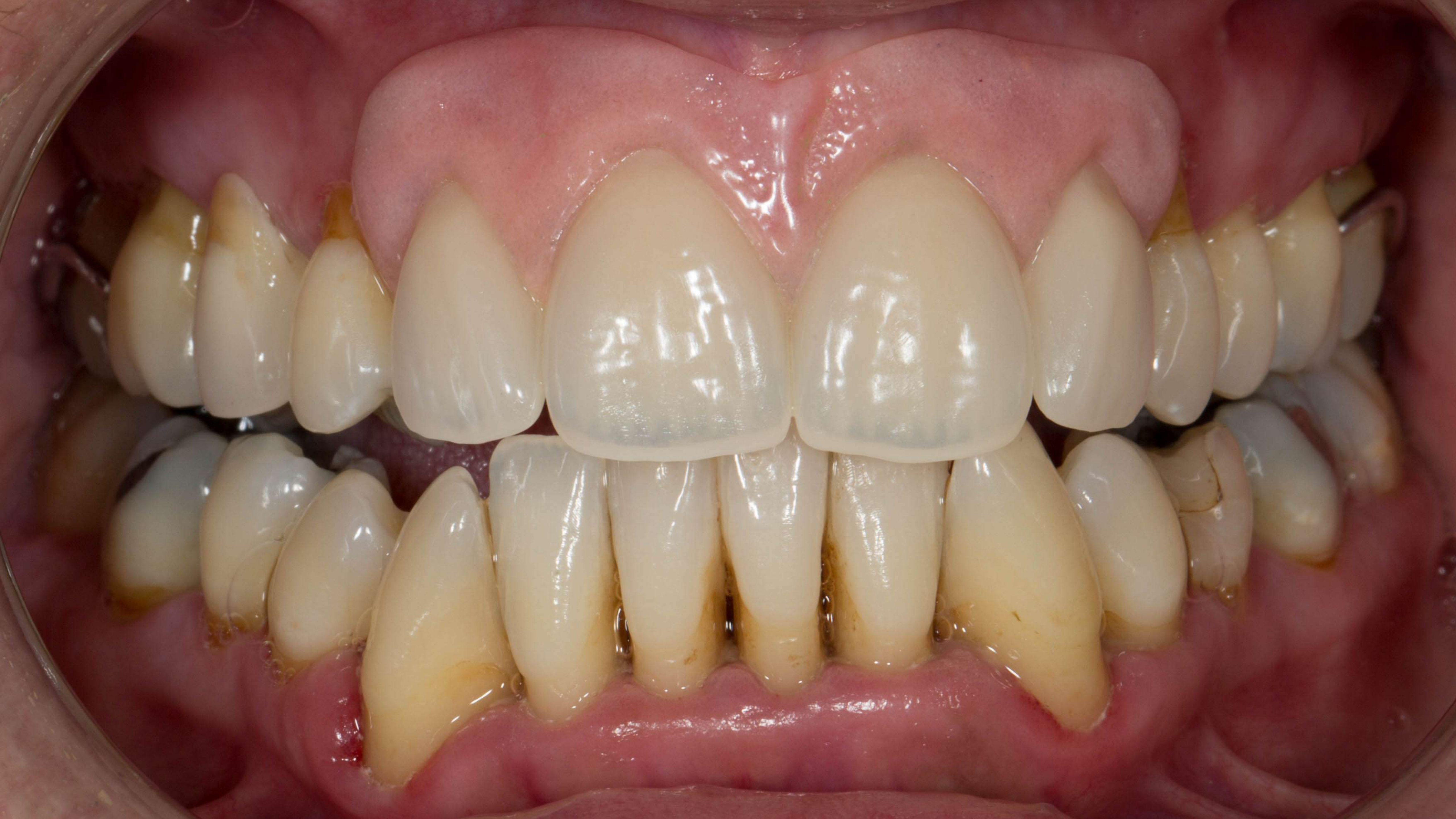


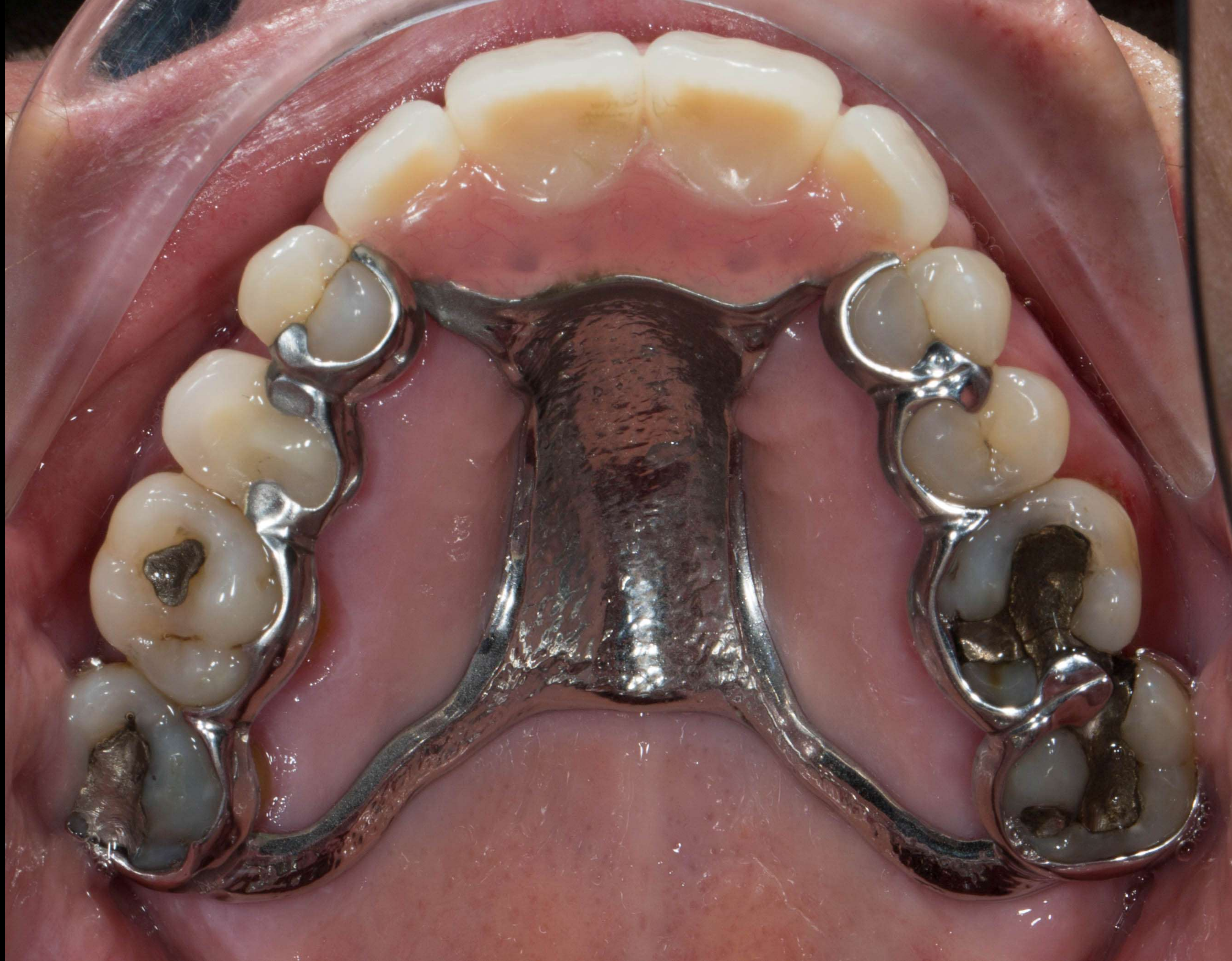













THANK YOU

To

Dr Sutton + Claire

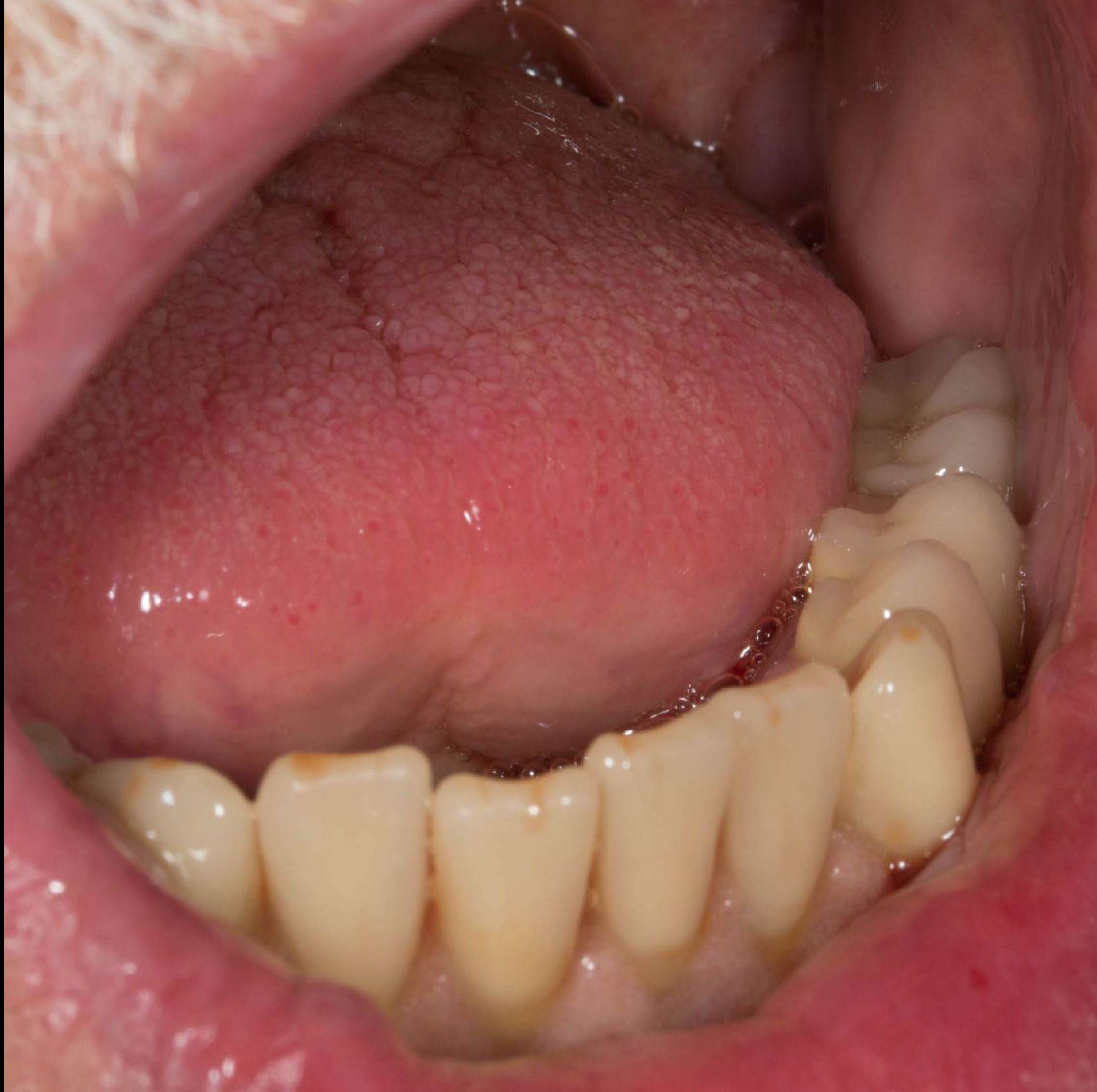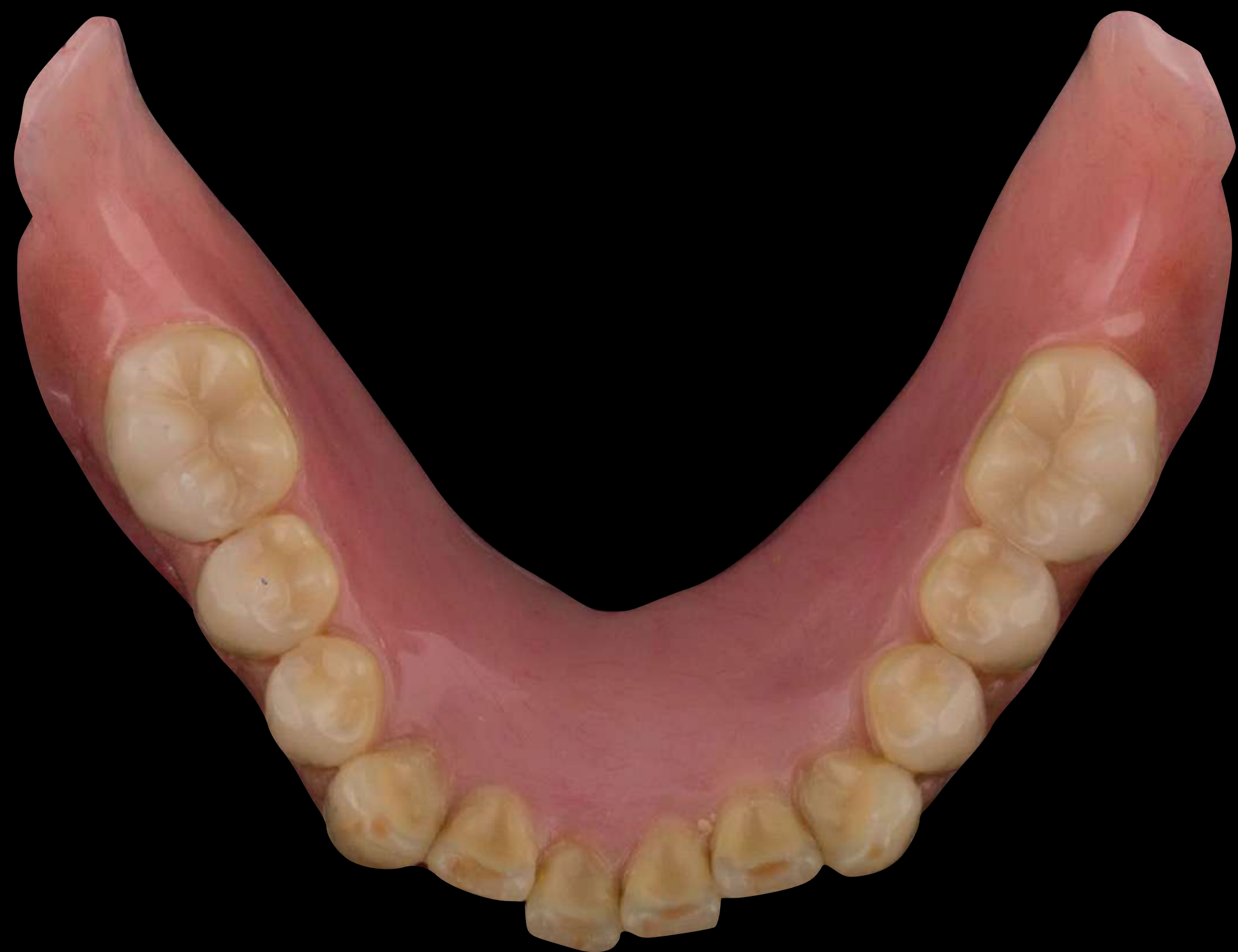Thank you for your brilliant work with my teeth. You have made me very happy and I would definitely recommend you to others. I can definitely smile with confidence and it's all you. Thank you both very much again. I will be back. I was very lucky to have been in this position. I am glad I came to you as you are brilliant! I will never forget

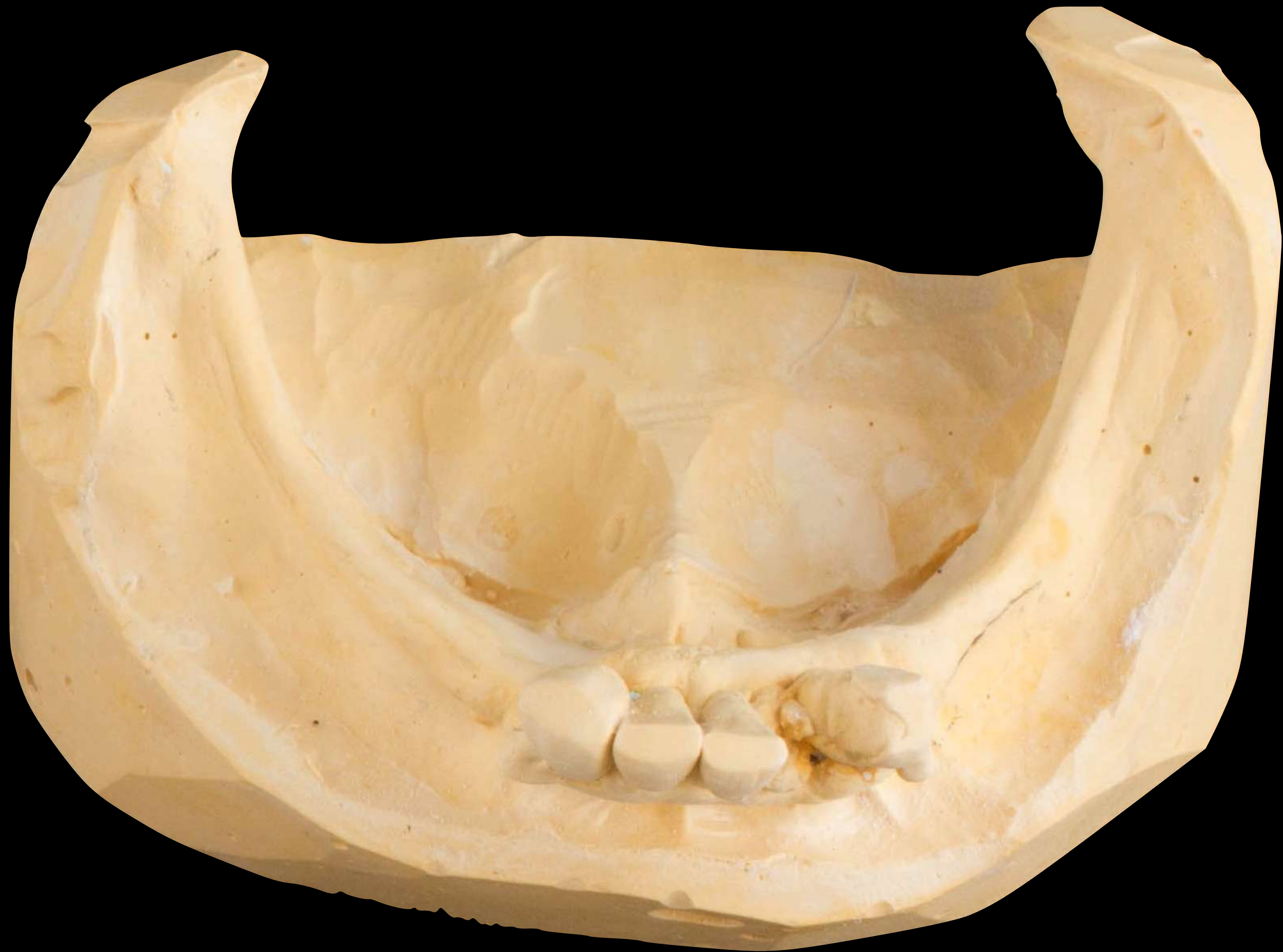Best of Luck

Till I visit again

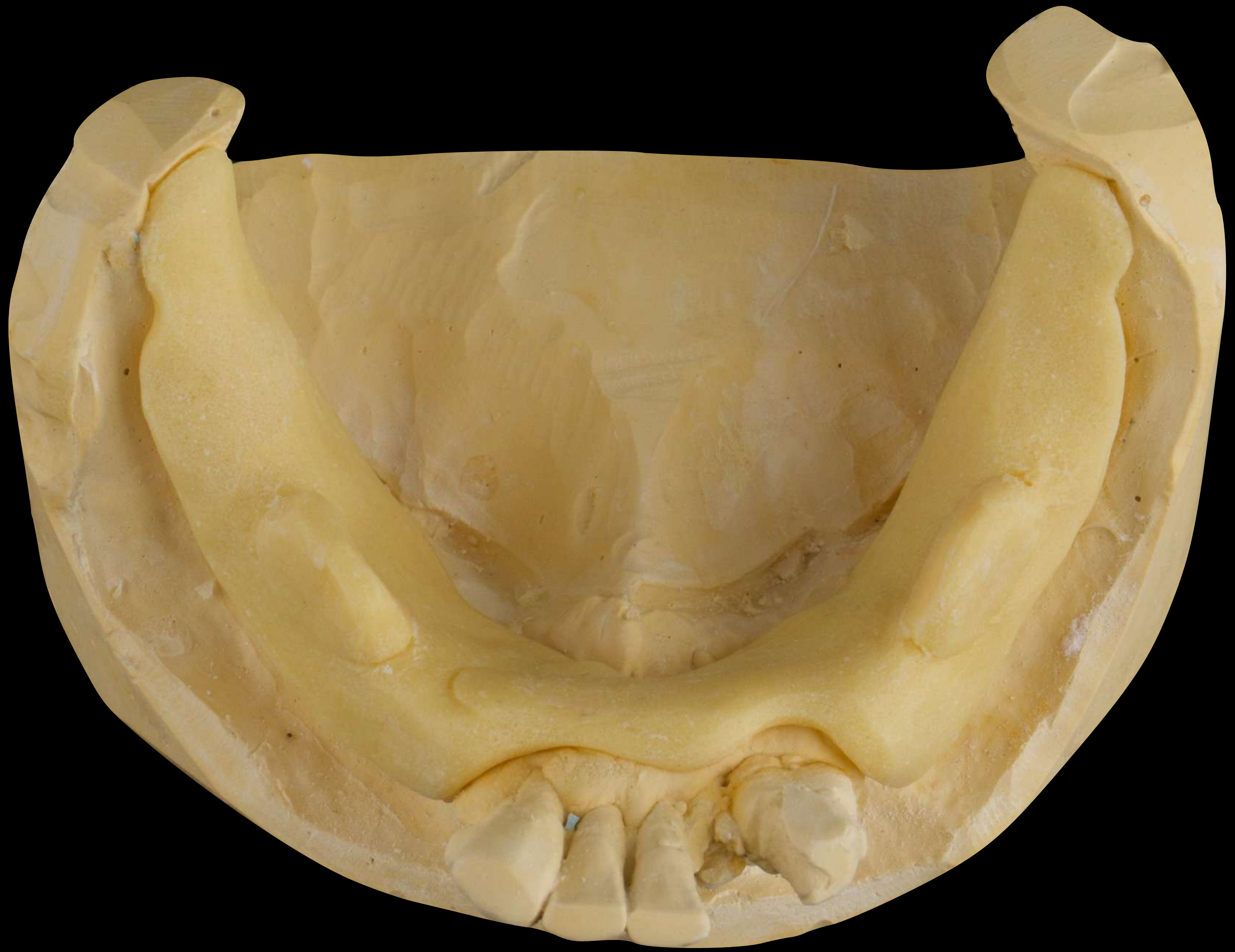Dian

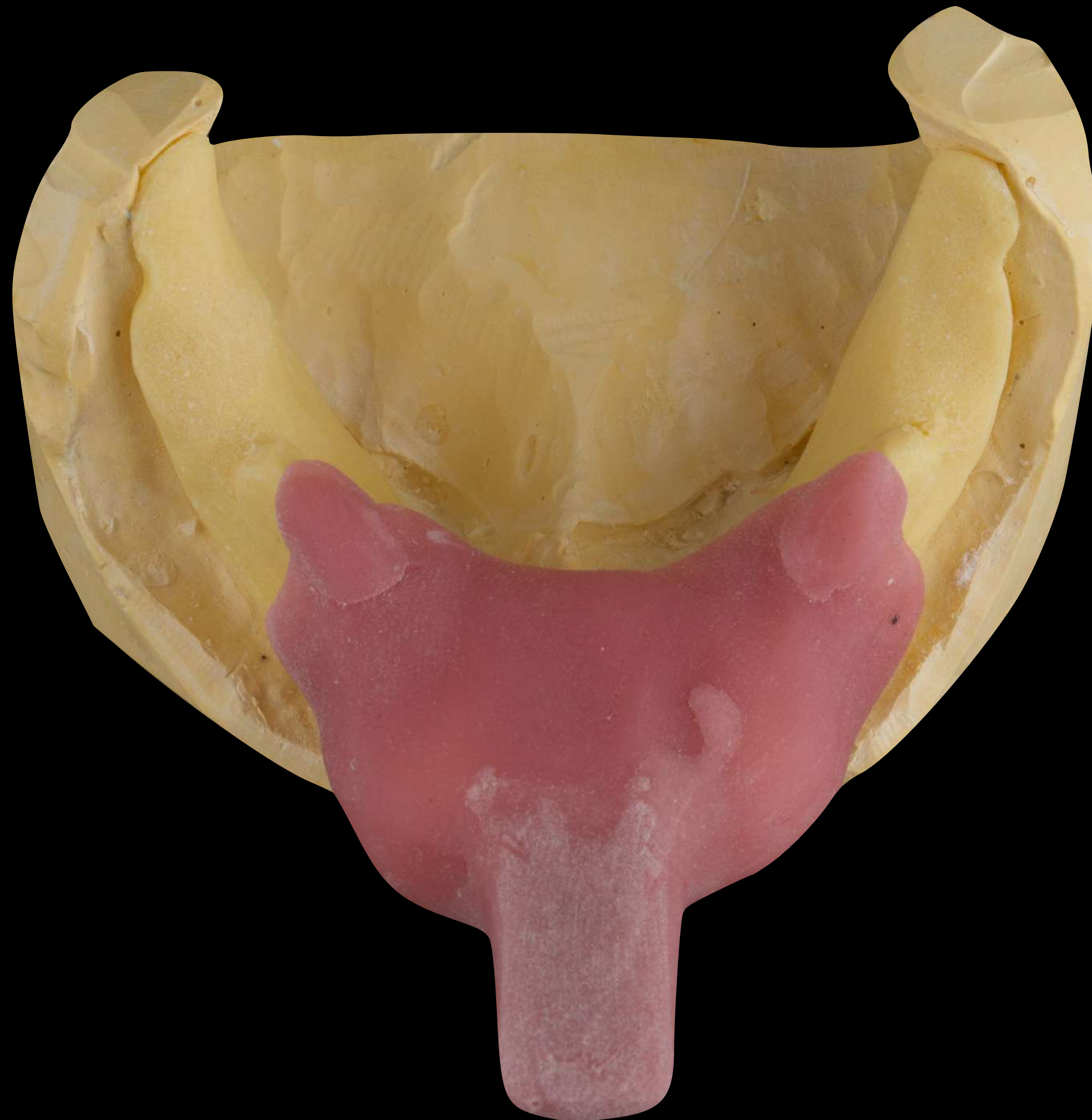Shape

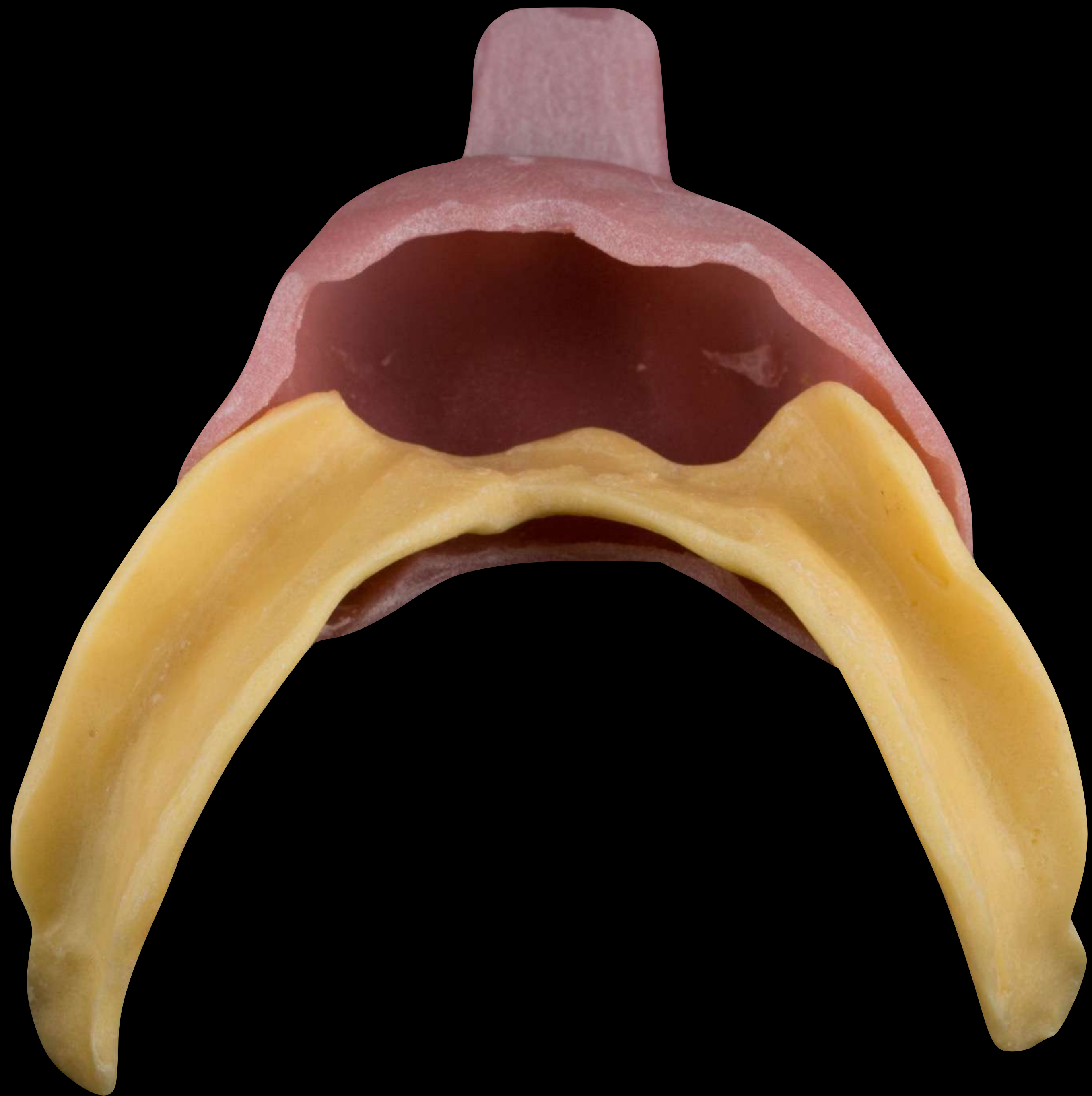


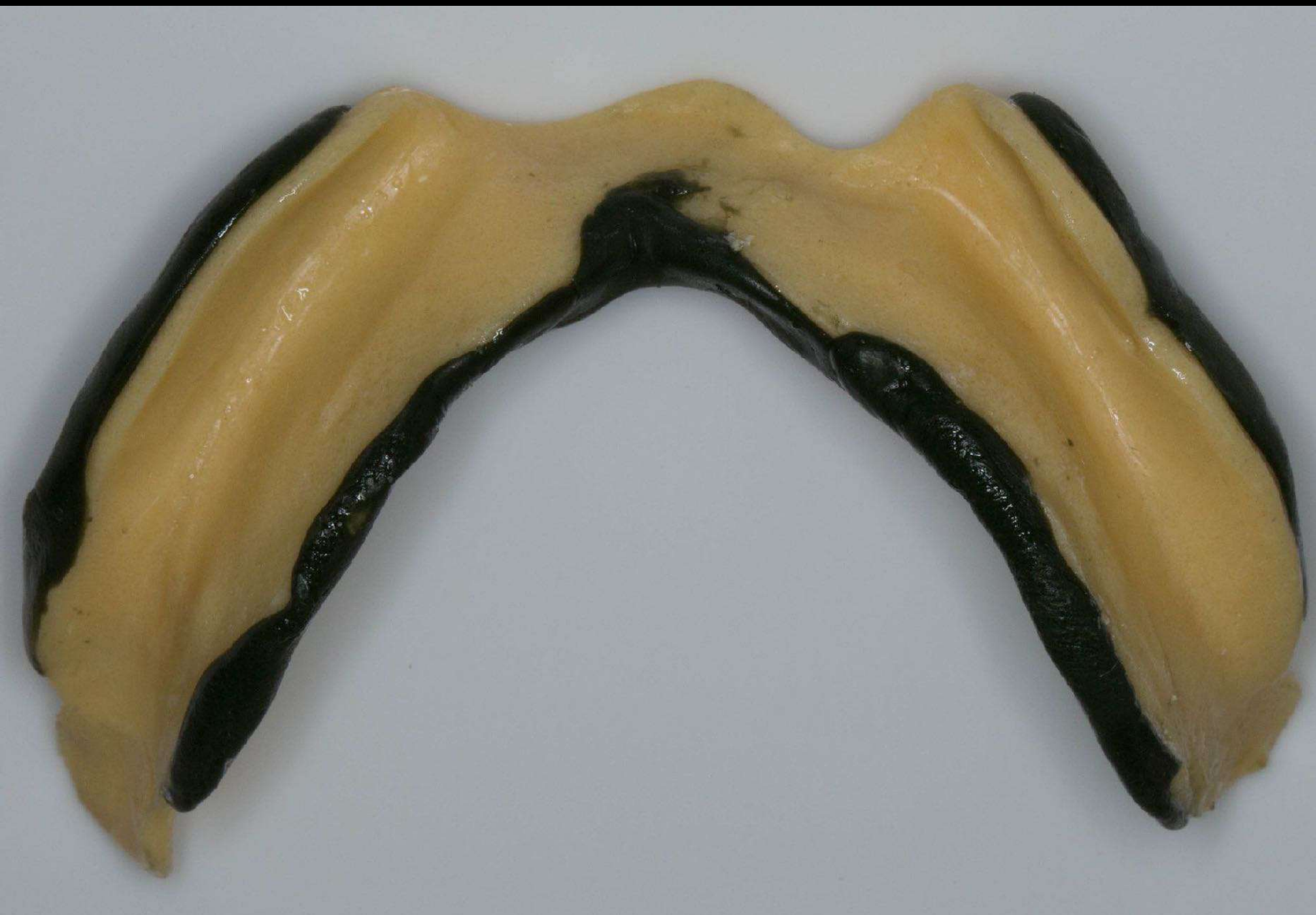
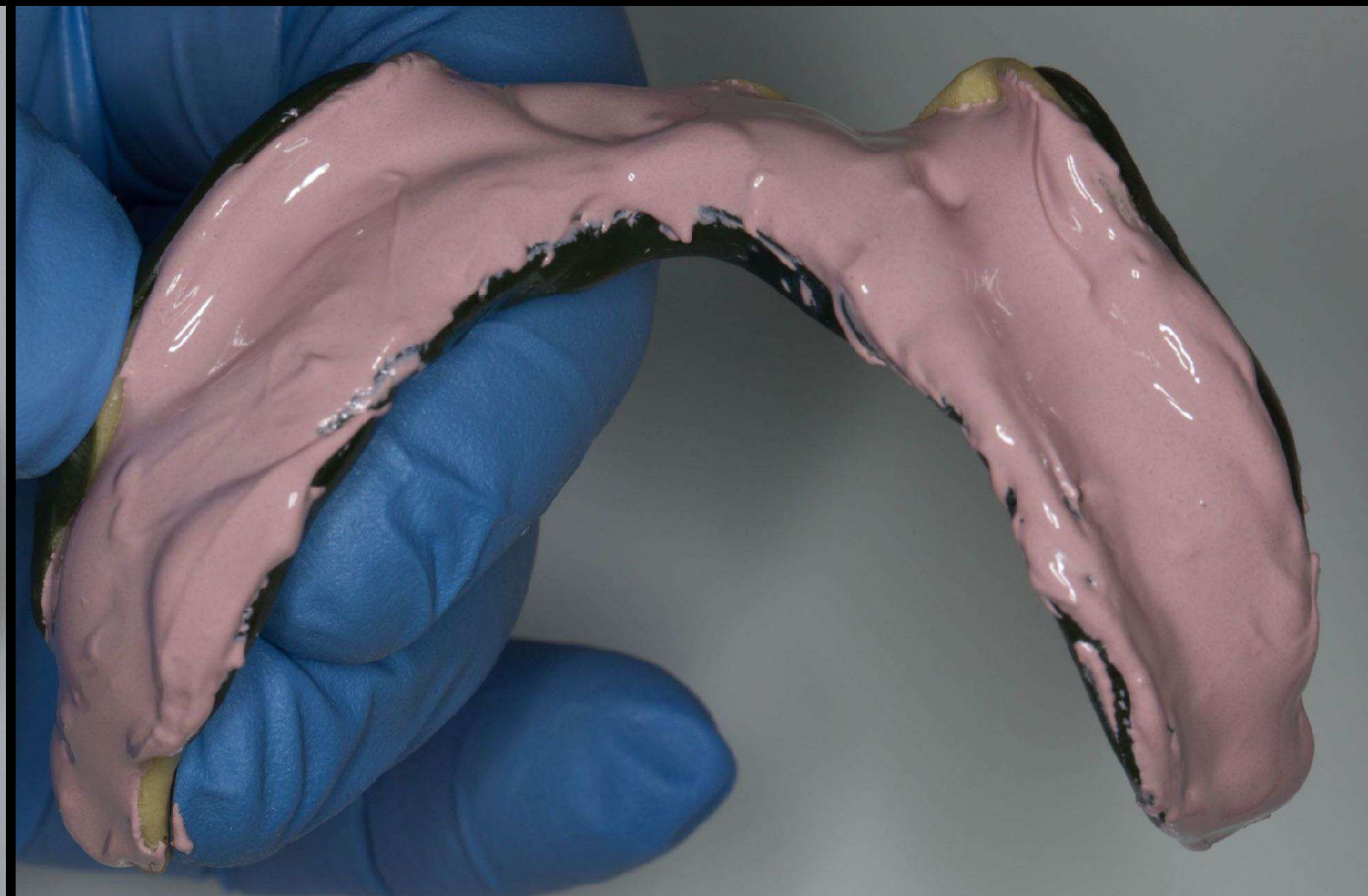





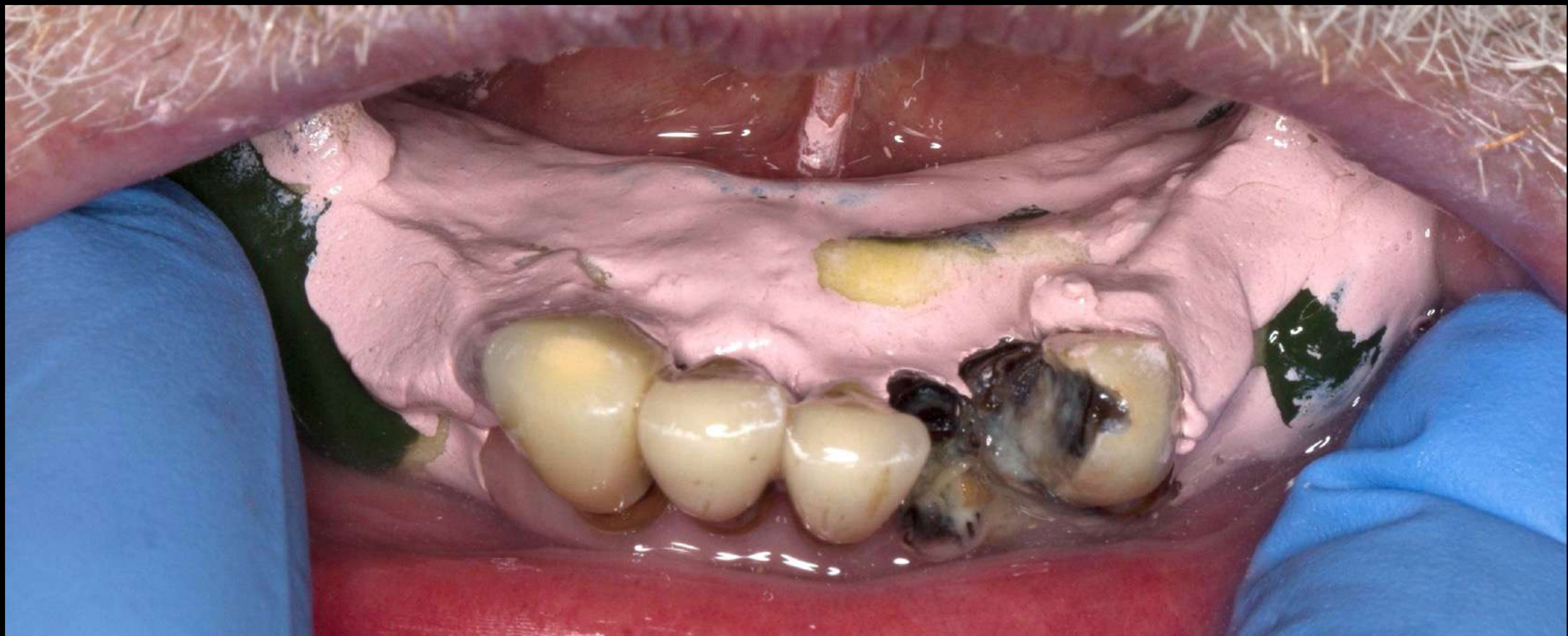
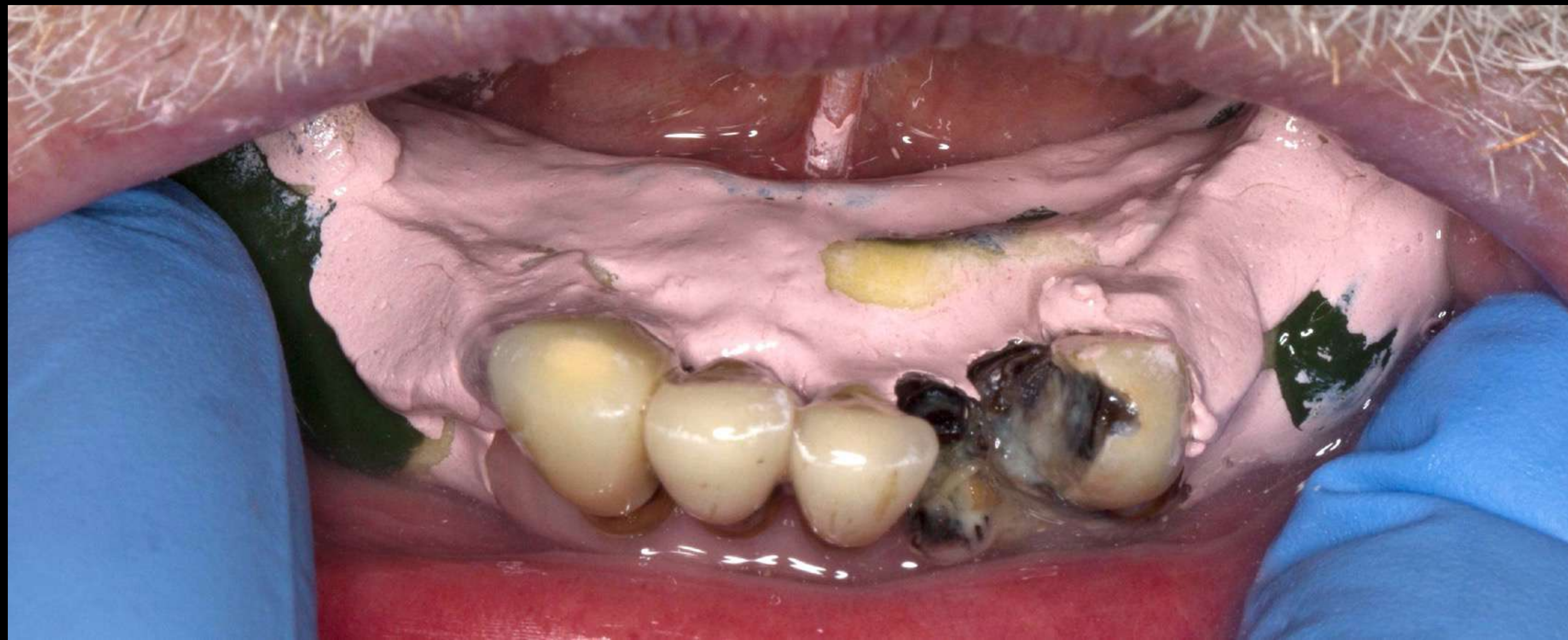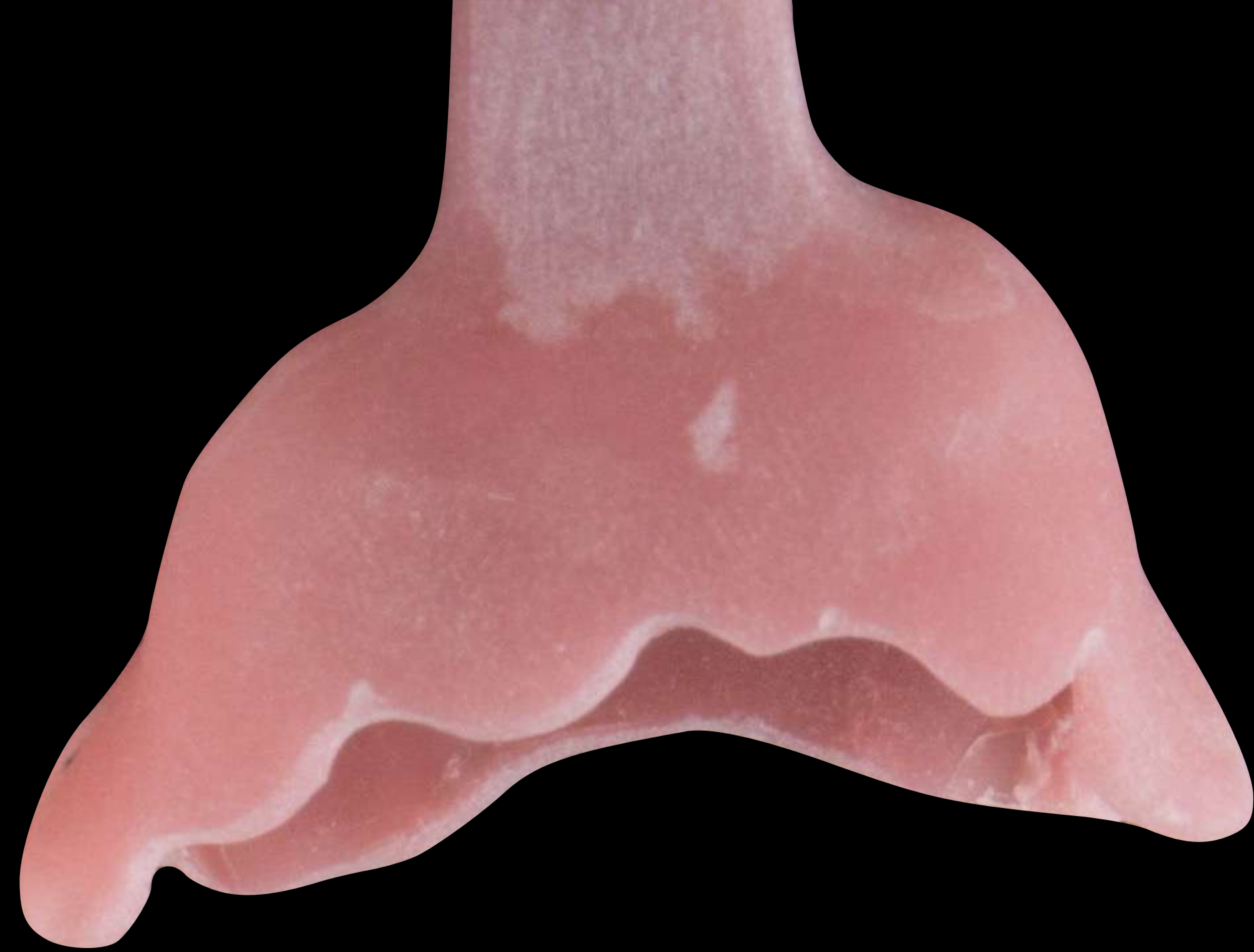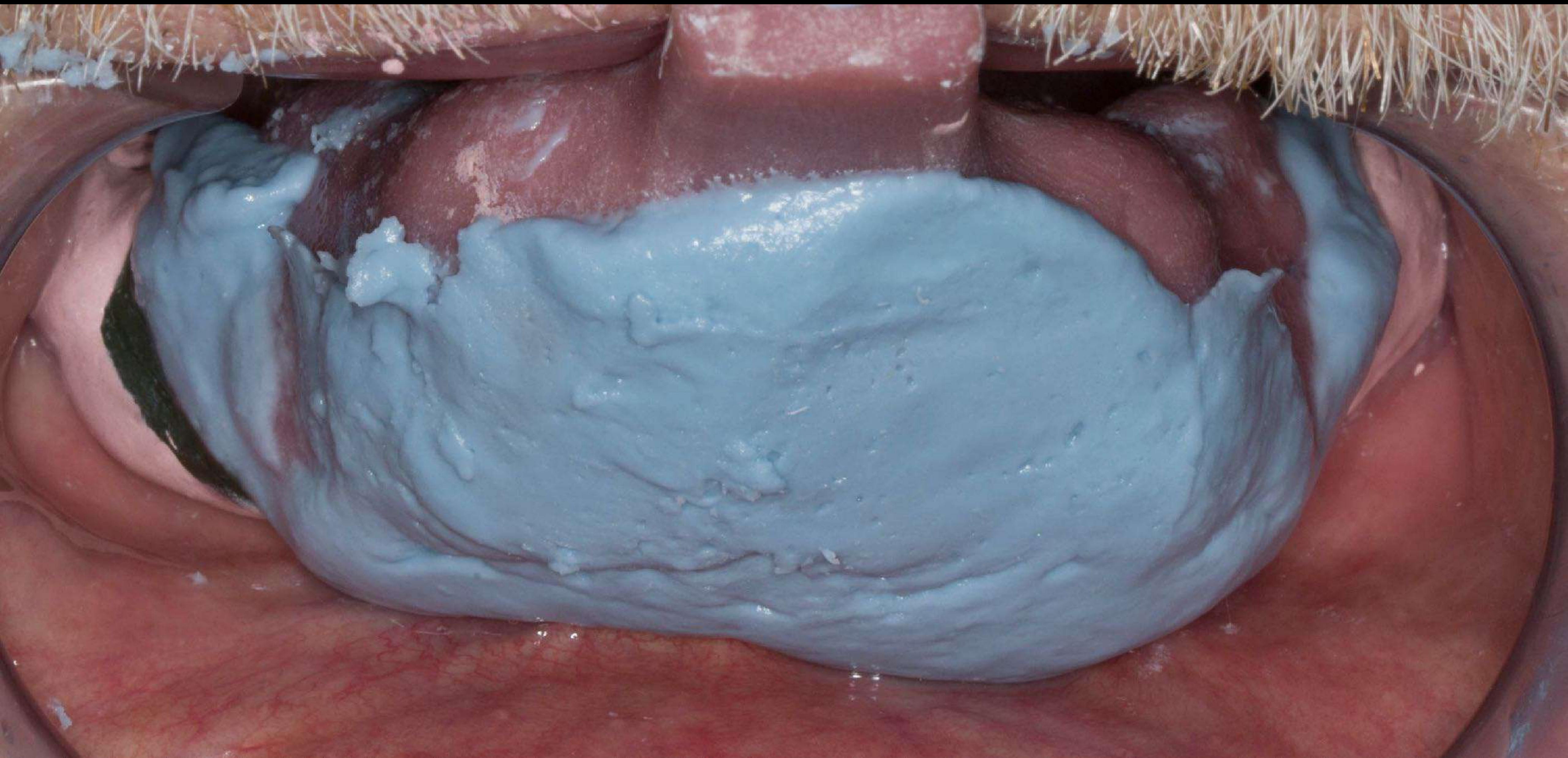










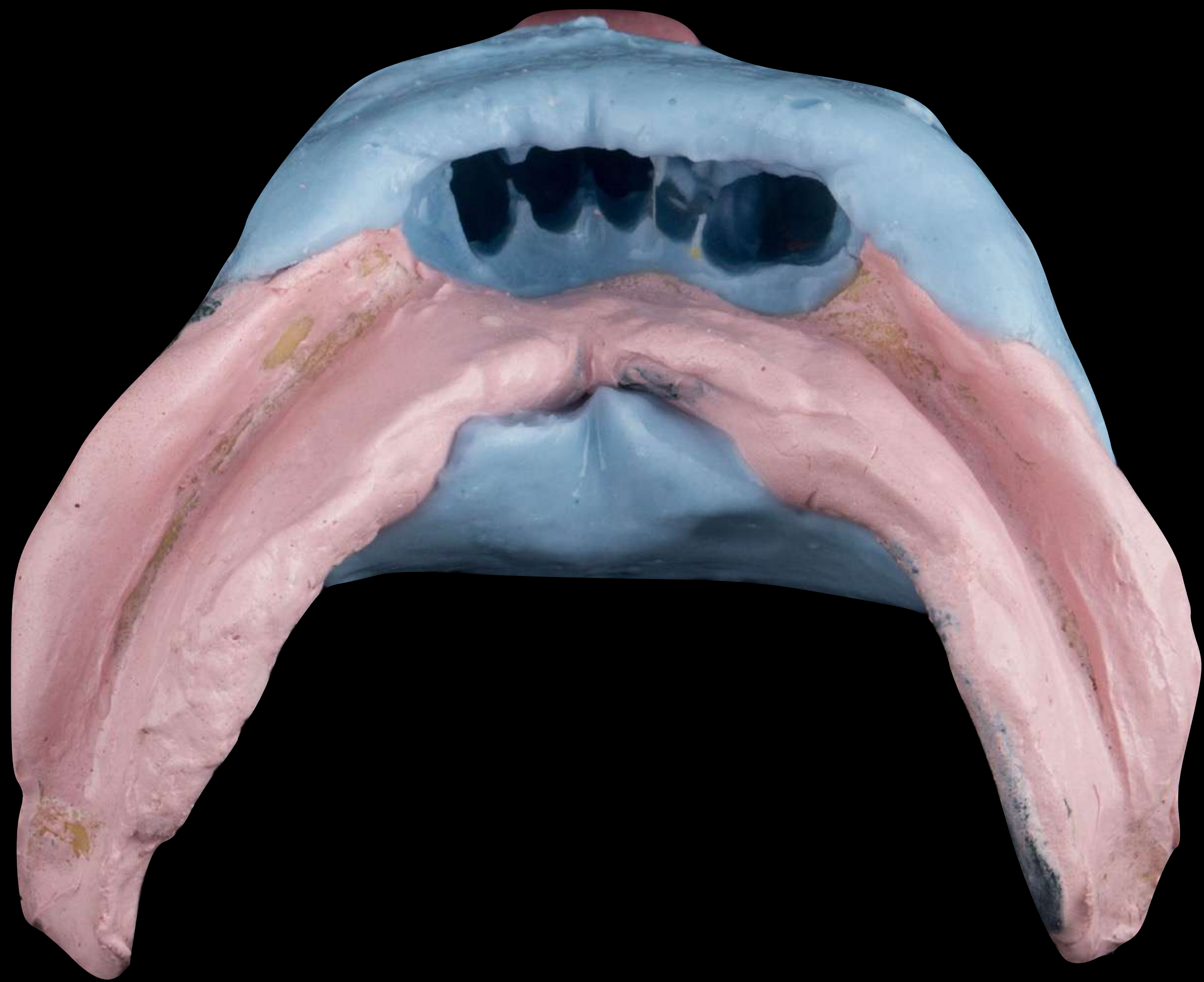


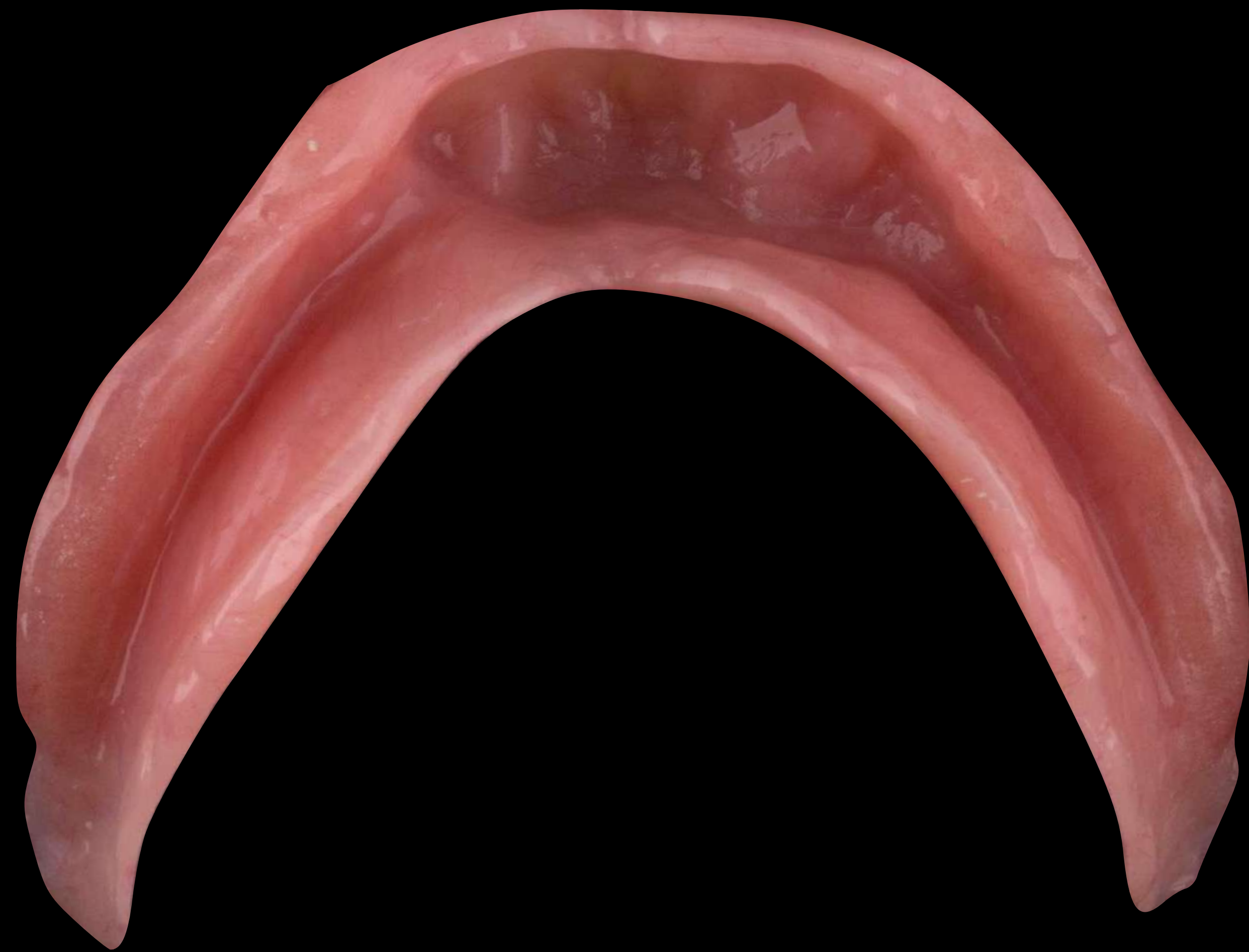




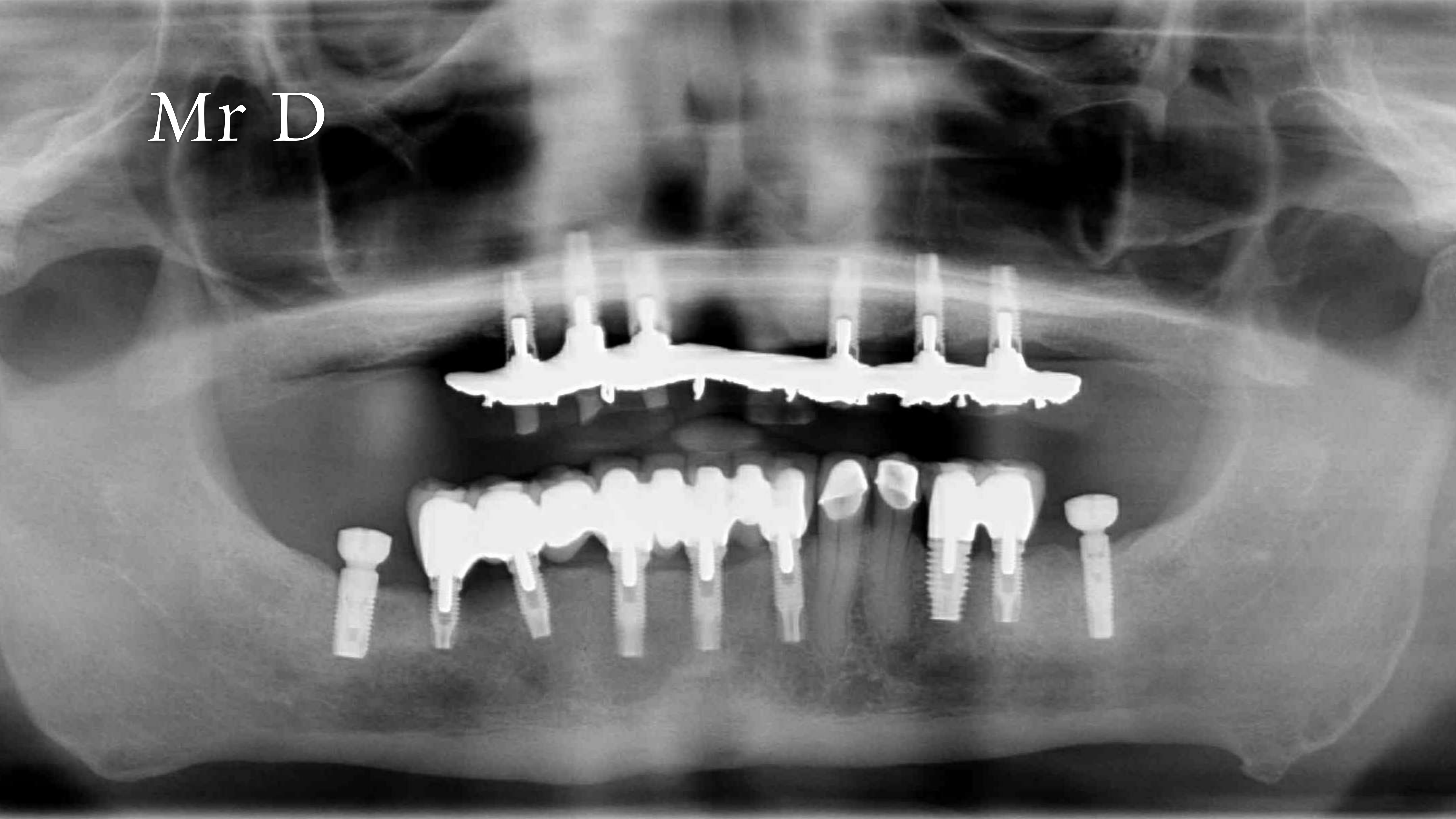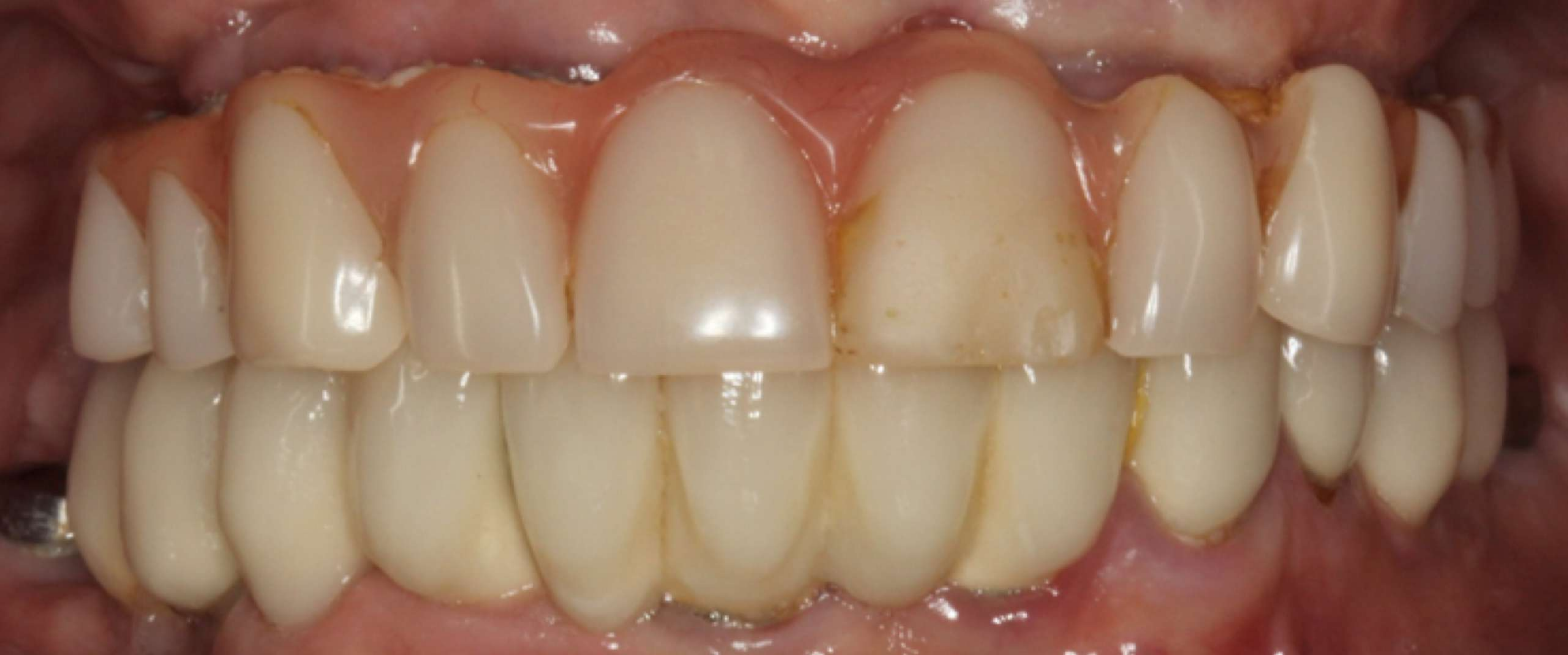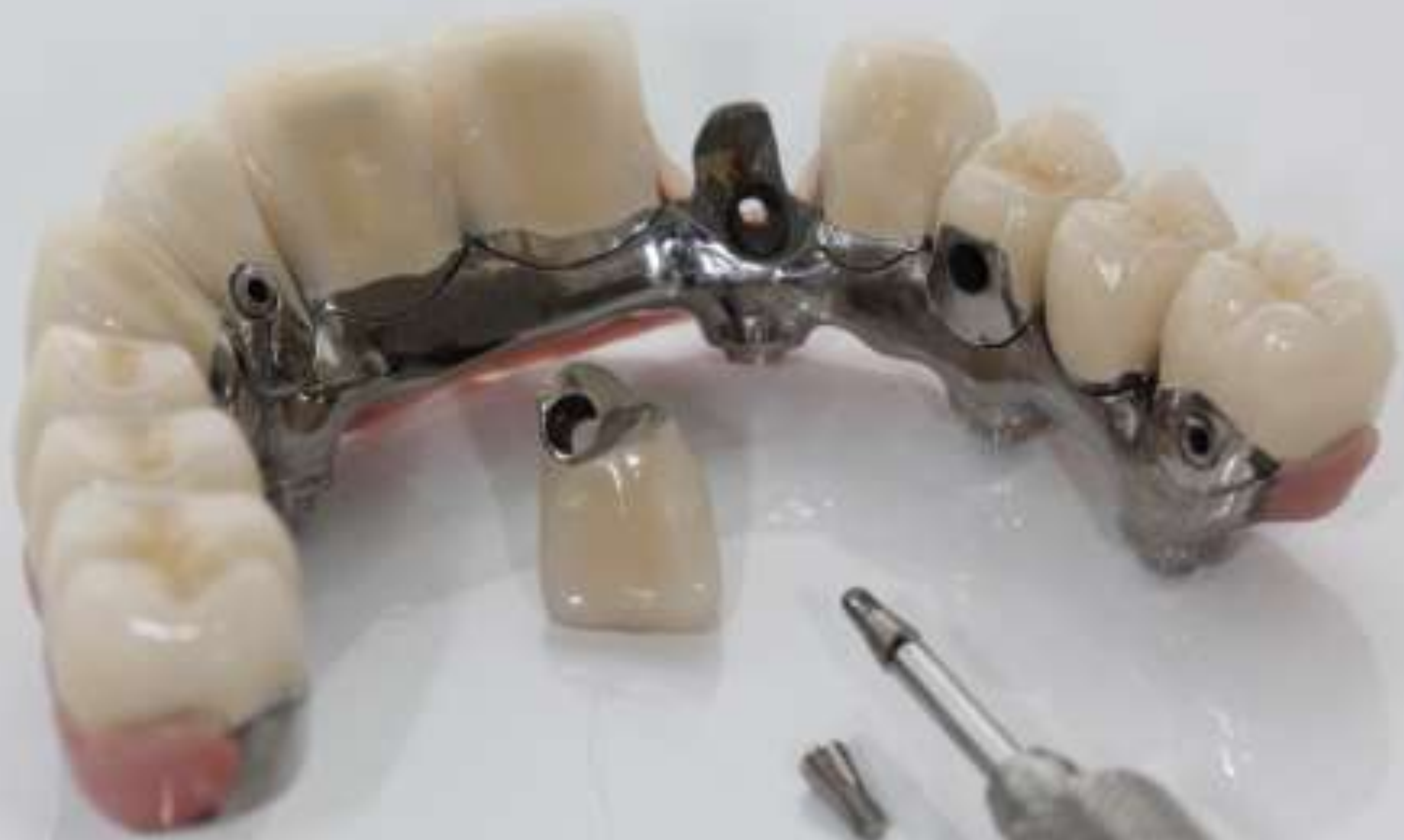Mr D



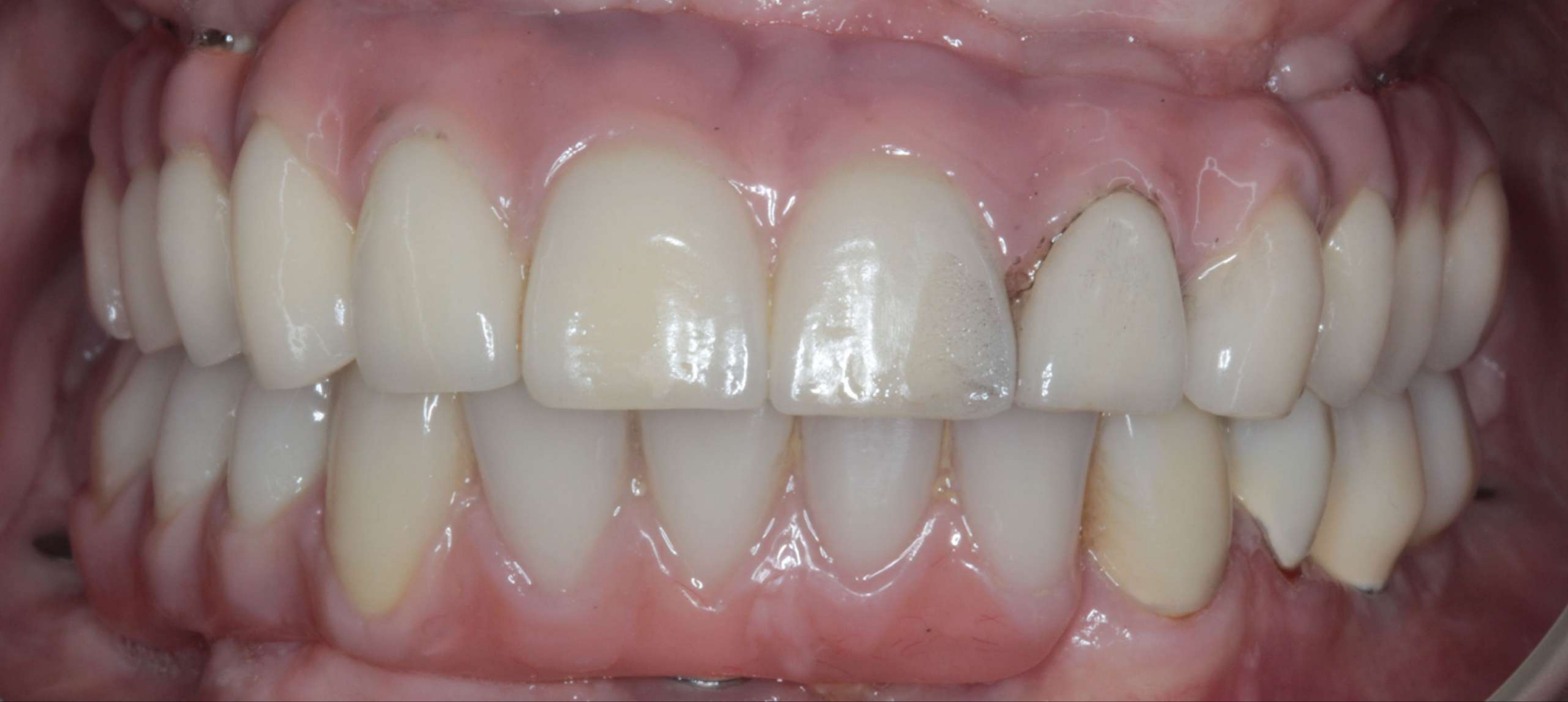

On arrival

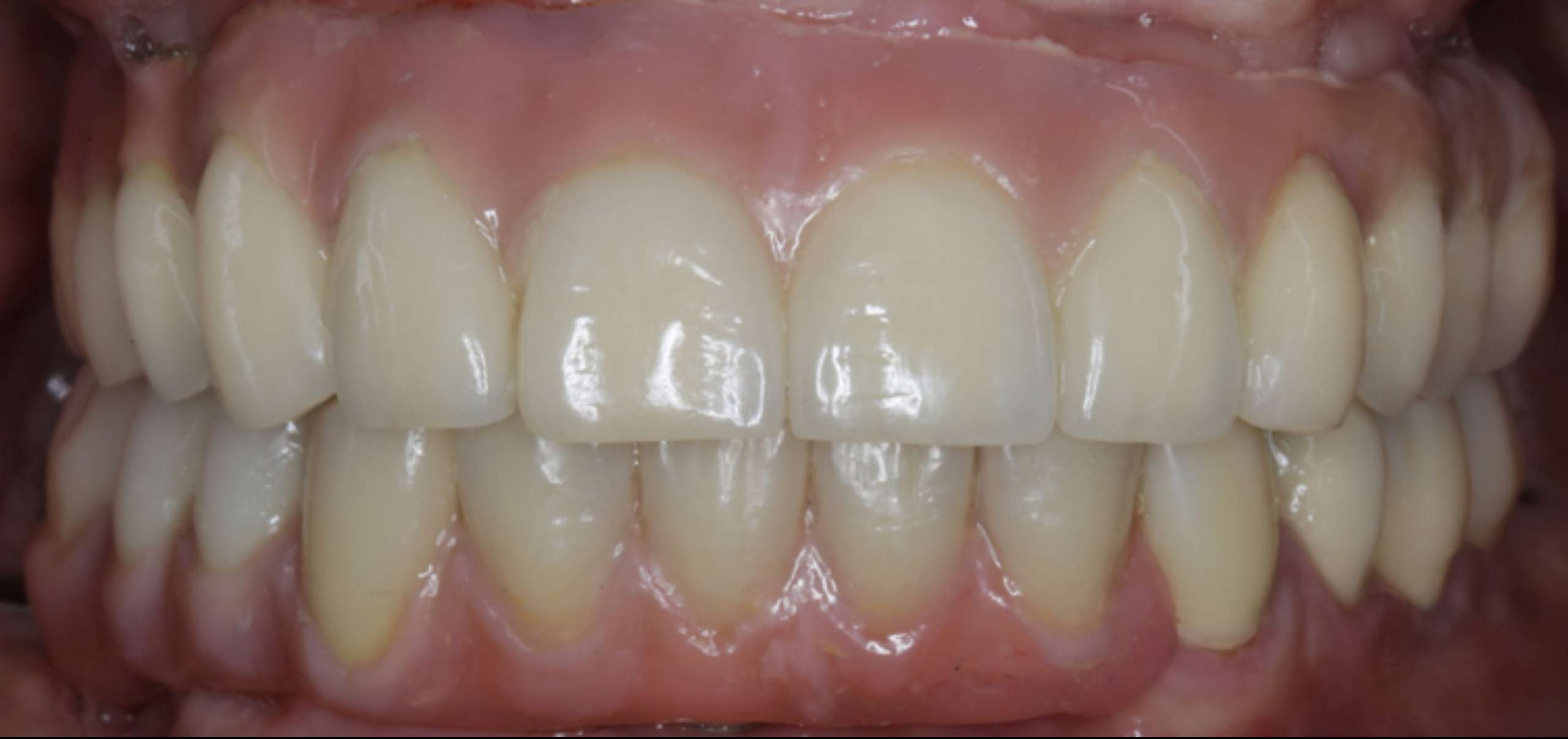

A dental arch model showing a metal bridge with a central abutment and a distal extension. The bridge is supported by a central abutment and a distal extension. The teeth are white and the metal is silver. A dental handpiece is visible in the lower right corner. The text "Fin, you idiot!" is overlaid on the bridge.

Fin, you idiot!

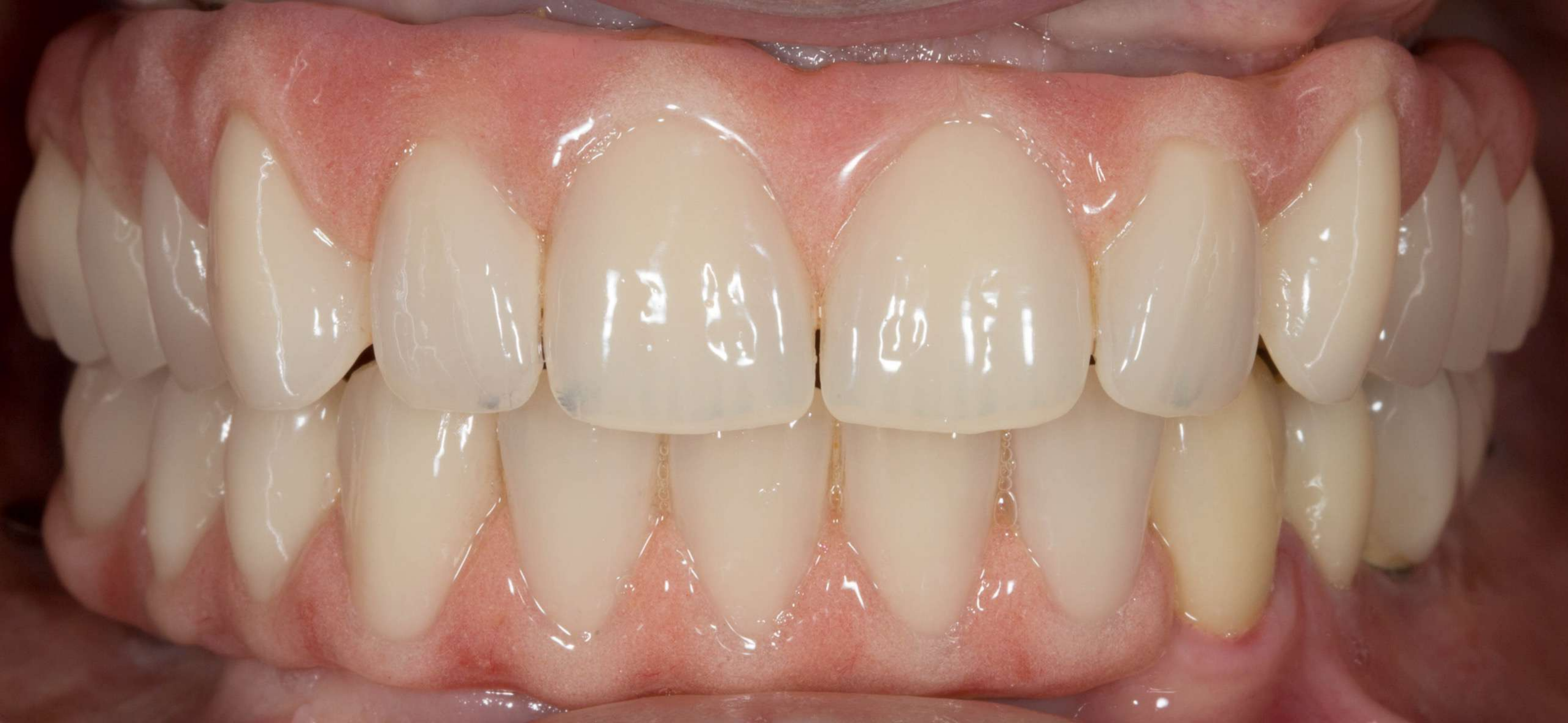

Ist attempt



2nd attempt





3rd attempt

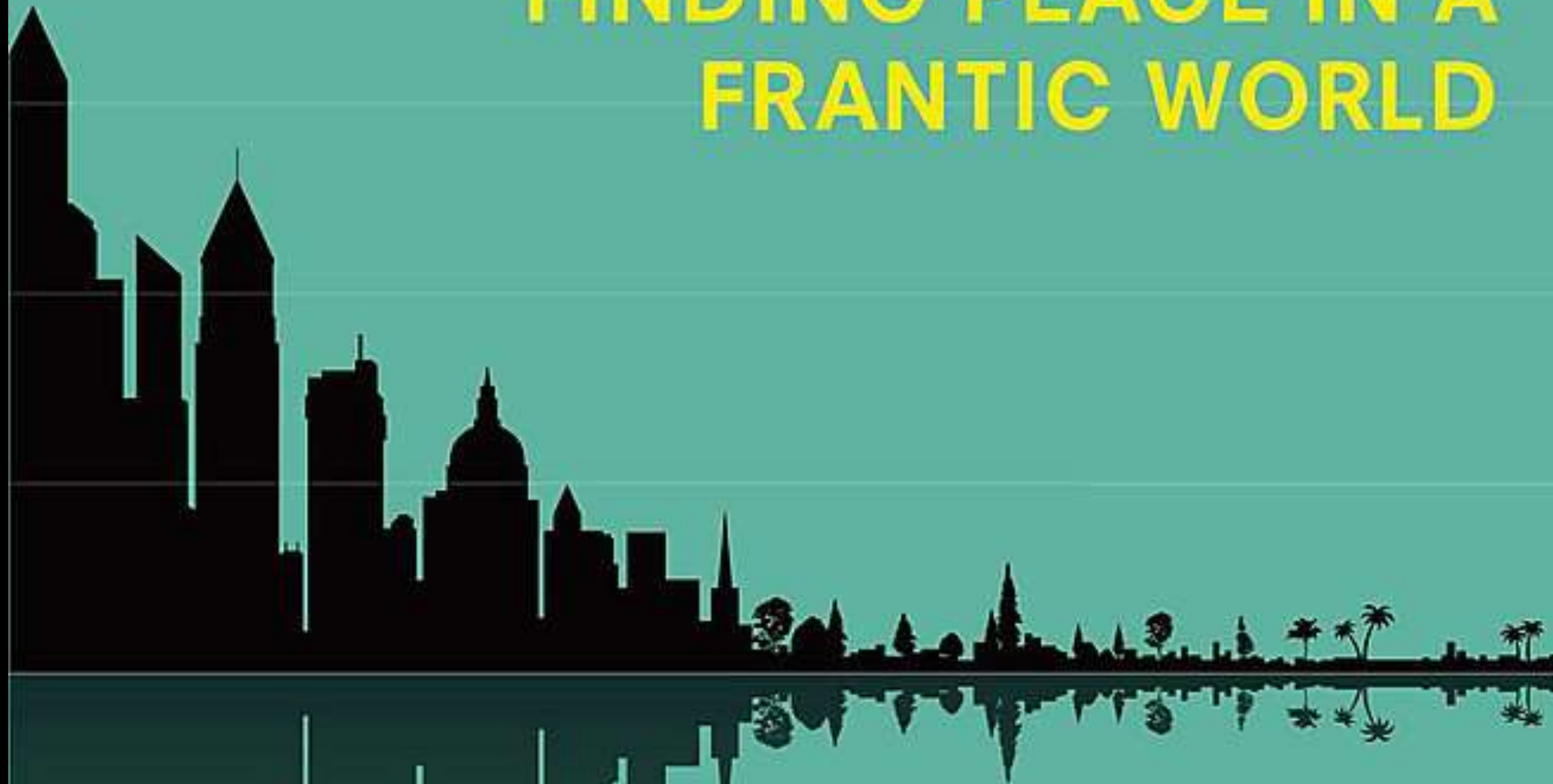John Riach  
Fin's Clinical Psychologist



INCLUDES FREE CD OF GUIDED MEDITATIONS

# Mindfulness

a practical guide to  
**FINDING PEACE IN A  
FRANTIC WORLD**



'If you want to free yourself from  
anxiety and stress, then read this book'

**RUBY WAX**

The  
life-changing  
bestseller

and **MARK WILLIAMS**  
**DANNY PENMAN**

Foreword by Jon Kabat-Zinn





# The Besford Study Club





